


WHAT'S NEW IN INTENSIVE CARE



Close collaboration between pathologists and intensivists to understand (not just) coronavirus disease

Christoph Brochhausen^{1,2}, Thomas Bein^{3*}  and Vittorio Fineschi⁴

© 2022 The Author(s)

Struggling with an unknown entity—challenge for intensivists

Despite improvements in imaging and diagnostic procedures in critically ill patients presenting with organ failure, uncertainty often exists with regard to the exact diagnosis and a corresponding targeted therapy. Recent studies have demonstrated an error rate of up to 44% in diagnosis after autopsy [1]. The novel coronavirus disease 2019 (COVID-19)—especially the associated severe acute respiratory syndrome—led to a rush of critically ill patients to intensive care units, which were neither prepared in terms of staff and logistic demands nor in terms of specific knowledge of such a new disease.

After a period of uncertainty and overload, more clinical insights into the ‘nature’ of the COVID-19 were revealed by autopsies. Assisted by pathologists, intensivists learnt to transfer such knowledge into therapeutic improvement. Specifically, the frequency of deep venous thrombosis or pulmonary embolism led to the adoption of an anticoagulation strategy. Autopsies, histopathological analyses, molecular findings, results of immunohistochemistry, and ultrastructural analyses had a direct impact, and, consequently, the pandemic started a new effective interdisciplinary collaboration, which should continue even beyond the pandemic.

Lightening pathophysiological shadows—crucial demand for clinical autopsies

Autopsy allows transparency by sharing [2] its results, and is crucial for risk mapping, root cause analysis, and identification of adverse events, even if some changes seen in autopsies may be post-mortem effects. Although their practice is decreasing, autopsies can have a significant impact on the quality of healthcare and its cost containment [3]. However, autopsy practice has been too easily relegated to the mere ascertainment for the sole purpose of diagnostic confirmation or matters of justice [4]. What has been overlooked, then, is how pathological changes can impact diagnostic procedures and the efficacy of therapies [5]. Therefore, autopsies play a fundamental role in understanding the pathophysiological mechanisms of diseases and potential therapeutic approaches [6].

An important and instructive example comes from the German experience with the recent pandemic, with the creation of the German Research Network for Autopsies in Pandemics (DEFEAT PANDEMICs). This network is highly organized at a national level to collect and share data, materials, and results as quickly as possible. Tissue sampling is followed by a diagnostic pathway using an extensive armamentarium of modern technologies. These include ribonucleic acid (RNA) sequencing, in situ hybridization, viral genome sequencing, RNA and proteome-wide gene expression analysis, innovative tissue imaging, and 3D reconstruction [7].

Today, the evidence regarding the thrombo-inflammatory mechanism underlying COVID-19, the diffuse alveolar damage, and the exuberant immune reaction characterized by cytokine production, known as the ‘cytokine storm,’ is the result of observations and answers

*Correspondence: thomas.bein@klinik.uni-regensburg.de

³ Faculty of Medicine, University Hospital Regensburg, Regensburg, Germany

Full author information is available at the end of the article

to specific questions asked by the clinician to the pathologist [8], which was not immediately possible when COVID-19 spread. However, the performance of clinical and forensic autopsies has revealed important aspects of the disease, clarifying morphological and virological features and promoting unexplored therapeutic approaches and new research frontiers [9].

Nevertheless, post-mortem investigation rates remain so low worldwide that the term ‘science blockade’ has been used to define the general reluctance towards autopsies. Each country has chosen to respond to this emergency situation with its own decisions. Countries such as Italy have chosen not to perform hospital autopsies, whereas countries like Germany—after initial procrastination—have mandated autopsies for all patients who died with a diagnosis of COVID-19 with a nationwide autopsy register [10]. Tissue collection during autopsy represents an invaluable source for research aimed at better defining controversial aspects of SARS-CoV-2 virulence and influencing potential new therapeutic strategies, even in COVID-19 survivors [11].

Recent studies investigate genetic susceptibility to COVID-19 and the prognostic value of specific loci. For example, the molecular biology of primary lung tissue is essential to understand the determinants of mortality in order to develop new precision therapies and to monitor the prognosis of the disease. Whole-transcriptome sequencing of autopsy lung tissue is critical to identify characteristic changes in the host transcriptome and unique microbial diversity in lung parenchyma of patients with severe COVID-19 [12].

As per acute distress respiratory syndrome (ARDS), validation of the vascular phenotype in the different causes represents an opportunity for vessel-targeted therapies, including promising ones like the trial of ANGPT1 supplementation in COVID-19 patients [13]. The study of cellular and molecular mechanisms underlying ineffective alveolar regeneration in ARDS and fibrosis may lead to new therapies to promote physiological regeneration, thereby accelerating restoration of barrier integrity, oedema resolution, ventilatory clearance, and survival in ARDS and prevention of fibrosis in fibroproliferative ARDS and idiopathic lung fibrosis [14]. Histopathological studies from deceased patients with ARDS caused by SARS-CoV-2 help us understand the thrombotic pathophenotype of SARS-CoV-2. ARDS is associated with increased expression of N9P in the pulmonary endothelium and colocalization of N9P-fibrin in the lumen of pulmonary arteries [15]. Furthermore, an association between N9P expression in the pulmonary

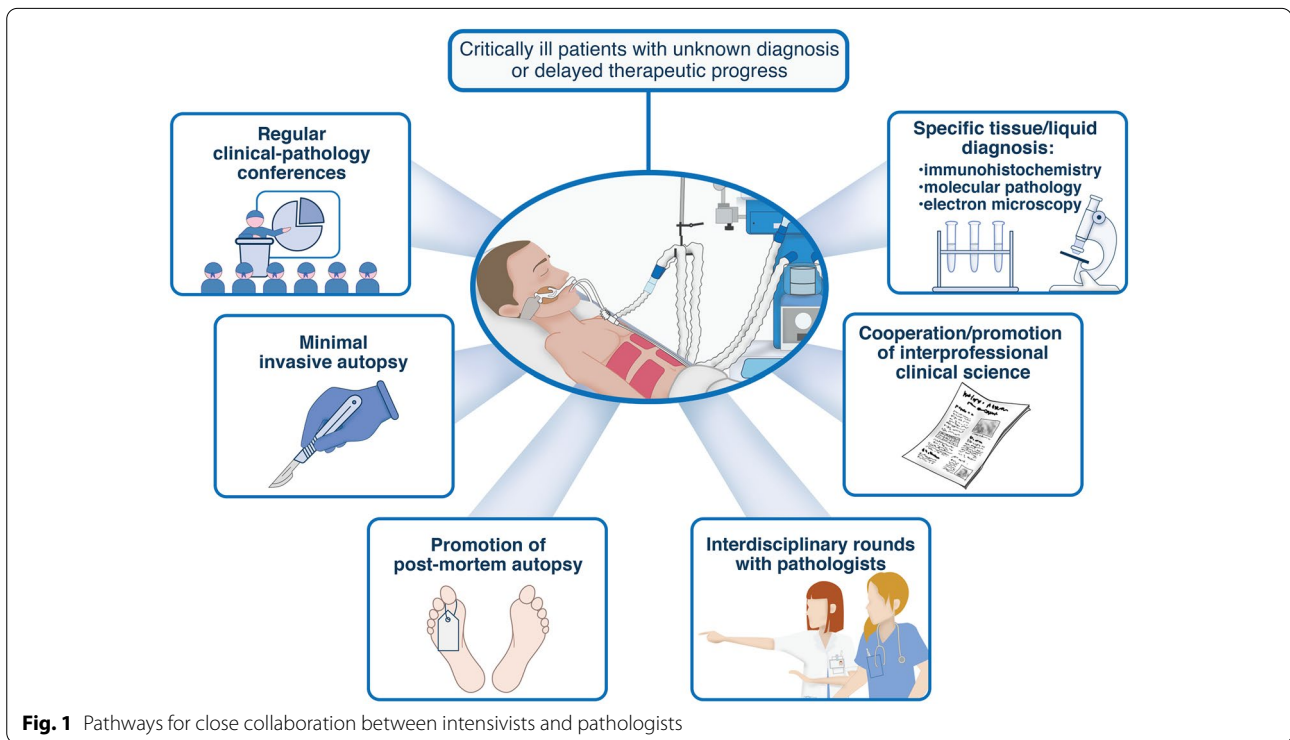
endothelium and ventilatory ratio was observed, suggesting that a clinically relevant correlation with histopathophenotypic data linking pulmonary vascular endothelial dysfunction to dead space fraction and a novel pathway by which NEDD9 may regulate pulmonary microthrombosis has been described: the formation of a protein complex with the $\beta 3$ subunit of $\alpha v\beta 3$ -integrin [16].

Formalizing interdisciplinary exchange—roadmap to optimize outcome in critical ill patients

Certainly, clinical–diagnostic sharing must be extended to biopsy procedures and fine-needle aspirates (FNA)—if appropriate, together with radiologists—with Rapid On-Site Assessment (ROSA) and immediate provisional diagnosis. This collaborative experience should also implement communication with patients and families in order to share diagnostic–therapeutic paths and to develop a consensus aimed at performing autopsies even when there are religious reasons against it, by offering valid alternative autopsy techniques [10].

The findings of autopsies regarding SARS-CoV-2 ushered in clinical improvements, and communication between pathologists and intensivists, which promotes a better understanding of the patho-mechanisms and causes of death. Regular clinical–pathological conferences on cases of critically ill patients, either with unknown diagnosis or delayed therapeutic progress, present an ideal platform to determine further diagnostic possibilities, such as immunohistochemical, molecular pathological, or even electron microscopical analyses in biopsies or cytological specimens. Hence, autopsies should be promoted in fatal cases, followed by interdisciplinary discussion and presentation of the pathological findings. Finally, interdisciplinary clinical science involving pathological findings should be promoted. To provide an appropriate platform for such efforts, a comprehensive database, including clinical, image, laboratory, and pathological findings, as also therapeutic strategy, is one lesson learned by coping with the pandemic (Fig. 1). Data and biomaterial collection over time is mandatory, since an autopsy study demonstrated differences in causes of death after long-term treatment of COVID-19 patients in intensive care [16].

In conclusion, our goal is to improve patient outcome by extrapolation from clinic–pathological autopsy studies. It is, therefore, appropriate to state that in the field of a closer collaboration between pathologists and intensivists, ‘*mors gaudet succurrere vitae*’ (‘death delights in helping life’) [5].



Author details

¹ Institute of Pathology, University Regensburg, Regensburg, Germany. ² Central Biobank Regensburg, University and University Hospital Regensburg, Regensburg, Germany. ³ Faculty of Medicine, University Hospital Regensburg, Regensburg, Germany. ⁴ Department of Anatomical, Histological, Forensic and Orthopedic Sciences, Institute of Legal Medicine, Sapienza University of Rome, Viale Regina Elena 336, 00161 Rome, Italy.

Funding

Open Access funding enabled and organized by Projekt DEAL.

Declarations

Conflicts of interest

All the authors declare no conflicts of interest.

Open Access

This article is licensed under a Creative Commons Attribution-NonCommercial 4.0 International License, which permits any non-commercial use, sharing, adaptation, distribution and reproduction in any medium or format, as long as you give appropriate credit to the original author(s) and the source, provide a link to the Creative Commons licence, and indicate if changes were made. The images or other third party material in this article are included in the article's Creative Commons licence, unless indicated otherwise in a credit line to the material. If material is not included in the article's Creative Commons licence and your intended use is not permitted by statutory regulation or exceeds the permitted use, you will need to obtain permission directly from the copyright holder. To view a copy of this licence, visit <http://creativecommons.org/licenses/by-nc/4.0/>.

Publisher's Note

Springer Nature remains neutral with regard to jurisdictional claims in published maps and institutional affiliations.

Received: 18 July 2022 Accepted: 13 October 2022

Published online: 02 November 2022

References

- Tejerina E, Esteban A, Fernández-Segoviano P, María Rodríguez-Barbero J, Gordo F, Frutos-Vivar F, Aramburu J, Algaba A, Gonzalo Salcedo García O, Lorente JA (2012) Clinical diagnoses and autopsy findings: discrepancies in critically ill patients. *Crit Care Med* 40:842–846
- Hanley B, Lucas SB, Youd E, Swift B, Osborn M (2020) Autopsy in suspected COVID-19 cases. *J Clin Pathol* 73:239–242
- Welsh TS, Kaplan J (1998) The role of postmortem examination in medical education. *Mayo Clin Proc* 73:802–805
- Bertozzi G, Ferrara M, Maiese A, Di Fazio N, Delogu G, Frati P, La Russa R, Fineschi V (2022) COVID-19 and H1N1-09: a systematic review of two pandemics with a focus on the lung at autopsy. *Front Biosci (Landmark Ed)* 27(6):182
- D'Errico S, Zanon M, Peruch M, Concato M, Padovano M, Santurro A, Scopetti M, Fineschi V (2021) Mors gaudet succurrere vitae. The role of clinical autopsy in preventing litigation related to the management of liver and digestive disorders. *Diagnostics (Basel, Switzerland)* 11(8):1436. <https://doi.org/10.3390/diagnostics11081436>
- D'Errico S, Zanon M, Montanaro M, Radaelli D, Sessa F, Di Mizio G, Montana A, Corrao S, Salerno M, Pomara C (2020) More than pneumonia: distinctive features of SARS-Cov-2 infection from autopsy findings to clinical implications: a systematic review. *Microorganisms* 8(11):1642
- Jonigk D, Werlein C, Acker T et al (2022) Organ manifestations of COVID-19: what have we learned so far (not only) from autopsies? *Virchows Arch* 481:139–159. <https://doi.org/10.1007/s00428-022-03319-2>
- Frisoni P, Neri M, D'Errico S, Alfieri L, Bonuccelli D, Cingolani M, Di Paolo M, Gaudio RM, Lestani M, Marti M, Martelloni M, Moreschi C, Santurro A, Scopetti M, Turriziani O, Zanon M, Scendoni R, Frati P, Fineschi V (2022) Cytokine storm and histopathological findings in 60 cases of COVID-19-related death: from viral load research to immunohistochemical

-
- quantification of major players IL-1 β , IL-6, IL-15 and TNF- α . *Foren Sci Med Pathol* 18(1):4–19
9. To KK, Sridhar S, Chiu KH, Hung DL, Li X, Hung IF et al (2021) Lessons learned 1 year after SARS-CoV-2 emergence leading to COVID-19 pandemic. *Emerg Microbes Infect* 10:507–535
 10. Price DR, Benedetti E, Hoffman KL, Gomez-Escobar L, Alvarez-Mulet S, Capili A, Sarwath H, Parkhurst CN, Lafond E, Weidman K, Ravishankar A, Cheong JG, Batra R, Büyükközkın M, Chetnik K, Easthausen I, Schenck EJ, Racanelli AC, Outtz Reed H, Laurence J, Rafi S (2022) Angiopoietin 2 is associated with vascular necroptosis induction in coronavirus disease 2019 acute respiratory distress syndrome. *Am J Pathol* 192(7):1001–1015
 11. Budh Raja A, Basu A, Gheware A, Abhilash D, Rajagopala S, Pakala S, Sumit M, Ray A, Subramaniam A, Mathur P, Nambirajan A, Kumar S, Gupta R, Wig N, Trikha A, Guleria R, Sarkar C, Gupta I, Jain D (2022) Molecular signature of postmortem lung tissue from COVID-19 patients suggests distinct trajectories driving mortality. *Dis Models Mech* 15(5):dmm049572
 12. Ting C, Aspal M, Vaishampayan N, Huang SK, Riemondy KA, Wang F, Farver C, Zemans RL (2022) Fatal COVID-19 and Non-COVID-19 acute respiratory distress syndrome is associated with incomplete alveolar type 1 epithelial cell differentiation from the transitional state without fibrosis. *Am J Pathol* 192(3):454–467
 13. Castro P, Palomo M, Moreno-Castaño AB, Fernández S, Torramadé-Moix S, Pascual G, Martínez-Sánchez J, Richardson E, Téllez A, Nicolas JM, Carreras E, Richardson PG, Badimon JJ, Escolar G, Díaz-Ricart M (2022) Is the endothelium the missing link in the pathophysiology and treatment of COVID-19 complications? *Cardiovasc Drugs Ther* 36(3):547–560
 14. Alba GA, Samokhin AO, Wang RS, Wertheim BM, Haley KJ, Padera RF, Vargas SO, Rosas IO, Hariri LP, Shih A, Thompson BT, Mitchell RN, Maron BA (2022) Pulmonary endothelial NEDD9 and the prothrombotic pathophenotype of acute respiratory distress syndrome due to SARS-CoV-2 infection. *Pulm Circ* 12(2):e12071
 15. von Stillfried S, Bülow RD, Röhrig R, Boor P, German Registry of COVID-19 Autopsies (DeRegCOVID), DeRegCOVID Collaborators (2022) First report from the German COVID-19 autopsy registry. *Lancet Reg Health Eur* 15:100330. <https://doi.org/10.1016/j.lanepe.2022.100330>
 16. Evert K, Dienemann T, Brochhausen C, Lutz D, Lubnow M, Ritzka M, Keil F, Trummer M, Scheiter A, Salzberger B, Reischl U, Boor P, Gessner A, Jantsch J, Calvisi DF, Evert M, Schmidt B, Simon M (2021) Autopsy findings after long-term treatment of COVID-19 patients with microbiological correlation. *Virchows Arch* 479:97–108