

ORIGINAL ARTICLE**TREATMENT OF IDIOPATHIC CLUBFOOT BY PONSETI TECHNIQUE OF MANIPULATION AND SERIAL PLASTER CASTING AND ITS CRITICAL EVALUATION****Sharma Pulak^{1*}, Swamy MKS¹****ABSTRACT**

BACKGROUND: Clubfoot has from long been an unsolved clinical challenge for the orthopedic surgeons. It is one of the commonest congenital deformities in children. More than 100,000 babies are born worldwide each year with congenital clubfoot. Around 80% of the cases occur in developing nations.

METHODS: Fifty three feet [mean Pirani score (total) 5.6] in 40 children were treated by the Ponseti method from June 2006 to December 2010. A prospective follow-up for a mean duration of 19.5 months (range 6–30 months) was undertaken. Evaluation of the deformity by Pirani score and goniometry was performed, before and after the treatment and the results were assessed through Wilcoxon signed rank test.

RESULTS: The average number of casts applied before full correction was 4.9. The duration of casts for more than 85% feet was <7 weeks. 94.3% patients needed tenotomy before full correction. There was a significant difference in the pre-treatment and the post-treatment Pirani score and goniometry values.

CONCLUSION: Ponseti method of manipulation and plaster casting is very effective in correcting clubfoot deformity. It is especially important in developing countries and well-trained physicians and health personnel can manage the cases effectively by manipulation and cast application.

KEYWORDS: Clubfoot, Pirani score, Ponseti

INTRODUCTION

Clubfoot has from long been an unsolved clinical challenge for the orthopedic surgeons. The problem is more serious in the developing countries on account of late presentation; higher rate of dropouts (of treatment) and superstitious beliefs attached to this congenital problem.

The literature is abound with wealth of information regarding various modalities of treatment ranging from bandages by Hippocrates and plaster casts by Kite to surgical treatment but still there is no single modality till date that can boast of achieving the ultimate goal of treatment i.e. to achieve a functional, pain-free, plantigrade foot with good mobility and without calluses(1).

Nonsurgical management generally led to inadequate correction whereas those children with idiopathic clubfoot who underwent surgery often developed extensive scarring of the soft tissues and residual pain. But these statements have been frequently sidelined by those people who use Ponseti method of serial manipulation and casting.

Ponseti claims to avoid open surgery in 89% of cases by using his technique of manipulation, casting, and limited surgery (2). Cooper and Dietz reviewed Ponseti's cases, with an average of 30 years of follow-up, and found that 78% of the patients had achieved excellent or good functional and clinical outcomes compared with 85% in a control group without congenital foot deformity (3).

¹ Central Institute of Orthopedics, Vardhmann Mahavir Medical College & Safdarjung Hospital, New Delhi, India.

*Corresponding Author, A2-403 ,Glaxo App., Mayur Vihar Phase 1, New Delhi-110091, India
e-mail: drpulaksharma@rediffmail.com

Careful evaluation of Ponseti technique and the results of manipulation were done with the aim of;

- Studying the effectiveness of Ponseti's technique of plaster cast application in the management of idiopathic clubfoot.
- Assessing the deformity using Pirani severity score & goniometry; and try to correlate the result of the goniometric evaluation with the Pirani severity score.

PATIENTS AND METHODS

The study was conducted from June 2006 to December 2010. Forty cases with 53 clubfeet were taken up for the study and were prospectively studied. The International Guidelines for Biomedical Research involving Human Subjects issued by CIOMS, (Geneva 1982) were compiled and a formal ethical committee clearance was undertaken before the study.

The Inclusion Criteria were: age less than two years, unilateral or bilateral idiopathic clubfoot and willingness to take part in the study while the Exclusion Criteria were: age more than two years, earlier treated with other methods of plaster cast application, earlier operated for clubfoot, concomitant major illness, atypical or secondary clubfoot and unwillingness to take part in the study.

Patients were evaluated through detailed history and physical examination. They were investigated by routine blood and urine

investigations to rule out any accompanying medical or surgical problem. Every clubfoot taken up for the study was graded according to the Pirani Severity score for hind foot, mid foot and total score & and also goniometric assessment of the deformities of clubfeet was performed. Ponseti (4) technique of manipulation and casting were performed on the cases.

The Ponseti Technique

The corrective process utilizing the Ponseti technique can be divided into two phases:

- The treatment phase, during which time the deformity is corrected, and
- The maintenance phase, during which time a brace is utilized to prevent recurrence.

The treatment phase starts as soon as the skin condition of the child permits the use of plaster casts, till that time regular corrective manipulation of the foot by the mother is carried out. The treatment phase starts with the first cast aiming to align the forefoot with the mid foot and hind foot. This is achieved by;

- Stabilizing the talus by placing the thumb over the lateral part of its head.
- Elevating the first ray to achieve supination of the forefoot in respect to the mid foot and hind foot.
- Putting on a well-padded plaster cast by holding this position and molding it well.

In doing so, the cavus (Figure 1) is corrected, typically after one cast.

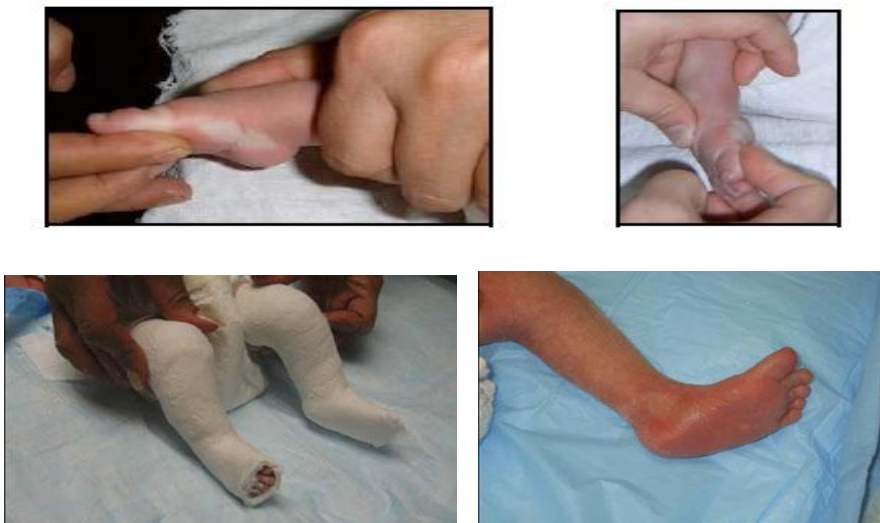

Figure 1: The First cast: Correction of cavus deformity

One week later, the first cast is removed and, if the cavus has been corrected, then after a short period of manipulation, the next toe-to-groin plaster cast is applied (Figure 2) by:

- Stabilizing the talus by placing thumb over the lateral part of its head.

- Holding the supinated foot in abduction while applying the cast.
- Applying a well-padded plaster by holding the corrected position and molding it well.

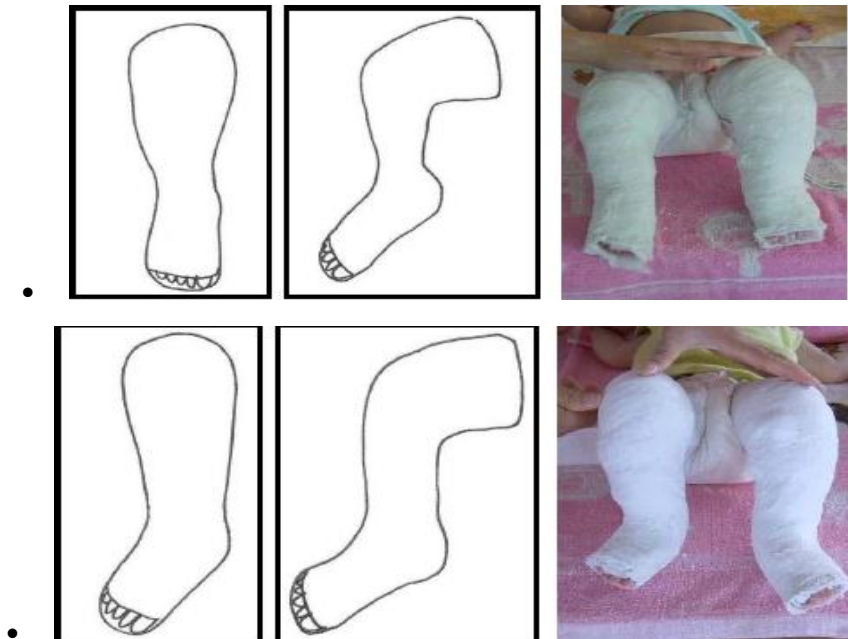


Figure 2: Further casts: After correcting the cavus, the foot is moved gradually moved outward.

A crucial point in the Ponseti technique is that the heel is never directly manipulated. The correction of heel varus and ankle equinus is takes place simultaneously because of coupling of the tarsal bones. Weekly plasters are applied till we get 70 degrees of abduction in supination.

In the majority of the children treated by Ponseti technique, there is some equinus deformity at ankle which persists. Correction of this residual deformity is accomplished with a percutaneous surgical release of the tendon, which allows the ankle to be positioned at a right angle with the leg (Figure 3).

After the tenotomy has been performed the final cast is applied with the foot in 70 degrees of abduction & 10 -15 degrees of dorsiflexion. This cast is retained for three weeks.

Upon removal of the final cast, an orthosis which typically consists of shoes mounted to a bar is used to maintain the foot in its corrected position.

In our study serial plaster casts were given for five weeks as per the schedule of Ponseti. In cases where correction was not achieved the correction casts were continued till 10th week. At each follow-up, foot was evaluated for deformity correction using the Pirani score and the goniometric assessment of the deformity which was charted on a graph paper. Achilles tendon tenotomy was performed when the hind-foot score was more than 1 and the mid-foot score was less than 1. After the final cast, all children were given orthosis as described in the Ponseti technique to maintain correction. The orthosis, was applied for 23 hours per day, for the first three months and then at night time only for two to four years. Once the child started walking, custom made clubfoot shoes were used. Patients not having satisfactory correction at the end of 10th week were subjected to operative methods of deformity correction.

At the end of the study the results were graded as good, acceptable or poor (Table 1) and

also the pre and post treatment Pirani's score and goniometry values (Table 2) were statistically

evaluated by the **Wilcoxon signed rank test.**

Table 1. Criteria for Grading the results

Result	Ankle dorsiflexion (degree)	Heel varus (degree)	Adduction of the forefoot (degree)	Tibial torsion (degree)
<i>Good</i>	10	0	0-10	Absent
<i>Acceptable</i>	0-10	0-10	10-20	Moderate
<i>Poor</i>	0	> 10	> 20	Severe

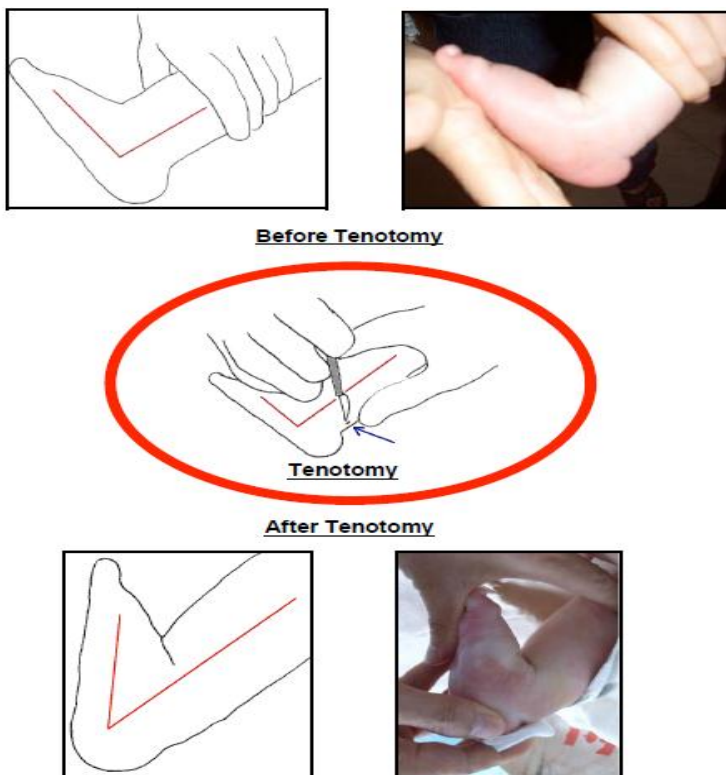


Figure 3: Role of tenotomy in correction of residual equinus

RESULTS

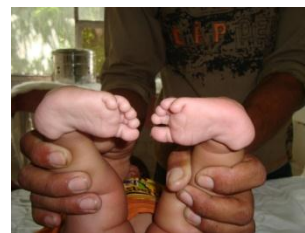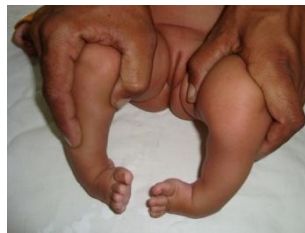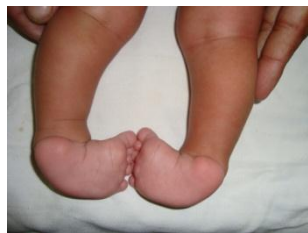A total 40 children [80.0% males and 20.0% females] with 53 idiopathic clubfoot were treated by the Ponseti method and the results were assessed in the present series, carried out from June 2006 to December 2010. Fourteen children had bilateral whereas 25 children had unilateral clubfoot. 35 feet (66.0%) were of first-born children, 18 feet were of second born. 35 cases

presented within six weeks. The total mean score at presentation was 5.6. The corresponding hind foot score and mid foot score were 2.9 and 2.8, respectively. The majority of cases (75.0%) required five casts to complete correction, with a mean of 4.9. The average duration of cast application was 4.9 weeks, a majority of clubfoot (75.5%) were treated for five weeks. Tenotomy was required in 50 feet (94.3%) and most of these had Pirani scores of more than 5. The average

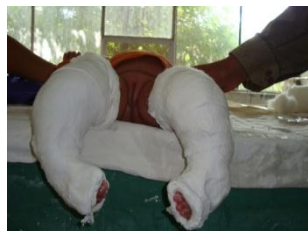duration of follow-up was 19.5 months (range 6–32 months).

All the observations regarding severity assessment were grouped into two groups one being the pretreatment group and the other being the final post treatment group. After pairing of the data (i.e. pre-treatment and post-treatment samples matching), the difference in rank was identified for each pair. If in a given pair the pretreatment observation scored 7 ranks higher than the post treatment observation, the

difference was noted as -7. If in another pair the pre-treatment observation scored 5 ranks lower than the post-treatment observation, the difference was noted as +5. Each pair was scored in this way. If the null hypothesis is true (i.e., if there is no real difference between the samples), the sum of the positive and negative scores should be close to zero. If the average difference is considerably different from 0, the null hypothesis can be rejected (5).



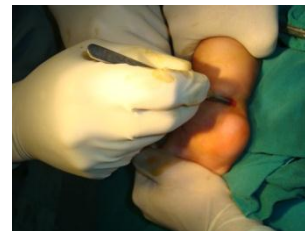Photographs at presentation



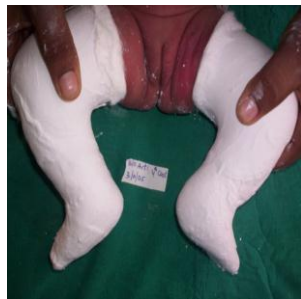After 1st cast



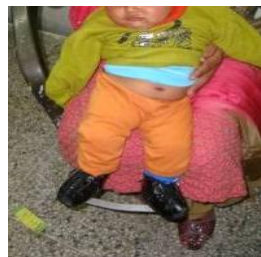After 2nd cast



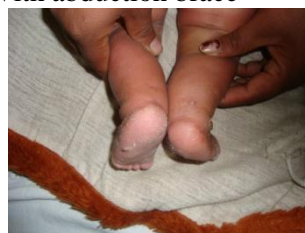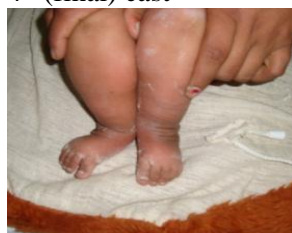Tenotomy after 3rd cast



4th (final) cast



With abduction brace



Follow up at 6 months of age

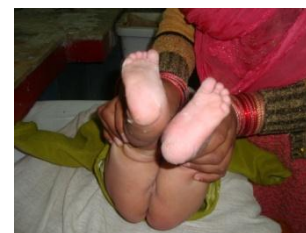

Figure 4. Serial photographs of a two Months old female child with Bilateral Clubfeet

In the study while evaluating the pre and post Pirani scores (Table 2) and the goniometric measurements by the Wilcoxon Signed Rank

Test, the Z value was away from zero therefore the test was significant i.e. there was a significant difference between the pre-treatment and post-

treatment values. Excoriation of the skin was the most common complication (7/53 feet). Recurrence was seen in only two cases. We were

able to achieve good results in 48 clubfeet (90.6%) and only two feet had poor results (Table 3).

Table 2: Pre and post treatment Pirani scores evaluated by Wilcoxon signed rank test.

	MSR2 MSR1	HSR2 HSR1	TSR2 TSR1	MSL2 MSL1	HSL2 HSL1	TSL2 TSL1
Z	-4.2	-4.1	-4.1	-4.6	-4.3	-4.6
Asymp. Sig. (2-tailed)	.0	.0	.0	.0	.0	.0

MSR- midfoot score right, HSR- hindfoot score right, TSR- total score right, MSL - midfoot score left, HSL- hindfoot score left, TSL-total score left, 1-Pre-treatment, 2- Post-treatment

Table 3: Final results of the Ponseti casting technique

Outcome	No. of Clubfeet	Percent
Good	48	90.6%
Acceptable	3	5.7%
Poor	2	3.8%
	53	100.0%

DISCUSSION

Clubfoot is a complex deformity of foot that requires meticulous and dedicated efforts on the part of the treating physician and parents for the correction of the deformity. The Ponseti method (1,2,6,7) of correction of clubfoot deformity requires serial corrective casts with long-term brace compliance for maintaining correction. The guidelines regarding patient selection and treatment protocol vary between investigators (4, 7, 8-13) but in general the treatment needs to be started as soon as possible and should be followed under close supervision.

In this series, the male to female ratio is high (male: female 4:1) in comparison to the series of Cowell and Wein (14) and Yamamoto (15) (male: female 3:1). Palmer (16) explained this by suggesting that females require a greater number of predisposing factors than males to produce a clubfoot deformity. Social bias and attention towards males in our region can account for the higher incidence in males in our study. The order of birth also seemed to have an influence on the occurrence of clubfoot, with 65.0% of cases in the first-born child, which is in accordance with various other studies (8,10,14,15,16). There was no relationship of clubfoot to the type of birth. Of the children with

clubfeet who presented to us, 87.5% were within six weeks of birth because of good referral organization. We put up clubfoot awareness posters during Pulse Polio programs and trained the supervisors at these camps to screen for the deformity in each child, report those cases and refer them to our hospital as soon as possible. We also organized special clubfoot clinics, where families of follow up patients shared their experiences with the parents of new patients and assured them about the treatment; simultaneously providing motivation and emphasizing the importance of regular follow up. Results were better if this method of treatment was started as early as possible after birth. The earliest cast applied was at an age of one week. The maximum age at which a cast was applied was at six months.

The number of casts per feet in our study was three to ten (average 4.9). In a series by Ponseti et al (4), the number of cast per feet was five to ten (average 7.6). In another study by Laaveg et al (13), the mean number of casts during their treatment was seven. Morcuende (17, 18) reported that 90.0% of the patients required five or fewer casts. Over a period of time, with more experience, people have started changing plaster casts at shorter intervals (17). Those feet which required a greater number of casts in our

study had a Pirani score of 6 at the onset of treatment. The duration of casts for more than 85.0% of feet was seven weeks or less. The duration decreased over time as we mastered the technique and started getting better correction early.

Ponseti et al (4) reported five to twelve week's duration of casts (average 9.5 weeks). In another study by Laaveg et al (13), the average duration was 8.6 weeks. Morcuende et al (17) reported an average time from the first cast to tenotomy as 16 days for one group and 24 days for another group in the same study. Their study showed that the duration of plaster casts can be decreased by using the accelerated Ponseti protocol for clubfoot treatment. In our study, tenotomy was needed in 94.3% of the cases and these patients had initial Pirani score >5. It shows that tenotomy was required in those patients who initially have severe deformity. It is advisable to do tenotomy after achieving forefoot abduction (19). Pirani carried out tenotomy in over 90.0% of his clubfoot patients. Laaveg et al (13) did tenotomy in 78.0% cases.

In a study by Thacker et al (10), 44 idiopathic clubfeet were treated with cast using the Ponseti method followed by Steenbeek foot abduction brace application. The feet of patients compliant with the brace, remained better corrected than the feet of those patients who were not compliant. We also used a Steenbeek foot abduction brace in our study. After six months of treatment (at the time when patients were on night splints) the Pirani score had become zero, indicating successful correction of the clubfoot deformity. Graphs were plotted for each patient, as recommended by Pirani.

The Ponseti method is an excellent method of treatment of clubfoot (8-10, 11-13, 15-20). The follow-up of patients treated with this deformity has been over forty years in some studies and these patients are leading a normal life now. It avoids the complications of surgery and gives a painless, mobile, normal-looking, functional foot which requires no special shoes and allows fairly good mobility. Results of the clubfoot treatment by Ponseti technique in our study have been good and rewarding and now all the clubfeet are treated in our institution by this technique. In a developing country like India and in remote areas, this technique is a very safe,

easy, result-oriented and economical method of clubfoot management. The study shows that managing a good referral by proper education and motivation along with integration into other programs improves the outcome not only in terms of age at presentation but also for deformity correction. Proper motivation and persuading the parents to accept long-term brace treatment helps maintain the correction over a longer period of time and prevents relapse.

REFERENCES

1. Ponseti IV. Treatment of congenital clubfoot. *J Bone Joint Surg Am*, 1992; 74(3):448-454.
2. Ponseti IV. The treatment of congenital clubfoot. *J Orthop Sports Phys Ther*, 1994; 20(1):1.
3. Cooper DM, Dietz FR. Treatment of idiopathic clubfoot: A thirty-year follow-up note. *J Bone Joint Surg Am*, 1995; 77:1477-89.
4. Ponseti IV, Smoley EN. Congenital clubfoot: the results of treatment. *J Bone Joint Surg Am* 1963; 45(2):2261-2275.
5. Jekel J.F., Ktaz L.D., Elmore J.G. *Epidemiology, Biostatistics and Preventive Medicine*. 2nd edition. W.B. Saunders Company, 2001; 173:177.
6. Ponseti IV. Correction of the talar neck angle in congenital clubfoot with sequential manipulation and casting. *Iowa Orthop J*, 1998; 18:74-75.
7. Ponseti IV. Clubfoot management. *J Pediatr Orthop*, 2000; 20(6):699-700.
8. Brand RA, Laaveg SJ, Crowninshield RD, Ponseti IV. The center of pressure path in treated clubfoot. *Clin Orthop Relat Res*, 1981; 160:43-47.
9. Colburn M, Williams M. Evaluation of the treatment of idiopathic clubfoot by using the Ponseti method. *J Foot Ankle Surg* 2003; 42(5):259-267.
10. Cooper DM, Dietz FR. Treatment of idiopathic clubfoot: a thirty-year follow-up note. *J Bone Joint Surg Am*, 1995; 77(10):1477-1489.
11. Herzenberg JE, Radler C, Bor N. Ponseti versus traditional methods of casting for idiopathic clubfoot. *J Pediatr Orthop*, 2002; 22(4):517-521.

12. Ippolito E, Farsetti P, Caterini R, Tudisco C. Long-term comparative results in patients with congenital clubfoot treated with two different protocols. *J Bone Joint Surg Am*, 2003;85(7):1286–1294.
13. Laaveg SJ, Ponseti IV. Long-term results of treatment of congenital clubfoot. *J Bone Joint Surg Am*, 1980; 62(1):23–31.
14. Cowell HR, Wein BK. Genetic aspect of clubfoot. *J Bone Joint Surg Am* 1980; 62(8):1381–1384.
15. Yamamoto H. A clinical, genetic and epidemiologic study of congenital clubfoot. *Jinrui Idengaku Zasshi*, 1979; 24(1):37–44.
16. Palmer RM. Genetics of talipes equinus varus. *J Bone Joint Surg Am* 1964; 46:542–556.
17. Morcuende JA, Abbasi D, Dolan LA, Ponseti IV. Results of an accelerated Ponseti protocol for clubfoot. *J Pediatr Orthop*, 2005 ;25(5):623–626.
18. Morcuende JA, Dolan LA, Dietz FR, Ponseti IV. Radical reduction in the rate of extensive corrective surgery for clubfoot using the Ponseti method. *Pediatrics*, 2004;113(2):376–380 .
19. Scher DM, Feldman DS, Van Bosse HJ, Sala DA, Lehman WB. Predicting the need for tenotomy in the Ponseti method for correction of clubfeet. *J Pediatr Orthop*, 2004; 24(4):349–352.
20. Thacker MM, Scher DM, Sala DA, Van Bosse HJ, Feldman DS, Lehman WB. Use of the foot abduction orthosis following ponseti casts: is it essential? *J Pediatr Orthop*, 2005; 25(2):225–228.