

Synchronous glioblastoma and brain metastases: illustrative case

Nastaran Shahsavari, MD,¹ Maleeha Ahmad, MD, FRCS,¹ Vashisht Sekar, MD, PhD, FRCS,¹ Antonio Meola, MD, PhD,¹ Steven L. Hancock, MD,² Steven D. Chang, MD,¹ and Veronica L. Chiang, MD³

Departments of ¹Neurosurgery and ²Radiation Oncology, Stanford University School of Medicine, Palo Alto, California; and ³Department of Neurosurgery, Yale University School of Medicine, New Haven, Connecticut

BACKGROUND Radiosurgical treatment of brain metastases is usually performed without brain tissue confirmation. While it is extremely rare for glioblastoma to develop concurrently in patients with brain metastases, they can look radiographically similar, and recognition is important because it alters management and prognosis. The synchronous presence of brain metastases and glioblastoma has not been published to date in the literature, making this a rare illustrative case.

OBSERVATIONS A 70-year-old female had lung biopsy-proven metastatic lung adenocarcinoma and multiple brain metastases. Her treatment course included initial carboplatin, pemetrexed, and bevacizumab followed by maintenance nivolumab, and she underwent stereotactic radiosurgery to the multiple brain metastases. During interval radiological surveillance, one lesion in the right temporal lobe was noted to slowly progress associated with development of significant perilesional edema causing midline shift despite repeated stereotactic radiosurgical treatments. Biopsy of this lesion revealed glioblastoma, IDH wildtype.

LESSONS Glioblastomas and brain metastases have similar radiological features, so the possibility of incorrect diagnosis needs to be considered for all lesions with interval growth poststereotactic radiosurgery. Biopsy and/or resection/laser ablation should be considered prior to reirradiation.

<https://thejns.org/doi/abs/10.3171/CASE21714>

KEYWORDS glioblastoma; brain metastases; lung adenocarcinoma; stereotactic radiosurgery; laser interstitial thermal therapy

Lung cancer is the leading cause of cancer-related mortality in the United States.¹ First-line treatment for lung cancer brain metastases remains stereotactic radiosurgery (SRS) or whole brain radiation therapy (WBRT) except in patients with central nervous system-penetrating targeted therapy options based on molecular markers.² Compared with use of WBRT, SRS use has been associated with lower rates of neurocognitive impairment in patients with multiple brain metastases.³ At recurrence of brain metastases, an increasing number of centers around the country are also using SRS rather than WBRT as second- and third-line treatments.⁴ Differentiating tumor regrowth from radiation necrosis in a previously SRS-treated lesion however remains imperfect. Laser interstitial thermal therapy (LITT) is a newer minimally invasive surgical technique that has recently been approved by the National Comprehensive Cancer Network (NCCN) for treatment of regrowing brain metastases failing SRS as well as radiation necrosis^{5,6} and it has therefore been

proposed that this option could be considered as an alternative to empirical repeat SRS.

Glioblastoma is the most common primary brain malignancy in adults.⁷ The current standard treatment of glioblastoma is maximal safe gross total resection, followed by adjuvant chemotherapy with temozolomide, and concurrent fractionated radiotherapy.^{8,9} The role of SRS in the treatment of glioblastomas remains controversial in newly diagnosed patients.^{10–13}

The concurrent presence of brain metastases and glioblastoma has not been published to date in the literature. Standardized brain tumor magnetic resonance imaging (MRI) protocols are used for detection and diagnosis of both glioblastoma and brain metastases.^{14,15} In a patient with metastatic brain disease who received SRS treatment, glioblastoma can be misdiagnosed as metastases recurrence or complication of radiation therapy such as radiation

ABBREVIATIONS ASL = arterial spin labeling; CBF = cerebral blood flow; CBV = cerebral blood volume; LITT = laser interstitial thermal therapy; MRI = magnetic resonance imaging; NCCN = National Comprehensive Cancer Network; SRS = stereotactic radiosurgery; WBRT = whole brain radiotherapy.

INCLUDE WHEN CITING Published March 21, 2022; DOI: 10.3171/CASE21714.

SUBMITTED December 21, 2021. **ACCEPTED** February 2, 2022.

© 2022 The authors, CC BY-NC-ND 4.0 (<http://creativecommons.org/licenses/by-nc-nd/4.0/>).

necrosis.¹⁶ In this study, we present a patient with multiple lung adenocarcinoma brain metastases responding to SRS and a single right temporal lesion noted to be nonresponsive to treatment. Radiological course and subsequent management are described.

Illustrative Case

A 70-year-old female with a 49 pack-year smoking history and hypertension presented with increasing confusion. Initial MRI of the brain demonstrated four enhancing lesions with moderate mass effect. One of these lesions was located in the right temporal lobe. A preliminary diagnosis of multiple metastases secondary to lung adenocarcinoma was made and primary tumor type was confirmed on lung biopsy. Treatment was commenced with carboplatin/pemetrexed, and bevacizumab and continued for three cycles. The patient also underwent SRS treatment for four brain metastases located at the right temporal, left occipital, and right and left frontal lobe. The patient's confusion resolved, and her neurological examination returned to normal.

First SRS Treatment to the Right Temporal Lesion

The right temporal lesion received 18 Gy to the 98% isodose line at the first SRS treatment (Fig. 1). Nine months later, restaging MRI of the brain demonstrated six additional new metastases. The right temporal lobe lesion was stable at this time, and it was measured at 5 × 12 × 18 mm. The patient underwent an SRS treatment session for the six new lesions and also commenced on Opdivo (Bristol Myers Squibb).

Second SRS Treatment to the Right Temporal Lesion

Seventeen months after the first SRS treatment to the right temporal lobe lesion, an interval scan showed the right temporal lesion had increased in size to 13 × 19 × 24 mm. SRS treatment was performed to treat the right temporal lesion for a second time, with 18 Gy to the 72% isodose line (Fig. 1). Additionally, at this SRS session 15 additional metastatic lesions were also radiated.

On 3-month interval scanning for the multiple metastases, right temporal lesion size remained stable but further increase in perilesional edema was noted and the etiology was thought to be radiation necrosis. Pentoxifylline (Trental, Validus Pharmaceuticals) was therefore commenced.

Third SRS Treatment to the Right Temporal Lesion

Sixteen months after the second SRS treatment, with the patient was receiving Trental, she developed increasingly severe headaches. On MRI the right temporal lobe lesion was again noted to have increased in size (18 × 14 × 16 mm). Craniotomy for resection of the right temporal lobe lesion for confirmatory tissue diagnosis was offered to and refused by the patient. Given concern for continued tumor progression, a third single fraction SRS with 20 Gy to 74% isodose line with 98% coverage was administered (Fig. 1).

Follow-up MRI up to 9 months after the third SRS, showed further increase in the size of the right temporal lobe lesion to 30 × 22 × 25 mm with further increase in edema extending into the right insula, basal ganglia, and posterior limb of the internal capsule. Right temporal craniotomy for resection was repeatedly offered to and refused by the patient because she remained relatively asymptomatic, and radiological surveillance was continued. However, nivolumab was discontinued given concern for the intracerebral edema.

Eighteen months after the third SRS treatment, continued MRI surveillance showed new extension of the region of enhancement anteriorly toward the temporal tip. Because it was unclear whether this new region was tumor or radiation necrosis, the patient agreed to undergo minimally invasive stereotactic biopsy and LITT (Fig. 2). Biopsy revealed a IDH wildtype, unmethylated MGMT, p53+ve, ATRX retained glioblastoma, with no EGFR amplification. Postoperatively the patient was treated with a modified Stupp protocol given that the lesion had previously received three SRS treatments.⁵ Unfortunately, despite excellent local control of the right temporal lesion and resolution of associated edema, the patient then developed a second focus of likely glioblastoma in the contralateral hemisphere that progressed rapidly (Fig. 3). She declined functionally, refused biopsy of the new lesion, decided not to undergo further treatment, and died 61 months after the first SRS session to the right temporal lesion, and 5 months after the confirmed diagnosis of glioblastoma.

Discussion

Observations

This is a case report of a patient with known lung cancer and multiple brain lesions, radiologically similar to and treated as metastases. Over a 5-year period, multiple brain lesions were treated with and responded well to SRS treatment in conjunction with systemic administration of Opdivo (nivolumab). In contrast, the right temporal lesion progressed despite three stereotactic radiosurgical treatments and biopsy ultimately showed that patient had developed synchronous glioblastoma.

Lessons

Depending on the tumor profile of the lung cancer, anywhere from 20% to 50% of patients with metastatic disease will develop brain metastases.¹⁷ Median survival for lung cancer brain metastases patients can vary significantly ranging from 6 to 8 months to 24 months depending on the mutational profile of the tumor type.^{2,18} One of the biggest challenges in patients with metastatic cancer is the ability to differentiate pathologies in the brain based on radiological imaging alone. Early-stage glioblastomas are detected as small ill-defined T2-weighted hyperintense lesion with poor contrast uptake, and it may take weeks to months to demonstrate the characteristic features of glioblastoma as a ring-like or heterogeneously enhanced lesion, with significant edema and central necrosis.¹⁹ While the most likely diagnosis for new enhancing lesions in these patients is brain metastases, new development of glioblastoma can appear very similar radiographically although their synchronous presence is extremely rare and there are no published case series on this. More likely, in a patient with previously SRS-treated brain metastases, the differential diagnosis in a lesion failing first SRS treatment includes radiation necrosis.¹⁶ It is therefore important to note that if any single lesion is not responding to SRS as expected then diagnoses other than recurrent brain metastasis growth need to be considered.

In a systematic review by Lundy et al.,²⁰ use of magnetic resonance diffusion and perfusion-weighted imaging can provide more assistance in the discrimination of glioblastoma with the other pathologies. In addition, the utilize of magnetic resonance spectroscopy and nuclear medicine imaging (fluorodeoxyglucose-18 positron emission tomography and carbon-11 methionine positron emission tomography) may also assist in the diagnosis. Arterial spin labeling

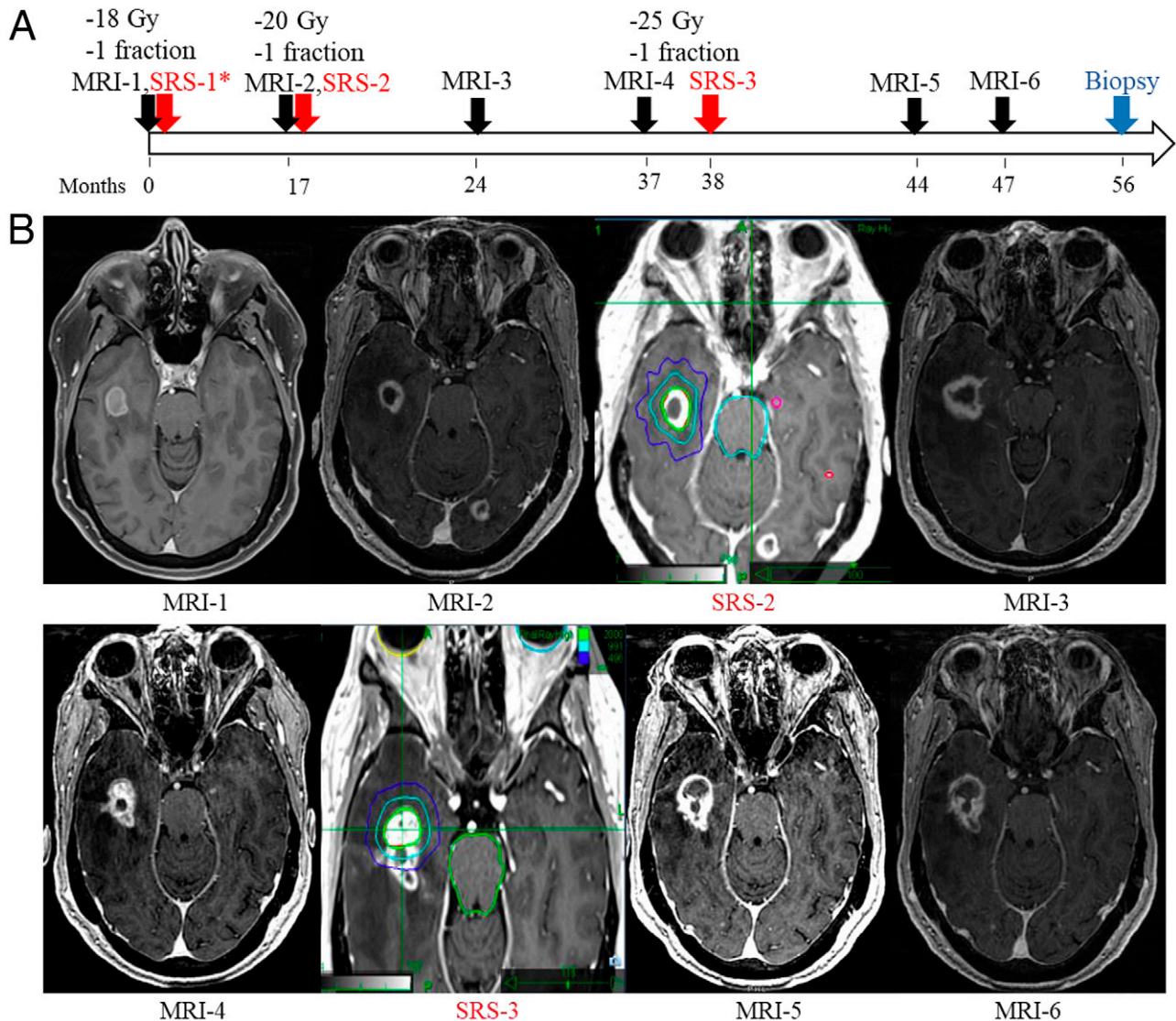


FIG. 1. Patient history timeline, with corresponding postcontrast T1-weighted axial magnetic resonance images and SRS treatment plans (*left to right*). **A:** A 70-year-old patient presented with multiple brain lesions and received a total of six SRS treatments to these lesions. Of specific note, a right temporal lobe lesion received three SRS treatments as the patient refused any form of invasive treatment. **B:** Chronological illustrative diagram of the MRI schedule over 47 months is depicted here, with the corresponding SRS treatment plans. This timeline is an overview of the ongoing radiological surveillance for the right temporal lesion that was biopsied and found to be a glioblastoma IDH wildtype 56 months after the first SRS treatment. * SRS-1 was performed abroad, and the treatment plan was not available.

(ASL) MRI was used in a study to differentiate glioblastomas from brain metastases. Intratumoral and peritumoral cerebral blood flow (CBF) were higher in glioblastoma. Receiver operating characteristic analysis for normalized CBF intratumor >1.04 cutoff had 64% sensitivity and 89.7% specificity. This study shows ASL perfusion MRI can sometimes be helpful in differentiation between glioblastoma and brain metastases²¹ if the specific question is raised.

Artzi et al.²² used radiomic analysis for the purpose of differentiation between glioblastoma and solitary brain metastasis in post-contrast T1-weighted MRI. The sensitivity, specificity, accuracy, and the area under the curve were reported as 86%, 85%, 85%, and 96%, respectively. In another study five classifiers were used to differentiate between solitary brain metastasis and glioblastoma by

using radiomic features of peri-enhancing edema region of MRI. The results of the validation data set showed an accuracy of 56%–64%, sensitivity of 39%–78%, and specificity of 50%–89%.²³ Inflow-based vascular-space-occupancy arteriolar cerebral blood volume (CBV) and dynamic susceptibility contrast MRI performed in a study to differentiate glioblastoma from solitary brain metastasis, and the results showed inflow-based vascular-space-occupancy arteriolar CBV and relative arteriolar CBV were significantly higher in glioblastoma in the intratumoral area, which are additional radiological assessment tools to distinguish between glioblastoma and brain metastases.²⁴ While some of these tests show a high probability of differentiating diagnoses, tissue diagnosis remains the gold standard method.

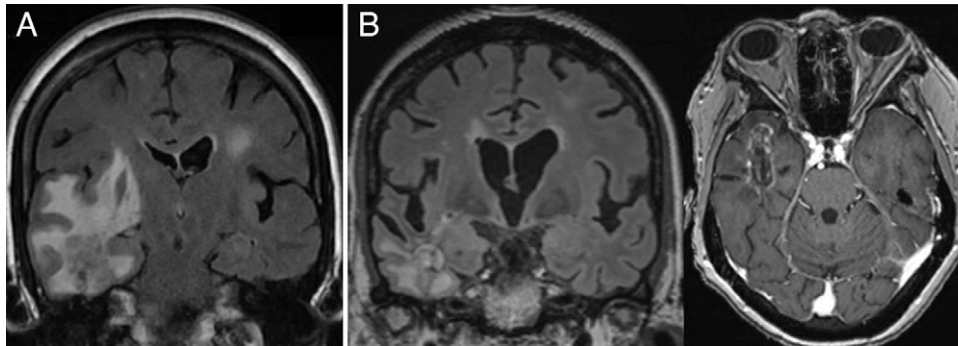


FIG. 2. A: Coronal fluid-attenuated inversion recovery (FLAIR) MRI showing the right temporal glioblastoma before LITT. **B:** Coronal FLAIR (*left*) and axial postcontrast T1-weighted (*right*) magnetic resonance images showing the right temporal glioblastoma 6 months after LITT and Stupp protocol.

While it is understandable that patients with metastatic cancer might not wish to undergo standard craniotomy, alternatives including biopsy only or biopsy with LITT are available today to assist with management. Surgical risks associated with biopsy alone are low and can be highly beneficial for diagnosis in cases such as this one.²⁵ LITT is a newer minimally invasive surgical technique that has recently been approved by the NCCN for treatment of regrowing brain metastases failing SRS as well as radiation necrosis and it has been shown to have a good safety profile.^{5,6} More recently the American Association for Neurological Surgeons and the Congress of Neurological Surgeons released a joint position statement supporting the use of LITT for brain tumors including both brain metastases and gliomas. In this case if the option of biopsy and LITT could have been offered earlier in the patient's course, her radiation treatment and clinical course might have been significantly different. This case highlights the need for obtaining tissue to confirm diagnosis in lesions failing SRS. Stereotactic biopsy and LITT can be offered as a minimally invasive alternative to craniotomy in these patients.

Radiation-induced glioma was also considered in this case. The Cahan et al.²⁶ criteria for how to diagnose a radiation-induced

glioma highlights the importance of different phenotypes between primary and secondary tumors, that the site of the secondary tumor should be in the field of original irradiation, and a prolonged time latency (usually more than 5 years) between treatment of the primary tumor and the appearance of the secondary tumor. In the presented case there was no latency period between the brain metastases and the glioblastoma occurrence, and the two pathologies occurred synchronously. In a systematic review, Yamanaka et al.²⁷ reported that the mean latency period between SRS treatment and the onset of secondary glioma was approximately 7 years and the overall survival was 8 months in patients with radiation-induced gliomas. Molecular markers in four patients with radiation-induced gliomas were reported in a study as P53-, ATRX+, and without IDH mutation.²⁸ In a previous study by Deng et al.,²⁹ radiation-induced gliomas in 32 pediatric patients who received radiation for medulloblastoma or acute lymphoblastic leukemia, the presence of IDH wildtype glioblastoma was common among the patients. Although our patient's tumor profile reported P53 mutation and IDH wildtype glioblastoma, the absence of latency period between brain radiation to brain metastases and glioblastoma makes the diagnosis of de novo glioblastoma more likely.

The incidence of glioblastoma is 3.21 per 100,000 population annually, median observed survival for glioblastoma is 8 months, and 5-year relative survival rate is 5%–13%.^{7,30} The single feature in this case that was highly unusual was the long durations of tumor control between SRS treatments. This patient's neurological stability and survival after each round of SRS to the glioblastoma lesion was at odds with this patient's tumor's molecular profile, unmethylated MGMT status, IDH1-, p53+, and ATRX+ mutations, which according to the literature has a poor prognosis. Interestingly, she did receive ongoing treatment with nivolumab, an agent that has also not been shown to have benefit in the treatment of recurrent glioblastoma but has increased overall survival in patients with non-small cell lung carcinoma.^{31,32} Studies show that the MGMT unmethylated status in patients, like ours, who underwent SRS for their glioblastomas had worse prognosis in comparison to the methylated or hypermethylated MGMT status.^{13,33}

A previous study reported that IDH1+, or ATRX-, or p53- glioblastomas showed better survival, and in the case of double protein pairs, the patients with ATRX-/p53-, ATRX-/IDH1+, and IDH1+/p53- glioblastomas had better survivals than the patients with other pairs.³⁴ Our patient's molecular profile was IDH wildtype, ATRX+, and P53+, and

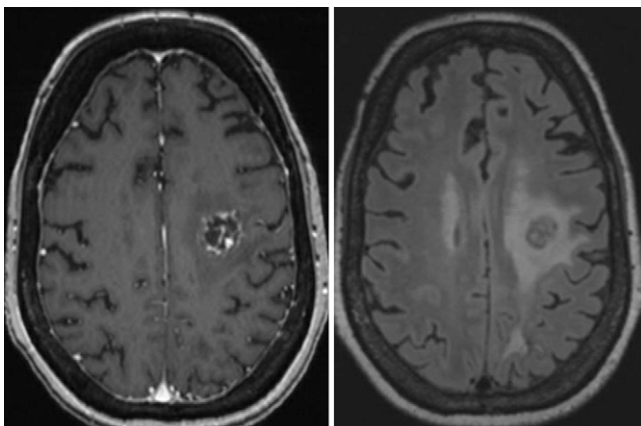


FIG. 3. Axial postcontrast T1-weighted (*left*) and fluid-attenuated inversion recovery (FLAIR) (*right*) magnetic resonance images showing the left contralateral glioblastoma that resulted in the patient's eventual demise.

her overall survival was more than 5 years, which is in contrast with this study. On the other hand, another study showed that IDH1 and ATRX mutations, p53 overexpression, and WT-1 expression were not associated with patients overall or progression-free survival although these factors affected chemotherapy and radiotherapy response and therefore could improve patient's prognosis.³⁵ Our patient had P53 and ATRX mutations and responded to SRS in a time span of 16 months despite being historically having poor prognostic markers.

In conclusion, with the increasing ease with which SRS can be delivered for the treatment of multiple brain metastases, it is critical for the treating physician to reassess the clinical situation at each encounter. The pathology underlying radiographic lesional regrowth after SRS has clearly been shown to include both tumor recurrence and radiation necrosis. This case adds to this differential diagnosis by showing that synchronous glioblastomas can also occur in these patients. In patients reluctant to undergo craniotomy or whose medical condition makes them poor candidates, biopsy and LITT is a minimally invasive option that is now available as a standard alternative. Biopsy should be considered and offered where diagnosis is unclear to avoid mismanagement. As seen in this case, LITT can be very effective management for lesions failing radiosurgery regardless of etiology.

References

- Siegel RLMK, Miller KD, Jemal A. Cancer statistics, 2020. *CA Cancer J Clin.* 2020;70(1):7–30.
- Ernani V, Stinchcombe TE. Management of brain metastases in non-small-cell lung cancer. *J Oncol Pract.* 2019;15(11):563–570.
- Brown PD, Jaeckle K, Ballman KV, et al. Effect of radiosurgery alone vs radiosurgery with whole brain radiation therapy on cognitive function in patients with 1 to 3 brain metastases: a randomized clinical trial. *JAMA.* 2016;316(4):401–409.
- Kowalchuk RO, Niranjana A, Lee C-c, et al. Reirradiation with stereotactic radiosurgery after local or marginal recurrence of brain metastases from previous radiosurgery. *Int J Radiat Oncol Biol Phys.* 2022;111(3):726–734.
- Ahluwalia M, Barnett GH, Deng D, et al. Laser ablation after stereotactic radiosurgery: a multicenter prospective study in patients with metastatic brain tumors and radiation necrosis. *J Neurosurg.* 2018;130(3):804–811.
- Rennert RC, Khan U, Bartek J, et al. Laser Ablation of Abnormal Neurological Tissue Using Robotic Neuroblate System (LAAN-TERN): procedural safety and hospitalization. *Neurosurgery.* 2020;86(4):538–547.
- Ostrom QT, Patil N, Cioffi G, Waite K, Kruchko C, Barnholtz-Sloan JS. CBTRUS Statistical Report: primary brain and other central nervous system tumors diagnosed in the United States in 2013–2017. *Neuro Oncol.* 2020;22(12 Suppl 2):iv1–iv96.
- Stupp R, Mason WP, van den Bent MJ, et al. Radiotherapy plus concomitant and adjuvant temozolomide for glioblastoma. *N Engl J Med.* 2005;352(10):987–996.
- Sulman EP, Ismaila N, Armstrong TS, et al. Radiation Therapy for Glioblastoma: American Society of Clinical Oncology Clinical Practice Guideline Endorsement of the American Society for Radiation Oncology Guideline. *J Clin Oncol.* 2017;35(3):361–369.
- Redmond KJ, Mehta M. Stereotactic radiosurgery for glioblastoma. *Cureus.* 2015;7(12):e413.
- Biswas T, Okunieff P, Schell MC, et al. Stereotactic radiosurgery for glioblastoma: retrospective analysis. *Radiat Oncol.* 2009;4:11.
- Niranjana A, Monaco EA III, Kano H, Flickinger JC, Lunsford LD. Stereotactic radiosurgery in the multimodality management of residual or recurrent glioblastoma multiforme. *Prog Neurol Surg.* 2018;31:48–61.
- Azoulay M, Chang SD, Gibbs IC, et al. A phase I/II trial of 5-fraction stereotactic radiosurgery with 5-mm margins with concurrent temozolomide in newly diagnosed glioblastoma: primary outcomes. *Neuro Oncol.* 2020;22(8):1182–1189.
- Ellingson BM, Bendszus M, Boxerman J, et al. Consensus recommendations for a standardized brain tumor imaging protocol in clinical trials. *Neuro Oncol.* 2015;17(9):1188–1198.
- Hishii M, Matsumoto T, Arai H. Diagnosis and treatment of early-stage glioblastoma. *Asian J Neurosurg.* 2019;14(2):589–592.
- Lee D, Riestenberg RA, Haskell-Mendoza A, Bloch O. Brain metastasis recurrence versus radiation necrosis: evaluation and treatment. *Neurosurg Clin N Am.* 2020;31(4):575–587.
- Gaspar LE. Brain metastases in lung cancer. *Expert Rev Anticancer Ther.* 2004;4(2):259–270.
- Waqar SN, Samson PP, Robinson CG, et al. Non-small-cell lung cancer with brain metastasis at presentation. *Clin Lung Cancer.* 2018;19(4):e373–e379.
- Ideguchi M, Kajiwara K, Goto H, et al. MRI findings and pathological features in early-stage glioblastoma. *J Neurooncol.* 2015;123(2):289–297.
- Lundy P, Domino J, Ryken T, et al. The role of imaging for the management of newly diagnosed glioblastoma in adults: a systematic review and evidence-based clinical practice guideline update. *J Neurooncol.* 2020;150(2):95–120.
- Sunwoo L, Yun TJ, You SH, et al. Differentiation of glioblastoma from brain metastasis: qualitative and quantitative analysis using arterial spin labeling MR imaging. *PLoS One.* 2016;11(11):e0166662.
- Artzi M, Bressler I, Ben Bashat D. Differentiation between glioblastoma, brain metastasis and subtypes using radiomics analysis. *J Magn Reson Imaging.* 2019;50(2):519–528.
- Dong F, Li Q, Jiang B, et al. Differentiation of supratentorial single brain metastasis and glioblastoma by using peri-enhancing oedema region-derived radiomic features and multiple classifiers. *Eur Radiol.* 2020;30(5):3015–3022.
- Li X, Wang D, Liao S, et al. Discrimination between glioblastoma and solitary brain metastasis: comparison of inflow-based vascular-space-occupancy and dynamic susceptibility contrast MR imaging. *AJNR Am J Neuroradiol.* 2020;41(4):583–590.
- Field M, Witham TF, Flickinger JC, Kondziolka D, Lunsford LD. Comprehensive assessment of hemorrhage risks and outcomes after stereotactic brain biopsy. *J Neurosurg.* 2001;94(4):545–551.
- Cahan WGWH, Woodard HQ, Higinbotham NL, Stewart FW, Coley BL. Sarcoma arising in irradiated bone: report of eleven cases. *Cancer.* 1998;82(1):8–34.
- Yamanaka R, Hayano A, Kanayama T. Radiation-induced gliomas: a comprehensive review and meta-analysis. *Neurosurg Rev.* 2018;41(3):719–731.
- Nakao T, Sasagawa Y, Nobusawa S, et al. Radiation-induced gliomas: a report of four cases and analysis of molecular biomarkers. *Brain Tumor Pathol.* 2017;34(4):149–154.
- Deng MY, Sturm D, Pfaff E, et al. Radiation-induced gliomas represent H3-IDH-wild type pediatric gliomas with recurrent PDGFRA amplification and loss of CDKN2A/B. *Nat Commun.* 2021;12(1):5530.
- Burgenske DM, Yang J, Decker PA, et al. Molecular profiling of long-term IDH-wildtype glioblastoma survivors. *Neuro Oncol.* 2019;21(11):1458–1469.
- Filley AC, Henriquez M, Dey M. Recurrent glioma clinical trial CheckMate-143 the game is not over yet. *Oncotarget.* 2013;8(53):91779–91794.
- Borghaei H, Paz-Ares L, Horn L, et al. Nivolumab versus docetaxel in advanced nonsquamous non-small-cell lung cancer. *N Engl J Med.* 2015;373(17):1627–1639.

33. Morris SL, Zhu P, Rao M, et al. Gamma knife stereotactic radiosurgery in combination with bevacizumab for recurrent glioblastoma. *World Neurosurg.* 2019;127:e523–e533.
34. Chaurasia A, Park SH, Seo JW, Park CK. Immunohistochemical analysis of ATRX, IDH1 and p53 in glioblastoma and their correlations with patient survival. *J Korean Med Sci.* 2016;31(8): 1208–1214.
35. Gülten G, Yalçın N, Baltalarlı B, Doğu G, Acar F, Doğruel Y. The importance of IDH1, ATRX and WT-1 mutations in glioblastoma. *Pol J Pathol.* 2020;71(2):127–137.

Disclosures

Dr. Chiang reported personal fees from Monteris Medical Inc outside the submitted work. No other disclosures were reported.

Author Contributions

Conception and design: Chiang, Shahsavari, Ahmad, Hancock. Acquisition of data: Chiang, Shahsavari, Ahmad, Hancock, Chang. Analysis and interpretation of data: all authors. Drafting the article: Chiang, Shahsavari, Ahmad, Sekar. Critically revising the article: all authors. Reviewed submitted version of manuscript: all authors. Approved the final version of the manuscript on behalf of all authors: Chiang. Statistical analysis: Ahmad. Administrative/technical/material support: Shahsavari, Ahmad, Meola. Study supervision: Ahmad, Hancock, Chang.

Correspondence

Veronica L. Chiang: Yale University School of Medicine, New Haven, CT. veronica.chiang@yale.edu.