



Since January 2020 Elsevier has created a COVID-19 resource centre with free information in English and Mandarin on the novel coronavirus COVID-19. The COVID-19 resource centre is hosted on Elsevier Connect, the company's public news and information website.

Elsevier hereby grants permission to make all its COVID-19-related research that is available on the COVID-19 resource centre - including this research content - immediately available in PubMed Central and other publicly funded repositories, such as the WHO COVID database with rights for unrestricted research re-use and analyses in any form or by any means with acknowledgement of the original source. These permissions are granted for free by Elsevier for as long as the COVID-19 resource centre remains active.



INFECTIOUS DISEASE

Non-tuberculous Mycobacteria can Cause Disseminated Mycobacteriosis in Cats

H. Pekkarinen^{*}, N. Airas^{*}, L. E. Savolainen[†], M. Rantala[‡], S. Kilpinen[‡],
O. Miuku[‡], M. Speeti[§], V. Karkamo[¶], S. Malkamäki^{*}, M. Vaara[†],
A. Sukura^{*} and P. Syrjä^{*}

^{*} Department of Veterinary Biosciences, Faculty of Veterinary Medicine, PO Box 66, University of Helsinki, [†] Department of Clinical Microbiology, University of Helsinki and Helsinki University Hospital, HUSLAB, [‡] Department of Equine and Small Animal Medicine, Faculty of Veterinary Medicine, PO Box 57, University of Helsinki, [§] Herttoniemi Veterinary Clinic, Hiihtomäentie 35 and [¶] Pathology Research Unit, Finnish Food Safety Authority Evira, Mustialankatu 3, Helsinki, Finland

Summary

Mycobacteriosis caused by non-tuberculous mycobacteria (NTM) is a rising concern in human medicine both in immunocompromised and immunocompetent patients. In cats, mycobacteriosis caused by NTM is considered mostly to be a focal or dermal infection, with disseminated disease mostly caused by *Mycobacterium avium*. We describe three cases of disseminated mycobacteriosis in cats, caused by *Mycobacterium malmoeense*, *Mycobacterium branderi/shimoidei* and *M. avium*, with no identified underlying immunosuppression. In all cases, extracellular mycobacteria were seen in the pulmonary epithelium, intestinal lumen and glomerular tufts, which could affect the shedding of the organism. The present study highlights the importance of mycobacteriosis as a differential even in immunocompetent animals. Considering the close relationship of owners and pets and the potential presence of free mycobacteria in secretions, cats should be considered as a possible environmental reservoir for mycobacteria.

© 2018 Elsevier Ltd. All rights reserved.

Keywords: cat; mycobacteriosis; non-tuberculous mycobacteria

Introduction

Mycobacteria are acid-fast, aerobic, non-spore forming rod shaped bacteria that range from obligate pathogens to environmental saprophytes. Mycobacteria can be divided into three groups based on the disease they cause: *Mycobacterium leprae* and *Mycobacterium lepromatosis* cause leprosy in man. The *Mycobacterium tuberculosis* complex (MTC) is formed from species that cause tuberculosis in man and animals, such as *M. tuberculosis*, *Mycobacterium bovis* and *Mycobacterium microti*. In human medicine the word ‘tuberculosis’ is reserved for infections caused by the MTC species (Esteban and Muñoz-Egea, 2016).

The rest of the mycobacterial species are grouped as non-tuberculous mycobacteria (NTM), which are mostly opportunistic environmental pathogens (Koh, 2017). Most mycobacteria have a particular host preference, but some can cause infections in other species, including man (Quinn *et al.*, 2011).

Human leprosy is caused by either *M. leprae* or the more recently discovered *M. lepromatosis*, with varying skin lesions and peripheral nerve thickening and occasionally with systemic or mucosal involvement (Renault and Ernst, 2010). It was at first presumed that these species infected only man, but both species have also been found in Eurasian red squirrels (*Sciurus vulgaris*) (Avanzi *et al.*, 2016) and *M. leprae* is known to infect nine-banded armadillos (*Dasybus novemcinctus*) (Balamayooran *et al.*, 2015).

Correspondence to: H. Pekkarinen (e-mail: henna.pekkarinen@helsinki.fi).

Tuberculosis can cause organ-specific infections, systemic infections or classical granulomatous pulmonary infections (Fitzgerald *et al.*, 2010; Pesciaroli *et al.*, 2014). MTC species are closely related to each other with a high sequence similarity (Esteban and Muños-Egea, 2016) and all of them have an established zoonotic potential (Thirunavukkarasu *et al.*, 2017). *M. tuberculosis* is the most common cause of tuberculosis in man, but *M. bovis* has been found in 5–10% of cases (Esteban and Muños-Egea, 2016) and *M. microti* has been described in over 20 human cases (Esteban and Muños-Egea, 2016). In man, most MTC species cause a disease similar to classical tuberculosis (Esteban and Muños-Egea, 2016). In animals, the most common cause of tuberculosis is *M. bovis*, which has been described to affect, with varying degree, all common domestic mammals (Pesciaroli *et al.*, 2014).

The *Mycobacterium avium* complex (MAC) is the most common NTM in man (Daley, 2017; Koh, 2017), but a multitude of NTM species are known to cause disease (Koh, 2017; Thirunavukkarasu *et al.*, 2017). NTM infections affect both immunocompromised and immunocompetent patients (Koh, 2017) and the incidence of NTM isolates in human samples has been rising (Shah *et al.*, 2016). Infections in people are classified into four distinct clinical syndromes: chronic pulmonary disease, lymphadenitis, cutaneous disease and disseminated disease (Koh, 2017). In animals MAC species are generally considered to be the most important NTM (Quinn *et al.*, 2011) and these include *M. avium*, causing avian tuberculosis, and *M. avium* subspecies *paratuberculosis*, causing paratuberculosis or Johne's disease. Other NTM species are described to cause mostly sporadic, non-specific infections in several species (Thirunavukkarasu *et al.*, 2017).

There are few data on the prevalence of mycobacterial infections in domestic cats. In the UK, a recent publication studying histopathological samples reported typical lesions with acid-fast bacteria in approximately 0.3% of all cases examined, with the most common mycobacteria isolated being *M. bovis* and *M. microti* (Gunn-Moore *et al.*, 2013). Broughan *et al.* (2013) reported *M. bovis*-positive cultures in 16% of feline samples over a period of 7 years when examining microbiological samples submitted to the Animal Health and Veterinary Laboratories Agency, UK, for confirmation of suspected mycobacteriosis. Cats with access to wildlife reservoirs or bovine milk infected with mycobacteria are predisposed to mycobacterial infections (Gunn-Moore, 2014; Pesciaroli *et al.*, 2014) and there might be an increased risk associated with immunosuppressive diseases, especially with NTM infections (Gunn-Moore, 2014).

Tuberculosis in cats usually presents as a localized cutaneous disease or, less commonly, as a disseminated or systemic respiratory or alimentary disease (Gunn-Moore *et al.*, 2011a; Gunn-Moore, 2014; Pesciaroli *et al.*, 2014). NTM infections cause mostly cutaneous or subcutaneous nodules or granulomatous panniculitis with variable lymph node involvement (Gunn-Moore *et al.*, 2011a; Gunn-Moore, 2014). The 'feline leprosy syndrome', a leprosy-like ulcerative and nodular skin disease especially affecting the head and limbs (Gunn-Moore, 2014), is also part of the NTM group of infections. Of the NTM species, a few cases of disseminated or systemic disease have been reported with *M. avium* (Morfitt *et al.*, 1989; Barry *et al.*, 2002; Griffin *et al.*, 2003; Knippel *et al.*, 2004; Baral *et al.*, 2006; De Groot *et al.*, 2010; Rivière *et al.*, 2011), two cases with *Mycobacterium xenopi* (MacWilliams *et al.*, 1998; Meeks *et al.*, 2008) and single cases with *Mycobacterium heckeshornense* (Elze *et al.*, 2013), *Mycobacterium simiae* (Dietrich *et al.*, 2003) and *Mycobacterium kansasii* (Lee *et al.*, 2017). Despite the reported cases, systemic mycobacteriosis caused by NTM species is still considered relatively rare, especially outside the MAC species (Lloret *et al.*, 2013; Gunn-Moore, 2014; Mauldin and Peters-Kennedy, 2016).

There is close contact between domestic cats and their owners. Given that the incidence of NTM isolates from human patients is rising and that there are still lingering views that systemic NTM mycobacteriosis rarely affects cats, the aim of this study was to describe the pathological and bacteriological findings in three cases of disseminated mycobacteriosis in cats caused by different NTM species.

Materials and Methods

Animals

Three privately owned cats from urban areas of Southern Finland were subjected to necropsy examination at the Department of Veterinary Biosciences, Faculty of Veterinary Medicine, University of Helsinki, Finland, between December 2014 and November 2016. The cats all had a cytological diagnosis of mycobacterial infection. The cats had tested negative for feline immunodeficiency virus (FIV) and feline leukaemia virus (FeLV) within the 8 months preceding their death by humane destruction. Cats A and B had current vaccinations against feline panleucopenia virus, felid herpesvirus and feline calicivirus at the time of death, while cat C had not been vaccinated for several years.

Cytology

Cytological samples, air-dried and stained with May–Grünwald–Giemsa (MGG), were provided from all cases during clinical workup. Samples were provided from initial lesion sites: the liver for cat A, an abdominal mass for cat B and an abdominal mass and a submandibular lymph node for cat C.

Necropsy Examination, Histopathology and Immunohistochemistry

A full necropsy examination was performed within 24 h after death, with tissue samples taken from internal organs, intestinal lymph nodes, the central nervous system (CNS) and bone marrow and from the eye in cats A and B. Tissue samples were fixed in 10% neutral buffered formalin, processed routinely and embedded in paraffin wax. Sections (4 µm) were stained by haematoxylin and eosin (HE) and Ziehl–Neelsen (ZN) stains.

Immunohistochemistry (IHC) was used to detect feline coronavirus antigen. Antigen retrieval was in 0.01 M citrate buffer (pH 6.0) and the primary reagent was mouse anti-feline coronavirus (FIPV3-70, MCA2194, Bio-Rad AbD Serotec Ltd, Oxford, UK) diluted at 1 in 600. The secondary reagent was anti-mouse antibody polymer linked to horseradish peroxidase (BrightVision + Poly-HRP-anti Ms/Rb; Immunologic, Duiven, the Netherlands) with 3,3'-diaminobenzidine tetrahydrochloride as chromogen. The FIPV3-70 anti-coronavirus antibody is routinely used for diagnosis of feline infectious peritonitis (Kipar *et al.*, 1998; Poncelet *et al.*, 2008).

Microbiology

Fresh tissue samples from the liver of cat A, the mass from cat B and the lymph node from cat C were submitted to the Helsinki University Hospital, Division of Clinical Microbiology, Helsinki, Finland, for mycobacterial culture. Firstly, the presence of the *M. tuberculosis* complex was excluded by use of a specific, direct nucleic acid amplification method (GeneXpert Mycobacterium tuberculosis/rifampicin (MTB/RIF), Cepheid, Sunnyvale, California, USA) (Ioannidis *et al.*, 2011) from the tissue sample. The tissue was cultured on solid and in liquid mycobacterial culture media. One month later, the bacterial deoxyribonucleic acid (DNA) was extracted from positive mycobacterial culture for a mycobacterial DNA line probe assay (GenoType Mycobacterium common mycobacteria (CM), Hain Lifescience, Nehren, Germany) (Russo *et al.*, 2006) and sequencing of a 525 base pair (bp) region of the 16S ribosomal ribonucleic acid (*rRNA*) gene (Tuuminen *et al.*, 2006) in order to

identify the mycobacteria to species level. The sequence obtained was compared with those in the database of the National Center for Biotechnology Information (NCBI, Rockville Pike, Bethesda Maryland, USA) by use of the BLAST (basic logical alignment search tool) database (Cummings *et al.*, 2002).

Results

Animals

The signalment, main clinical complaint and affected organs for each case are presented in Table 1. All were middle-aged domestic shorthair cats, with at least a partial history of outdoor life. Cat A was a shelter cat, which had been adopted approximately 2 years before diagnosis. Cat B had been a barn cat for most of its life. Cat C lived partly outdoors during the summer, but was kept indoors during other seasons.

Cytology

In all cases, fine needle aspiration yielded a highly cellular sample with macrophages as the main cellular population. The macrophages were enlarged and distended, with the nucleus often at the periphery of the cytoplasm. Numerous MGG-negative, slender, rod-shaped bacteria were readily seen within macrophages and freely in the background. Cat A had numerous uni- or multinucleated macrophages within the liver sample and mild hepatic lipidosis. In cat B, the abdominal mass was comprised of severe granulomatous inflammation with scant neutrophils and lymphocytes. In cat C, the cytology of both the abdominal mass and the lymph node were consistent with granulomatous inflammation.

Macroscopical Findings

In all cases, innumerable miliary to partly coalescing, 1–5 mm, slightly raised, white or pale grey, oval to round nodules were seen in multiple organs, both on the serosal surfaces and on the cut surfaces. Cat A had severe hepato- and splenomegaly (Fig. 1A) and a moderate generalized lymphadenomegaly of the peripheral, thoracic and abdominal lymph nodes, with 1–5 mm pale grey nodules on the cut surfaces. Cat B had a large mass replacing the mesenteric lymphoid tissue (Fig. 1B) and moderate lymphadenomegaly of the retropharyngeal and prescapular lymph nodes and severe lymphadenomegaly of the sternal lymph nodes. Cat C had a 7 × 8 × 7 cm, partly necrotic and cystic mass replacing the mesenteric and ileocaecal lymphoid tissue, two approximately 1 cm diameter pale mural nodules in the wall of the

Table 1
Clinical information and affected organs

	Cat A	Cat B	Cat C
Age (years)	8	10	12
Sex	FN	MN	FN
Significant clinical finding	Hepatomegaly	Abdominal mass	Generalized lymphadenomegaly
Lymph nodes			
Macroscopical	+	+	+
Microscopical	+	+	+
Liver			
Macroscopical	+	–	+
Microscopical	+	+	+
Spleen			
Macroscopical	+	+	+
Microscopical	+	+	+
Lung			
Macroscopical	+	–	+
Microscopical	+	+	+
Adrenal gland			
Macroscopical	+	–	–
Microscopical	+	+	–
Peritoneum			
Macroscopical	–	+	+
Microscopical	–	+	+
Bone marrow			
Macroscopical	–	–	–
Microscopical	+	+	+
Kidney			
Macroscopical	–	–	–
Microscopical	+	+	+

FN, neutered female; MN, neutered male.

small intestine and a severe generalized lymphadenomegaly (Fig. 1C). In all cats, enlarged lymph nodes were firm and pale. In addition, cat B had chronic infarction of the left kidney and cat C had bilaterally small, pale kidneys.

Histology and Immunohistochemistry

Cat A had a uniform sheet-like infiltration of large polygonal macrophages in almost all affected organs, with these having abundant, pale eosinophilic, slightly granular cytoplasm containing numerous acid-fast bacteria. Admixed with the macrophages were moderate numbers of giant cells and small numbers of neutrophils, lymphocytes and plasma cells. Depending on the affected organ, histiocytic infiltrates were either arranged as multifocal to coalescing nodules or as a diffuse infiltration encompassing large areas of the affected tissue. The nodular infiltrations were mostly associated with vascular or lymphatic structures and no clear granuloma formation was seen in the affected organs. In addition, varying sized areas of coagulative necrosis were present multifocally (Fig. 2A) and there was a mild histiocytic infiltration bilaterally in the collector vessels of the limbus of the eye and in the choroid plexus.

Cat B had a similar sheet-like infiltration of macrophages in all affected organs. The abdominal mass was almost completely comprised of markedly enlarged macrophages and giant cells (Fig. 2B), with small lymphocytic foci admixed with the inflammatory cells, interpreted as possible replacement of normal lymph node tissue by the histiocytic infiltrate. In addition, cat B had a moderate, multifocal, histiocytic infiltration within the small intestine and in the connective tissue of the renal papilla, retro-orbital fat, gastric submucosa and surrounding the thyroid glands. Free mycobacteria were also seen within the lamina propria of the small intestinal villi.

In the affected organs of cat C, the macrophages were smaller and spindle shaped, with a moderate amount of eosinophilic cytoplasm and numerous intracytoplasmic mycobacteria; only a few multinucleated giant cells were seen. The macrophages were arranged in concentric circles, reminiscent of classical granulomas (Fig. 2C), with multifocal areas of coagulative necrosis and moderate numbers of lymphocytes and plasma cells admixed with the inflammation. Individual granulomas were readily distinguished even in heavily infiltrated tissues. In addition, cat C had a severe, multifocal, partly

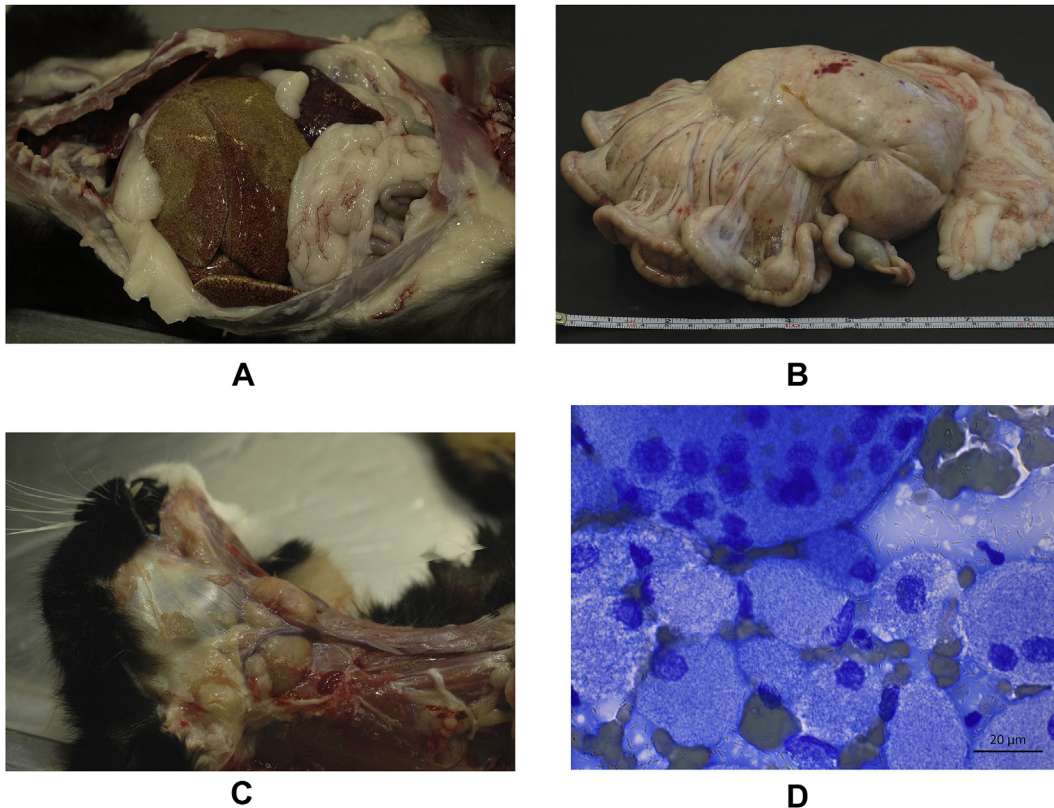


Fig. 1. (A) Severe diffuse hepatomegaly (cat A). (B) Mesenteric mass (cat B), approximately $16 \times 18 \times 15$ cm, soft and pale, weighing 500 g. (C) Severe lymphadenomegaly of the retropharyngeal lymph nodes (cat C). (D) Cytology of the mesenteric mass (cat B) showing markedly distended macrophages, giant cells and numerous unstained rod-shaped bacteria within the macrophages intracellularly and extracellularly. MGG.

transmural, granulomatous enteritis in the small intestine and microscopical miliary granulomas in the subepicardial area of the left ventricle and within the thyroid glands.

In all cats, macrophages laden with ZN-positive bacteria were present within the alveolar walls and were free in the alveoli and occasionally, free mycobacteria were seen within the alveolar fluid (Fig. 2D). Cat C had multifocal histiocytic infiltration of the tracheal lymphoid tissue with ulceration of the overlying epithelium and free mycobacteria in the tracheal lumen. In cats A and B, single mycobacteria-filled macrophages were present multifocally within the glomerular tufts of the kidney (Fig. 2E) and in cat C, mild focal histiocytic infiltration was noted around a renal cortical vein, with free mycobacteria within glomerular tufts, separated from glomerular filtrate by the basement membrane. The infiltration was mild without granuloma formation and at times, macrophages were difficult to ascertain in HE-stained sections. In cat B the epithelium of the small intestinal villi was eroded multifocally, with mycobacteria-laden macrophages separated from faeces by the basement membrane, and in

cat C, multifocal epithelial ulceration was seen with free mycobacteria in the intestinal lumen (Fig. 2D).

In addition, cat A had moderate multifocal chronic lymphoplasmacytic interstitial nephritis with mild fibrosis and mild, multifocal, chronic neutrophilic subendocardial myocarditis affecting the left ventricle. IHC for feline coronavirus antigen was negative in all cases.

Microbiology

All cats had different NTM species isolated from tissue samples. In cat A, *Mycobacterium malmoeense* was isolated from the liver. In cat B, DNA sequence closest to *Mycobacterium branderi/shimoidei* was amplified from the abdominal mass. In cat C, *M. avium* was isolated from a lymph node.

Discussion

This case series describes three cases of disseminated NTM infections in cats with no apparent underlying immunocompromise. To the authors' knowledge, *M. branderi/shimoidei* has not previously been verified as the

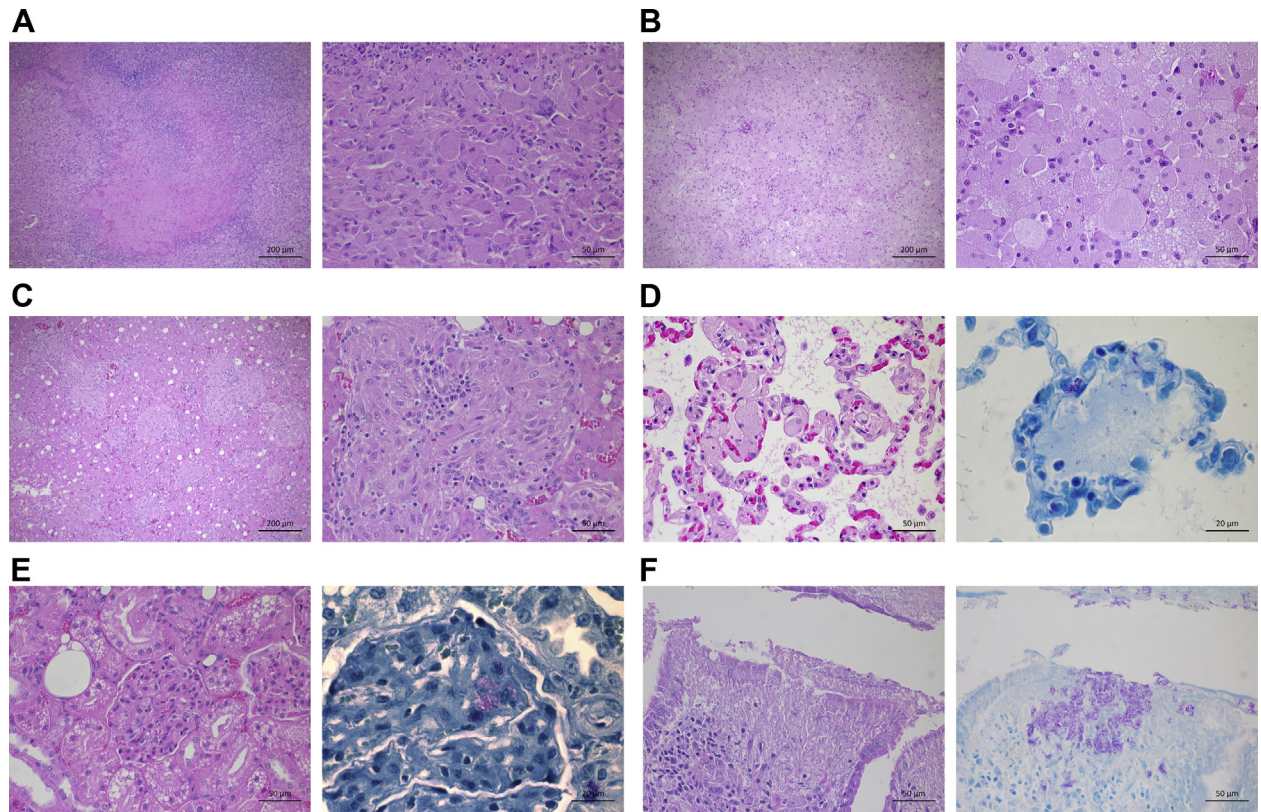


Fig. 2. (A) Adrenal (cat A), showing a large area of necrosis with surrounding histiocytic infiltration and scattered giant cells. HE. Inset: closer view of the histiocytic infiltration. HE. (B) Abdominal mass (cat B), showing marked infiltration of enlarged macrophages. HE. Inset: high-power view of the diffuse histiocytic infiltration. HE. (C) Liver (cat C), showing multifocal nodular granulomas. HE. Inset: high-power view of a granuloma. HE. (D) Lung (cat B), showing multifocal large histiocytes within the alveolar walls. HE. Inset: acid-fast rods within the histiocytes and free in the alveolar space. ZN. (E) Kidney (cat B), showing mild basement membrane thickening in the glomeruli and multifocal aggregates of histiocytes within the glomerular tufts. HE. Inset: acid-fast rods within the glomerular tufts. ZN. (F) Small intestine (cat C) with focal epithelial ulceration. HE. Inset: numerous acid-fast rods within the ulcerated villus and free in the intestinal lumen. ZN.

cause of a generalized infection in cats. *M. malmloense* has been reported in a soft tissue mass (Hetzl *et al.*, 2012) and as an unspecified infection (Gunn-Moore *et al.*, 2011a).

All animals had at least a partial history of an outdoor life and as hunting and fighting has been described as predisposing factors for mycobacterial infections (Gunn-Moore, 2014), the infections most likely originated from contact with infected prey or soil. Of the systemic NTM infections described, only *M. avium* and *M. simiae* have been described in cats with no apparent immunocompromise (Morfitt *et al.*, 1989; Barry *et al.*, 2002; Dietrich *et al.*, 2003; Knippel *et al.*, 2004; Baral *et al.*, 2006; De Groot *et al.*, 2010; Rivière *et al.*, 2011). An idiopathic CD4⁺ (cluster of differentiation) T-cell lymphopenia was suspected to be the cause of a *M. xenopi* infection (Meeks *et al.*, 2008) and local surgery may have caused fulminant of another *M. xenopi* infection (MacWilliams *et al.*, 1998). FIV infection was described with *M. heckeshornense* infection (Elze *et al.*, 2013). No apparent immu-

nocompromising factors were noted in the history or macroscopical or histological findings in the present cases. Mycobacterial infection should be considered a differential diagnosis for systemic granulomatous inflammation, even in immunocompetent cats, especially in shelter or barnyard animals.

The cytological appearance of samples from all cases correlated well with findings described in the literature (Raskin, 2010; Cowell and Arndt, 2014) and cytological interpretation was straightforward from MGG staining. Cytology is described to be a useful tool in lepromatous lesions, but has lower sensitivity in tuberculoid lesions (Raskin, 2010). However, all of the present cases had abundant mycobacteria within macrophages and organisms free in the background, readily allowing cytological diagnosis.

There were slight differences in the gross findings between the cases. Lymph nodes and spleen were affected in all cases, while only cats A and C had gross changes in the liver and lungs. The presence of necrosis also varied between the cases. *M. malmloense* is

phylogenetically closer to *M. avium* than to *M. branderi/shimodei* (Schrenzel, 2012), which could in part account for the different gross findings. However, no morphological differences are reported between different mycobacterial infections (Gunn-Moore *et al.*, 2011a) and more cases are needed to determine whether there are differences between the infections caused by different mycobacterial species. In previous studies (Morfitt *et al.*, 1989; Knippel *et al.*, 2004; Baral *et al.*, 2006; De Groot *et al.*, 2010; Gunn-Moore *et al.*, 2011a), lymph node involvement was common, as it was in the present study. Sampling an enlarged lymph node can be a fast and relatively easy way to confirm a diagnosis. *M. avium* has been described to cause enlarged abdominal lymph nodes (Barry *et al.*, 2002; Knippel *et al.*, 2004; Rivière *et al.*, 2011), similar to cats B and C in this study and in addition to feline infectious peritonitis and lymphoma, mycobacteriosis should be considered as a differential diagnosis when markedly enlarged abdominal lymph nodes are noted.

There were clear histological differences between the cases. The lesions of cat C resembled classical tuberculous granulomas, while cats A and B had more diffuse infiltration with no apparent granuloma formation. There also appeared to be an affinity for vascular structures in cats A and B, which was absent from the lesions in cat C. Histological patterns similar to those reported in cat C are described with *M. avium* infection (Morfitt *et al.*, 1989; Knippel *et al.*, 2004; Baral *et al.*, 2006). To the best of our knowledge, there are no detailed descriptions in the literature concerning the histological pattern for *M. branderi/shimodei* or *M. malmoense* infection, but Gunn-Moore *et al.* (2011b) found no significant differences between the histological changes related to infections by different mycobacteria. However, most of those cases involved infection with MTC species, MAC species or were culture-negative, with only one cat with *M. malmoense* infection studied. When considering giant cells, the present findings match the results of Gunn-Moore *et al.* (2011b), with giant cells appearing with *M. malmoense* infection, but being rare in lesions caused by *M. avium*. In cat C, mycobacteria-laden macrophages were also often seen within the adipose tissue of different organs, which could indicate similar predilection for adipose tissue as reported for some NTM species (Gunn-Moore, 2014).

All grossly affected organs had an abundance of mycobacteria-laden macrophages, with strong acid-fast staining. Hetzel *et al.* (2012) described similar results with *M. malmoense*, but *M. avium* has been described with either myriad or only few intralosomal bacteria (Baral *et al.*, 2006). In addition, all cases had

several histologically-affected organs where gross lesions were absent. Based on these results, mycobacterial spreading between organ systems may happen faster than the formation of visible lesions. This should be taken into account when considering surgical excision of lesions.

The presence of free mycobacteria within pulmonary structures, the intestinal lumen and glomerular tufts could lead to shedding of the mycobacteria. NTM species are widespread in the environment (Koh, 2017) and because of the composition of their outer membrane are relatively resistant to chlorine and ozone (Daley, 2017). Even though people and animals are readily exposed to the bacteria in the environment (Griffith *et al.*, 2007), infections caused by NTM are rare and, to our knowledge, there are no reported animal-to-human infections of NTM species outside the MAC. However, considering the close relationship of owners and pets and the survivability of mycobacteria in the household environment, a cat shedding mycobacteria in its faeces and sputum may increase the owner's exposure to mycobacteria. This should be taken into consideration, especially if the animal is infected with MAC species or if the owner has any immunocompromise.

To our knowledge, *M. branderi/shimodei* has not been described previously as a naturally occurring infection in animals. Both are relatively uncommon pathogens in human medicine (Bittner and Preheim, 2016) and have been described mostly in the lung of both immunocompromised and immunocompetent patients (Galizzi *et al.*, 2013; Kanaji *et al.*, 2013; Turvey *et al.*, 2017). The sequencing method used in this study could not differentiate between the two species. *M. malmoense* has been isolated from natural waters in Finland (Bittner and Preheim, 2016) and causes mainly pulmonary infections in people (Bittner and Preheim, 2016; Koh, 2017), with cases reported in immunocompetent patients (Jeon *et al.*, 2015). *M. avium* causes respiratory disease in both immunocompetent and immunocompromised patients, as well as disseminated disease in immunocompromised patients (Daley, 2017).

Our findings in this case series highlight that systemic mycobacterial infection in cats is not only restricted to immunocompromised animals and that NTM species outside the MAC can be causative agents of feline disease. Mycobacterial infection should be considered as a differential diagnosis in cats with generalized lymphadenomegaly or an abdominal mass, especially in free-roaming or shelter animals. Cytology or biopsy of affected tissue can give a speedy diagnosis in systemic forms of the disease.

Acknowledgments

The authors thank the laboratory technicians from the histology laboratory and post-mortem room for invaluable assistance, J. Linden for help with methodology and T. Grönthal for assistance with images. This research did not receive any specific grant from funding agencies in the public, commercial or not-for-profit sectors.

Conflict of Interest Statement

The authors declare no conflict of interest with respect to publication of this manuscript.

Supplementary data

Supplementary data related to this article can be found at <https://doi.org/10.1016/j.jcpa.2018.02.002>.

References

- Avanzi C, del-Pozo J, Benjak A, Stevenson K, Simpson VR *et al.* (2016) Red squirrels in the British Isles are infected with leprosy bacilli. *Science*, **354**, 744–747.
- Balamayooran G, Pena M, Sharma R, Truman RW (2015) The armadillo as an animal model and reservoir host for *Mycobacterium leprae*. *Clinics in Dermatology*, **33**, 108–115.
- Baral RM, Metcalfe SS, Krockenberger MB, Catt MJ, Barrs VR *et al.* (2006) Disseminated *Mycobacterium avium* infection in young cats: overrepresentation of Abyssinian cats. *Journal of Feline Medicine & Surgery*, **8**, 23–44.
- Barry M, Taylor J, Woods JP (2002) Disseminated *Mycobacterium avium* infection in a cat. *Canadian Veterinary Journal*, **43**, 369–371.
- Bittner MJ, Preheim LC (2016) Other slow-growing nontuberculous mycobacteria. *Microbiology Spectrum*, **4**, <https://doi.org/10.1128/microbiolspec.TNMI7-0012-2016>.
- Broughan JM, Downs SH, Crawshaw TR, Upton PA, Brewer J *et al.* (2013) *Mycobacterium bovis* infections in domesticated non-bovine mammalian species. Part I: Review of epidemiology and laboratory submissions in Great Britain 2004–2010. *The Veterinary Journal*, **198**, 339–345.
- Cowell RL, Arndt TP (2014) Selected infectious agents. In: *Cowell and Tyler's Diagnostic Cytology and Hematology of the Dog and Cat*, 4th Edit., AC Valenciano, RL Cowell, Eds., Elsevier Mosby, St Louis, pp. 49–50.
- Cummings L, Riley L, Black L, Souvorov A, Resenchuk S *et al.* (2002) Genomic BLAST: custom-defined virtual databases for complete and unfinished genomes. *FEMS Microbiology Letters*, **216**, 133–138.
- Daley CL (2017) *Mycobacterium avium* complex disease. *Microbiology Spectrum*, **5**, <https://doi.org/10.1128/microbiolspec.TNMI7-0045-2017>.
- De Groot PHS, van Ingen J, de Zwaan R, Boeree MJ, van Soolingen D (2010) Disseminated *Mycobacterium avium* subsp. *avium* infection in a cat, the Netherlands. *Veterinary Microbiology*, **144**, 527–529.
- Dietrich U, Arnold P, Guscetti F, Pfyffer GE, Spiess B (2003) Ocular manifestation of disseminated *Mycobacterium simiae* infection in a cat. *Journal of Small Animal Practice*, **44**, 121–125.
- Elze J, Grammel L, Richter E, Aupperle H (2013) First description of *Mycobacterium heckeshornense* infection in a feline immunodeficiency virus-positive cat. *Journal of Feline Medicine & Surgery*, **15**, 1141–1144.
- Esteban J, Muñoz-Egea MC (2016) *Mycobacterium bovis* and other uncommon members of the *Mycobacterium tuberculosis* complex. *Microbiology Spectrum*, **4**, <https://doi.org/10.1128/microbiolspec.TNMI7-0021-2016>.
- Fitzgerald DW, Sterling TR, Haas DW (2010) *Mycobacterium tuberculosis*. In: *Mandell, Douglas, and Bennett's Principles and Practice of Infectious Diseases*, 7th Edit., Vol. 2, GL Mandell, JE Bennet, R Dolin, Eds., Churchill Livingstone Elsevier, Philadelphia, pp. 3129–3163.
- Galizzi N, Tortoli E, Gori A, Morini F, Lapadula G (2013) A case of mild pulmonary disease due to *Mycobacterium shimoidei* with a favourable outcome. *Journal of Clinical Microbiology*, **51**, 3467–3468.
- Griffin A, Newton AL, Aronson LR, Brown DC, Hess RS (2003) Disseminated *Mycobacterium avium* complex infection following renal transplantation in a cat. *Journal of the American Veterinary Medical Association*, **222**, 1097–1101.
- Griffith DE, Aksamit T, Brown-Elliott BA, Catanzaro A, Daley C *et al.* (2007) An official ATS/IDSA statement: diagnosis, treatment, and prevention of nontuberculous mycobacterial diseases. *American Journal of Respiratory and Critical Care Medicine*, **174**, 367–416.
- Gunn-Moore DA (2014) Feline mycobacterial infections. *Veterinary Journal*, **201**, 230–238.
- Gunn-Moore DA, Gaunt C, Shaw DJ (2013) Incidence of mycobacterial infections in cats in Great Britain: estimate from feline tissue samples submitted to diagnostic laboratories. *Transboundary and Emerging Diseases*, **60**, 338–344.
- Gunn-Moore DA, McFarland SE, Brewer JI, Crawshaw TR, Clifton-Hadley RS *et al.* (2011a) Mycobacterial disease in cats in Great Britain: I. Culture results, geographical distribution and clinical presentation of 339 cases. *Journal of Feline Medicine & Surgery*, **13**, 934–944.
- Gunn-Moore DA, McFarland SE, Schock A, Brewer JI, Crawshaw TR *et al.* (2011b) Mycobacterial disease in a population of 339 cats in Great Britain: II. Histopathology of 225 cases, and treatment and outcome of 185 cases. *Journal of Feline Medicine & Surgery*, **13**, 945–952.
- Hetzel U, Dixon CE, Just AE, Birtles RJ, Kipar A (2012) *Mycobacterium malmoense* as an extrapulmonary pathogen of cats. *Veterinary Record*, **171**, 274.
- Ioannidis P, Papaventsis D, Karabela S, Nikolaou S, Panagi A *et al.* (2011) Cepheid GeneXpert MTB/RIF assay for *Mycobacterium tuberculosis* detection and rifampin resistance identification in patients with substantial clinical indications of tuberculosis and smear-negative microscopy results. *Journal of Clinical Microbiology*, **49**, 3068–3070.

- Jeon MK, Yoon JA, Kim J, Yi S, Sung H *et al.* (2015) Lung disease caused by *Mycobacterium malmoeense* in an immunocompetent patient. *Tuberculosis and Respiratory Diseases*, **78**, 293–296.
- Kanaji N, Kushida Y, Bandoh S, Ishii T, Haba R *et al.* (2013) Membranous glomerulonephritis associated with *Mycobacterium shimoidei* pulmonary infection. *American Journal of Case Reports*, **14**, 543–547.
- Kipar A, Bellmann S, Kremendahl J, Köhler K, Reinacher M (1998) Cellular composition, coronavirus antigen expression and production of specific antibodies in lesions in feline infectious peritonitis. *Veterinary Immunology and Immunopathology*, **65**, 243–257.
- Knippel A, Hetzel U, Baumgärtner W (2004) Disseminated *Mycobacterium avium-intracellulare* infection in a Persian cat. *Journal of Veterinary Medicine. B*, **51**, 464–466.
- Koh WJ (2017) Nontuberculous mycobacteria – overview. *Microbiology Spectrum*, **5**, <https://doi.org/10.1128/microbiolspec.TNMI7-0024-2016>.
- Lee SH, Go DM, Woo SH, Park H-T, Kim E *et al.* (2017) Systemic *Mycobacterium kansasii* infection in a domestic shorthair cat. *Journal of Comparative Pathology*, **157**, 215–219.
- Lloret A, Hartmann K, Pennisi MG, Gruffydd-Jones T, Addie D *et al.* (2013) Mycobacterioses in cats: ABCD guidelines on prevention and management. *Journal of Feline Medicine & Surgery*, **15**, 591–597.
- MacWilliams PS, Whitley N, Moore F (1998) Lymphadenitis and peritonitis caused by *Mycobacterium xenopi* in a cat. *Veterinary Clinical Pathology*, **27**, 50–53.
- Mauldin EA, Peters-Kennedy J (2016) Integumentary system. In: *Jubb, Kennedy and Palmer's Pathology of Domestic Animals*, 6th Edit., Vol. 1, MG Maxie, Ed., Elsevier, St. Louis, pp. 639–640.
- Meeks C, Levy JK, Crawford PC, Farina LL, Origgi F *et al.* (2008) Chronic disseminated *Mycobacterium xenopi* infection in a cat with idiopathic CD4⁺ T lymphocytopenia. *Journal of Veterinary Internal Medicine*, **22**, 1043–1047.
- Morfitt DC, Matthews JA, Thoen CO, Kluge JP (1989) Disseminated *Mycobacterium avium* serotype 1 infection in a seven-month-old cat. *Journal of Veterinary Diagnostic Investigation*, **1**, 354–356.
- Pesciaroli M, Alvarez J, Boniotti MB, Cagiola M, Di Marco V *et al.* (2014) Tuberculosis in domestic animal species. *Research in Veterinary Science*, **97**, S78–S85.
- Poncelet L, Coppens A, Peeters D, Bianchi E, Grant CK *et al.* (2008) Detection of antigenic heterogeneity in feline coronavirus nucleocapsid in feline pyogranulomatous meningoencephalitis. *Veterinary Pathology*, **45**, 140–153.
- Quinn PJ, Markey BK, Leonard FC, FitzPatrick ES, Fanning S *et al.* (2011) *Mycobacterium* species. In: *Veterinary Microbiology and Microbial Disease*, 2nd Edit., PJ Quinn, BK Markey, FC Leonard, ES FitzPatrick, S Fanning *et al.*, Eds., Blackwell Science Ltd., Singapore, pp. 250–261.
- Raskin RE (2010) Skin and subcutaneous tissue. In: *Canine and Feline Cytology: A Color Atlas and Interpretation Guide*, 2nd Edit., RE Raskin, DJ Meyer, Eds., Saunders Elsevier, St. Louis, pp. 34–37.
- Renault CA, Ernst JD (2010) *Mycobacterium leprae*. In: *Mandell, Douglas, and Bennett's Principles and Practice of Infectious Diseases*, 7th Edit., Vol. 2, GL Mandell, JE Bennet, R Dolin, Eds., Churchill Livingstone Elsevier, Philadelphia 3165–3163.
- Rivière D, Pingret J-L, Etievant M, Jechoux A, Lanore D *et al.* (2011) Disseminated *Mycobacterium avium* subspecies infection in a cat. *Journal of Feline Medicine & Surgery*, **13**, 125–128.
- Russo C, Tortoli E, Menichella D (2006) Evaluation of the new genotype *Mycobacterium* assay for identification of mycobacterial species. *Journal of Clinical Microbiology*, **44**, 334–339.
- Schrenzel MD (2012) Molecular epidemiology of mycobacteriosis in wildlife and pet animals. *Veterinary Clinics of North America: Exotic Animal Practice*, **15**, 1–23.
- Shah NM, Davidson JA, Anderson LF, Lalor MK, Kim J *et al.* (2016) Pulmonary *Mycobacterium avium-intracellulare* is the main driver of the rise in non-tuberculous mycobacteria incidence in England, Wales and Northern Ireland, 2007–2012. *BMC Infectious Diseases*, **16**, <https://doi.org/10.1186/s12879-016-1521-3>.
- Thirunavukkarasu S, Plain KM, de Silva K, Marais BJ, Whittington RJ (2017) Applying the One Health concept to mycobacterial research – overcoming parochialism. *Zoonoses and Public Health*, **64**, 401–422.
- Tuuminen T, Heinäsmäki T, Kerttula T (2006) First report of bacteremia by *Asaia bogorensis*, in a patient with a history of intravenous drug abuse. *Journal of Clinical Microbiology*, **44**, 3048–3050.
- Turvey SL, Tyrrell GJ, Hernandez C, Kabbani D, Duocette K *et al.* (2017) *Mycobacterium branderi* infection: case report and literature review of an unusual and difficult-to-treat non-tuberculous mycobacterium. *International Journal of Infectious Diseases*, **58**, 65–67.

[Received, October 13th, 2017]
 [Accepted, February 21st, 2018]