

Review Article



Iteration of Reverse Controlled Antegrade and Retrograde Tracking for Coronary Chronic Total Occlusion Intervention: a Current Appraisal

Debabrata Dash , MD, DM, FCCP, FAPSC, FSCAI

Department of Cardiology, Aster Hospital, Dubai, UAE



Received: Apr 13, 2020

Revised: May 20, 2020

Accepted: Jun 10, 2020

Correspondence to

Debabrata Dash, MD, DM, FCCP, FAPSC, FSCAI

Department of Cardiology, Aster Hospital, Mankhool, Kuwait Road, Al Mankhool, 119428 Dubai, UAE.

E-mail: dr_dash2003@yahoo.com

Copyright © 2020. The Korean Society of Cardiology

This is an Open Access article distributed under the terms of the Creative Commons Attribution Non-Commercial License (<https://creativecommons.org/licenses/by-nc/4.0>) which permits unrestricted noncommercial use, distribution, and reproduction in any medium, provided the original work is properly cited.

ORCID iDs

Debabrata Dash 

<https://orcid.org/0000-0003-1354-3808>

Conflict of Interest

The author has no financial conflicts of interest.

ABSTRACT

Coronary chronic total occlusion (CTO) remains one of the most challenging subsets for percutaneous coronary intervention (PCI). The retrograde recanalization is one of the most significant amendments of the technique that remains critical to improved success of CTO PCI. Currently the reverse controlled antegrade and retrograde tracking (CART) is the most dominant retrograde technique. With emergence of new equipment and important iterations, this approach has become safer, faster and more successful. In this review, the author proposes the iteration and standardization of this technique which would further facilitates its adoption with more efficacy and safety.

Keywords: Percutaneous coronary intervention; Chronic total occlusion; Reverse controlled antegrade and retrograde tracking

INTRODUCTION

The retrograde approach has revolutionized percutaneous coronary intervention (PCI) to coronary chronic total occlusions (CTO) by significantly improving success rate up to 95%.¹⁻⁴⁾ Historically the technical success rate has been limited to 65% to 70% with the antegrade approach.⁵⁾⁶⁾ Early retrograde approaches focused on direct retrograde wire crossing and the kissing wire technique. However, the modern era of retrograde CTO PCI began with the development of the controlled antegrade and retrograde tracking (CART) technique consisting of antegrade wiring into distal true lumen through a local subintimal space created by retrograde balloon dilatation.⁷⁾ The reverse CART is the most commonly employed retrograde technique which involves inflation of a balloon over the antegrade guidewire followed by retrograde guidewire crossing into proximal true lumen utilizing the space created by the antegrade balloon inflation.⁴⁾⁸⁾⁹⁾ It is employed as primary approach in many situations like ostial occlusions, long occlusions, severe proximal tortuosity or calcification, occlusions with ambiguous proximal cap, occlusions with a distal major bifurcation and poorly visualized distal vessel. Furthermore, this technique can be employed in lieu of converting to an investment procedure when antegrade strategy fails (**Table 1**). Since its introduction, the reverse CART technique has been modified elegantly into several subtypes to improve procedure success and efficiency.

Table 1. Indications of reverse controlled antegrade and retrograde tracking technique

Ostial occlusion
Ambiguous proximal cap: blunt stump, side branch
Long occlusions
Severe proximal tortuosity or calcification
Poor distal target
Bifurcation at distal cap
Good interventional collateral channel
Failed antegrade attempt

CONTROLLED ANTEGRADE AND RETROGRADE TRACKING TECHNIQUE

In CART technique a balloon is advanced over the retrograde guidewire and inflated to create a localized subintimal dissection within the CTO segment. This is followed by navigation of antegrade guidewire from the proximal true lumen into this subintimal space and subsequently into the distal true lumen (**Figures 1A and 2**). Then PCI is performed in an antegrade fashion. The advantage of this technique is to minimize the length of subintimal tracking through the CTO lesion.^{7,8)} The limitation is that, it is not always possible to negotiate a retrograde balloon inside the occlusion, particularly in complex CTO lesions. Sometimes, it is impossible to cross or dilate tortuous septal collateral channels (CCs). The dilatation of septal CCs carries the risk of septal injury, and retrograde passage of balloons through epicardial CCs carries considerable risks of channel rupture or balloon trapping. The CART technique involves inflation of retrograde balloon within the CTO segment to make a subintimal dissection without information about vessel size or the position of the retrograde guidewire. Extension of the subintimal space to the proximal true lumen of the CTO may cause a fatal (e.g. dissection of the left main) event when the occlusion is in the proximal segment of the left coronary system.¹⁰⁾ Other limitations are empiric estimation of retrograde balloon size and unpredictable procedure time. In the CART technique, formation of the retrograde subintimal dissection cannot be confirmed by intravascular ultrasound (IVUS), resulting in technical uncertainty and potentially augmented risk. Nowadays a classic CART is rarely performed except in some cases of ostial occlusions, heavily calcified occlusions, and when the retrograde equipment is not long enough to reach antegrade guiding catheter

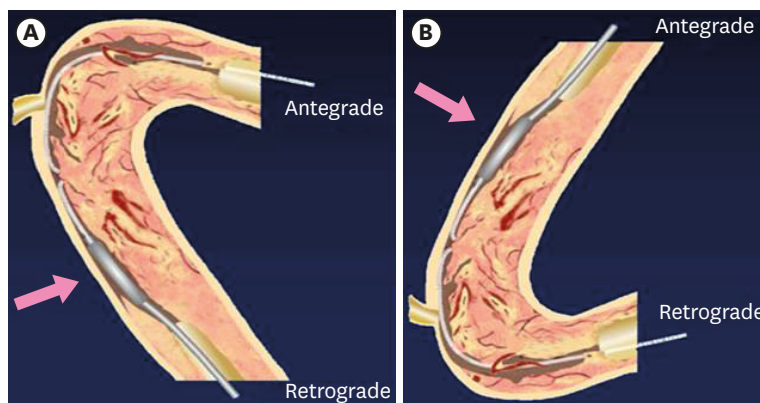


Figure 1. Schematic illustration of CART (A) and reverse CART (B). (A) Antegrade navigation of guidewire through the CTO into distal true lumen through a local subintimal dissection created by retrograde balloon (pink arrow indicates retrograde balloon). (B) Retrograde navigation of a guidewire through a subintimal space created by antegrade balloon (pink arrow indicates antegrade balloon).
 CART = controlled antegrade and retrograde tracking; CTO = chronic total occlusion.

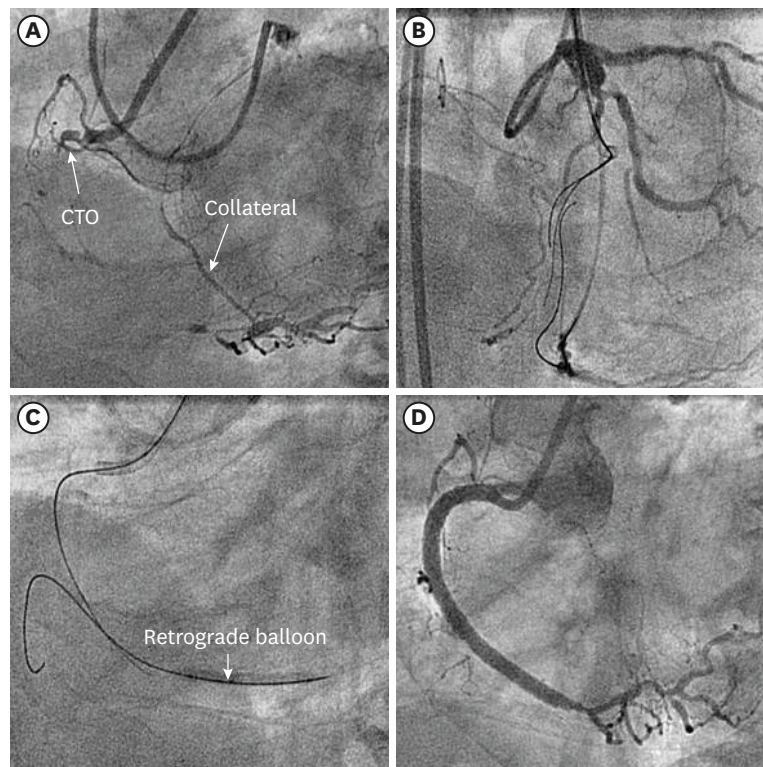


Figure 2. Depiction of CART technique in CTO. (A) A baseline coronary angiogram showing CTO of proximal RCA with good epicardial collateral channel from LCX. (B) Navigation of retrograde guidewire in epicardial collateral with support of microcatheter. (C) Dilatation of subintimal space with a retrogradely followed by antegrade guidewire advancement along the deflated balloon. (D) Final result after three overlapping DES in RCA. CART = controlled antegrade and retrograde tracking; CTO = chronic total occlusion; DES = drug-eluting stent; LCX = left circumflex artery; RCA = right coronary artery.

(with long epicardial CCs and enlarged heart). It is replaced with a safer, more efficient and reproducible reverse CART.⁸⁾

REVERSE CONTROLLED ANTEGRADE AND RETROGRADE TRACKING

The novel innovation of the Corsair microcatheter (Asahi Intecc, Aichi, Japan)¹¹⁾ resulted in a major improvement of the retrograde approach along with development of the reverse CART technique. Use of the Corsair or other microcatheters (**Table 2**) for retrograde CC crossing largely eliminates the need for balloon dilatation of CCs, reducing the risk of septal injury and allowing greater use of epicardial CCs. In addition, these microcatheters promote the exchange of retrograde guidewire and improve retrograde guidewire support and handling. The reverse CART involves retrograde dissection with a guidewire creating subintimal space past the distal cap, navigation of retrograde microcatheter over the dissection to near the proximal cap, antegrade dissection with subintimal space to a point distal to the retrograde microcatheter, and inflation of an antegrade balloon in the subintimal space next to the retrograde microcatheter with subsequent connection of both the subintimal space (common subintimal space [CSS]) followed by retrograde wiring from the microcatheter into the proximal true lumen (**Figure 1B**).⁴⁾ The reverse CART is the dominant retrograde strategy employed currently as it is easier, more predictable, quicker and safer (**Table 3**).

Table 2. Microcatheters used in CTO PCI

Name	Catheter length	Distal shaft OD	Proximal shaft OD	Design features	Recommendations
Finecross (Terumo)	150 cm	1.8 Fr	2.6 Fr	Stainless steel shaft, hydrophilic coating	Very low profile, good deliverability with limited pushability or ability to spin. Good for small & straight CC
Corsair (Asahi)	135/150 cm	2.6 Fr	2.8 F	Double layer braided stainless steel, kink resistant flexible tip (composed of tungsten powder)	Low profile, easily, deliverable, pushable. Used for traversing and dilating CC. Provides good wire backup and spinning
TurnPike (Vascular solution)	135/150 cm	2.6 Fr	3.1 Fr	Hybrid of braid & a double layer coil encapsulated between 2 polymer layers (5 layers total)	Workhorse catheter that performs well in most CTO cases
TurnPike Spiral (Vascular solution)	135/150 cm	2.6 Fr	3.1 Fr	Similar construction	Spiral enhances trackability
TurnPike Gold (Vascular solution)	135 cm	3.2 Fr	3.1 Fr	Similar construction	Tip on tip Gold enhances forward movement
TurnPike LP (Vascular solution)	135/150 cm	2.2 Fr	2.9 Fr	Similar construction with thinner tip braiding for lowering profile	Excellent for very tortuous or epicardial CC
Micro 14 (Roxwood Medical)	155 cm	1.9 Fr	2.5 Fr	Variable pitch braided shaft, torquable	Very low profile for fine & tortuous CC. Micro 14es has extra-supportive tip profile for enhanced pushability
Caravel (Asahi)	135 cm	1.9 Fr	2.6 Fr	ACT-one core precision braided shaft, hydrophilic coating	Low crossing profile, excellent for tortuous CC
Tornus (Asahi)	135	Tapered	2.1 Fr	Stainless steel braided catheter	Available in 2.1 & 2. Fr. Used as support and CC dilator
2 sizes	135	2.6 F	3.0		

CC = collateral channel; CTO = chronic total occlusion; Fr = French gauge; LP = low profile; OD = outer diameter; PCI = percutaneous coronary intervention.

Table 3. Comparison of CART and conventional reverse CART

Variables	CART	Reverse CART
Basic wiring	Antegrade	Usually retrograde
Guidewire guidance	Fluoro alone	Fluoro and IVUS
CTO re-entry method	Retrograde balloon	Antegrade balloon
Reproducibility	Less	More
Procedure time	Longer	Quicker
Gear handling	Cumbersome	Easier
Complications	More	Safer

CART = controlled antegrade and retrograde tracking technique; CTO = chronic total occlusion; IVUS = intravascular ultrasound.

This technique has been further divided into four subtypes to improve procedural success and efficacy: 1) conventional reverse CART,⁴⁾ in which increasingly larger antegrade balloons are used to achieve re-entry within the CTO segment; 2) contemporary reverse CART,⁴⁾ involving the use of small antegrade balloons and more active, intentional vessel tracking and penetration with a controllable retrograde wire still within the CTO segment and 3) assisted reverse CART⁴⁾ involving assistance from IVUS, stent, guide extension catheter etc.; 4) shifting reverse CART, in which the intimal/subintimal dissection is extended either proximal or distal to the CTO segment.

Conventional reverse controlled antegrade and retrograde tracking

Achieving a longitudinal overlap of the antegrade and retrograde guidewires is the first step of conventional reverse CART. The conventional wiring in both an antegrade and a retrograde fashion is easier to make an overlap with unambiguous course of the CTO segment. With vessel course ambiguity, severe tortuosity or heavy calcification within the CTO segment, conventional wiring is not only cumbersome but also carries the risk of vessel perforation. This warrants more efficient and safer knuckle wiring with low (Fielder XT; Asahi Intecc) to intermediate penetration force polymer-jacketed (Pilot 200; Abbott Vascular, Santa Clara, CA, USA) guidewires. The appropriate low (Fielder XTA; Asahi Intecc) to intermediate penetration force wire (Gaia second/third; Asahi Intecc) is navigated across the distal cap to

lie in subintimal space. This wire, with or without a knuckle (an umbrella-type bend or loop), is advanced via the microcatheter through CTO body within the subintimal space to establish retrograde base of operation. An antegrade base of operation is established by placing a short microcatheter at proximal cap using a workhorse wire which is then is exchanged with a low to intermediate penetration force wire to breach the proximal cap to enter subintimal space. After creating an antegrade and retrograde overlap zone, an antegrade balloon sized based on angiography is negotiated into the CTO segment to the point of guidewire overlap and inflated. The balloon dilatation makes or enlarges intimal/subintimal dissection and creates a connection between the spaces, known as CSS within which both guidewires are lying.⁴⁾¹²⁾ In the conventional reverse CART technique, a large size antegrade balloon (**Table 4**) is selected to maximize the chance of CSS formation (**Figure 3**). Usually, a low to intermediate penetration force wire is used as the retrograde wire to track the created connection. However, in case of subintimal position of antegrade wire and intimal position of the retrograde wire, a high penetration force wire (Gaia Third, Conquest 12; Asahi Intecc), Hornet 14 (Boston Scientific, Marlborough, MA, USA), may be required to advance through the intimal plaque into the subintimal space.¹²⁾

Assisted reverse controlled antegrade and retrograde tracking

If after few tissue ablations, there is failure of retrograde guidewire navigation into the antegrade guide, a guide-extension catheter (Guideliner; Vascular Solutions, Minneapolis, MN, USA), Guidezilla (Boston Scientific) can be delivered into the subintimal space to facilitate the process (mother-child reverse CART). Alternative strategies include IVUS assisted reverse CART, use of larger balloon to achieve greater tissue ablation, the use of smaller balloons with retrograde navigation of Gaia series of wires (contemporary reverse CART), deployment of stent in antegrade subintimal space for successful retrograde navigation of wire (stent assisted reverse CART) (**Figure 4**), or movement of base of operation overlap zone to a different location (shifting reverse CART).⁴⁾

Intravascular ultrasound assisted reverse controlled antegrade and retrograde tracking

IVUS is a useful imaging tool to estimate optimal size of antegrade balloon that can lead to medial disruption. The risk of perforation can be reduced substantially under IVUS assistance. Furthermore, the risk of development of medial disruption and CSS recoil is prevented by usage of IVUS. Redilatation with a larger balloon may be indicated if the CSS recoils (**Figure 4**). IVUS also is useful to monitor the position and movement of the retrograde guidewire in the subintimal space.¹³⁾¹⁴⁾ This retrograde guidewire is better navigated into the proximal true lumen under IVUS guidance. Further treatment is dictated by presence or absence of connection between antegrade and retrograde guidewire and position of antegrade guide wire (**Figure 5**).

Table 4. Comparison of conventional and contemporary reverse CART

	Conventional reverse CART	Contemporary reverse CART
Basic CTO wiring	Antegrade or retrograde	Antegrade
Knuckling (antegrade or retrograde)	Suitable	Unsuitable
Antegrade balloon size	Large	Small
Retrograde guidewire	Low to intermediate penetration force wire	Gaia (Asahi Intecc, Aichi, Japan) series of guidewires
Retrograde wire control	Often imprecise	Precise and intentional
Indication	CTOs requiring bilateral wiring, calcific and tortuous anatomy	Clear proximal cap, occlusion course without heavy calcification or tortuosity
Unsuitability	None	Short (<15 mm) occlusion, CTOs with ambiguous proximal cap, heavy calcification and severe tortuosity, use of knuckle wires

CART = controlled antegrade and retrograde tracking technique; CTO = chronic total occlusion.

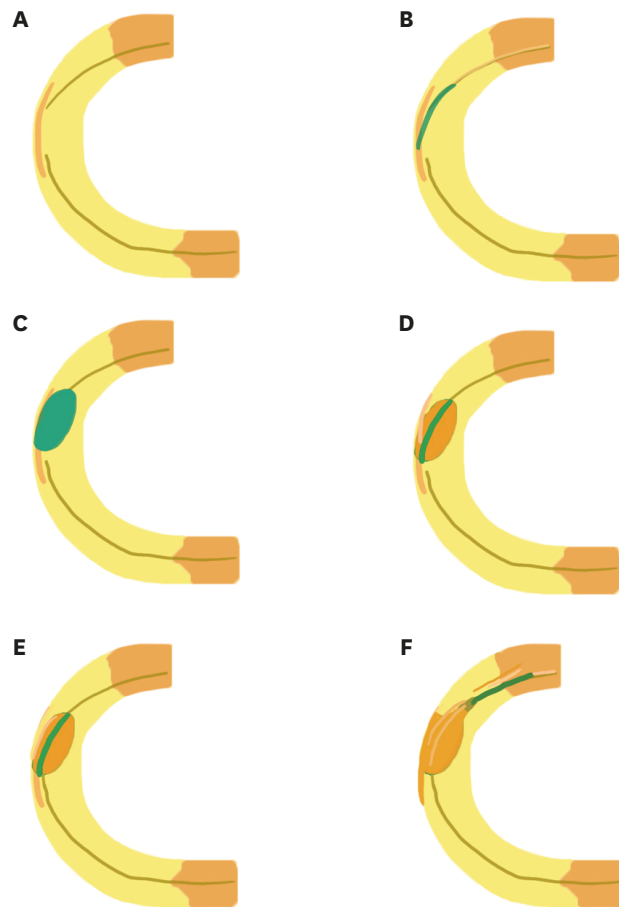


Figure 3. Schematic illustration of the conventional reverse CART technique. (A) A longitudinal overlap of the antegrade and retrograde guidewires in a case of proximal RCA CTO. (B) Delivery of a balloon over the antegrade guidewire to the point of guidewire overlap. (C) Inflation of the balloon. (D) Creation of a connection is between the spaces (CSS) containing both the guidewires. (E) Navigation of the retrograde guidewire through the CSS. (F) The subsequent advancement of the retrograde guidewire into the proximal true lumen. CART = controlled antegrade and retrograde tracking; CSS = common subintimal space; CTO = chronic total occlusion; RCA = right coronary artery.

Stent facilitated reverse controlled antegrade and retrograde tracking

This is another novel way of optimizing re-entry. It consists of deployment of a stent from the antegrade true lumen into the subintimal space created by antegrade balloon inflation. The stent forms a clear open target, enabling rapid advancement of retrograde guidewire into the proximal true lumen. Once the retrograde guidewire engages the proximal true lumen, the approach is conventional reverse CART with externalization of a long wire and PCI via antegrade fashion. The stent reverse CART prevents recoil of CSS after antegrade ballooning and eliminates proximal vessel dissection flaps that could trap the retrograde guidewire. However, this technique is by nature an irreversible procedure as once the stent is deployed, it cannot be removed. Therefore, the failure to complete reverse CART after stent implantation might lead to stent thrombosis due to proximal thrombus propagation. So, IVUS documentation of connection between antegrade and retrograde guidewire is a prerequisite for this technique. In case of failure of clear connection, the retrograde guidewire may fail to enter the distal part of the stent and instead enter via side of the stent causing its deformation. The author places this technique as last resort option (Figure 4) in the era of contemporary reverse CART (Figure 6).⁴⁾¹⁵⁾¹⁶⁾

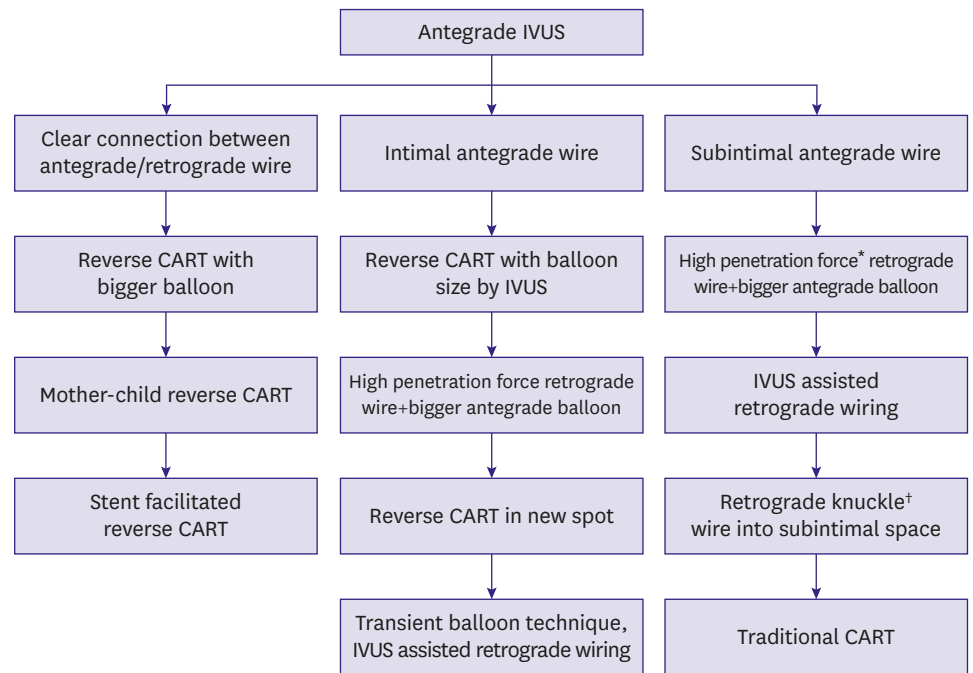


Figure 4. IVUS assisted reverse CART.

IVUS = intravascular ultrasound; CART = controlled antegrade and retrograde tracking technique.

*High penetration force wire: Gaia Third, Conquest 12(Asahi Intecc, Aichi, Japan), Hornet 14 (Boston Scientific, Marlborough, MA, USA); †Knuckle wire: Fielder XT (Asahi Intecc, Aichi, Japan), Pilot 200 (Abbott Vascular, Santa Clara, CA, USA).

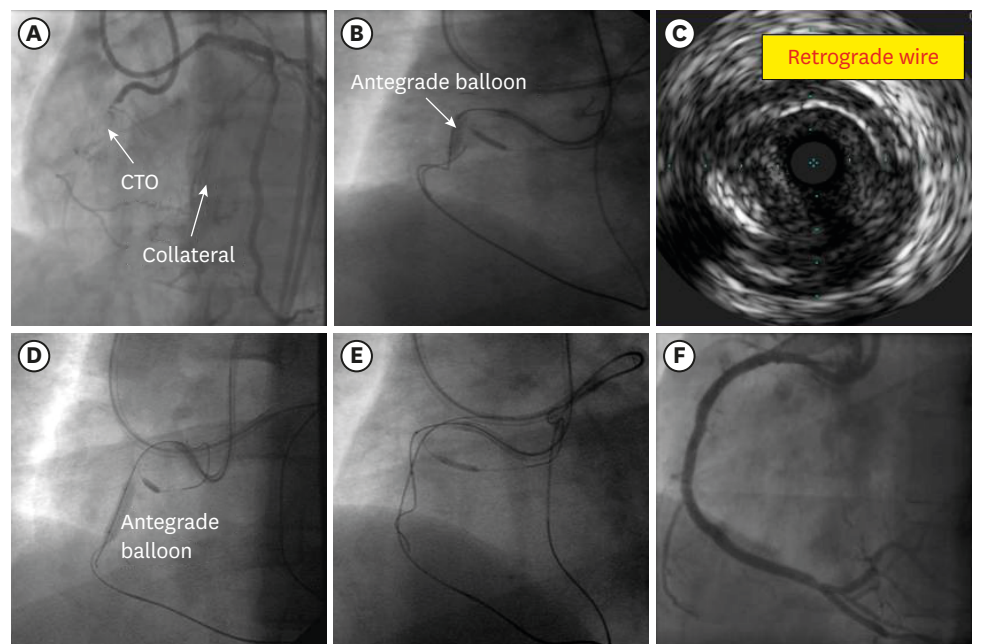


Figure 5. Depiction of IVUS assisted reverse CART. (A) A baseline coronary angiogram showing total occlusion of proximal RCA with good septal collateral channel from LAD. (B) Failure of reverse CART with 3.5 mm balloon at antegrade and retrograde wire overlap zone. (C) Depiction of large size (6 mm) vessel by IVUS. (D) Antegrade inflation of 4.5 mm balloon. (E) Successful navigation of retrograde guidewire into proximal true lumen followed by externalization. (F) Final result after three overlapping DES.

CART = controlled antegrade and retrograde tracking; DES = drug-eluting stent; IVUS = intravascular ultrasound; LAD = left anterior descending artery; RCA = right coronary artery.

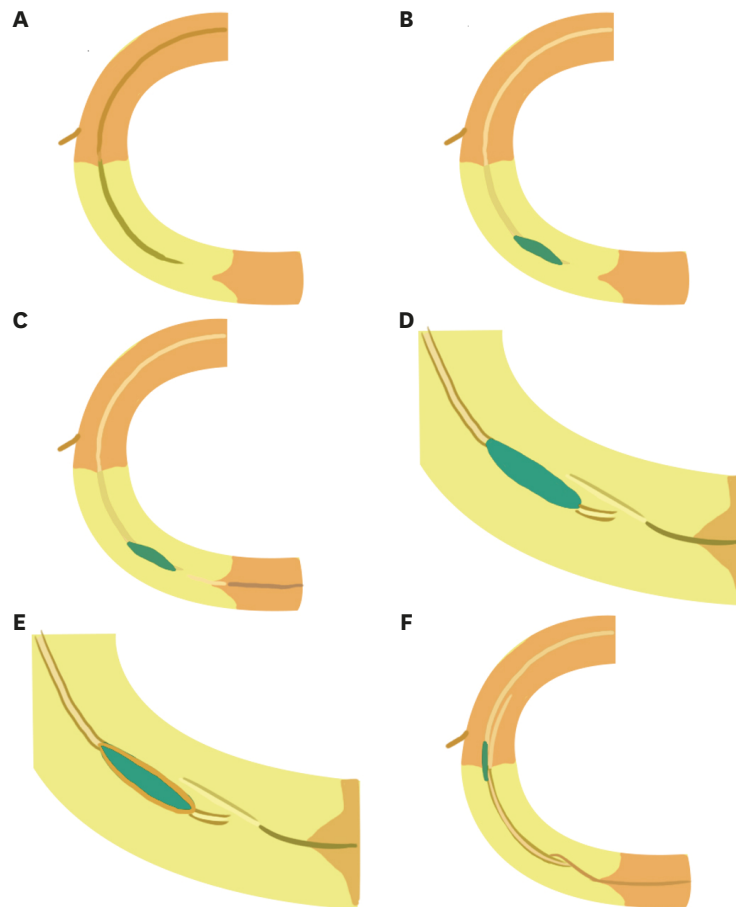


Figure 6. Schematic illustration of contemporary reverse CART. (A) Antegrade preparation depicting navigation of an antegrade guidewire through the occlusion until 5–10 mm proximal to the distal cap with the support of a microcatheter in a case of mid RCA CTO. (B) Advancement of a small balloon to the tip of the antegrade guidewire. (C) Navigation of the retrograde guidewire towards the antegrade balloon after the collateral channel crossing by a guidewire and a microcatheter. (D) The manipulation and gentle push of the retrograde guidewire towards the inflated antegrade balloon catheter (retrograde wire is lateral to balloon in this figure). (E) Navigation of the retrograde guidewire into the space (created by the balloon) after balloon deflation. (F) Negotiation of the retrograde guidewire into the proximal true lumen with sequential antegrade balloon inflation within the CTO segment proximal to the connecting point.
 CART = controlled antegrade and retrograde tracking; CTO = chronic total occlusion; RCA = right coronary artery.

Mother-child reverse controlled antegrade and retrograde tracking

The mother-child concept, an elegant modification of reverse CART, involves the use of a guide-extension catheter such as Guideliner (Vascular Solutions), Guidezilla (Boston Scientific) into antegradely created subintimal space to facilitate retrograde guidewire navigation into proximal true lumen. When positioned in the subintimal space, guide extension device provides a continuous conduit to the antegrade guide (Figure 4). So, creation of another new dissection plane or wiring into side branches may not be required. Unlike a stent, the guide extension device may be removed or repositioned once there is failure of connection between the antegrade and retrograde true lumen.⁴⁾¹⁷⁾

Transit balloon assisted reverse controlled antegrade and retrograde tracking

In this technique, the antegrade balloon is kept inflated during retrograde crossing attempts and is punctured by the retrograde guidewire, which is then advanced while the punctured antegrade balloon is retracted (Figure 4).¹⁸⁾

Contemporary reverse controlled antegrade and retrograde tracking

The unwarranted intentional intimal/subintimal dilatation with a large balloon in the conventional reverse CART technique may lead to distal propagation of the subintimal hematoma and vessel perforation. Some reports indicate that the CART and conventional reverse CART techniques could be associated with subsequent coronary artery aneurysm formation and increased risk for target vessel revascularization due to longer stent length.¹⁹⁾²⁰⁾ Moreover, excessive manipulation of the retrograde guidewire or use of a knuckle wire technique to achieve guidewire overlap can create a large space around the retrograde guidewire, that may be an obstacle for the precise directional control of the same guidewire. Although this challenge may be overcome by dilatation with a larger antegrade balloon and tracking with low to intermediate penetration force guidewires, it is often cumbersome and time consuming.

The contemporary reverse CART technique has been introduced⁵⁾ to minimize trauma to the vessel wall and to make the procedure more efficient through a precise directional control by efficient use of deflection mechanisms of the retrograde guidewire (Gaia series). The key steps of this technique are the: 1) antegrade preparation; 2) use of a small antegrade balloon as a target for the retrograde wire; and 3) retrograde intentional vessel tracking using a guidewire with high torque control (**Figures 6 and 7**).

This technique commences with simultaneous dual contrast injection from the antegrade and retrograde guiding catheters and navigation of an antegrade guidewire through the occlusion with the support of a microcatheter to within 5 to 10 mm of the distal cap. It is

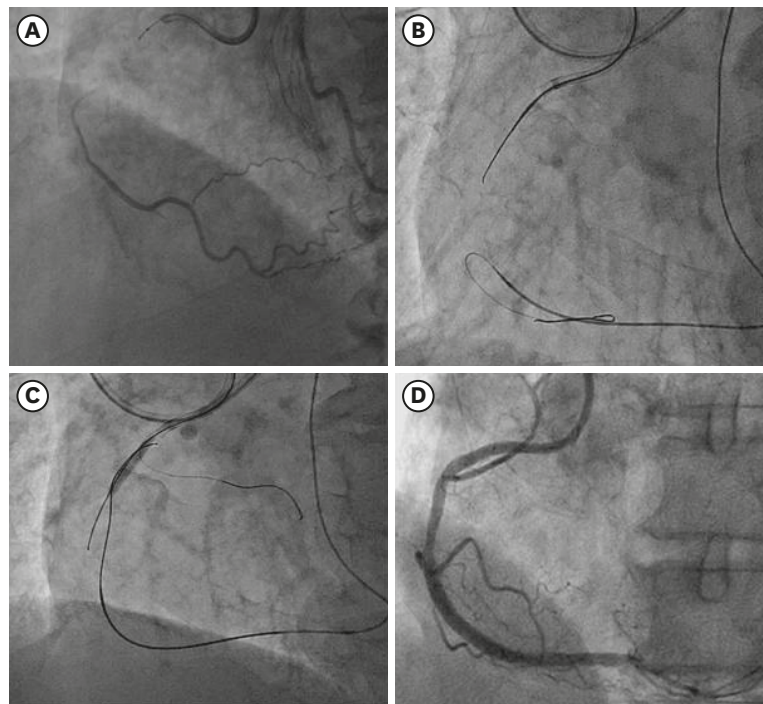


Figure 7. Depiction of contemporary reverse CART. (A) A baseline coronary angiogram depicting CTO of proximal RCA with good septal collateral from LAD. (B) Subintimal position of antegrade guidewire. (C) Antegrade small (2 mm) balloon inflation followed by retrograde penetration of wire into proximal true lumen. (D) Final result after wire externalization and three overlapping DES.

CART = controlled antegrade and retrograde tracking; CTO = chronic total occlusion; DES = drug-eluting stent; LAD = left anterior descending artery; RCA = right coronary artery.

taken care not to advance the antegrade guidewire beyond the CTO segment to minimize the risk of formation of distal hematoma. Next, the microcatheter is exchanged for a small balloon (2.0 mm diameter in most cases) which is advanced towards the tip of the guidewire. Except for an ambiguous proximal cap or uncertainty of CC crossing, antegrade preparation first is preferable as it reduces donor artery risk and ischemic time of the CTO territory, and encourages going directly to reverse CART after retrograde CC crossing.

The retrograde approach is then commenced with CC crossing by guidewire and microcatheter. The retrograde CTO segment wiring is performed using a guidewire with good torque control and high penetration efficiency (Gaia series). The retrograde guidewire should be navigated without excessive torqueing and directed towards the antegrade balloon so that the shaft of the antegrade balloon and the retrograde wire are as coaxial as possible at the point of puncture. The retrograde puncture should aim towards the end of the balloon first (end balloon wiring technique) and, if this fails, towards the lateral side of the balloon. Fluoroscopy in two orthogonal projections is recommended to confirm the positional relationship between the retrograde guidewire and the antegrade balloon. After gently pushing the retrograde guidewire, the antegrade balloon is deflated, allowing the retrograde guidewire to puncture into the space created by the antegrade balloon. In case of failure, retrograde guidewire is still controllable because of smaller dissection plane created by smaller antegrade balloon. This technique does not usually warrant IVUS guidance as the retrograde wire is intentionally directed towards and then into the space created by the antegrade balloon under fluoroscopic guidance. However, if there is difficulty in achieving a connection, it is recommended to embark on IVUS assisted reverse CART.⁴⁾¹²⁾

The initial procedural strategy for CTO PCI is crafted based on anatomy such as proximal cap ambiguity, length of occlusion, distal vessel, interventional CCs. It is important to exploit the situation of conditional probability and attempts to use the procedure that is most likely to be successful, and in case of failures, endorses rapid change to alternative strategies.²¹⁾ Once the decision to perform reverse CART is considered, it is recommended to adopt contemporary subtype because of its efficiency and safety. This technique could be employed as a primary approach or as an investment procedure when the antegrade approach is unsuccessful. The contemporary reverse CART is considered unsuitable in CTO cases with ambiguous proximal cap and/or CTO course, severe tortuosity, and heavy calcification because this technique requires antegrade preparation before embarking on retrograde CTO segment wiring, and the knuckle wire technique cannot be contemplated to advance the antegrade or retrograde guidewire as it is likely to create large spaces around the guidewires resulting in reduced retrograde wire control (**Table 4**). Also, short segment (<15 mm) CTOs are not suitable for the contemporary reverse CART, because of difficulty in embarking on antegrade preparation without propagating the hematoma beyond the distal cap.¹²⁾ Short CTOs are best dealt with antegrade or retrograde wire escalation. Similarly, the contemporary reverse CART may not be possible with poor torque control of the retrograde guidewire due to tortuosity of CCs or strong cardiac motion.¹²⁾²²⁾ The length alone is not predictive of failure to cross the CTO body with traditional wiring techniques. However, traditional wiring is likely to fail in case of a long CTO accompanied by tortuosity or calcification or ambiguity. This situation warrants intentional subintimal wiring.²²⁾ The ideal method of intentional subintimal wiring from the retrograde side is knuckle wiring which should be followed by use of a large balloon intended for conventional reverse CART.

Shifting reverse controlled antegrade and retrograde tracking

In the shifting (extended) reverse CART technique the inflation of antegrade balloon is undertaken outside the CTO segment (either proximal or distal) and the intimal/subintimal dissection is shifted beyond the beyond the CTO segment (**Figure 8**). This is followed by navigation of retrograde guidewire through the connection created between the proximal true lumen and the retrograde intimal/subintimal space. It is critical to identify the ideal point with diffuse plaque and to determine an appropriate balloon size in order to create an intimal/subintimal dissection efficiently with antegrade balloon. This technique may be applied if there is failure of retrograde penetration of a calcified distal cap or if the retrograde microcatheter cannot pass severe calcification. In such scenarios, the antegrade guidewire can be placed in the subintimal space beyond the distal cap. This follows inflation of antegrade balloon and retrograde navigation of a high penetration into the dilated subintimal space. Shifting reverse CART technique is useful in cases where antegrade preparation or retrograde cap penetration is not possible and where there are no significant side branches close to the site of the reverse CART technique.¹²⁾

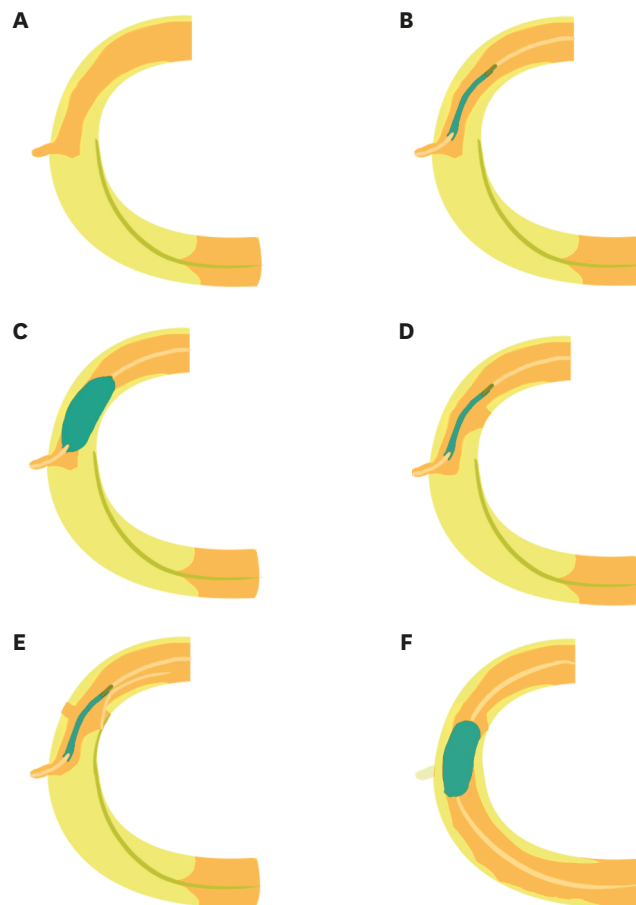


Figure 8. Schematic illustration of shifting reverse CART. (A) Navigation of a retrograde guidewire into the subintimal space in a case of mid RCA CTO with a small side branch around the proximal cap. (B) Negotiation of an antegrade balloon to the planned connecting point. (C) Inflation of the antegrade balloon in an attempt to create a medial dissection. (D) Creation of a connection between the retrograde subintimal space and the proximal true lumen after balloon deflation. (E) Navigation of the retrograde guidewire into the proximal true lumen through the created connection. (F) Performance of the guidewire externalisation and balloon dilatation. CART = controlled antegrade and retrograde tracking; CTO = chronic total occlusion; RCA = right coronary artery.

CONCLUSION

The reverse CART technique has evolved significantly over time with the tremendous improvement in technology and techniques. The contemporary reverse CART is the most frequently used technique and can be used as primary retrograde approach or an alternative to an unsuccessful antegrade approach. Though the efficiency of this technique is anticipated to be superior to that of the conventional reverse CART technique, but future studies are required to validate this strategy. The proposed iteration of the current reverse CART techniques will go a long way to help the interventionists to appropriately adopt wire crossing strategies and also facilitate communication and teaching of the reverse CART techniques. Although, the sub-types of reverse CART are likely to achieve the goal of more open arteries worldwide, prospective validation of the usefulness and the clinical impact of the proposed techniques are required.

REFERENCES

1. Karpaliotis D, Michael TT, Brilakis ES, et al. Retrograde coronary chronic total occlusion revascularization: procedural and in-hospital outcomes from a multicenter registry in the United States. *JACC Cardiovasc Interv* 2012;5:1273-9.
[PUBMED](#) | [CROSSREF](#)
2. Brilakis ES, Grantham JA, Thompson CA, et al. The retrograde approach to coronary artery chronic total occlusions: a practical approach. *Catheter Cardiovasc Interv* 2012;79:3-19.
[PUBMED](#) | [CROSSREF](#)
3. Dash D. Deja Vu of retrograde recanalization of coronary chronic total occlusion: A tale of a journey from Japan to India. *Indian Heart J* 2016;68:584-5.
[PUBMED](#) | [CROSSREF](#)
4. Dash D. Retrograde coronary chronic total occlusion intervention using a novel reverse controlled antegrade and retrograde subintimal tracking. *J Interv Cardiol* 2016;29:70-4.
[PUBMED](#) | [CROSSREF](#)
5. Hoye A, van Domburg RT, Sonnenschein K, Serruys PW. Percutaneous coronary intervention for chronic total occlusions: the Thoraxcenter experience 1992–2002. *Eur Heart J* 2005;26:2630-6.
[PUBMED](#) | [CROSSREF](#)
6. Ruocco NA Jr, Ring ME, Holubkov R, Jacobs AK, Detre KM, Faxon DP. Results of coronary angioplasty of chronic total occlusions (the National Heart, Lung, and Blood Institute 1985–1986 Percutaneous Transluminal Angioplasty Registry). *Am J Cardiol* 1992;69:69-76.
[PUBMED](#) | [CROSSREF](#)
7. Surmely JF, Tsuchikane E, Katoh O, et al. New concept for CTO recanalization using controlled antegrade and retrograde subintimal tracking: the CART technique. *J Invasive Cardiol* 2006;18:334-8.
[PUBMED](#)
8. Dash D. A step-by-step guide to mastering retrograde coronary chronic total occlusion intervention in 2018: the author's perspective. *Indian Heart J* 2018;70 Suppl 3:S446-55.
[PUBMED](#) | [CROSSREF](#)
9. Dash D. Retrograde coronary total occlusion intervention. *Curr Cardiol Rev* 2015;11:291-8.
[PUBMED](#) | [CROSSREF](#)
10. Nguyen TN, Hu D, Chen SL, et al. Practical Handbook of Advanced Interventional Cardiology. 4th ed. Chichester: Wiley-Blackwell; 2013.
11. Tsuchikane E, Katoh O, Kimura M, Nasu K, Kinoshita Y, Suzuki T. The first clinical experience with a novel catheter for collateral channel tracking in retrograde approach for chronic coronary total occlusions. *JACC Cardiovasc Interv* 2010;3:165-71.
[PUBMED](#) | [CROSSREF](#)
12. Matsuno S, Tsuchikane E, Harding SA, et al. Overview and proposed terminology for the reverse controlled antegrade and retrograde tracking (reverse CART) techniques. *EuroIntervention* 2018;14:94-101.
[PUBMED](#) | [CROSSREF](#)

13. Dash D, Li L. Intravascular ultrasound guided percutaneous coronary intervention for chronic total occlusion. *Curr Cardiol Rev* 2015;11:323-317.
[PUBMED](#) | [CROSSREF](#)
14. Rathore S, Katoh O, Tuschikane E, Oida A, Suzuki T, Takase S. A novel modification of the retrograde approach for the recanalization of chronic total occlusion of the coronary arteries intravascular ultrasound-guided reverse controlled antegrade and retrograde tracking. *JACC Cardiovasc Interv* 2010;3:155-64.
[PUBMED](#) | [CROSSREF](#)
15. Dash D. Guidewire crossing techniques in coronary chronic total occlusion intervention: A to Z. *Indian Heart J* 2016;68:410-20.
[PUBMED](#) | [CROSSREF](#)
16. Fung R, Wu EB, Jim MH. Dislodged stent after stent reverse controlled antegrade and retrograde subintimal tracking (CART) - Is stent reverse CART a necessary tool or an unnecessary evil? *J Cardiol Cases* 2017;16:205-9.
[PUBMED](#) | [CROSSREF](#)
17. Dash D. Reverse controlled antegrade and retrograde subintimal tracking for chronic total occlusion intervention: my approach in 2017. *SL Clin Exp Cardiol* 2017;1:111.
18. Wu EB, Chan WW, Yu CM. Antegrade balloon transit of retrograde wire to bail out dissected left main during retrograde chronic total occlusion intervention--a variant of the reverse CART technique. *J Invasive Cardiol* 2009;21:e113-8.
[PUBMED](#)
19. Kim U, Seol SH, Kim DI, et al. Clinical outcomes and the risk factors of coronary artery aneurysms that developed after drug-eluting stent implantation. *Circ J* 2011;75:861-7.
[PUBMED](#) | [CROSSREF](#)
20. Hasegawa K, Tsuchikane E, Okamura A, et al. Incidence and impact on midterm outcome of intimal versus subintimal tracking with both antegrade and retrograde approaches in patients with successful recanalisation of chronic total occlusions: J-PROCTOR 2 study. *EuroIntervention* 2017;12:e1868-73.
[PUBMED](#) | [CROSSREF](#)
21. Dash D. "Putting it all together": a global approach to chronic total occlusion revascularization. *J Indian Coll Cardiol* 2016;6:152-7.
[CROSSREF](#)
22. Wu BE, Tsuchikane E, Lo S, et al. Retrograde algorithm for chronic total occlusion from the Asia Pacific Chronic Total Occlusion Club. *Asian Interv* 2018;4:98-107.