

Assessment of visual evoked potentials in patients eligible for penetrating keratoplasty

Wojciech Mańkowski, MD^{a,*}, Adam Wylęgała, MD, PhD^b, Edward Wylęgała, MD, PhD^{a,b}

Abstract

Corneal opacities can obstruct ophthalmology examination in patients before penetrating keratoplasty (PK).

To assess the usefulness of visual evoked potentials (VEPs) in estimating postoperative visual acuity (VA) in patients eligible for (PK) with opaque cornea in 1 eye and good VA in the fellow eye.

In this observational study, the mean age of 52 males and 48 females was 57.17 ± 15.99 (21–87 years old). A total of 100 patients eligible for PK underwent an ophthalmological examination including VA and a VEP examination. The P2/P2 ratio was calculated. The correlation coefficient of the VA and the P2/P2 ratio was evaluated 1, 6, and 12 months after PK.

A positive correlation of the P2/P2 ratio and VA 1, 6, and 12 months after PK were observed.

VEPs including the P2/P2 ratio can be useful in estimating postoperative VA in patients eligible for PK.

Abbreviations: PK = penetrating keratoplasty, VA = visual acuity, VEP = visual evoked potential.

Keywords: assessment keratoplasty, BCVA, PK, VEP

1. Introduction

Visual evoked potentials (VEPs) are used to assess the visual pathways through the eyes, optic nerves, and brain. VEPs are noninvasive studies that measure the electrophysiological responses of the optical cortex to different sensory stimuli. The visual field can be stimulated with a checkboard pattern (pattern-reversal VEP, pattern onset/offset VEP) or a white light flash (flash VEP) and the response is recorded using surface electrodes attached to the skin over the occipital lobe.^[1] Pattern-reversal VEP is the preferred stimulus in patients with good visual acuity (VA) because it has low variability of waveform and peak latency both within the subject and over the normal population. Flash VEP is preferred in patients with low VA.^[2] A white light flash can stimulate the retina even if the optical centers of the eye are not transparent. The most important phase is prominent positive deflection (P2). The peak amplitude of these waves is then measured.^[1]

Penetrating keratoplasty (PK) is the 2nd most common tissue transplant performed in both Europe and the United States. Visual reasons are indications for 91% of PK. Regrafts, keratoconus, Fuchs endothelial dystrophy, trauma, and infectious keratitis are the most frequent indications.^[3]

PK is a very expensive procedure and proper qualification for the surgery is very important. Many patients have an unknown medical history and a physical examination is difficult due to an opaque cornea. Ultrasonography of the eye is useful to assess the vitreous and the retina but shows no information about the function of the visual.^[4–6] The aim of this paper is to assess the usefulness of pre-PK VEP examination in eyes with unknown medical history and fully opaque cornea.

VEP records in the fellow eye with good VA were used as a reference.

2. Materials and methods

The study was conducted on 100 patients of the Ophthalmology Clinic, Medical University of Silesia, Railway Hospital Katowice in Poland who had been admitted for PK in an age group of 21 to 87 years old, which consisted of 52 males and 48 females. The study was conducted between 2014 and 2016 after the approval of the Ethics Committee of the Medical University of Silesia. The procedure of the study was explained to all of the subjects who provided informed written consent. Patients with medical indications for PK, opaque cornea, and an unknown medical history regarding treated eye were enrolled in the study. Patients under 18 years of age, pregnant women, patients with photosensitive epilepsy, any changes to the skin in the occipital region, and with no fellow eye or bad VA in the fellow eye were excluded from the study.

Only patients with best corrected VA of 85 letters (mean 94.83 ± 5.54) or higher in contralateral eye were included in the study.

The ophthalmological examination including VA with Early Treatment Diabetic Retinopathy Study charts with the best correction and a slit lamp examination was performed before PK and 1, 6, and 12 months after surgery.

Editor: Alparslan Şahin.

Ethical Approval: Approval for the study was obtained from the Ethics Committee of the Medical University of Silesia.

The authors have no funding and conflicts to interest to disclose.

^a Department of Ophthalmology, District Railway Hospital Katowice, ^b II School of Medicine with the Division of Dentistry in Zabrze, Medical University of Silesia, Katowice, Poland.

* Correspondence: Wojciech Mańkowski, Department of Ophthalmology, District Railway Hospital Katowice, Panewnicka 65, 40765 Katowice, Poland (e-mail: wrman.dr@gmail.com).

Copyright © 2018 the Author(s). Published by Wolters Kluwer Health, Inc. This is an open access article distributed under the terms of the Creative Commons Attribution-Non Commercial-No Derivatives License 4.0 (CCBY-NC-ND), where it is permissible to download and share the work provided it is properly cited. The work cannot be changed in any way or used commercially without permission from the journal.

Medicine (2018) 97:9(e9861)

Received: 26 October 2017 / Received in final form: 29 December 2017 /

Accepted: 23 January 2018

<http://dx.doi.org/10.1097/MD.0000000000009861>

Table 1
Characteristic of the study group.

Age, y	Standard deviation	Minimum	Maximum	Gender	
				Males	Females
57.17	15.99	21	87	52	48

Table 2
Visual acuity before, then 1, 6, and 12 mo after penetrating keratoplasty (PK), *t* test study versus control group.

	Mean visual acuity			<i>P</i>
	Letters	Snellen acuity equivalent	Standard deviation (letters)	
Before PK	26.99	20/80	14.37	<.05
1 mo after PK	40.05	20/40	18.93	<.05
6 mo after PK	44.88	20/32	19.02	<.05
12 mo after PK	50.27	20/25	18.97	<.05

The VEP examination was done once, before PK with EP-1000 Multi-Electrophysiology, Tomey GmbH, Germany according to International Society for Clinical Electrophysiology of Vision standards.^[1] A one-channel montage was used to record the VEPs. Silver cup scalp electrodes were placed according to the International 10/20 system. An active electrode was placed at Oz, which is the highest point of the occiput, over the visual cortex. The reference and ground electrodes were put at Fz and Cz (vertex), respectively. The examination was done in a dark room with quiet surroundings. Monocular stimulation was done with a white light flash. Electrode

Table 3
Mean P2 amplitudes in both eyes and mean P2/P2 ratio.

Mean P2 amplitude in the study eye ± SD, μV	Mean P2 amplitude in the fellow-eye ± SD, μV	Mean P2/P2 ratio ± SD
9.70 ± 4.50	13.67 ± 4.84	0.72 ± 0.25

SD = standard deviation.

impedance was kept at less than 5 kΩ. The amplitude of the P2 wave in both eyes was recorded. The P2/P2 ratio, defined as the ratio of the amplitude of the P2 wave in the eye selected for transplantation to the amplitude of the P2 wave in the fellow eye, was evaluated. Statistica version 10 software, Statsoft, was used for statistical analysis. The correlation coefficient of the VA and the P2/P2 ratio was evaluated 1, 6, and 12 months after PK. Student *t* test was used to compare the results in the groups and *P*-values were obtained.

3. Results

The main characteristic of the study group was shown in Table 1.

The mean VA before PK was 26.99 ± 14.37 (*P* < .05) letters. One month after PK the mean VA increased significantly to 40.05 ± 18.93 (*P* < .05) letters. Six and 12 months after surgery the VA was, respectively, 44.88 ± 19.02 (*P* < .05) and 50.27 ± 18.97 (*P* < .05) letters (Table 2).

A statistically significant increase in VA was observed in all of the time points (Fig. 1).

The mean P2 amplitude in the study, fellow eye, and P2/P2 ratio is shown in Table 3. There was no statistically significant difference between the eyes (*P* = .47).

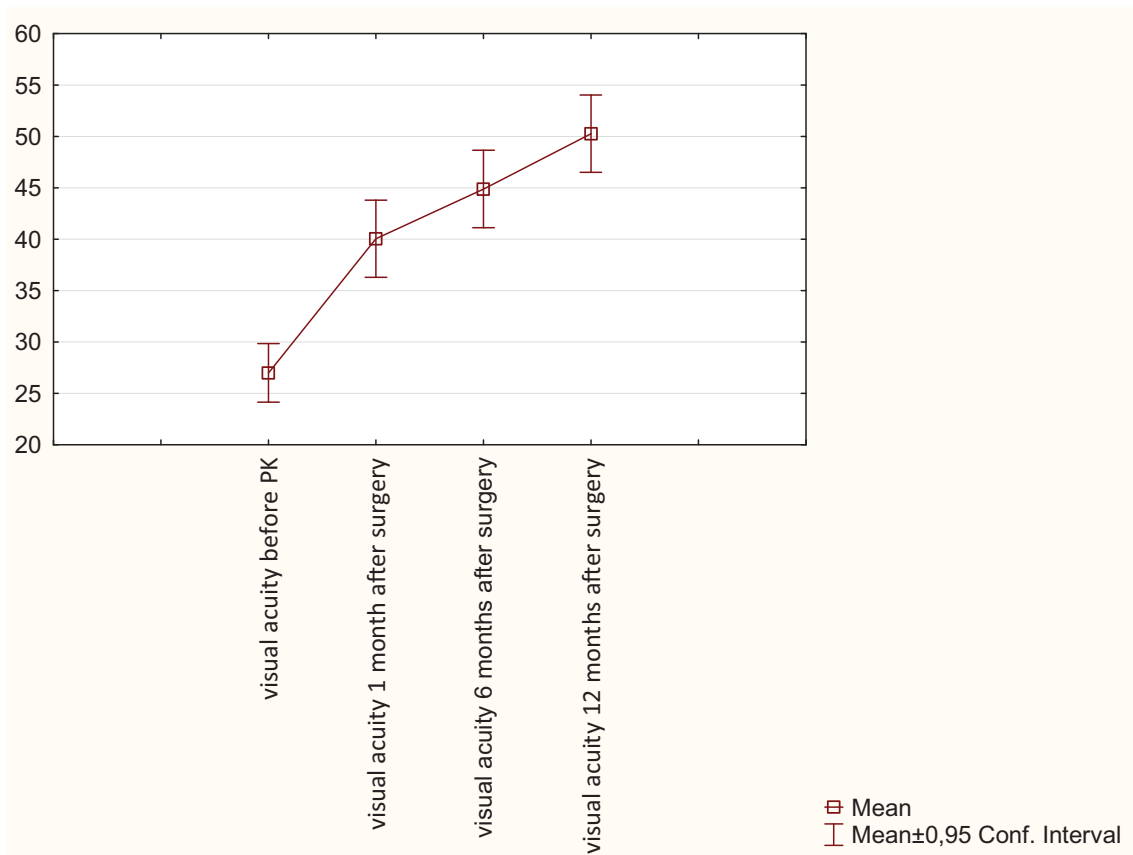


Figure 1. Visual acuity in all time points.

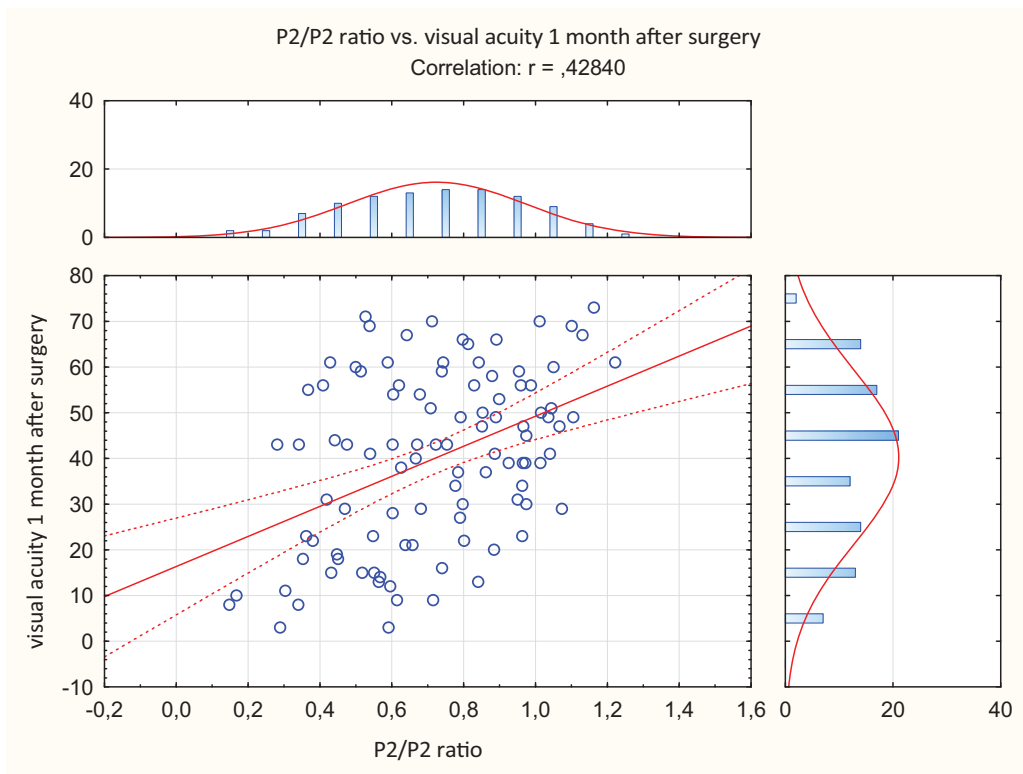


Figure 2. P2/P2 ratio versus visual acuity 1 month after surgery.

The correlation coefficient of VA 1 month after PK and the P2/P2 ratio was $r=0.43$ (0.95 CI), after 6 months it was $r=0.49$ (0.95 CI), and 12 months after surgery it was $r=0.57$ (0.95 CI)

(Figs. 2–4). There is a positive correlation between the P2/P2 ratio in all of the time points, particularly 12 months after PK. VA can be estimated based on the correlation equation (Table 4).

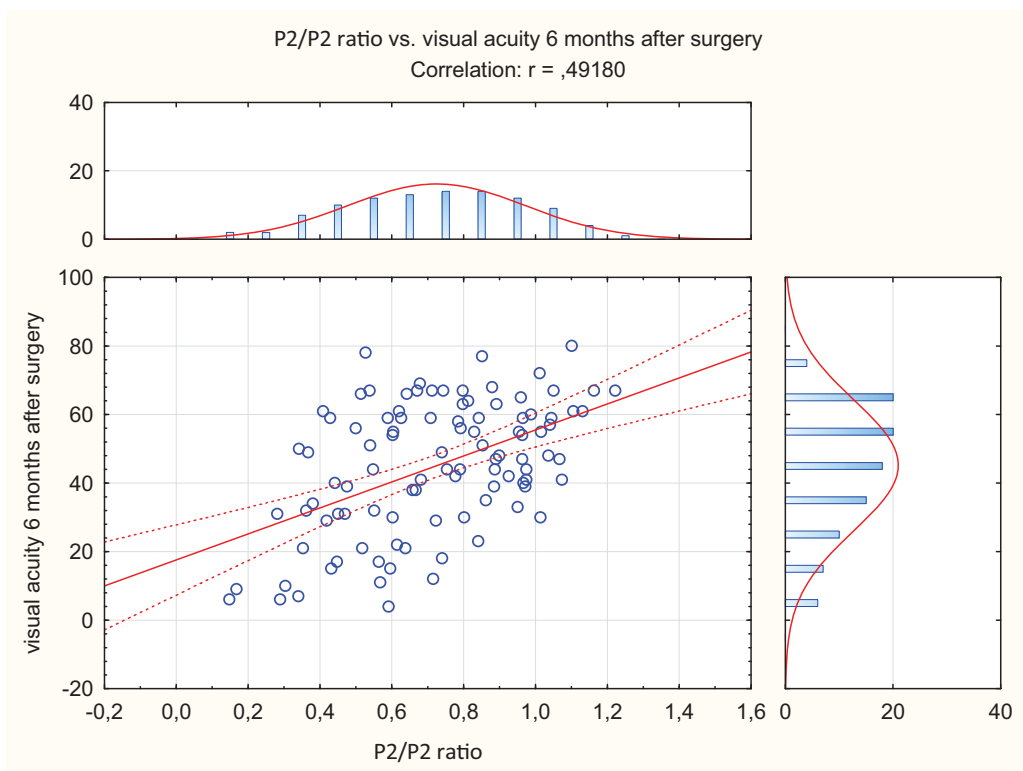


Figure 3. P2/P2 ratio versus visual acuity 6 months after surgery.

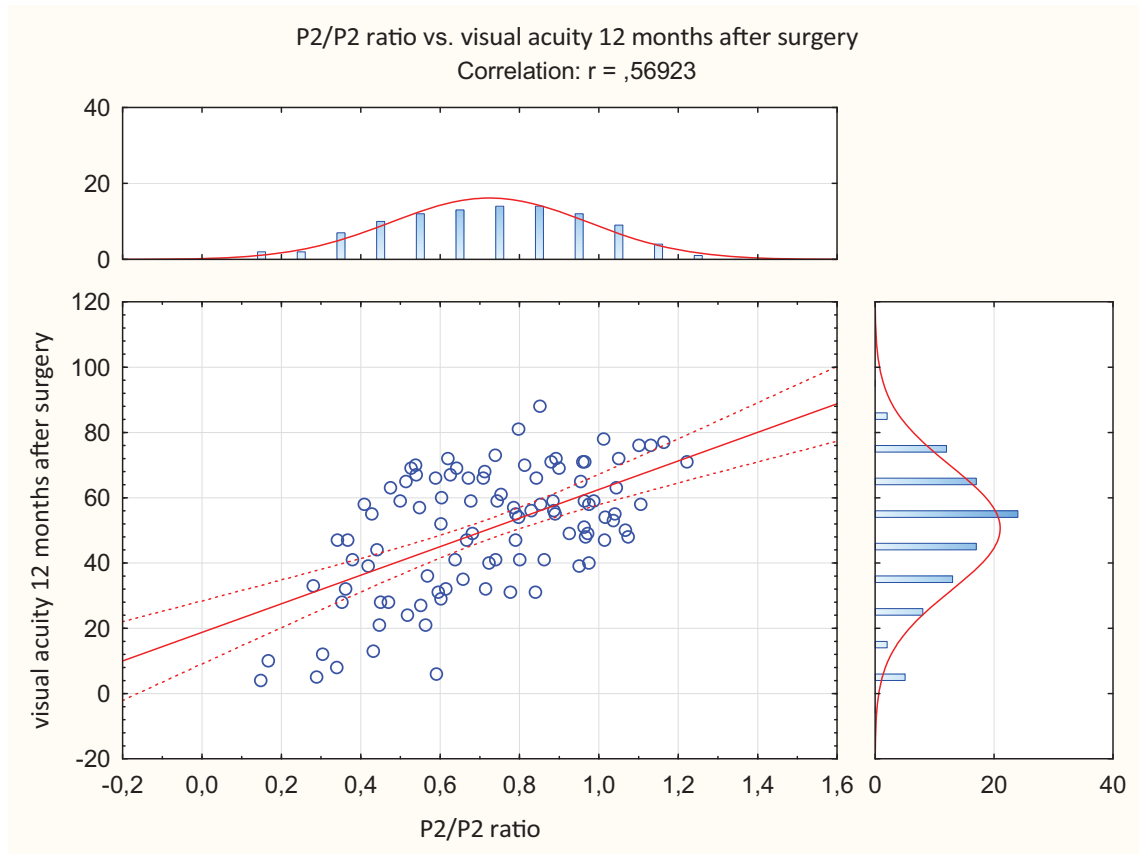


Figure 4. P2/P2 ratio versus visual acuity 12 months after surgery.

4. Discussion

The main indications for PK are keratoconus, re-grafts, Fuchs corneal dystrophy, corneal scarring including adherent leucoma, and cases of infectious keratitis.^[3,7,8] Good qualification for PK is required due to high costs and difficulty in obtaining tissue for the transplant. However, corneal opacity might obstruct visualization of the dilated fundus as well as Optical Coherence Tomography examination. Ultrasounds may only provide general information about the state of the retina and optic nerve. Many patients have an unknown ocular history and some may not benefit from the surgery, for example, patients with optic nerve atrophy^[9] or extensive macular atrophy,^[10] and should be excluded from PK. VEP test was considered to be the only objective visual examination currently available in ophthalmology.^[11] Furthermore, flash VEP is the only objective examination in patients with low VA.^[12] Several reports in the literature on the use of electrophysiological studies before PK had conclusions that were contradictory.^[13–15] Wendel et al^[13] advocated the use of VEP before the PK, due to high level of postoperative VA correlation. In their inspirational study Binder et al^[14] compared VEP prior to keratoplasty, the predictor value of postoperative

VA was 58% till 76% depending on the group. Thungtong et al^[15] showed that both P2 amplitude and a-wave have a good visual prognostic value in patients' who underwent PK. The authors compared results to the fellow healthy eye.^[15] All of the studies consisted of small groups of less than 40 participants.

One of the limitations of our article is the inherently high standard deviation of flash VEPs; however, the numerical data from 1 eye were always adjusted with the values from the healthy eye. Another limitation is that we did not have medical history of the patients who were examined.

In our study, we assumed that a comparison of VEP in an eye with opaque cornea and a fellow eye with good VA could be helpful in estimating the benefits from PK. During the qualification for PK, patients had an ophthalmological examination including flash VEP and a calculated P2/P2 ratio. We can use the correlation equation to estimate postoperative VA (Table 4).

5. Conclusion

A flash VEP examination is useful in estimating postoperative VA in patients eligible for PK. There is a strong positive correlation between the P2/P2 ratio before PK and VA after surgery. The correlation equations may be used to calculate postoperative VA.

Table 4

Correlation equation in all time points.

1 mo after PK	$VA = 17.576 + 37.925 * P2/P2 \text{ ratio}$
6 mo after PK	$VA = 16.380 + 32.878 * P2/P2 \text{ ratio}$
12 mo after PK	$VA = 18.749 + 43.782 * P2/P2 \text{ ratio}$

PK=penetrating keratoplasty, VA=visual acuity.

References

- [1] Odom JV, Bach M, Brigell M, et al. ISCEV standard for clinical visual evoked potentials: (2016 update). *Doc Ophthalmol* 2016;133:1–9.
- [2] Odom JV, Bach M, Barber C, et al. Visual evoked potentials standard (2004). *Doc Ophthalmol* 2004;108:115–23.

- [3] Matthaei M, Sandhaeger H, Hermel M, et al. Changing indications in penetrating keratoplasty. *Transplantation* 2017;101:1387–99.
- [4] Vrablik ME, Snead GR, Minnigan HJ, et al. The diagnostic accuracy of bedside ocular ultrasonography for the diagnosis of retinal detachment: a systematic review and meta-analysis. *Ann Emerg Med* 2015;65:199–203e1.
- [5] Agarwal A, Fan S, Invernizzi A, et al. Characterization of retinal structure and diagnosis of peripheral acquired retinoschisis using high-resolution ultrasound B-scan. *Graefe's Arch Clin Exp Ophthalmol* 2016;254:69–75.
- [6] Parchand S, Singh R, Bhalekar S. Reliability of ocular ultrasonography findings for pre-surgical evaluation in various vitreo-retinal disorders. *Semin Ophthalmol* 2014;29:236–41.
- [7] Dasar L, Pujar C, Gill KS, et al. Indications of penetrating keratoplasty in southern India. *J Clin Diagn Res* 2013;7:2505–7.
- [8] Raj A, Gupta N, Dhasmana R, et al. Indications and visual outcome of penetrating keratoplasty in Tertiary Eye Care Institute in Uttarakhand. *J Clin Diagn Res* 2016;10:NC01–4.
- [9] Brooks AM, Cairns JD. Contusion injuries of the optic nerve. *Aust N Z J Ophthalmol* 1986;14:269–73.
- [10] Hamdi HK, Kenney C. Age-related macular degeneration: a new viewpoint. *Front Biosci* 2003;8:e305–14.
- [11] Sarnthein J, Andersson M, Zimmermann MB, et al. High test-retest reliability of checkerboard reversal visual evoked potentials (VEP) over 8 months. *Clin Neurophysiol* 2009;120:1835–40.
- [12] Contestabile MT, Recupero SM, Palladino D, et al. A new method of biofeedback in the management of low vision. *Eye* 2002;16:472–80.
- [13] Wendel RT, Mannis MJ, Keltner JL. Role of electrophysiologic testing in the preoperative evaluation of corneal transplant patients. *Ann Ophthalmol* 1984;16:788–93.
- [14] Binder PS, Ayazuddin M, Hintze R. Visual prognosis for corneal transplantation based on preoperative visual evoked potential and electroretinogram. *Ophthalmology* 1982;89:661–7.
- [15] Thuangtong A, Samsen P, Ruangvaravate N. Visual prognostic value of ocular electrophysiology tests in corneal transplantation. *J Med Assoc Thai* 2012;95(Suppl 4):S50–5.