



Case report

Incidental finding of metastatic prostatic adenocarcinoma of cerebellopontine angle presenting as acoustic neuroma: A case report and review of literature

Qing-Fang Ma^{a,1}, Chun-Ying Ou^{b,1}, Qi-Hong Wang^a, Yong-Nan Wang^{a,*}

^a Department of Neurosurgery, Xu Zhou Central Hospital, Xuzhou Clinical School of Xuzhou Medical University, Xuzhou, China

^b Department of Neurology, Xu Zhou Central Hospital, Xuzhou Clinical School of Xuzhou Medical University, Xuzhou, China

ARTICLE INFO

Keywords:

Metastatic prostate carcinoma
Cerebellopontine angle
Cranial nerve deficits
Prostate specific antigen ; case report

ABSTRACT

Introduction: Brain metastases from carcinoma of prostate are rare and only few cases with brain metastases preceding the diagnosis of carcinoma of prostate have been reported in the literature. Lesions of brain metastasis from prostate cancer had a large variety of imaging presentations and it is very difficult to distinguish them from the other types of brain occupying lesions. We report one case of metastatic prostatic adenocarcinoma of cerebellopontine angle presenting as acoustic neuroma, as the first clinical evidence of metastatic carcinoma of the prostate.

Presentation of case: The 57-year-old male presented to the neurology clinic complaining of dizziness accompanied by right tinnitus, he was proposed to be diagnosed with acoustic neuroma, and the tumor resection was performed later in our neurosurgery department. The postoperative histopathological and immunohistochemical (IHC) examinations revealed a cerebellar pontine angle metastatic adenocarcinoma, which was then confirmed as prostate cancer metastasis. The patient refused surgical castration and only agreed to conservative treatment. The patient's condition continued to deteriorate, and he died 12 months after the initial presentation.

Discussion: Brain metastasis is rare in prostate cancer, which accounts for only 0.2 % to 2 % of all brain metastases. Intracranial metastasis as the first clinical symptom of prostate cancer is extremely rare. In our article, we report the VIIIth and VIIth cranial nerves palsy for the first time, caused by brain metastases from prostate cancer, with symptoms similar to an acoustic neuroma. Prostate cancer most commonly spreads to the bones, including the skull, Cranial nerve palsy is caused by extensive invasion of the skull base. The serum PSA level is considered the most valuable tool to monitor the disease progression of patients with prostate cancer metastasis. A high PSA level significantly increases the tendency of prostate cancer to metastasize to the brain. A high Gleason score is believed to help determine the risk and likelihood of brain metastases in patients with prostatic carcinoma.

Conclusion: In our case, we initially report the VIIIth and VIIth cranial nerve palsy, mimicking an acoustic neuroma, caused by metastatic prostate carcinoma. For early diagnosis, the prostate should not be neglected as a possible source of the metastases in male patients presenting with brain metastases. High prostate specific antigen (PSA) level and high Gleason score can be useful parameters for the prediction of brain metastasis from prostate cancer. The PSA should play a vital role in distinguishing metastatic prostate carcinoma in male patients.

1. Introduction

Brain metastases are the most common cause of intracranial tumors in adults. As many as 30 % of cancer patients develop intracranial

metastases during their lifetime, and the 2-year survival rate of cancer patients with brain metastases is <10 % [1]. Brain metastases arising from lung cancer, breast cancer, and melanoma are common and well-studied. However, brain metastases from prostate cancer are rare and

* Corresponding author at: Department of Neurosurgery, Xu Zhou Central Hospital, Xuzhou Clinical School of Xuzhou Medical University, Xuzhou 221009, China.
E-mail address: hnwang_2010@126.com (Y.-N. Wang).

¹ Qing-Fang Ma, MD, and Chun-Ying Ou, MD are the co-first author.

<https://doi.org/10.1016/j.ijscr.2022.107493>

Received 4 July 2022; Received in revised form 31 July 2022; Accepted 6 August 2022

Available online 9 August 2022

2210-2612/© 2022 The Authors. Published by Elsevier Ltd on behalf of IJS Publishing Group Ltd. This is an open access article under the CC BY-NC-ND license (<http://creativecommons.org/licenses/by-nc-nd/4.0/>).

reports of brain metastases symptoms precede the diagnosis of prostate cancer are even rarer. Moreover, there are many different imaging manifestations of brain metastases from prostate cancer, so it is difficult to differentiate it from other intracranial space-occupying lesions [2]. In the present article, we report a case of metastatic prostate cancer of cerebellopontine angle presenting with clinical symptoms of acoustic neuroma, as the first clinical evidence of metastatic carcinoma of the prostate.

This case report was prepared in accordance with the SCARE guidelines [3].

2. Presentation of case

A 57-year-old male presented to the neurology clinic complaining of dizziness accompanied by right tinnitus for 1 month and right facial paralysis for 20 days, he was then admitted to Xu Zhou Central Hospital for further examination and treatment on June 13th, 2020. The patient denied a history of chronic diseases and had no history of genitourinary diseases. He then underwent a series of examinations. Magnetic resonance imaging (MRI) of the brain demonstrated a mass in the right cerebellopontine angle (which was enhanced with intravenous contrast) (Fig. 1). A hearing examination revealed neuropathic hearing impairment. The patient was proposed to be diagnosed with acoustic neuroma, and on June 16th, 2020, we performed the resection of the cerebellopontine angle tumor via the right suboccipital retrosigmoid approach under general anesthesia. Surprisingly, the postoperative histopathological and immunohistochemical (IHC) examinations (P40-, CK5/6-, CK7-, NapA-, TTF-1-, Ki67 + 30 %, P504S+, PSA+, PAP+) revealed a cerebellar pontine angle metastatic adenocarcinoma, which was highly considered prostate cancer metastasis (Fig. 2A). Soon after, the diagnosis was confirmed by further examination. Tumor-associated antigen test showed that the free prostate specific antigen (FPSA) was 6.830 ng/ml. Prostate MRI showed abnormal signals in the bilateral and peripheral lobes of the prostate, suggesting a possibility of prostate cancer (Fig. 3). Needle biopsy of the prostate showed focal poorly differentiated adenocarcinoma, the Gleason score was 8 (3 + 5) (Fig. 2B). Widespread bone metastases were detected by Emission Computed Tomography (ECT) (Fig. 4). Due to poor prognosis and financial reasons, the patient refused surgical castration and only agreed to conservative treatment with leuprorelin acetate (3.75 mg/time, once every four weeks, subcutaneous injection), prednisolone (5 mg/time, twice a day, orally), abiraterone acetate (1000 mg/time, once a day,

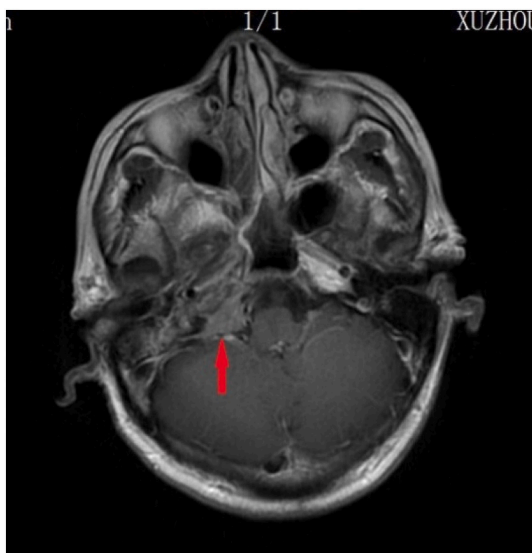

Fig. 1. Brain MRI demonstrating an enhanced mass lesion in the right cerebellopontine angle.

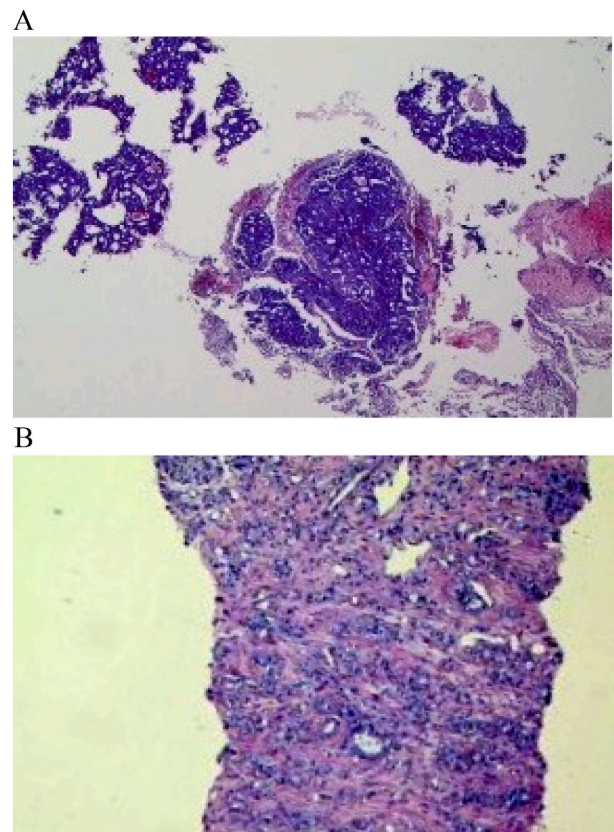


Fig. 2. A. Pathological findings of the cerebellar pontine angle metastatic adenocarcinoma (hematoxylin and eosin, original magnification 100 \times). B. Pathological findings of the primary prostate lesion, showing focal poorly differentiated adenocarcinoma. (Hematoxylin and eosin, original magnification 100 \times).

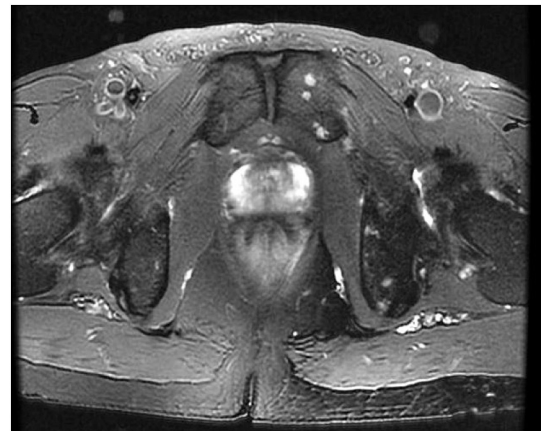

Fig. 3. Prostate MRI showing abnormal signals in the bilateral and peripheral lobes of the prostate, suggesting a possibility of prostate cancer.

orally), and zoledronic acid (4 mg/time, once every four weeks, intravenous infusion). The patient's condition continued to deteriorate, and he died 12 months after the initial presentation. An autopsy was not obtained.

3. Discussion

Brain metastasis is common in cancer patients, but unlike other types of cancer, Brain metastasis is rare in prostate cancer, which accounts for

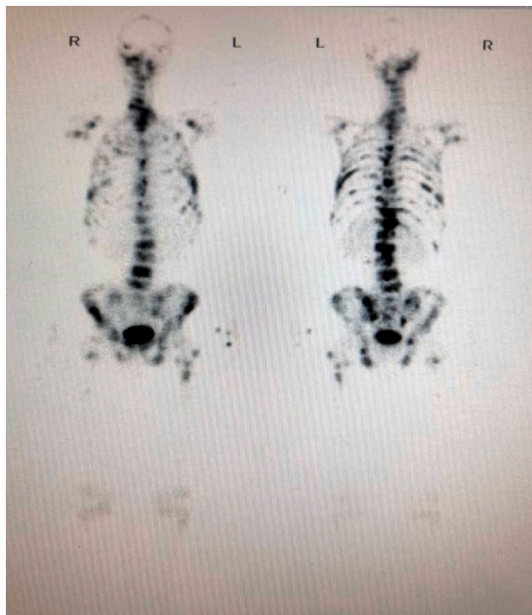

Fig. 4. Widespread bone metastases were detected by ECT.

only 0.2 % to 2 % of all brain metastases [1,4]. Intracranial metastasis as the first clinical symptom of prostate cancer is extremely rare. To our knowledge, this is the first report of a misdiagnosis of acoustic neuroma followed by confirmation of prostate cancer metastasis. The rarity of such reports may be related to the reason for the rare infratentorial metastasis of prostate cancer. A retrospective study of 31 prostate cancer patients with intracranial metastases from Stanford Medical Center found that 61 % had supratentorial metastases and only 10 % had infratentorial metastases [1]. Cranial nerve injury due to intracranial metastasis of prostate cancer is uncommon, but its clinical manifestations are significant. There are a number of reports about the symptoms of cranial nerve dysfunction caused by brain metastases of prostate cancer. The cranial nerves involved include IInd, IIIrd, IVth, Vth, VIth, VIIth, and XIIth [5], but there is no report of the VIIIth cranial nerve injury. In our article, we report the VIIIth and VIIth cranial nerves palsy for the first time, caused by brain metastases from prostate cancer, with symptoms similar to an acoustic neuroma.

It is believed that prostate cancer often metastasizes through blood or lymph nodes, but the exact mechanism of metastasis is not well understood. However, the following three mechanisms of brain metastasis are widely recognized [6]: the tumor embolism passes through a patent foramen ovale, thus bypassing the lung; Cancer cells enter the pulmonary capillaries, enter the left atrium, and then spread through the arterial blood; Secondary spreading from pulmonary metastasis. Prostate cancer most commonly spreads to the bones, including the pelvis, vertebra, ribs, femur, and skull [7]. Cranial nerve palsy is caused by extensive invasion of the skull base [5]. Our patient had numerous bone metastases, including in the vertebral bodies, pelvic bones, and femur, especially in the skull bones. He, therefore, was at risk for skull base metastasis with petrosal osseous involvement.

In the present case, the patient initially presented with tinnitus and facial paralysis, which is similar to an acoustic neuroma. His follow-up examination revealed a cerebellopontine angle space-occupying lesion, which was confirmed to originate from a brain metastasis of prostate cancer. The patient's diagnosis and treatment process give us several suggestions or lessons. First, as reported by Smedby Ke et al. [8] prostate cancer is the fourth most common primary malignancy in men with brain metastases, and the prostate should not be overlooked as a possible source of metastasis in men with brain metastases without a known primary site. Secondly, a comprehensive record of the previous medical

history is the basis for improving the clinical and radiographic treatment of those challenging cases. Thirdly, the PSA, as a sensitive indicator of the presence of prostate carcinoma, should have played a more important role in the differential diagnosis between metastatic prostate carcinoma and acoustic neuroma.

The serum PSA level is considered the most valuable tool to monitor the disease progression of patients with prostate cancer metastasis. It has been proved that a PSA rate > 4 ng/ml is a useful predictor [9]. A high PSA level significantly increases the tendency of prostate cancer to metastasize to the brain [10]. In the present case, an extremely high PSA level may indicate that the cerebellopontine angle lesion originated from prostate cancer.

A high Gleason score is believed to help determine the risk and likelihood of brain metastases in patients with prostatic carcinoma [2,11]. Kanyilmaz et al. [2] studied 339 patients with radiographically confirmed brain metastases from prostate cancer, 100 % of whom had a Gleason score of 7 or higher. The Gleason score of the present case is 8 points, higher than 7 points, which is consistent with previous reports.

In terms of treatment, the patient chose aggressive surgical resection of intracranial tumor, followed by endocrine therapy for prostate cancer, which is basically consistent with the previously reported treatment of brain metastases. Tal Grenader et al. [12] proposed that the treatment options for patients with brain metastases of prostate cancer should be a combination of local therapy (radiotherapy, surgery, and radiation) and hormonal ablation. Another article further proposed the treatment strategy of prostate brain metastasis [13], that is, surgical treatment for patients with a single and metastatic lesion that is easy to be removed and in good condition; Patients with 1–3 brain metastases that are difficult to remove and in good condition should be treated with radiotherapy; For >3 metastases that cannot be surgically resected, whole brain irradiation is performed.

4. Conclusion

In conclusion, intracranial metastasis as the first clinical symptom of prostate cancer is extremely rare. Cranial nerve injury due to intracranial metastasis of prostate cancer is uncommon, but its clinical manifestations are significant. In our case, we initially report the VIIIth and VIIth cranial nerve palsy, mimicking an acoustic neuroma, caused by metastatic prostate carcinoma. For early diagnosis, the prostate should not be overlooked as a possible source of metastasis in men with brain metastases. High PSA level and high Gleason score can be useful parameters for predicting the brain metastases of prostate cancer. The PSA should play a vital role in distinguishing metastatic prostate carcinoma in male patients. The treatment strategy for patients with brain metastases of prostate cancer should be a combination of radiotherapy, surgery, radiation, and hormonal ablation.

Sources of funding

This study did not receive any funding support.

Ethical approval

Not applicable.

Consent

Written informed consent was obtained from the patient next of kin for publication of this case report and accompanying images. A copy of the written consent is available for review by the Editor-in-Chief of this journal on request.

Author contribution

Qing-Fang Ma and Chun-Ying Ou contributed to the writing and

literature review.

Yong-Nan Wang: Wrote and edited the manuscript.

Qi-Hong Wang was the attending doctor for the patient and he helped edit the case report.

Qing-Fang Ma and Chun-Ying Ou are the co-first author.

Research registration

Not applicable.

Guarantor

Dr. Yong-Nan Wang.

Provenance and peer review

Not commissioned, externally peer-reviewed.

Declaration of competing interest

None.

References

- [1] H.P. Bhambhani, D.R. Greenberg, S. Srinivas, G.M. Hayden, Prostate cancer brain metastases: a single-institution experience, *World Neurosurg.* 138 (2020) 445–449.
- [2] G. Kanyilmaz, M. Aktan, B.B. Yavuz, M. Koç, Brain metastases from prostate cancer: a single-center experience, *Turk.J. Urol.* 45 (2019) 279–283.
- [3] R.A. Agha, T. Franchi, C. Sohrabi, G. Mathew, A. Kerwan, The SCARE 2020 guideline: updating consensus Surgical CAse REport (SCARE) guidelines, *Int. J. Surg.* 84 (2020) 226–230.
- [4] B.E. de Oliveira, D.C.N. Meireles, C.Y. Palmero, P.L. Ribeiro, L.E. Nasciutti, A. J. Palumbo, Malignant invasion of the central nervous system: the hidden face of a poorly understood outcome of prostate cancer, *World J. Urol.* 36 (2018) 2009–2019.
- [5] R.S. McDermott, P.R. Anderson, R.E. Greenberg, B.N. Milestone, G.R. Hudes, Cranial nerve deficits in patients with metastatic prostate carcinoma: clinical features and treatment outcomes, *Cancer-Am. Cancer Soc.* 101 (2004) 1639–1643.
- [6] M. Ganau, P. Gallinaro, H. Cebula, A. Scibilia, J. Todeschi, A. Gubian, B. Nannavecchia, F. Signorelli, R. Pop, H.A. Coca, F. Proust, S. Chibbaro, Intracranial metastases from prostate carcinoma: classification, management, and prognostication, *World Neurosurg.* 134 (2020) 559–565.
- [7] M. Sukumaran, Q. Mao, D.R. Cantrell, B.S. Jahromi, M.B. Potts, Holohemispheric prostate carcinoma dural metastasis mimicking subdural hematoma: case report and review of the literature, *J. Neurol. Surg. Rep.* 83 (2022) 23–28.
- [8] K.E. Smedby, L. Brandt, M.L. Bäcklund, P. Blomqvist, Brain metastases admissions in Sweden between 1987 and 2006, *Br. J. Cancer* 101 (2009) 1919–1924.
- [9] M. Ganau, M. Paris, N. Syrmos, L. Ganau, G. Ligarotti, A. Moghaddamjou, L. Prisco, R. Ambu, S. Chibbaro, How nanotechnology and biomedical engineering are supporting the identification of predictive biomarkers in neuro-oncology, *Medicines (Basel)* 5 (2018).
- [10] M. Movahed-Ezazi, K.A. Skalina, K. Parashar, S. Manjila, A. Vdovenko, C. Iannuzzi, R.W. Cartun, A rare presentation of low-grade prostate adenocarcinoma as delayed pineal region metastasis: a case report and review of multicenter clinical experience in prostate carcinoma brain metastases, *J. Neuropathol. Exp. Neurol.* 80 (2021) 1128–1133.
- [11] V. Hatzoglou, G.V. Patel, M.J. Morris, K. Curtis, Z. Zhang, W. Shi, J. Huse, M. Rosenblum, A.I. Holodny, R.J. Young, Brain metastases from prostate cancer: an 11-year analysis in the MRI era with emphasis on imaging characteristics, incidence, and prognosis, *J.Neuroimaging* 24 (2014) 161–166.
- [12] T. Grenader, L. Shavit, A. Lossos, G. Pizov, M. Wygoda, Brain metastases: a rare initial presentation of prostate cancer, *Int. Urol. Nephrol.* 39 (2007) 537–539.
- [13] G.J. Castro, H.U. Anido, C.A. Carballo, C.A. Gómez, M.L. León, V.C. Porto, L. R. López, Brain metastases from prostate adenocarcinoma, *Clin. Transl. Oncol.* 11 (2009) 63–64.