

# Implanting iodine-125 seeds into rat dorsal root ganglion for neuropathic pain: neuronal microdamage without impacting hind limb motion

Ling Jiao<sup>1</sup>, Tengda Zhang<sup>1</sup>, Huixing Wang<sup>2</sup>, Wenyi Zhang<sup>1</sup>, Saijun Fan<sup>1</sup>, Xiaodong Huo<sup>2</sup>, Baosen Zheng<sup>2</sup>, Wenting Ma<sup>2</sup>

<sup>1</sup> Institute of Radiation Medicine, Chinese Academy of Medical Sciences, Tianjin, China  
<sup>2</sup> Second Affiliated Hospital of Tianjin Medical University, Tianjin, China

Ling Jiao and Tengda Zhang contributed equally to this work.

**Corresponding author:**  
Wenting Ma, Second Affiliated Hospital of Tianjin Medical University, Tianjin 300211, China, md518880@163.com.

doi:10.4103/1673-5374.135326  
<http://www.nrronline.org/>

Accepted: 2014-04-22

## Abstract

The use of iodine-125 (<sup>125</sup>I) in cancer treatment has been shown to relieve patients' pain. Considering dorsal root ganglia are critical for neural transmission between the peripheral and central nervous systems, we assumed that <sup>125</sup>I could be implanted into rat dorsal root ganglia to provide relief for neuropathic pain. <sup>125</sup>I seeds with different radioactivity (0, 14.8, 29.6 MBq) were implanted separately through L<sub>4-5</sub> and L<sub>5-6</sub> intervertebral foramen into the vicinity of the L<sub>5</sub> dorsal root ganglion. von Frey hair results demonstrated the mechanical pain threshold was elevated after implanting <sup>125</sup>I seeds from the high radioactivity group. Transmission electron microscopy revealed that nuclear membrane shrinkage, nucleolar margination, widespread mitochondrial swelling, partial vacuolization, lysosome increase, and partial endoplasmic reticulum dilation were visible at 1,440 hours in the low radioactivity group and at 336 hours in the high radioactivity group. Abundant nuclear membrane shrinkage, partial fuzzy nuclear membrane and endoplasmic reticulum necrosis were observed at 1,440 hours in the high radioactivity group. No significant difference in combined behavioral scores was detected between preoperation and postoperation in the low and high radioactivity groups. These results suggested that the mechanical pain threshold was elevated after implanting <sup>125</sup>I seeds without influencing motor functions of the hind limb, although cell injury was present.

**Key Words:** nerve regeneration; iodine-125; analgesia; radioactive seeds; ultrastructure; pain threshold; dorsal root ganglion injury; neuropathic pain; neural regeneration

**Funding:** This project was supported by Technology Foundation for Selected Overseas Chinese Scholar, Ministry of Personnel of China, 2011, Ren1144.

Jiao L, Zhang TD, Wang HX, Zhang WY, Fan SJ, Huo XD, Zheng BS, Ma WT. Implanting iodine-125 seeds into rat dorsal root ganglion for neuropathic pain: neuronal microdamage without impacting hind limb motion. *Neural Regen Res.* 2014;9(12):1204-1209.

## Introduction

Is there an ideal therapy for intractable pain? Are physical methods better than chemical methods in some aspects of medical treatment? Intractable pain describes cancer pain, prosopalgia, postherpetic neuralgia, failed back surgery syndrome and neuropathic pain induced by unknown mechanisms that cannot be cured with current normal methods including the high-dose use of opioids. Pain is caused by a variety of factors, involving different mechanisms and stages. Furthermore, the treatment side effects of medicines will be different (Meuser et al., 2001; Rodrigues et al., 2006; Johnson et al., 2008).

Dorsal root ganglia, according to a description by Schaeffer et al. (2010), containing glial cells and somas of primary sensory neurons are critical for neural transmission between the peripheral and central nervous systems. It is well established that neuropeptides such as substance P and calcitonin gene-related peptide located in dorsal root ganglion neurons control sensory and pain mechanisms. Recently, research

regarding blocking dorsal root ganglion functions to treat neuropathic pain has increased. Wilkinson and Chan (2001) demonstrated the good efficacy of sensory ganglionectomy for treatment of refractory neuralgia, which offers theoretical advantages over rhizotomy, although the operation is invasive leading to severe complications and potential rejection by patients. Meanwhile, Chun-jing et al. (2012) demonstrated that dorsal root ganglion destruction by adriamycin for treatment of patients with postherpetic neuralgia could relieve pain, but did not demonstrate any long-term effects. However, adriamycin-induced cardiotoxicity and adriamycin-induced nephropathy in mice have been reported (Liu et al., 2013; Zhang et al., 2013). Based on previous studies, the current study explored further whether physical methods and radiation had the same effects on dorsal root ganglia for the relief of neuropathic pain.

Our study investigated (1) the effects of different radioactive seeds; (2) the relationship between changes in the effects of iodine-125 (<sup>125</sup>I) and time; (3) the ultrastructural changes

of neurons and nerve fibers; and (4) the pain threshold by paw withdrawal threshold.

Over the last decade, there have been no reports regarding dorsal root ganglion ultrastructure irradiated by radioactive  $^{125}\text{I}$ .

The aim of this study was to measure changes in the pain threshold, to record the ultrastructural changes of dorsal root ganglia, and to observe the effects of  $^{125}\text{I}$  on motor function. This information will aid our understanding of whether  $^{125}\text{I}$  can relieve pain safely and effectively.

## Materials and Methods

### Experimental animals

A total of 36 six-month-old male Sprague-Dawley rats, weighing 220–250 g were obtained from Tianjin Experimental Animal Center in China (license No. SCXK (Jin) 2010-0002). They were separately bred and kept at a controlled temperature of 25°C in a 12-hour light/dark cycle, and allowed free access to food and water. For acclimatization, the animals were delivered to the animal facility at least 1 week prior to the study. Approval for this study was obtained from the Peking Union Medical College & China Academy of Medical Science Biomedical Research Ethics Committee.

### Surgery of $^{125}\text{I}$ seed implantation

The rats were divided into a control group ( $n = 12$ ), low radioactivity group ( $n = 12$ ) and high radioactivity group ( $n = 12$ ). Three groups of rats were anesthetized using intraperitoneal injection of chloral hydrate (4 mL/kg) before surgery. When full anesthesia was achieved as assessed using tail pinch, each animal was placed in a ventral decubitus position and skin at the surgical site was shaved. A lateral incision at the  $L_5$  spinous process was made. The back muscles were separated and spinous processes and paravertebral muscles were exposed. Paravertebral soft tissue was stripped from the spinous processes on the operation side. The  $L_5$  transverse process and intervertebral foramen were exposed. According to the report of Chaplan et al. (1994), we chose the  $L_5$  dorsal root ganglia for implantation of radioactive seeds. Three groups of rats were implanted with two  $^{125}\text{I}$  seeds with different radioactivities (0, 14.8, 29.6 MBq) (Seeds Biological Pharmacy (Tianjin) Ltd., China) by surgery. Because the radioactivity of  $^{125}\text{I}$  commonly used in the clinic is 14.8 to 29.6 MBq, and the phenomena of damage was higher when the high radioactivity level was two-fold higher than the low radioactivity level, we administered either 14.8 MBq or 29.6 MBq radioactivities separately to  $L_{4,5}$  and  $L_{5,6}$  intervertebral foramen (provided by Seeds Biological Pharmacy (Tianjin) Ltd). The skin and muscles were then closed. The positions of  $^{125}\text{I}$  seeds were observed by GE Light Speed VCT (64-slice spiral CT; GE, New York, NY, USA). Rats whose internal seeds deviated from the  $L_5$  dorsal root ganglia by more than 1 cm or less than 0.5 cm were excluded from the study. After an intramuscular injection of 40,000–50,000 U penicillin to prevent infection, the rats were individually housed.

### Measurement of paw withdrawal threshold

According to the report of Chaplan et al. (1994), we measured paw withdrawal threshold at 24 hours prior to seed implantation and at 48, 168, 336, 720 and 1,440 hours after treatment, with a series of 8 von Frey hairs of logarithmically incremental stiffness (0.41, 0.70, 1.20, 2.04, 3.63, 5.50, 8.50, and 15.10 g). The von Frey hair was presented perpendicular to the plantar surface with sufficient force to cause slight buckling against the paw, and held for approximately 6–8 seconds. Stimuli were presented at intervals of several seconds, allowing for apparent resolution of any behavioral responses to previous stimuli. A positive response was noted if the paw was sharply withdrawn. Flinching immediately upon removal of the hair was also considered a positive response. Ambulation was considered an ambiguous response, and in such cases, the stimulus was repeated. Using this series of 8 von Frey hairs, we obtained a resulting pattern of positive and negative responses ( $X =$  withdrawal,  $0 =$  no withdrawal). According to this pattern, we found a parameter described in Chaplan's appendix. Using this parameter and the formula in his report, we could obtain the paw withdrawal threshold value.

### Behavior of hind limbs

In accordance with the combined behavior score (0–100 scores) reported by Babu et al. (2007), combined behavioral scores were assessed at 24 hours prior to seed implantation and at 48, 168, 336, 720 and 1,440 hours after implantation. A score of 100 represents complete paralysis. A higher score indicated a more severe injury. The animals traversed locomotor runways, narrow beam, incline plane, and grid runways, and were evaluated using the combined behavioral score system.

### Specimen collection and observation by electron microscopy

Two rats were chosen from each group at 336 and 1,440 hours, respectively after operation with intraperitoneal injection of 10% chloral hydrate (4 mL/kg). After anesthesia, rats were in the supine position and received heart perfusion *via* the left ventricular ascending aorta with 100 mL of normal saline and 100 mL of a fixative solution containing 4% paraformaldehyde. Twitching limbs indicated the solution had entered the brain. Then, the left  $L_5$  dorsal root ganglion was collected. The samples were fixed with 3% glutaraldehyde for 4 hours, washed with 0.1 mol/L PBS, pH 7.2, 4°C, for 10 minutes three times. A series of graded alcohol (30–100%, 4°C) was used to dehydrate the samples, which were then immersed in epoxy propane for 20 minutes twice, embedded in SPI-Pon 812, and then cut into slices with a LKB-V ultramicrotome. The sections were stained with uranyl acetate and lead citrate. Finally, all tissue samples were examined with a Philips EM400ST electron microscope (Philips, Amsterdam, the Netherlands), and the magnified images were captured.

### Estimation of the irradiation doses

The irradiation doses of the dorsal root ganglia were estimat-

ed, and the relationship between tissue change and doses was analyzed. According to the formula (1), the dose rate of  $^{125}\text{I}$  around the ganglion,  $\dot{D}(r, \theta)$ , could be calculated as follows.

$$\dot{D}(r, \theta) = S_k \cdot \Lambda \cdot \frac{G_L(r, \theta)}{G_L(r_0, \theta_0)} \cdot g_L(r) \cdot F(r, \theta) \quad (1)$$

Using this formula, the relative position of ganglion and seeds could be represented by  $P(r, \theta)$ , where  $r$  represents distance (cm) and  $\theta$  represents angle (degree).  $S_k$  is the air-kerma strength, the TG-43 report recommends  $S_k = 1.27 \text{ U}/37 \text{ MBq}$  ( $\text{U} = 1 \mu\text{Gy}\cdot\text{m}^2/\text{h}$  or  $1 \text{ cGy}\cdot\text{cm}^2/\text{h}$ );  $\Lambda$  is dose-rate constant in water and defined as the dose rate at  $P(r_0, \theta_0)$  ( $r_0 = 1.0 \text{ cm}$ ,  $\theta_0 = 90^\circ$ ) per unit  $S_k$ . In the report of Rivard et al. (2004), the  $6,711 \text{ }^{125}\text{I}$  recommended  $\Lambda$  is  $0.88 \text{ cGy}/\text{hU}$ .  $G_L(r, \theta)$  is a geometric function. Assuming radionuclide physical distribution is uniform in the seeds and can be regarded as line-source, then  $G_L(r, \theta) = \beta/Lr\sin\theta$ :  $L$  is the active length of source,  $\beta$  is the angle subtended by  $P(r, \theta)$  and the two ends of the  $L$  length.  $G_L(r_0, \theta_0)$  is the geometric function of  $P(r_0, \theta_0)$ .  $g_L(r)$ , radial dose function, according to the TG-43 report, is 1.04 and 1 when  $r$  is 0.5 and 1.0 cm respectively.  $F(r, \theta)$  represents 2D anisotropy function describing the ratio of dose rate at radius  $r$  and angle  $\theta$  around the source and equal a constant,  $\phi$ , independent of distance. According to the report of Rivard et al. (2004),  $\phi$  of  $6,711 \text{ }^{125}\text{I}$  was recommended as 0.93.

### Statistical analysis

SPSS 13.0 software (IBM, New York, NY, USA) was used to perform all statistical analyses. The measurement data of Gaussian distribution were shown as mean  $\pm$  SD. Analysis of variance of repeated measurement data was used for the comparison of measurement data among the three groups and between values from each group. A value of  $P < 0.05$  was considered statistically significant.

## Results

### Effect of implanting $^{125}\text{I}$ on paw withdrawal threshold

From pre-operation to 1,440 hours after treatment, there was no significant change in paw withdrawal threshold of rat hind limbs of the control group ( $P > 0.05$ ). The paw withdrawal threshold did not significantly decrease at 48 hours after implantation in the low radioactivity group and high radioactivity group compared with pre-operation and control group ( $P > 0.05$ ). The paw withdrawal threshold was lower in the low radioactivity group at 14 and 30 days compared with the control group ( $P < 0.05$ ). Paw withdrawal threshold returned to preoperative levels at 60 days in the low radioactivity group ( $P > 0.05$ ). The paw withdrawal threshold was diminished at 7 and 14 days ( $P < 0.05$ ), but significantly increased at 60 days ( $P < 0.05$ ) in the high radioactivity group as compared with pre-operation and control group (Table 1).

### Effect of implanting $^{125}\text{I}$ on hind limb motor function

The motor function of rats of all groups was normal before and after operation, and no significant difference in com-

bined behavioral score was observed ( $P > 0.05$ ). This result showed that the maximally radioactive seeds of 29.6 MBq implanted in  $L_{4-5}$  and  $L_{5-6}$  intervertebral foramen had no impact on rat motion function at 60 days after implantation (Table 2).

### Effect of implanting $^{125}\text{I}$ on ultrastructural changes of dorsal root ganglion cells

Electron microscopy indicated that nuclear membrane shrinkage, nucleolar margination, widespread mitochondrial swelling, partial vacuolization, lysosome increase, and partial endoplasmic reticulum dilation were observed at 1,440 hours in the low radioactivity group and at 336 hours in the high radioactivity group. Abundant nuclear membrane shrinkage, partial fuzzy nuclear membrane and endoplasmic reticulum necrosis were observed at 1,440 hours in the high radioactivity group (Figure 1).

### Dose estimation

Animals were implanted with two  $^{125}\text{I}$  seeds around the  $L_5$  dorsal root ganglia. Assuming they were implanted at the same time, according to the relative position  $P(r, \theta)$  between dorsal root ganglia and seeds, verified by CT after 24 hours, the irradiation doses and dose rate around the  $L_5$  dorsal root ganglia of two rats picked randomly from different groups at 336 and 1,440 hours were calculated (Table 3).

## Discussion

In recent years, imaging device-guided implantation of  $^{125}\text{I}$  seeds to treat tumors has cured various solid tumors with a wide use clinically (Lin et al., 2012a; Lin et al., 2012b; Huang et al., 2013). Some investigators (Zhongmin et al., 2010; Du et al., 2013) demonstrated the implantation of radioactive  $^{125}\text{I}$  seeds for treatment of pancreatic cancer could relieve cancer pain, and was safe, effective and simple. Wang et al. (2009, 2012) investigated celiac ganglion irradiation with  $^{125}\text{I}$  seeds in a porcine model and pancreatic cancer patients for pain control, and indicated that this method could reduce visual analogue scale scores and analgesic drug consumption. Furthermore, implanting  $^{125}\text{I}$  in celiac ganglia was safe and feasible. In contrast with the study by Wang et al., we investigated the implantation of  $^{125}\text{I}$  into the dorsal root ganglia because dorsal root ganglia are pivotal for neural transmission between the peripheral and central nervous systems. On the basis of the study by Wang et al., we investigated the paw withdrawal threshold and combined behavioral score of rats. We observed analgesia as the pain threshold increased after implanting  $^{125}\text{I}$  seeds without harming motor function. In 1993, Sheen and Chung (1993) found "cutting off"  $L_5$  and  $L_6$  dorsal root ganglia could relieve rats' pain after spinal nerve ligation. On the basis of these previous studies, we implanted  $^{125}\text{I}$  seeds into dorsal root ganglia of Sprague-Dawley rats directly, to investigate hind limb paw withdrawal threshold, combined behavioral score and ultrastructural changes of dorsal root ganglia.

Taschereau et al. (2002) clearly demonstrated the impact of radioactive  $^{125}\text{I}$  seeds in surrounding tissues at 336 hours.

**Table 1 Comparison of withdrawal threshold (g) in rats at various time points before and after <sup>125</sup>I implantation**

Group	24 hours preoperation	Time post operation (hour)				
		48	168	336	720	1,440
Control	17.8±4.4	17.0±1.2	17.3±3.3	17.6±3.2	17.7±1.7	16.5±3.4
Low radioactivity	17.5±3.2	15.1±1.2	12.5±2.3	11.2±1.6 <sup>a</sup>	12.3±1.4	15.6±1.7 <sup>a</sup>
High radioactivity	16.2±4.4	15.0±1.0	10.0±3.0 <sup>a</sup>	8.2±1.5 <sup>a</sup>	16.2±3.6	23.9±4.4

According to the “up-down” method reported by Chaplan et al. (1994), we measured paw withdrawal threshold with a series of 8 von Frey hairs of logarithmically incremental stiffness (0.41, 0.70, 1.20, 2.04, 3.63, 5.50, 8.50, and 15.10 g). <sup>a</sup>*P* < 0.05, vs. control group (the same time point). Data are expressed as mean ± SD of six rats in each group. Analysis of variance of repeated measurement data was used to compare measurement data.

**Table 2 Changes in combined behavioral scores in rats at different time points after <sup>125</sup>I implantation**

Group	24 hours preoperation	Time post operation (hour)				
		48	168	336	720	1,440
Control	2.56±1.33	2.55±1.35	2.47±1.42	2.54±1.36	2.44±1.66	2.62±1.57
Low radioactivity	2.56±1.03	2.33±1.31	2.45±1.29	2.35±1.38	2.42±1.29	2.35±1.87
High radioactivity	2.53±1.04	2.52±1.23	2.45±1.32	2.56±1.23	2.61±1.58	2.89±1.45

Evaluation of hind limb motor function by combined behavioral scores: higher scores indicate more severe injury. Data are expressed as mean ± SD of six rats in each group. Analysis of variance of repeated measurement data was used to compare measurement data.

**Table 3 Relative position, dose rate and irradiation dose of rats in each group at various time points**

Group	Rat number	Time (hour)	Relative position		Dose rate (cGy/h)	Dose (Gy)
			r (cm)	θ (°)		
Low radioactivity	1	336	0.68	42	0.79	4.89
	1	336	0.59	32	0.93	5.75
	1	1,440	0.53	19	0.91	18.77
	1	1,440	0.55	25	0.94	19.51
High radioactivity	1	336	0.53	20	1.81	11.24
	1	336	0.56	27	1.94	12.02
	1	1,440	0.53	20	1.81	37.55
	1	1,440	0.54	24	1.88	39.03

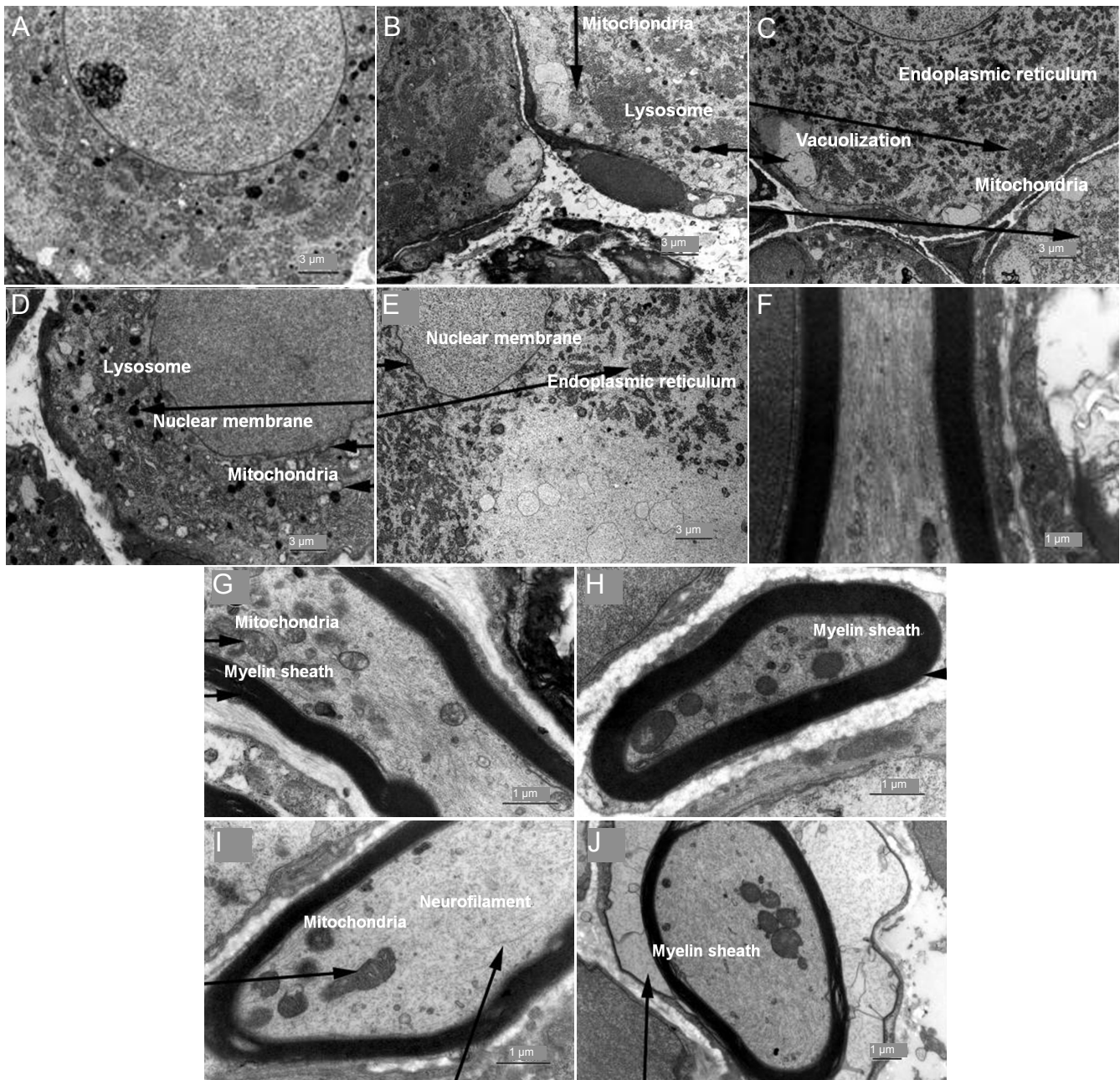
Thus, 336 hours was chosen as the first timepoint to observe ultrastructural changes. The half-life of <sup>125</sup>I is about 60 days. Thus, 1,440 hours was chosen as the second timepoint.

This study showed the paw withdrawal threshold decreased at 336 and 720 hours in the low radioactivity group and at 168 and 336 hours in the high radioactivity group, and then gradually returned to preoperative levels. This result indicated the mechanical response pain threshold declined with hyperpathia. Considering the early timepoint of dorsal root ganglion injury, it appeared likely that hyperpathia occurred because of the increasing excitability (Holmes et al., 2003; Coronel et al., 2008). Nevertheless, the paw withdrawal threshold of hind limbs increased significantly at 1,440 hours in the high radioactivity group, indicating the pain threshold increased. To eliminate the influence of acute inflammatory

mediator exudation caused by mechanical injury of paravertebral muscles incision, a control group was established.

Dorsal root ganglia from normal rats are composed of sensory neurons and nerve fibers. The current study observed that dorsal root ganglion cells underwent necrosis, abundant nuclear membrane retraction, partial fuzzy nuclear membrane, vacuolization, apparent increased lysosome and endoplasmic reticulum dilation at 1,440 hours in the high radioactivity group. Myelin sheaths collapsed and mitochondria were reduced with obvious vacuolization. These pathological changes showed that the implantation of radioactive <sup>125</sup>I seeds could lead to cell necrosis and degeneration of sensory neurons and nerve fibers of dorsal root ganglia.

Thus, the motor function of rats in each group was good before and after therapy, without statistically significant differences in combined behavioral scores, suggesting the maximal radioactivity of 29.6 MBq did not impact motion. This might be due to the following: (1) implantation was in the L<sub>4-5</sub> and L<sub>5-6</sub> intervertebral foramen and the cauda equina is the most vulnerable area inside the spinal canal. There have been no reports about the tolerance dose of cauda equina thus far. According to conventional standard radiation therapy, the highest tolerance dose of the spinal cord to external irradiation was 60 Gy, and for the brainstem it was 54 Gy (Mayo et al., 2010a). Mayo et al. (2010b) demonstrated the tolerance dose of the optic nerve was 60 Gy and a single dose was less than 12 Gy. The accumulative irradiation doses of two 29.6 MBq seeds implanted into L<sub>4-5</sub> and L<sub>5-6</sub> intervertebral foramen were calculated at 1,440 hours, and the dose was 39.03 Gy, less than the previously reported dose. Additionally, the dorsal root ganglia and spinal cord are physically separated. Consequently the radiation dose was lower. (2)



**Figure 1** Ultrastructural changes of dorsal root ganglion cells and nerve fibers after implanting various iodine-125 seeds.

Control group: dorsal root ganglion cells had a clear and centered nucleolus, regular nuclear membranes, and normal organelles (A). Nerve fibers were normal with complete myelin sheaths and mitochondria without lysosome (F). Low radioactivity group: at 336 hours, most dorsal root ganglion cells were normal with a few abnormal cells showing mitochondrial swelling and lysosome increase (B), and nerve fibers showed slight myelin sheath swelling and mitochondrial swelling (G). At 1,440 hours, dorsal root ganglion cells showed mitochondrial swelling, partial vacuolization, lysosome increase, and partial endoplasmic reticulum dilation (C). The nerve fibers showed myelin sheath swelling and mitochondrial decrease (H). High radioactivity group: at 336 hours, dorsal root ganglion cells showed nuclear membrane buckling, widespread mitochondrial swelling, lysosome increase, partial endoplasmic reticulum dilation and vacuolization (D), and nerve fibers showed thin myelin sheaths, mitochondrial decrease and high neurofilament levels (I). At 1,440 hours, nuclear membranes buckling evidently, endoplasmic reticulum dilation with obvious vacuolization and cell necrosis was observed (E). Myelin sheaths collapsed and the number of mitochondria was reduced in nerve fibers (J).

The experiment only lasted 1,440 hours, 60 days to determine whether delayed effects occurred.

In conclusion, implanting different radioactive  $^{125}\text{I}$  seeds around the dorsal root ganglia caused dorsal root ganglion cell necrosis, degeneration and increased pain threshold, but did not impact motor function. Our investigation only

lasted for the equivalent of one half-life (*i.e.*, 60 days) of  $^{125}\text{I}$ ; however, the radioactive seeds require at least 3 half-lives (180 days) for efficacy. Therefore, in the future we will investigate the effects after 180 days and how long this effect would last. Regardless, this study provides preliminary data and introduces a novel method for the treatment of

neuropathic pain.

**Author contributions:** Jiao L, Zhang WY, Ma WT, Wang HX, Zhang TD, Fan SJ participated in study concept and design. Zhang TD, Wang HX, Jiao L, Zhang WY and Huo XD participated in data acquisition, quality control of data and algorithms. Zhang TD, Wang HX, Ma WT, Zhang WY and Jiao L participated in data analysis, interpretation, statistical analysis and wrote the manuscript. Zhang TD, Zhang WY, and Fan SJ edited the manuscript. Jiao L and Fan SJ were in charge of manuscript review. Zheng BS was responsible for technical support and supervision. All authors approved the final version of the paper.

**Conflicts of interest:** None declared.

## References

- Babu RS, Anand P, Jeraud M, Periasamy P, Namasivayam A (2007) Bipedal locomotion of bonnet macaques after spinal cord injury. *Motor Control* 11:322-347.
- Chaplan SR, Bach FW, Pogrel JW, Chung JM, Yaksh TL (1994) Quantitative assessment of tactile allodynia in the rat paw. *J Neurosci Methods* 53:55-63.
- Chun-jing H, Yi-ran L, Hao-xiong N (2012) Effects of dorsal root ganglion destruction by adriamycin in patients with postherpetic neuralgia. *Acta Cir Bras* 27:404-409.
- Coronel MF, Brumovsky PR, Hokfelt T, Villar MJ (2008) Differential galanin upregulation in dorsal root ganglia and spinal cord after graded single ligature nerve constriction of the rat sciatic nerve. *J Chem Neuroanat* 35:94-100.
- Du Y, Jin Z, Meng H, Zou D, Chen J, Liu Y, Zhan X, Wang D, Liao Z, Li Z (2013) Long-term effect of gemcitabine-combined endoscopic ultrasonography-guided brachytherapy in pancreatic cancer. *J Interv Gastroenterol* 3:18-24.
- Holmes FE, Bacon A, Pope RJ, Vanderplank PA, Kerr NC, Sukumaran M, Pachnis V, Wynick D (2003) Transgenic overexpression of galanin in the dorsal root ganglia modulates pain-related behavior. *Proc Natl Acad Sci U S A* 100:6180-6185.
- Huang Q, Chen J, Chen Q, Lai Q, Cai S, Luo K, Lin Z (2013) Computed tomographic-guided iodine-125 interstitial implants for malignant thoracic tumors. *Eur J Radiol* 82:2061-2066.
- Johnson RW, Wasner G, Saddier P, Baron R (2008) Herpes zoster and postherpetic neuralgia: optimizing management in the elderly patient. *Drugs Aging* 25:991-1006.
- Lin ZY, Chen J, Deng XF (2012a) Treatment of hepatocellular carcinoma adjacent to large blood vessels using 1.5T MRI-guided percutaneous radiofrequency ablation combined with iodine-125 radioactive seed implantation. *Eur J Radiol* 81:3079-3083.
- Lin ZY, Lin J, Lin C, Li YG, Chen SM, Hu JP, Hu R, Chen J (2012b) 1.5T conventional MR-guided iodine-125 interstitial implants for hepatocellular carcinoma: feasibility and preliminary clinical experience. *Eur J Radiol* 81:1420-1425.
- Liu S, Jia Z, Zhou L, Liu Y, Ling H, Zhou SF, Zhang A, Du Y, Guan G, Yang T (2013) Nitro-oleic acid protects against adriamycin-induced nephropathy in mice. *Am J Physiol Renal Physiol* 305:F1533-1541.
- Mayo C, Yorke E, Merchant TE (2010a) Radiation associated brainstem injury. *Int J Radiat Oncol Biol Phys* 76:S36-41.
- Mayo C, Martel MK, Marks LB, Flickinger J, Nam J, Kirkpatrick J (2010b) Radiation dose-volume effects of optic nerves and chiasm. *Int J Radiat Oncol Biol Phys* 76:S28-35.
- Meuser T, Pietruck C, Radbruch L, Stute P, Lehmann KA, Grond S (2001) Symptoms during cancer pain treatment following WHO-guidelines: a longitudinal follow-up study of symptom prevalence, severity and etiology. *Pain* 93:247-257.
- Rivard MJ, Coursey BM, DeWerd LA, Hanson WF, Huq MS, Ibbott GS, Mitch MG, Nath R, Williamson JF (2004) Update of AAPM Task Group No. 43 Report: A revised AAPM protocol for brachytherapy dose calculations. *Med Phys* 31:633-674.
- Rodrigues FF, Dozza DC, de Oliveira CR, de Castro RG (2006) Failed back surgery syndrome: casuistic and etiology. *Arq Neuropsiquiatr* 64:757-761.
- Schaeffer V, Meyer L, Patte-Mensah C, Mensah-Nyagan AG (2010) Progress in dorsal root ganglion neurosteroidogenic activity: basic evidence and pathophysiological correlation. *Prog Neurobiol* 92:33-41.
- Sheen K, Chung JM (1993) Signs of neuropathic pain depend on signals from injured nerve fibers in a rat model. *Brain Res* 610:62-68.
- Taschereau R, Roy R, Pouliot J (2002) Relative biological effectiveness enhancement of a 125I brachytherapy seed with characteristic x rays from its constitutive materials. *Med Phys* 29:1397-1402.
- Wang K, Jin Z, Du Y, Chen J, Zhan X, Wang L, Li Z, Zou D, Liu Y (2009) Evaluation of endoscopic-ultrasound-guided celiac ganglion irradiation with iodine-125 seeds: a pilot study in a porcine model. *Endoscopy* 41:346-351.
- Wang KX, Jin ZD, Du YQ, Zhan XB, Zou DW, Liu Y, Wang D, Chen J, Xu C, Li ZS (2012) EUS-guided celiac ganglion irradiation with iodine-125 seeds for pain control in pancreatic carcinoma: a prospective pilot study. *Gastrointest Endosc* 76:945-952.
- Wilkinson HA, Chan AS (2001) Sensory ganglionectomy: theory, technical aspects, and clinical experience. *J Neurosurg* 95:61-66.
- Zhang Y, Li L, Xiang C, Ma Z, Ma T, Zhu S (2013) Protective effect of melatonin against Adriamycin-induced cardiotoxicity. *Exp Ther Med* 5:1496-1500.
- Zhongmin W, Yu L, Fenju L, Kemin C, Gang H (2010) Clinical efficacy of CT-guided iodine-125 seed implantation therapy in patients with advanced pancreatic cancer. *Eur Radiol* 20:1786-1791.

*Copypedited by Croxford L, Frenchman B, Wang J, Qiu Y, Li CH, Song LP, Zhao M*