

## Transposition of the persistent sciatic artery for lower limb revascularization after resection of an embolizing proximal sciatic artery aneurysm

Rudolf Feer, MD,<sup>a</sup> Peter Stierli, MD,<sup>a</sup> Claude Haller, MD,<sup>b</sup> and Giovanni Cito, MD,<sup>b</sup> Aarau and Sion, Switzerland

### ABSTRACT

We present a novel surgical technique for lower limb revascularization after resection of an aneurysm of the persistent sciatic artery that had led to recurrent peripheral embolization and severe ischemia. The superficial femoral artery in this patient was hypoplastic, and the sciatic artery continued into the popliteal artery as the source of blood supply to the lower leg. For revascularization, we used the distally pedicled healthy two-thirds of the persistent sciatic artery, transposed it from its posterior position to a nearly anatomic anteromedial position, and anastomosed it to the proximal superficial femoral artery. (*J Vasc Surg Cases and Innovative Techniques* 2017;3:139-41.)

A 74-year-old woman presented to our emergency department with claudication of the left lower limb rapidly progressing to rest pain and distal sensory loss. She was otherwise in good health (American Society of Anesthesiologists class 2). She had a history of coronary stenting 3 years earlier and was taking hypertensive medication, aspirin, and a statin. She had previously undergone saphenous vein surgery. The left femoral pulse was diminished, and pulses on the left foot were absent; on the right foot, only the dorsal pedal artery was palpable. The popliteal pulses were notably symmetric. A pulsating mass was felt in the left buttock. Computed tomography angiography showed a unilateral complete persistent sciatic artery (PSA) as the dominant source of blood supply to the lower leg with a partially thrombosed aneurysm (maximal outer diameter, 33 mm) below the sciatic notch. All three lower leg arteries were occluded and showed signs of recurrent embolization. The superficial femoral artery was hypoplastic and tapered and terminated in the middle thigh. No other vascular anomaly was noted (*Fig 1*). The patient's informed consent was obtained for this publication.

### SURGICAL TECHNIQUE

Surgery was performed in two stages. The first stage consisted of resection of the aneurysm and dissection of the healthy part of the PSA down to the level of the proximal popliteal artery, leaving it distally pedicled. The second stage consisted of revascularization of the lower limb by transposing the mobilized PSA to the groin and anastomosing it to the femoral artery as the inflow vessel, thus giving it a nearly anatomic course.

For the first stage, the patient was placed in a right lateral position. A curved incision over the gluteal region was continued distally to the posterior aspect of the thigh (*Fig 2*). The skin and subcutaneous tissue were retracted medially. The gluteus maximus muscle was partially released from its insertion at the ilium and split along its fibers to expose the sciatic artery aneurysm with its healthy neck at the level of the greater sciatic notch just below the piriform muscle. After heparinization, the sciatic artery was transected distal to the aneurysm, where it was visually normal and not dilated. This segment of healthy PSA was dissected out of the sciatic groove down to the level where it turned into the popliteal artery. Care was taken not to injure the sciatic nerve. The aneurysm sac was incised longitudinally, and the backbleeding branches were ligated. After division of the sciatic artery above the aneurysm and closure of the stump with a Blacklock suture, the aneurysm was resected and sent for histologic analysis. The posterior incision was closed.

For the second stage, we placed the patient in the supine position. The femoral bifurcation was exposed using a groin incision. Through a medial supragenicular incision, the mobilized sciatic artery was tunneled to the groin and anastomosed to the origin of the superficial femoral artery, incorporating a long venous Taylor patch into the superficial femoral artery to accommodate the diameter mismatch and missing length onto the common femoral artery. To treat the occluded lower leg

From the Department of Surgery, University Center for Vascular Surgery, Aarau-Basel, Aarau<sup>a</sup>; and the Département de Chirurgie, Unité de Chirurgie Vasculaire, Hôpital du Valais, Sion.<sup>b</sup>

Author conflict of interest: none.

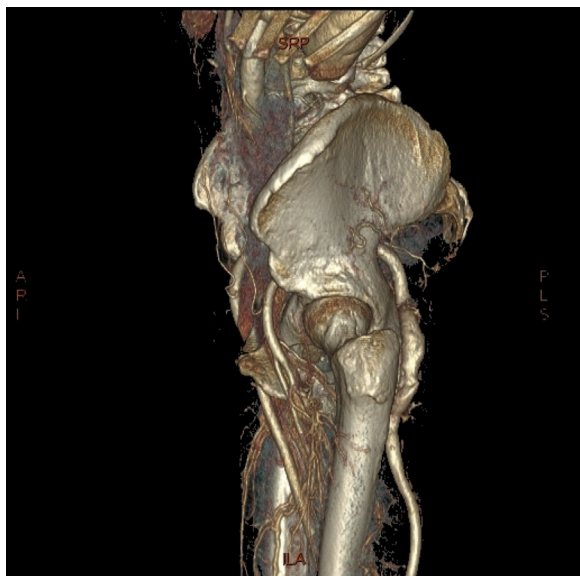Correspondence: Rudolf Feer, MD, Department of Surgery, University Center for Vascular Surgery, Aarau-Basel, Tellstrasse 25, Aarau 5001, Switzerland (e-mail: [rudolf.feer@ksa.ch](mailto:rudolf.feer@ksa.ch); [rudolf.feer@bluewin.ch](mailto:rudolf.feer@bluewin.ch)).

The editors and reviewers of this article have no relevant financial relationships to disclose per the Journal policy that requires reviewers to decline review of any manuscript for which they may have a conflict of interest.

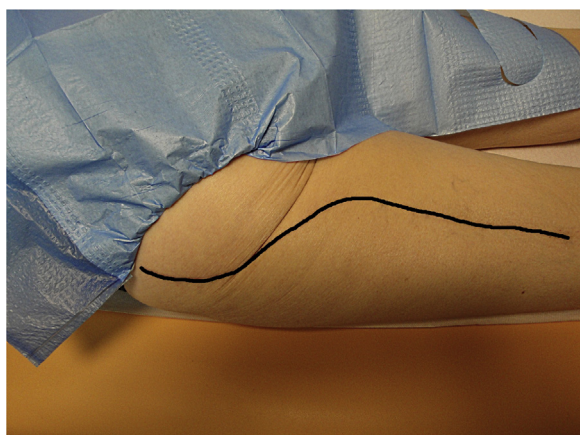
2468-4287

© 2017 The Authors. Published by Elsevier Inc. on behalf of Society for Vascular Surgery. This is an open access article under the CC BY-NC-ND license (<http://creativecommons.org/licenses/by-nc-nd/4.0/>).

<http://dx.doi.org/10.1016/j.jvscit.2017.04.002>

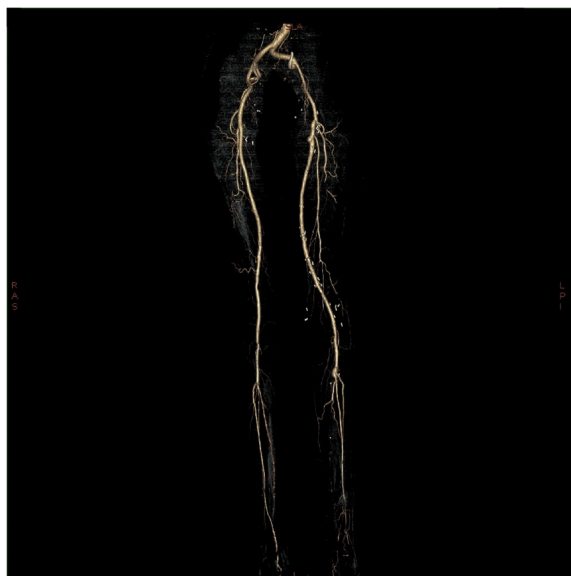


**Fig 1.** Preoperative lateral computed tomography angiography reconstructed three-dimensional view of the perfused sciatic artery aneurysm of the left side. In the foreground, anterior, note the left femoral artery bifurcation with its outgoing hypoplastic superficial femoral artery in comparison to the normal-caliber contralateral one in the background.



**Fig 2.** Surgical access, as seen with the patient in prone position 19 months postoperatively, of the left buttock into the dorsal aspect of the thigh for exposing the aneurysm and skeletonizing the sciatic artery.

arteries, we accessed the popliteal artery through a medial infragenicular incision and performed an embolectomy of the distal popliteal artery with its trifurcation under direct vision and selectively of the three lower leg arteries with Fogarty balloon catheters followed by pharmacologic lysis (Actilyse; Boehringer Ingelheim, Ingelheim, Germany). The popliteal arteriotomy was closed with a venous patch plasty. After intravascular application of a vasodilator (papaverine), blood flow of 188 mL/min in the popliteal artery was measured with



**Fig 3.** Early postoperative computed tomography angiography reconstruction three-dimensional view of the whole arterial tree from the pelvis to the foot. Note the perfused internal iliac artery, with the exception of the thrombosed inferior gluteal artery (poorly illustrated because of image processing); the physiologic course of the transposed segment of the persistent sciatic artery (PSA) with its enlargement at the proximal anastomosis by the Taylor patch; the hypoplastic, incompletely tapered superficial femoral artery; the enlargement of the calf trifurcation by a venous patch; and an incomplete distal runoff due to the previous embolizations caused by the aneurysm.

a 5-mm ultrasonic flow measurement probe (Transit Time Flow Measurement, VeriQ; Medistim ASA, Oslo, Norway), and the wounds were closed (Fig 3).

The postoperative course was uneventful, and 19 months after the procedure, the patient remains without symptoms and has an ankle-brachial pressure index of 0.95 but no palpable foot pulses. Early and late control computed tomography angiography showed a perfused internal iliac artery and its branches (with the exception of the inferior gluteal artery), a well-contrasted femoropopliteal axis, and an incomplete distal runoff as a sign of only partially successful embolectomy of the lower leg arteries.

## DISCUSSION

The PSA is an embryonic remnant from the stage before the development of the external iliac and femoral arteries, when the entire leg is perfused through the sciatic artery.<sup>1</sup> The sciatic artery originates from the inferior gluteal artery and runs along the sciatic nerve at the back of the thigh. Different classifications have been proposed in the literature.<sup>2,3</sup> Bower et al<sup>2</sup> distinguished the complete from the incomplete PSA. In our case, it was the complete form characterized

by the PSA as the dominant blood supply to the lower leg associated with a hypoplastic superficial femoral artery. The sciatic artery runs along the buttock and is thus exposed to repeated compression and stretching. This, along with a postulated structural vessel wall alteration, is believed to favor aneurysmal degeneration of the proximal sciatic artery.<sup>4</sup>

To our knowledge, this is the first description of the use of the transposed, distally pedicled sciatic artery for revascularization. With this open surgical technique, we achieved a good result, which is still maintained 19 months after surgery. There are several advantages to our technique. An autologous artery is used for the revascularization, the transposed PSA has a nearly normal anatomic course, only one anastomosis needs to be created, and no autologous vein is needed, which is of particular importance in patients who do not have veins suitable for a bypass. A major limitation of our technique is that it relies on a healthy distal segment of the sciatic artery, without excessive arteriosclerotic changes, stenosis, or dilation. Long-term surveillance with duplex ultrasound will be necessary as the PSA might be more likely to undergo aneurysmal degeneration.

In the literature, fewer than 200 cases of this rare<sup>2</sup> pathologic entity are described.<sup>5</sup> Multiple surgical options have been recommended, mostly open surgical techniques reconstructing the femoropopliteal axis with a vein bypass. However, in the recent literature, more endovascular and hybrid procedures have been reported,<sup>6</sup> mostly with a short follow-up of only a few months and with a possibly slightly inferior outcome for endovascular repair<sup>7</sup> compared with open surgical repair.

## CONCLUSIONS

For most patients with a symptomatic PSA, we consider open surgical treatment the “gold standard.” The reported alternative techniques for revascularization or exclusion of a complete PSA appear to lead to an inferior outcome and do not have adequate follow-up. The technique described in this article might be a useful addition to the therapeutic armamentarium for the treatment of a symptomatic PSA in properly selected patients.

## REFERENCES

1. Mandell VS, Jaques PF, Delany DJ, Oberheu V. Persistent sciatic artery: clinical, embryologic, and angiographic features. *AJR Am J Roentgenol* 1985;144:245-9.
2. Bower EB, Smullens SN, Parke WW. Clinical aspects of persistent sciatic artery: report of two cases and review of the literature. *Surgery* 1977;81:588-95.
3. Pillet J, Cronier P, Mercier P, Chevalier JM. The ischiopopliteal arterial trunk: a report of two cases. *Anat Clin* 1982;3:329-31.
4. Brantley SK, Rigdon EE, Raju S. Persistent sciatic artery: embryology, pathology, and treatment. *J Vasc Surg* 1993;18:242-8.
5. Ahmad W, Majd P, Luebke T, Gawenda M, Brunkwall JS. Clinical outcome after surgical and endovascular treatment of symptomatic persistent sciatic artery with review of the literature and reporting of three cases. *Vascular* 2016;24:469-80.
6. Yamamoto H, Yamamoto F, Ishibashi K, Yamaura G, Shiroto K, Motokawa M, et al. Intermediate and long-term outcomes after treating symptomatic persistent sciatic artery using different techniques. *Ann Vasc Surg* 2011;25:837.e9-15.
7. Girsowicz E, Georg Y, Lejay A, Ohana M, Delay C, Bouamaied N, et al. Midterm failure after endovascular treatment of a persistent sciatic artery aneurysm. *Ann Vasc Surg* 2014;28:1323.e7-12.

Submitted Nov 23, 2016; accepted Apr 10, 2017.