

Management of Naevoid Conditions Following the Lines of Blaschko in Paediatric Age Group

Dear Editor,

Blaschko's lines also termed as the lines of Blaschko, are believed to represent normal cell development in the skin. This concept was first introduced by the German dermatologist Alfred Blaschko at the 7th Congress of German Dermatological Society in 1901.^[1] These lines create a surface pattern which is distinct from other morphological lines of the skin and skin dermatomes. They do not correspond to nervous, muscular, or lymphatic systems.^[2] They are invisible under normal conditions and become apparent when some diseases of the skin or mucosa manifest themselves according to these patterns.^[1] They follow a "V"-shape over the upper spine, an S-shape on the abdomen, and an inverted U-shape from the breast area over to the upper arm. These are perpendicular down the front and back of the lower extremities.^[1] Pictorial view of the distribution of these lines is displayed in [Figure 1a and b]. Because of their linear distribution, historically, these were assumed to represent Koebner's phenomenon, but the curvature of the lesions does not advocate this theory. These are not clearly defined over head and neck. Happle *et al.*^[3,4] pronounced these lines to the posterior scalp, whereas, Bologna *et al.*^[5] further reported them over the lateral aspect of the face and neck. Brown and Gorlin introduced vertical striations on the lips, linear midline lesions on the hard and soft palate, and linear unilateral and/or midline bands over the tongue in patients with epidermal nevi. The anatomic equivalent of Blaschko's lines have also been reported over the teeth as well as in the eyes.^[6]

Naevus is the Latin word for "maternal impression" or "birthmark" and designates

a circumscribed, non-neoplastic skin or mucosal lesion, commonly present at or soon after birth, and fixed. The term should always be qualified according to the cell or tissue origin, for instance, "connective tissue naevus" and "vascular naevus". Confusingly, "naevus", "naevo-" and "naevoid" are often used to refer to melanocytic naevus. The term 'naevus' is identical with cutaneous hamartoma (e.g., smooth muscle naevus/hamartoma), both containing an abnormal mixture of a usual tissue components (the word "hamartoma" originates from the Greek word *hamartia*, meaning "to err").^[7]

Lines of Blaschko are believed to represent pathways of epidermal cell migration and proliferation during the development of the fetus. Hitherto, the embryological basis of the distribution pattern of these lines is a riddle. Many, probably all, naevi express clones of genetically modified cells emerging from mosaicism.^[8,9,10]

Genetic mosaicism implies the presence of two or more genetically different cell populations in an individual derived from a single zygote. The variations can be between single genes, groups of genes or entire chromosomes. Chimerism denotes the presence of two or more genetically distinct cell populations in an individual derived from two different zygotes. Chimeras can result from the fusion of dizygotic twin embryos or the fertilization by two spermatozoa, and consequent splitting of an ovum comprising a polar body. Mosaicism typically involves an abnormal clone within a normal individual whereas, chimerism includes two different normal clones. Cutaneous anomalies due to mosaicism affect any skin cell type, but the cutaneous abnormalities observed in human chimeras are always pigmentary.^[11,12]

Jagdish Jadavbhai Sakhiya,
Dhruv J. Sakhiya¹,
Trusha Gajjar,
Neha Virmani,
Jashmin Gandhi,
Madhav Purohit,
Krishna Bhalala,
Ravi Khambhati,
Feral Daruwala

Sakhiya Skin Clinic,
 2nd Floor, Ayush Doctor House,
 Station-Lal Darwaja Road,
 Surat, ¹B.J. Medical College,
 New Civil Hospital Asarwa,
 Ahmedabad, Gujarat, India

Address for correspondence:
 Dr. Jagdish Jadavbhai Sakhiya,
 Sakhiya Skin Clinic,
 2nd Floor, Ayush Doctor House,
 Station-Lal Darwaja Road,
 Surat - 395 003, Gujarat, India.
 E-mail: sakhiya.academic@rediffmail.com

Access this article online

Website: www.idoj.in

DOI: 10.4103/idoj.IDOJ_681_20

Quick Response Code:



This is an open access journal, and articles are distributed under the terms of the Creative Commons Attribution-NonCommercial-ShareAlike 4.0 License, which allows others to remix, tweak, and build upon the work non-commercially, as long as appropriate credit is given and the new creations are licensed under the identical terms.

For reprints contact: WKHLRPMedknow_reprints@wolterskluwer.com

How to cite this article: Sakhiya JJ, Sakhiya DJ, Gajjar T, Virmani N, Gandhi J, Purohit M, *et al.* Management of naevoid conditions following the lines of blaschko in paediatric age group. Indian Dermatol Online J 2021;12:433-8.

Received: 29-Aug-2020. **Revised:** 20-Oct-2020.

Accepted: 14-Dec-2020. **Published:** 12-May-2021.

Table 1: Laser specification for various nevoid condition and special concern

Conditions	Laser settings	Comment
Naevoid psoriasis	Excimer laser (308 nm); initial irradiation dosage: 200 to 2000 mJ/cm ² ; increment dose: 20%; spot size: 4×4 cm ² ; power density: 50 mW/cm ² ; single dose per session; total session: 20-30; interval between each session: 2 weeks.	Erythema, tenderness and blistering are the most common side effects at the site of treatment.
Naevoid comedonicus	Non-ablative fractional erbium glass laser (1550 nm); fluence: 100 mJ/cm ² ; coverage: 20%; passes: 2-4; total session: 6-10; interval between each session: 4 weeks. Or CO ₂ ablative laser (10,600 nm); power: 30 watts; fractional mode; total session: 8-10; interval between each session: 4-6 weeks.	The risks of post-inflammatory dyspigmentation and erythema may occur.
Angiofibroma [Figure 2a and b]	CO ₂ ablative laser (10,600 nm); power: 10-15 watts; continuous mode; total session: 1-5; interval between each session: 4 weeks.	Recurrence may occur and also a risk of transient hyperpigmentation.
Neurofibromatosis [Figure 3a and b]	CO ₂ ablative laser (10,600 nm); power: 12-15 watts; continuous mode; total session: 3-6; interval between each session: 4-6 weeks.	Minor complication including, bleeding, secondary local infections and hypertrophic scars may occur and to prevent these, a short course of oral antibiotic treatment should be prescribed. Recurrence is usual.
Nevus achromicus [Figure 4a and b]	Excimer laser (308 nm); initial irradiation dosage: 200 mJ/cm ² ; increment dose: 10%; spot size: 4 × 4 cm ² ; power density: 50 mW/cm ² ; single dose per session; total session: 10-20; interval between each session: 2 weeks.	Its treatment is often unnecessary, but cosmetic camouflage by lasers may be helpful in patients, who ask for treatment.
Compound melanocytic nevus [Figure 5a and b]	Surgical excision Or CO ₂ ablative laser (10,600 nm); power: 2-10 watts; continuous mode; total session: 1-3; interval between each session: 4-6 week along with Q-switched ND: YAG laser (1064 nm) (for correcting post-inflammatory hyperpigmentation); fluence: 1.2-2 J/cm ² ; spot size: 7-8mm; total session: 3-6; interval between each session: 4-6 weeks and diode; fluence: 18-24 J/cm ² ; spot size: 12×12, pulse duration: 30ms with chilled tip	The patients was instructed to avoid rubbing and excessive washing. A broad-spectrum sunscreen was recommended to prevent side effect of hyper pigmentation.
Epidermal melanocytic nevus [Figure 6a and b]	Fractional CO ₂ laser (10,600 nm); power: 2-12 watts; fractional mode; total session: 2-10; interval between each session: 4 weeks along with Q-switched ND: YAG laser (1064 nm) (for correcting post-inflammatory hyperpigmentation); fluence: 1.2-2 J/cm ² ; spot size: 7-8mm; total session: 3-6; interval between each session: 4 weeks.	Due to the risk of hypo/hyper pigmentation, the patient was suggested to avoid sun exposure for 4 to 6 weeks after laser treatment. Minimum gap of 4 to 6 weeks between sessions.
Lymphangioma circumscriptum [Figure 7a and b]	CO ₂ ablative laser (10,600 nm); power: 30 watts; continuous mode; total session: 4-6; interval between each session: 4-6 weeks.	The risk of further symptomatic lesion recurrence remains high.
Sebaceous nevus [Figure 8a and b]	Fractional CO ₂ laser (10,600 nm); fluence: 50-100mJ/cm ² ; spot density: 160 spots/cm ² ; treatment level: 160 MTZ/cm ² ; total session: 3-6; interval between each session: 4 weeks.	To ablate large lesions and subsequent treatment with pulsed dye laser is recommended to reduce scarring.
Freckles [Figure 9a and b]	Q-switched ND: YAG laser (1064 nm); fluence: 4J/cm ² ; spot size: 12×12 mm; total session: 2-10; interval between each session: 4-6 weeks.	There is a chance of dyspigmentation.
Lentigines [Figure 10a and b]	Q-switched ND: YAG laser (1064 nm); fluence: 8-10 J/cm ² ; spot size: 3 mm; frequency: 2 Hz; total session: 2-8; interval between each session: 4-6 weeks.	The patient was recommended to avoid sun exposure for 4 to 6 weeks following laser treatment due to the risk of hypo/hyper pigmentation.
Faun tail nevus [Figure 11a and b]	Diode; energy: 20-40J; spot size: 10×10, pulse duration: 30-100 ms with chilled tip; total session: 8-10; interval between each session: 4-8 weeks.	In the case of well-localized paraspinal hypertrichosis, a neurological and radiological evaluation must be advised to eliminate spinal abnormalities.

Contd...

Table 1: Contd...

Conditions	Laser settings	Comment
Zosteriform vitiligo [Figure 12a and b]	Excimer laser (308 nm); initial irradiation dosage: 200-350 mJ/cm ² ; increment dose: 10%; spot size: 4×4 cm ² ; power density: 50 mW/cm ² ; single dose per session; total session: 20-30; interval between each session: 2 weeks.	History of herpes Zoster followed by Zosteriform Herpes Simplex Virus Type I infection should be taken.
Zosteriform Eczema [Figure 13a and b]	Excimer laser (308 nm); initial irradiation dosage: 600 mJ/cm ² ; increment dose: 20%; spot size: 4×4 cm ² ; power density: 50 mW/cm ² ; single dose per session; total session: 20-30; interval between each session: 2 week along with Fractional CO ₂ laser (10,600 nm); power: 10-12 watts; pulse energy: 100 mJ; coverage: 40%; total session: 2-10; interval between each session: 4 weeks.	History of herpes Zoster followed by Zosteriform Herpes Simplex Virus Type I infection should be taken.
Nevus of Ota [Figure 14a and b]	Q-switched ND: YAG laser (1064 nm); fluence: 3-8 J/cm ² ; spot size: 3-8 mm; frequency: 8 Hz; total session: 6-18; interval between each session: 4-6 weeks.	Patients are advised to use a sunscreen at least 15 days before the onset of laser therapy and throughout treatment. If the patients have tanned skin, bleaching creams containing hydroquinone and kojic acid are used. Special care has to be taken to treat lesions near the eye. Minimum gap of 6-8 weeks between sessions.
Capillary haemangioma and Vascular malformation [Figure 15a and b]	Intense pulsed light; a cutoff filter wavelength: 550 nm; fluence: 8-10 J/cm ² ; pulse duration: 4-20 ms; total session: 6-10; interval between each session: 4 weeks.	Temporary erythema may occur.
Verrucous epidermal nevus [Figure 16a and b]	CO ₂ ablative laser (10,600 nm); power: 10-18 watts; continuous mode; total session: 3-8; interval between each session: 4-6 weeks.	Side effects of slight hyperpigmentation, transitory desquamation and erythematous papules may occur.
Café-au-lait spots	Q-switched ND: YAG laser (1064 nm); fluence: 2-2.4 J/cm ² ; spot size: 7-8 mm; frequency: 8 Hz; total session: 12-24; interval between each session: 4-6 weeks.	Recurrence is usual, requiring multiple treatments. Minimum gap of 4 to 6 weeks between sessions. Simultaneous use of 1064 and 523 nm wavelengths can provide better clearance and further prevent recurrence.
Becker's nevus	Alternate use of Q-switched ND: YAG laser (532 nm); fluence: 2-2.4 J/cm ² ; spot size: 7-8 mm; frequency: 8 Hz; total session: 12-24; interval between each session: 4-6 weeks and diode; energy: 10-20J; spot size: 8×8 mm ² , pulse duration: 60 ms with chilled tip.	Can be combined with laser hair removal if there is hair growth over the nevus. Minimum gap of 6-8 weeks between sessions.
Fordyce spots	CO ₂ ablative laser (10,60nm); power: 1-2 watts; continuous mode; total session: 2-3; interval between each session: 3-4 weeks.	Referred to as "Harmless spots" can cause concern because of their appearance but do not present any health risks.

† a denotes pretreatment view; b denotes post-treatment view

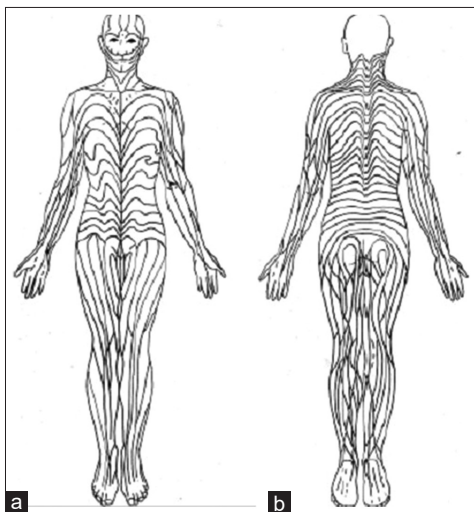


Figure 1: Distribution of the line of Blaschko in human body (a) front view (b) back view

Successive hypotheses have been proposed to describe Blaschko's lines and each one is more convincing than the previous one, but till date, mosaicism remains the most widely accepted one.^[13] Nonetheless, no conclusive decision was drawn, so the room for study remains therein.

Various congenital and acquired dermatological conditions are recognized to follow the lines of Blaschko such as X-linked dominant skin disorders, epithelial naevi, pigmentary disorders. These dermatoses have been classified into three groups: genodermatoses, congenital and/or naevoid conditions, and acquired conditions. Of these, naevoid skin lesions are most common and are present at birth or have a later onset. The term 'naevoid' is referred to mosaic forms of inherited skin conditions following these lines such as naevoid psoriasis^[8] epidermal nevi (naevus unius lateris, linear porokeratosis), adnexal nevi (linear

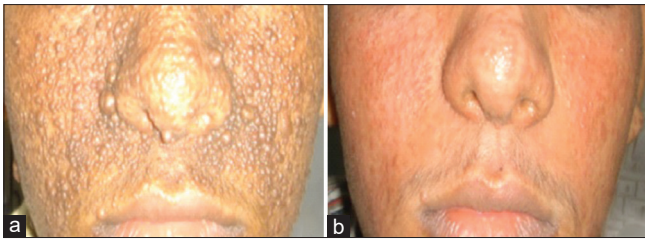


Figure 2: Angiofibroma (a) before laser (b) after laser

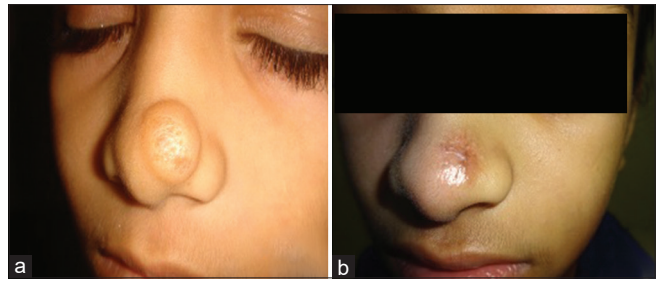

Figure 3: Photograph of neurofibromatosis (a) pre-treatment (b) post treatment

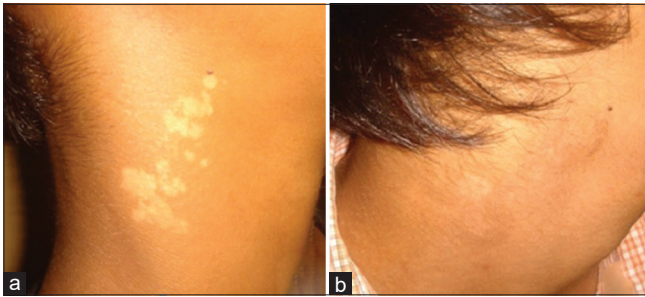


Figure 4: Nevus achromicus (a) before laser (b) effectively cleared with laser

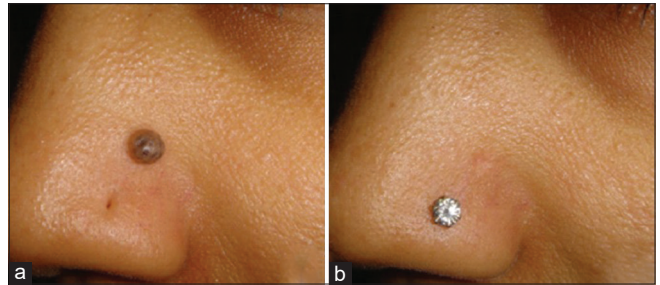


Figure 5: Compound Nevi on nose (a) before laser (b) after treatment

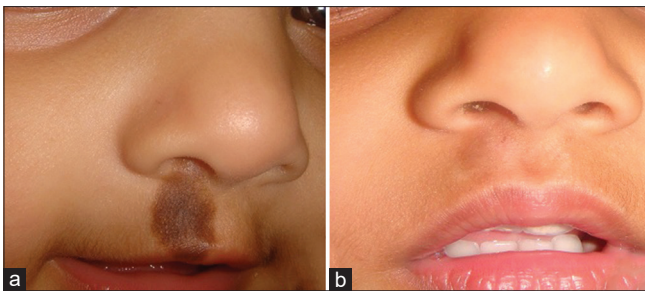


Figure 6: Epidermal melanocytic nevus (a) pre-treatment (b) post treatment

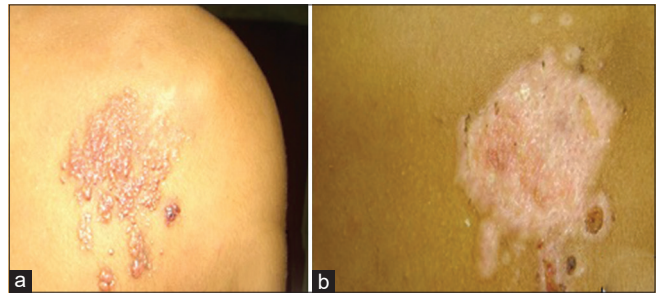


Figure 7: Lymphangioma circumscriptum (a) before treatment (b) after treatment

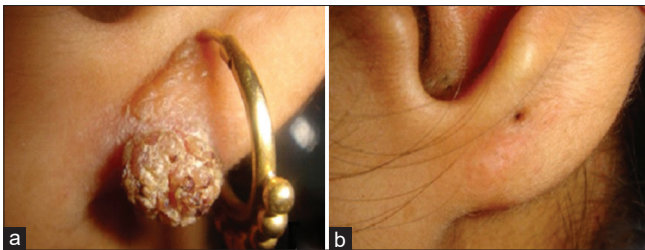


Figure 8: Sebaceous nevus (a) before laser (b) improved with laser

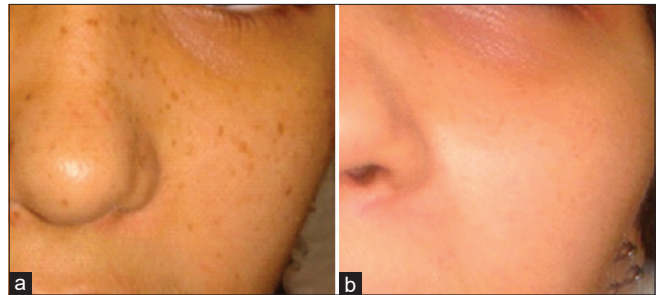


Figure 9: Freckles (a) pre-treatment (b) post treatment

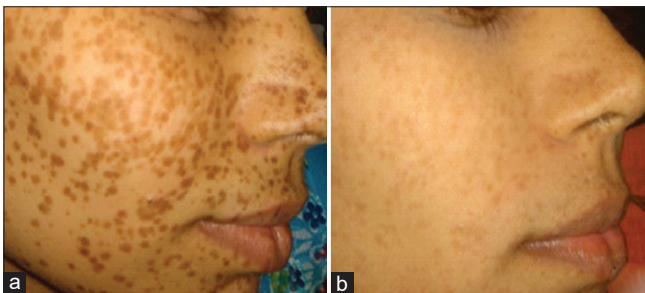

Figure 10: Lentiginos (a) pre-treatment (b) post treatment

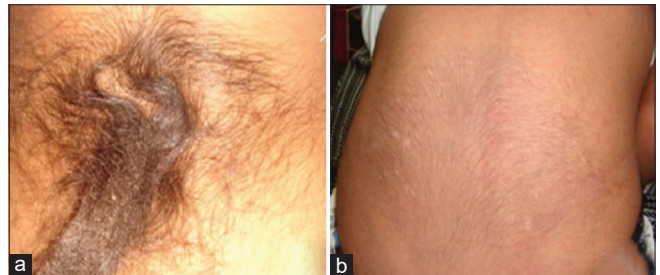


Figure 11: Faun tail nevus (a) before treatment (b) after treatment

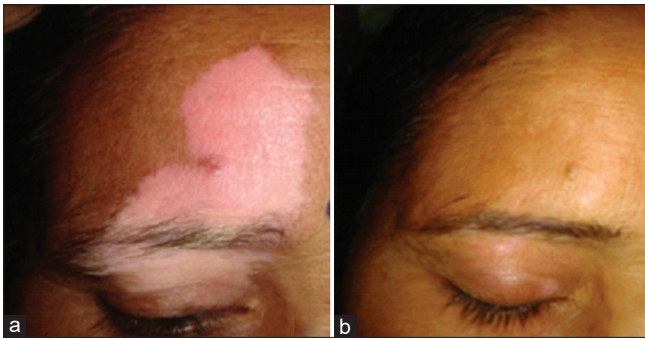


Figure 12: Zosteriform vitiligo (a) before treatment (b) improved cosmetic appearance after treatment

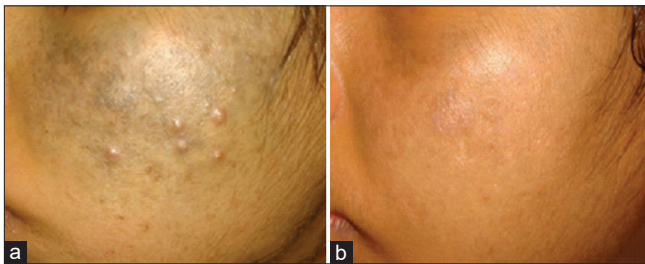


Figure 14: Nevus of ota (a) pre-treatment (b) post treatment

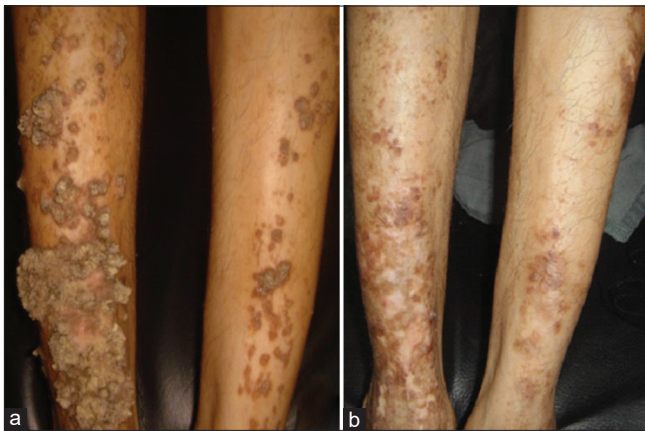


Figure 16: Verrucous epidermal nevus (a) before treatment (b) after treatment

sebaceous nevus, linear basal cellnevus), pigmented lesions (systematized linear achromicnevus) and intricat nevi of the connective tissue (angio-lipomatous nevus).^[14,15,16]

Naevoid conditions appear frequently in the pediatric population. Usually, they are developmental defects, means those originating in the embryo and fetus, that is, in the prenatal period. Given the increased general awareness of melanoma, however, caregivers often express concerns about the development or appearance of their child's nevus. An understanding of the more common types of nevus seen in children and the associated risk for the development of melanoma is essential to properly counsel caregivers and patients about management recommendations. Here, we explore potential treatment options involving either specific

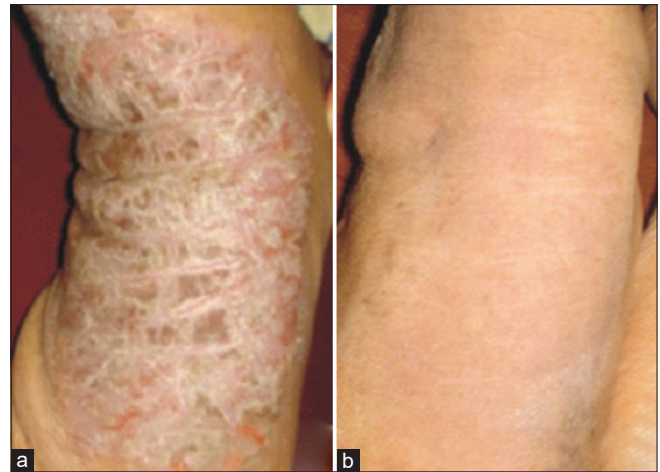


Figure 13: Zosteriform Eczema (a) before treatment (b) after treatment

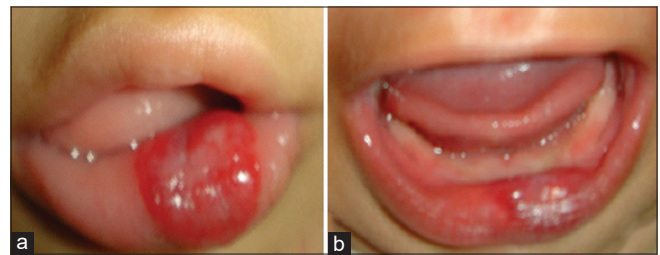


Figure 15: Capillary haemangioma (a) pre-treatment (b) post treatment

laser or combined lasers to tackle the majority of the naevoid condition to get more cosmetically acceptable benefits.

Management of Naevoid Condition in the Pediatrics Age Group

As adhering to the concept, if the lesion is small, less energy, and reduced number of sessions are required resulting in a less painful procedure. Final cosmetic appearance is more acceptable. Though lesion is small and benign, it has a great psychological impact on the child and, hence, early clearance will minimize the effect on the self-esteem of the child. Before starting the procedure, informed consent should be obtained from all the patients. Position the patient according to the area of a lesion so that the site to be treated is close to the laser. Gloves mask and cap should be used by operators and assistants. Clean the area with a cleanser. All mentioned procedure to be done under topical anesthesia (eutectic Mixture of Local Anesthesia (EMLA 2.5%) cream). Apply 2mg/cm² topically under occlusion for 45-60 min. The occlusion should be removed just before the procedure. Patient's eye should be protected with the eye shield or with wet gauze. Dermatologist and assistants should use wavelength-rated spectacles. Various laser specific parameters and concern regarding individual treatment for naevoid conditions are tabulated in [Table 1]. [Figures 2a, 2b-16a and 16b] show the results after treatment in different naevoid conditions.

Confusingly, Blaschko's lines are difficult to diagnose with dermatomes because distribution patterns for both are delineated by a striking demarcation of cutaneous lesions at the midline. But on the close comparison, the two do not appear to be related, though on the upper extremities there is a resemblance to the anatomical location of the motor nerves. Similarly, Blaschko's lines can be differentiated from Voigt's lines (the boundaries of the areas of distribution of the main cutaneous nerve stems) as these lines do not explain the V-shape on the back or the S-shape on the abdomen.^[1,5]

In the end, each naevoid cell is genetically capable for recurrence of the lesion if treated partially. Some dermatological practitioners believe that patients should wait for the treatment of naevoid conditions until the child grows to be an adult. But our practical experience recommends that it should be treated as soon as possible regardless of the age of the child. The treatment thumb rule, therefore, is 'strike hard strike early'. To sum up, we have tried to bust the age-old myth that many diseases just cannot be cured or helped.

Declaration of patient consent

The authors certify that they have obtained all appropriate patient consent forms. In the form the patient(s) has/have given his/her/their consent for his/her/their images and other clinical information to be reported in the journal. The patients understand that their names and initials will not be published and due efforts will be made to conceal their identity, but anonymity cannot be guaranteed.

Financial support and sponsorship

Nil.

Conflicts of interest

There are no conflicts of interest.

References

1. Jackson R. The lines of Blaschko: A review and reconsideration: Observations of the cause of certain unusual linear conditions of the skin. *Br J Dermatol* 1976;95:349-60.
2. Harper JL. Genetics and genodermatoses. In: Champion RH, Burton JL, Burns DA, Breathnach SM, editors. *Rook, Wilkinson/Ebling Textbook of Dermatology*. 6th ed. Oxford: Blackwell Science; 1998, p. 360-1.
3. Happle R, Fuhrmann RA, Fuhrmann W. Wiever-laufen die Blaschko-Linien am behaarten Kopf? *Hautarzt* 1984;35:366-9.
4. Happle R. Absence of bipolarity in Blaschko's lines. *Ann Dermatol Venereol* 1990;117:397.
5. Bologna JL, Orlow SJ, Glick SA. Lines of Blaschko. *J Am Acad Dermatol* 1994;31:157-90; quiz 190.
6. Brown HM, Gorlin RJ. Oral mucosal involvement in nevus unius lateralis (ichthyosis Hystrix): A review of the literature and report of a case. *Arch Dermatol* 1960;8:509-15.
7. Albrecht E. Über hamartome. *Verh Dtsch Ges Pathol* 1904;7:153-7.
8. Moss C, Shahidullah H. Nevi and other developmental defects. In: Burns T, Breathnach S, Cox N, Griffiths C, editors. *Rooks Textbook of Dermatology*. 8th ed. Oxford, United Kingdom: Blackwell Publishing Ltd; 2010. p. 18.1-30.
9. Happle R, Mittag H, Küster W. What is a Nevus? A proposed definition of a common medical term. *Dermatology* 1995;191:1-5.
10. Moss C, Jones DO, Blight A, Bowden PE. Birthmark due to cutaneous mosaicism for keratin 10 mutation. *Lancet* 1995;345:596.
11. Paller AS. Expanding our concepts of mosaic disorders of skin. *Arch Dermatol* 2001;137:1236-8.
12. Stosiek N, Ulmer R, von den Driesch P, Claussen U, Hornstein OP, Rott HD. Chromosomal mosaicism in two patients with epidermal verrucous nevus. Demonstration of chromosomal breakpoint. *J Am Acad Dermatol* 1994;30:622-5.
13. Findlay GH, Moores PP. Pigment anomalies of the skin in the human chimaera: Their relation to systematized naevi. *Br J Dermatol* 1980;103:489-98.
14. Goudie RB, Jack AS, Goudie BM. 1985. Genetic and developmental aspects of pathological pigmentation patterns. In: Berry CL, editor. *Dermatopathology. Current Topics in Pathology*. Vol. 74. Berlin, Heidelberg: Springer. Available from: https://doi.org/10.1007/978-3-642-69574-2_3. [Last accessed on 23 2020 July]
15. Thomas IT, Frias JL, Cantu ES, Lafer CZ, Flannery DB, Graham JG Jr. Association of pigmentary anomalies with chromosomal and genetic mosaicism and chimerism. *Am J Hum Genet* 1989;45:193-205.
16. Tagra S, Talwar AK, Walia RS. Lines of Blaschko. *Indian J Dermatol Venereol Leprol* 2005;71:57-9.