

## Immunohistochemical study of STAT3, HIF-1 $\alpha$ and VEGF in pterygium and normal conjunctiva: Experimental research and literature review

Shiqi Dong,<sup>1</sup> Xiying Wu,<sup>1</sup> Yuting Xu,<sup>1</sup> Guohua Yang,<sup>2</sup> Ming Yan<sup>1</sup>

<sup>1</sup>Department of Ophthalmology, Zhongnan Hospital of Wuhan University, Wuhan, Hubei, China; <sup>2</sup>Demonstration Center for Experimental Basic Medicine Education of Wuhan University, Wuhan, Hubei, China

**Purpose:** Signal transducer and activator of transcription 3 (STAT3) is a DNA-binding protein that regulates various biologic processes, including cell growth, apoptosis, and malignant transformation. Abnormal activation of STAT3 is associated with many diseases, and there is currently no relevant study on the pathogenesis of pterygium. The purpose of this study was to investigate the expression and clinical significance of STAT3, HIF-1 $\alpha$ , and VEGF in pterygium at different stages.

**Methods:** Immunohistochemistry was used to study the expression levels of STAT3, HIF-1 $\alpha$ , and VEGF in 50 cases of pterygium and 20 cases of control conjunctival tissue. The expression intensity of the three proteins was evaluated with Image-Pro Plus 6.0 image analysis software.

**Results:** In the pterygium group, the positive rates for STAT3, HIF-1 $\alpha$ , and VEGF were 82.0%, 86.0%, and 84.0%, respectively, while those in the normal conjunctiva group were 40.0%, 25.0%, and 15.0%. The expression of STAT3, HIF-1 $\alpha$ , and VEGF in pterygium was higher than that in control conjunctiva, and the expression in advanced pterygium was statistically significantly higher than that in stationary pterygium ( $p < 0.01$ ). The expression levels of STAT3 and HIF-1 $\alpha$  in pterygium were related to the length and depth of the corneal invasion of pterygium. The expression level of VEGF in pterygium was related to the length of pterygium, but not to the depth. In addition, there was a significant positive correlation between the expression of STAT3, HIF-1 $\alpha$ , and VEGF ( $p < 0.01$ ).

**Conclusions:** For the first time, the expression levels of the STAT3, HIF-1 $\alpha$ , and VEGF proteins were detected simultaneously in pterygium tissue. Compared with normal conjunctiva, STAT3, HIF-1 $\alpha$ , and VEGF were highly expressed in pterygium, and the expression in advanced pterygium tissue was more significant than in the stationary pterygium tissue. It is suggested that STAT3 may directly or through HIF-1 $\alpha$  promote VEGF expression and participate in the growth and angiogenesis of pterygium. Targeting STAT3 may provide a new direction for the treatment of pterygium.

Pterygium, one of the most common ocular surface diseases, is characterized by the invasive growth of fibrovascular conjunctiva tissue extending on the corneal surface. In the early stage, pterygium often has no symptoms or only mild eye discomfort. In the later stage, pterygium can cause foreign body sensation, photophobia and tears, visual occlusion, corneal astigmatism, and other symptoms. For a long time, pterygium has attracted much attention because of its high prevalence rate and high recurrence rate after surgery [1]. However, the pathogenesis of pterygium remains unclear. Pterygium is the result of many factors, such as oxidative damage, apoptosis, lack of limbal stem cells, inflammation, etc. [2-4]. Angiogenesis plays a major role in the pathogenesis of pterygium, and vascular endothelial growth factor (VEGF) is the most powerful promoter of neovascularization. Hypoxia-inducible factor-1 (HIF-1) is a transcription factor that is directly involved in angiogenesis by mediating transcription-related genes and is involved in the regulation

of VEGF expression. Signal transducer and activator of transcription 3 (STAT3) is a family of highly homologous transcription factors, which mediates the signal transduction of various cytokines and growth factors to the nucleus, affects the transcription of target genes, and maintains and regulates a series of normal biologic behaviors, including embryonic development, programmed cell death, organogenesis, innate immunity, adaptive immunity, cell growth, etc. [5]. STAT3 is abnormally activated in many kinds of malignant tumors, such as ovarian cancer, lung cancer, etc. [6,7]. Increasing studies have shown that pterygium is a tumor-like proliferative lesion with tumor-like characteristics, such as excessive proliferation, mild dysplasia, local infiltration, high recurrence rate, etc. [8,9]. Therefore, we speculate that STAT3 also plays an important role in the occurrence of pterygium. In this study, the expression of STAT3, HIF-1 $\alpha$ , and VEGF in pterygium and normal conjunctival tissues at different stages was detected with immunohistochemistry. The purpose of this study was to investigate the role of STAT3, HIF-1 $\alpha$ , and VEGF in the course of pterygium and provide new ideas and theoretical basis for the treatment of pterygium.

Correspondence to: Ming Yan, Department of Ophthalmology, Zhongnan Hospital of Wuhan University, Wuhan, Hubei 430071, China; email: [yanming72@whu.edu.cn](mailto:yanming72@whu.edu.cn)

## METHODS

**Patients and study design:** Fifty primary pterygium samples and 20 normal conjunctival samples were recruited from patients at the Department of Ophthalmology, Zhongnan Hospital of Wuhan University, from April 2018 to December 2018. All patients with pterygium (28 men and 22 women) underwent excision combined with conjunctival autograft transplantation by the same ophthalmologist. The ages of the case group ranged between 35 and 77 years (mean age  $43.35 \pm 13.90$ ). All lesions were located on the nasal side, and only the fleshy part of the original pterygium was taken as the specimen. The control group tissue was collected from healthy bulbar conjunctiva of 20 patients (11 men and 9 women) without pterygium who had undergone strabismus or ocular trauma surgery, ages ranging between 18 and 68 years (mean age  $48.5 \pm 17.5$ ).

All patients with pterygium were divided into stationary and progressive stages through slit-lamp microscope examination before surgery by the same surgeon. The length of the pterygium was evaluated. In addition, the depth of the extension on the corneal surface of pterygium was measured with optical coherence tomography (OCT) at the anterior segment. A slit-lamp microscope examination showed that stationary pterygium is characterized by thinner pterygium tissue, less vascular tissue, mild hyperemia, and inconspicuous corneal infiltration. In contrast, progressive pterygium has obvious hyperemia, hypertrophy, and more blood vessels. In addition, the cornea is covered by white triangular hyperplastic tissue and notably corneal infiltration on the head. According to the length of pterygium invading the cornea, pterygium can be divided into two grades: grade I, tissue between the corneal limbus and pupillary margin; and grade II, tissue beyond the pupillary margin.

Except a topical anesthetic, none of the patients received any medication for the surgery, and no drugs or chemical agents were used during the surgical operation. The study was approved by the Medical Ethics Committee of Zhongnan Hospital of Wuhan University, and informed consent was obtained according to the World Medical Association Declaration of Helsinki. Complete information on patients was available in all cases.

**Immunohistochemistry staining:** All samples were fixed for 30 min *in vitro* with a general tissue fixation solution (4% paraformaldehyde and PB buffer). The tissues were removed from the fixation solution and soaked in 75%, 85%, 95%, and 100% ethanol for 3 h, respectively. Then xylene was used 3 times for 10 min each time to make the tissues transparent. The transparent tissue blocks were put in paraffin wax, and the tissue wax blocks were quickly placed in the

embedder after being soaked. After the tissue wax blocks were completely solidified, slicing could begin. The paraffin blocks were installed on the slicer and sliced along the long axis of the specimen. Each specimen was sectioned continuously with a thickness of 3  $\mu\text{m}$ . The method employed for the immunohistochemical tests was the streptavidin-peroxidase (SP) technique. The sections were dewaxed and dehydrated in gradient alcohol and xylene. The tissue sections were completely soaked in citric acid antigen repair buffer (PH6.0; Wuhan servicebio technology, Wuhan, China, G1202), and then placed in the microwave oven. First use medium heat 8 min to boil, then cease fire 8 min and then turn to medium and low heat for 7 min. After natural cooling, wash fully with phosphate buffered saline (PBS, pH7.4, at room temperature; Wuhan servicebio technology, Wuhan, China, G0002). Subsequently, the sections were incubated in 3% hydrogen peroxide solution at room temperature and away from light for 25 min to eliminate endogenous peroxidase activity. To avoid non-specific binding, the sections were incubated with goat serum (Wuhan servicebio technology, G5001) for 30 min and then immersed with the primary antibodies at 4 °C overnight. Rabbit polyclonal anti-VEGF antibody (1:100, ABclonal, A0280, China), polyclonal anti-HIF-1 $\alpha$  antibody (1:100, ABclonal, A7684, China) and polyclonal anti-STAT3 antibody (1:100, ABclonal, A15729, China) were used as the primary antibodies. Next, the tissues were covered with secondary antibody (horseradish peroxidase mark) and incubated at room temperature for 50 min. The immunoreactions were visualized by 3, 3'-diamino-benzidine (DAB). Finally, the sections were counterstained with Mayer's hematoxylin solution, dehydrated, and mounted. Negative controls were obtained by replacing the primary antibody with PBS. Breast cancer tissue sections known to have high expression of STAT3, HIF-1, and VEGF were used as positive control. Cells dark stained into brown showed positive expression.

**Semiquantitative analysis of the immunohistochemical results:** Immunohistochemical results were analyzed by Image-Pro Plus 6.0 software (Media Cybernetics, Rockville, MD). Five non-overlapping fields were randomly selected for each section under a 40-fold objective lens, and images were collected. All images were collected at the same exposure time and white balance settings, and the blank area of the image was selected for optical density correction. The brownish yellow particles in the cytoplasm were considered the positive expression of STAT3, HIF-1 $\alpha$ , and VEGF, and the expression intensity was measured by the cumulative value of the integral optical density (IOD) and the area of the target region (Area). Finally, the average density (IOD / Area) of the five fields (MD) was used as the analysis index to reflect the protein expression. The  $\bar{\text{MD}}$  of all samples were divided



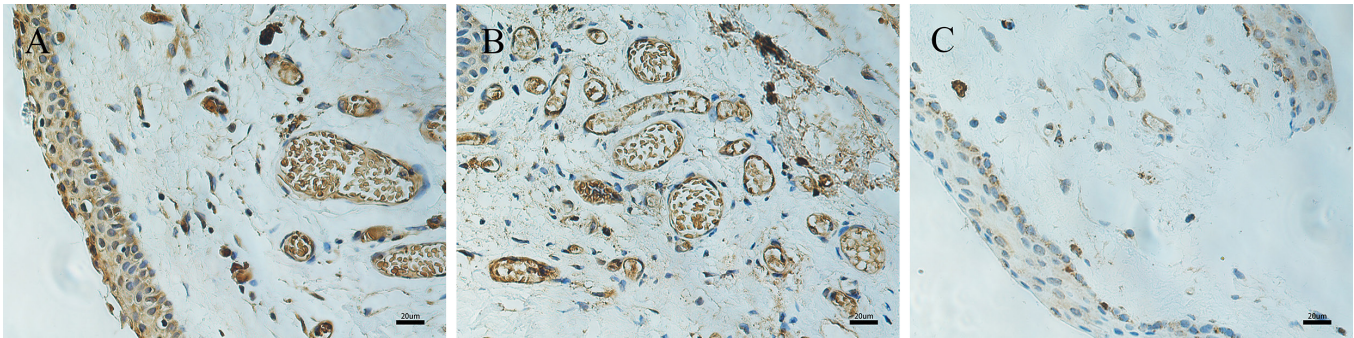


Figure 1. Immunohistochemical expression of STAT3 in pterygium and normal conjunctiva. Immunohistochemical expression of STAT3 in pterygium (A–B) and normal conjunctiva (C). A: STAT3 appears to be strongly positive expressed in the cytoplasm of the endothelial cells of blood vessels, epithelial cells, and stromal inflammatory tissue. B: A large number of STAT3-positive vessels in pterygium tissue. C: Epithelial cells with weak cytoplasmic immunoreactivity are detected mainly in control conjunctival samples (400X, bar = 20 µm).

into four grades according to the maximum value of  $\bar{M}D$ , which was non-expression (0,  $\bar{M}D_{\max} \times 10\%$ ), low expression ( $\bar{M}D_{\max} \times 10\%$ ,  $\bar{M}D_{\max} \times 40\%$ ), middle expression ( $\bar{M}D_{\max} \times 40\%$ ,  $\bar{M}D_{\max} \times 70\%$ ), and high expression ( $\bar{M}D_{\max} \times 70\%$ ,  $\bar{M}D_{\max}$ ).

**Statistical analysis:** The experimental data were analyzed by SPSS 23.0 statistical software (SPSS Inc., Chicago, IL). The measurement data were expressed as mean  $\pm$  standard deviation. The expression level of STAT3, HIF-1 $\alpha$ , and VEGF in the groups was tested with a Student *t* test, the Mann–Whitney test was used to compare the different grades, and the correlation between STAT3, HIF-1 $\alpha$ , and VEGF was analyzed with Spearman correlation analysis. A *p* value of less than 0.05 was considered significantly significant.

## RESULTS

**Differential expression of STAT3, HIF-1 $\alpha$ , and VEGF:** Immunohistochemical images of positive localization of STAT3, VEGF, and HIF-1 $\alpha$  in pterygium and normal conjunctiva are shown in Figure 1, Figure 2, and Figure 3. In the pterygium samples, the positive staining of the three proteins was mostly located in the epithelial cytoplasm, a small amount of positive staining in the nucleus was brown, and positive staining could also be seen in some neovascularization endothelial cells in the stroma layer. However, the expression in the normal conjunctiva was weakly positive or negative.

The  $\bar{M}D$  values of the STAT3, HIF-1 $\alpha$ , and VEGF proteins in the pterygium group were considerably higher than those in the normal conjunctival group, and the differences were statistically significant (*p* < 0.001). Among the 50 cases of pterygium, there were 38 cases of pterygium in advanced stage and 12 cases of pterygium in stationary stage. The  $\bar{M}D$  values of the three proteins in the group of

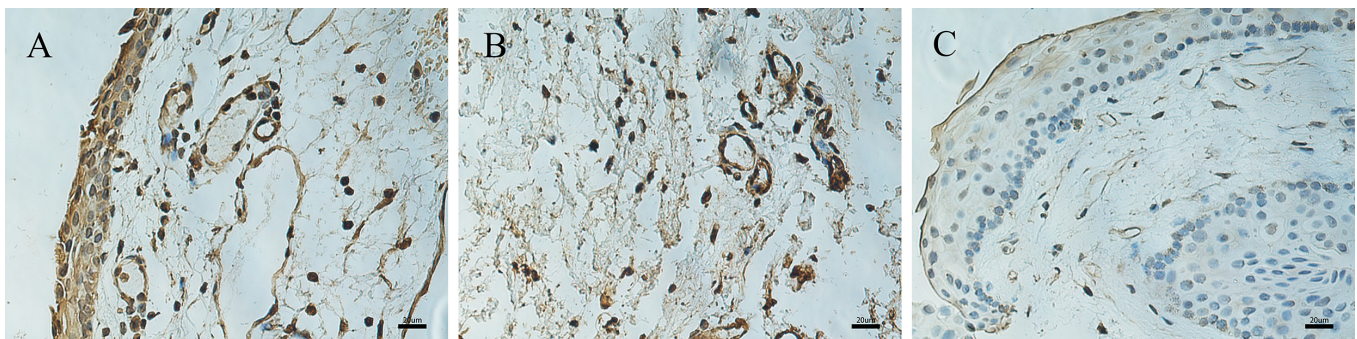


Figure 2. Immunohistochemical expression of HIF-1 $\alpha$  in pterygium and normal conjunctiva. Immunohistochemical expression of HIF-1 $\alpha$  in pterygium (A–B) and normal conjunctiva (C). A: Strong nuclear and cytoplasmic immunoreactivity in all epithelial layers of the pterygium sample. B: A large number of vascular endothelial cells in the stromal layer show brown positive staining. C: Weak cytoplasmic immunoreactivity is detected in the control conjunctival sample (400X, bar = 20 µm).

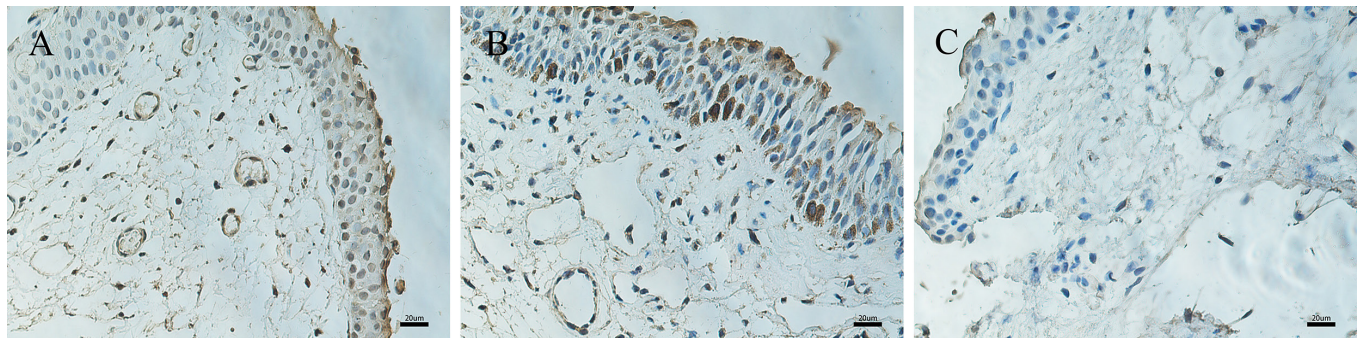


Figure 3. Immunohistochemical expression of VEGF in pterygium and normal conjunctiva. Immunohistochemical expression of VEGF in pterygium (A–B) and normal conjunctiva (C). A: Epithelial and stromal layers display moderate VEGF immunoreactivity. B: There is moderate to strong nuclear immunoreactivity in the basal layers of epithelial cells. C: There is almost no positive expression in control conjunctival tissue (400X, bar = 20 μm).

advanced pterygium were higher than those of stationary pterygium. The difference was statistically significant ( $p < 0.05$ ; Table 1). All positive expression levels were classified into four levels according to the maximum value of MD, as shown in Table 2. In the pterygium group, the positive rates of STAT3, HIF-1 $\alpha$ , and VEGF were 82.0% (41/50), 86.0% (43/50), and 84.0% (42/50), respectively, and the positive rates of the normal conjunctiva group were 40.0% (8/20), 25.0% (5/20), and 15.0% (3/20), respectively. The Mann–Whitney U test was used to compare the expression of STAT3, HIF-1 $\alpha$ , and VEGF between groups. The expression of three proteins in the pterygium group was statistically significantly higher than that in the normal conjunctiva group, and the expression of the three proteins in the progressive pterygium group was statistically significantly higher than that in the stationary pterygium group ( $p < 0.05$ ).

*Relationship between the expression of STAT3, HIF-1 $\alpha$ , and VEGF and the clinical features of pterygium:* The results showed that the expression levels of STAT3, HIF-1 $\alpha$ , and VEGF in the pterygium length grade II group were statistically significantly higher than those in the pterygium length grade I group ( $p < 0.05$ ). The expression levels of STAT3 and HIF-1 $\alpha$  in the pterygium depth  $\geq 100$  μm group were significantly higher than those in the pterygium depth  $< 100$  μm group ( $p < 0.05$ ). However, interestingly, there was no statistically significant difference in the expression level of VEGF between pterygium length and depth ( $p = 0.084 > 0.05$ ; Table 3). In conclusion, the expression levels of STAT3 and HIF-1 $\alpha$  in pterygium were related to the length and depth of the corneal invasion of pterygium. The expression level of VEGF in pterygium was related to the length of pterygium, but not to the depth of pterygium.

TABLE 1. RESULTS OF THE IMMUNOHISTOCHEMICAL ANALYSIS FOR STAT3, HIF-1A AND VEGF ( $\sim$ MD $\times 10^3$ ).

| Group                 | Number | STAT3              | HIF-1 $\alpha$     | VEGF               |
|-----------------------|--------|--------------------|--------------------|--------------------|
| pterygium             | 50     | 6.99 $\pm$ 4.53*** | 7.13 $\pm$ 6.08*** | 7.06 $\pm$ 4.84*** |
| progressive pterygium | 38     | 7.90 $\pm$ 4.76**  | 8.12 $\pm$ 6.62**  | 7.88 $\pm$ 5.24**  |
| stationary pterygium  | 12     | 4.11 $\pm$ 1.71    | 3.98 $\pm$ 1.84    | 4.47 $\pm$ 1.63    |
| normal conjunctiva    | 20     | 2.60 $\pm$ 1.54    | 1.88 $\pm$ 1.09    | 2.08 $\pm$ 0.93    |

TABLE 2. EXPRESSION OF VEGF, HIF-1A AND STAT3 IN PTERYGIUM SUBGROUPS AND CONTROL GROUP.

| Group/Grade | STAT3 (n) |    |    |     | HIF-1 $\alpha$ (n) |    |    |     | VEGF (n) |    |    |     |
|-------------|-----------|----|----|-----|--------------------|----|----|-----|----------|----|----|-----|
|             | —         | +  | ++ | +++ | —                  | +  | ++ | +++ | —        | +  | ++ | +++ |
| pterygium   | 9         | 26 | 12 | 3   | 7                  | 33 | 5  | 5   | 8        | 36 | 5  | 1   |
| progressive | 5         | 18 | 12 | 3   | 4                  | 24 | 5  | 5   | 5        | 27 | 5  | 1   |
| stationary  | 4         | 8  | 0  | 0   | 3                  | 9  | 0  | 0   | 3        | 9  | 0  | 0   |
| conjunctiva | 12        | 8  | 0  | 0   | 15                 | 5  | 0  | 0   | 17       | 3  | 0  | 0   |



*Correlations among the expression of STAT3, HIF-1 $\alpha$ , and VEGF in pterygium:* The Spearman rank correlation test showed a positive correlation between the expression of VEGF and HIF-1 $\alpha$  in pterygium ( $r = 0.547$ ,  $p < 0.001$ ), a positive correlation between VEGF and STAT3 ( $r = 0.396$ ,  $r = 0.004$ ), and a positive correlation between HIF-1 $\alpha$  and STAT3 ( $r = 0.628$ ,  $p < 0.001$ ). In other words, the expression of three proteins is positively correlated with each other.

## DISCUSSION

Neovascularization plays a major role in the proliferation of pterygium, which may promote the transformation from the quiescent stage to the progressive stage of pterygium. VEGF is a specific heparin-binding growth factor acting on vascular endothelial cells, which promotes endothelial cell proliferation and migration by binding to specific receptors on vascular endothelial cells, thus stimulating angiogenesis [10]. In addition, VEGF can increase vascular permeability through paracrine mechanism, which is beneficial to the growth of neovascularization and stromal cells. Hoyama et al. [11] used immunohistochemistry to analyze the expression of VEGF in pterygium tissues and control pterygium conjunctival cells before and after exposure with 5-fluorouracil and found endothelial cells of pterygium had a higher VEGF expression while 5-fluorouracil did not affect VEGF expressions. Our study found that the expression of VEGF was positively correlated with the length of pterygium corneal invasion and there was no significant difference in the expression of pterygium at different depth of extending on the corneal surface of pterygium. The latter was not consistent with our expectation. There may be three reasons for this. First, it may be due to the insufficient sample size and inaccurate measurement of the depth of extending on the corneal surface of pterygium resulting in the deviation of the experimental results. Secondly, some studies have shown that the expression of cell proliferation-related proteins such as KI-67 and PCNA in pterygium tissue is higher in the head of pterygium than in the body of pterygium [12]. That is to say, the proliferation and invasion ability of the head of pterygium is higher than that of the body of pterygium. VEGF is mainly

related to angiogenesis and the depth of tissue growth may be more closely related to the invasiveness of the tissue. Finally, some studies using corneal alkali burn model to observe corneal angiogenesis found that VEGF began to express on the third day after corneal burn and reached a peak at 7 day – 14 day, then it began to decline [13,14]. We speculate that in the case of chronic tissue hypoxia and inflammation, the expression of VEGF is regulated by multiple factors and may be in a state of dynamic equilibrium. It tends to be stable after the tissue growth reaches a certain stage. Therefore, there is no significant difference in the expression of VEGF in pterygium in different depth.

HIF-1 is a nuclear protein with transcriptional activity produced by cells in an anoxic environment. It has more than 60 target genes involved in biological processes such as apoptosis, angiogenesis, tumor proliferation and metastasis. VEGF is one of its downstream genes. In this study, we found that the expression of HIF-1 $\alpha$  in pterygium was significantly higher than that in normal conjunctiva. May et al. [15] found that hypoxia can promote the activation of HIF-1 and the transcription of VEGF in active proliferative tissues, thus activating a series of hypoxia signal transduction pathways and promoting neovascularization and tumorigenesis. Recent studies have shown that the expression of VEGF seems to be regulated by a dual interdependence mechanism directly and indirectly related to HIF-1, which is closely related to the NF-kappaB-mediated COX-2 expression and PGE production [16]. And most importantly, based on the degree of hypoxia, HIF-1 has both pro-apoptotic and anti-apoptotic regulatory effects on apoptosis. During mild hypoxia, HIF-1 $\alpha$  can bind to the  $\beta$  subunit and inhibit apoptosis by activating the transcription of its target gene, reducing the proportion of Bax/Bcl-2 and reducing the activity of Caspase-3. In severe hypoxia, HIF-1  $\alpha$  binds to p53, which stabilizes p53 and promotes apoptosis [17]. Based on the above research, we speculate that in pterygium the activation of HIF-1  $\alpha$  maybe not only the result of hypoxia but also the result of hypoxia independent mechanisms, such as oncogene activation and growth factor signal pathway. HIF-1 $\alpha$  may be involved in the transformation of the stationary phase and the progressive phase of pterygium disease course by its dual effects of

**TABLE 3. RELATIONSHIPS BETWEEN THE CLINICAL CHARACTERISTICS OF PTERYGIUM AND THE EXPRESSIONS OF STAT3, HIF-1A, AND VEGF.**

| Group          | The length of invading the limbus |                    |        | The depth of invading the cornea |                  |        |
|----------------|-----------------------------------|--------------------|--------|----------------------------------|------------------|--------|
|                | Grade I (16cases)                 | Grade II (34cases) | P      | <100um (27cases)                 | ≥100um (23cases) | P      |
| STAT3          | 3.27±1.46                         | 8.74±4.43          | <0.001 | 3.97±1.81                        | 10.53±4.18       | <0.001 |
| HIF-1 $\alpha$ | 3.44±1.58                         | 8.86±6.65          | <0.001 | 5.23±4.74                        | 9.36±6.81        | 0.015  |
| VEGF           | 4.17±1.60                         | 8.42±5.27          | 0.003  | 5.97±3.52                        | 8.34±5.87        | 0.084  |

different activation degrees and apoptosis. But its specific mechanism remains to be confirmed by further studies. In conclusion, our study shows that HIF-1 $\alpha$  is involved in the occurrence and development of pterygium. Further study of its mechanism is of great significance for finding a safer and more effective small-molecule drug for the treatment of pterygium.

STAT3 are DNA-binding proteins that can be activated by many cytokines, growth factors and other factors to induce gene transcriptional regulation. Abnormal activation of STAT3 can lead to a variety of diseases [18], which is an indispensable key molecule in the process of chronic inflammation promoting tumorigenesis and tumor-associated inflammation [19], and can be used as a potential drug target [20]. Furthermore, studies have confirmed that STAT3 activation is essential in the basic expression of HIF-1 and growth factor-induced expression, that is, STAT3 and HIF-1 jointly activate the HIF-1 target gene and drive tumor development [21]. In addition, STAT3 is a direct transcriptional activator of VEGF genes, and there is a binding site of STAT3 on VEGF promoter, which can directly bind to the promoter of VEGF and up-regulate the expression of VEGF in tumor cells [22]. In our study, spearman level correlation analysis showed that there was a positive correlation among STAT3, HIF-1 and VEGF in pterygium. In addition, Epithelial-mesenchymal transformation (EMT) refers to the biological process in which epithelial cells change to stromal cell phenotype through specific procedures. Many studies have shown that the expression of EMT marker vimentin and smooth muscle actin,  $\alpha$ -SMA in pterygium is higher than that in normal conjunctiva, suggesting that EMT is involved in the occurrence and progression of pterygium [23,24]. In recent years, large number of studies have shown that STAT3 in tumor cells is activated by growth factors and cytokines to promote EMT by inhibiting the expression of E-Cadherin [25-27]. Interestingly, when STAT3 acts as a molecular adapter rather than a transcription factor, it can promote ubiquitination of Snail by activating GSK-3 $\beta$ , down-regulate the expression of Snail, and then inhibit EMT [28]. In conclusion, we speculate that STAT3 may directly or indirectly up-regulate the expression of VEGF by regulating HIF to participate in the occurrence and development of pterygium. And the double regulation of STAT3 on EMT under different conditions is involved in the transformation of the pterygium in the quiescent stage and the progression stage. The specific mechanism needs to be confirmed by further studies.

All in all, this study for the first time found that the expression of STAT3 was increased in pterygium, and the expression level was positively correlated with HIF-1 $\alpha$  and

VEGF suggest that STAT3 may be involved in the occurrence and progression of pterygium through STAT3/HIF/VEGF pathway. In addition, the dual effects of STAT3 on EMT and HIF-1 $\alpha$  on apoptosis may play an important role in the transformation between quiescent and progressive pterygium. Additionally, this study uses Image-Pro Plus software to analyze the immunohistochemical results. Compared with the previous visual assessment of the positive staining intensity, this method is more accurate and objective. But only using immunohistochemical method to study the qualitative and semi-quantitative expression of STAT3 in pterygium may cause not rigorous results. In the future, we will further supplement PCR, western blot and other experiments to further verify the expression of STAT3. And in vitro cell experiments also will be done to further explore the specific mechanism of STAT3 on endothelial cell proliferation and migration. In-depth study of the mechanism of STAT3 in pterygium will be of great significance to optimize its treatment.

#### ACKNOWLEDGMENTS

Funding. This research was supported by the National Natural Science Foundation of China (No.81770898).

#### REFERENCES

1. Kim KW, Kim JC. Current approaches and future directions in the management of pterygium. *Int J Ophthalmol* 2018; 11:709-11. [PMID: 29862166].
2. Cui YH, Li HY, Gao ZX, Liang N, Ma SS, Meng FJ, Li ZJ, Pan HW. Regulation of Apoptosis by miR-122 in Pterygium via Targeting Bcl-w. *Invest Ophthalmol Vis Sci* 2016; 57:3723-30. [PMID: 27415790].
3. Malozhen SA, Trufanov SV, Krakhmaleva DA. Pterygium: etiology, pathogenesis, treatment. *Vestn Oftalmol* 2017; 133:76-83. [PMID: 29165417].
4. Feng QY, Hu ZX, Song XL, Pan HW. Aberrant expression of genes and proteins in pterygium and their implications in the pathogenesis. *Int J Ophthalmol* 2017; 10:973-81. [PMID: 28730091].
5. Lv J, Sun B. STAT3 potentiates the ability of airway smooth muscle cells to promote angiogenesis by regulating VEGF signalling. *Exp Physiol* 2017; 102:598-606. [PMID: 28295786].
6. Liang R, Chen X, Chen L, Wan F, Chen K, Sun Y, Zhu X. STAT3 signaling in ovarian cancer: a potential therapeutic target. *J Cancer* 2020; 11:837-48. [PMID: 31949487].
7. Sun W, Hu S, Zu Y, Deng Y. KLF3 is a crucial regulator of metastasis by controlling STAT3 expression in lung cancer. *Mol Carcinog* 2019; 58:1933-45. [PMID: 31486564].

8. Liu T, Liu Y, Xie L, He X, Bai J. Progress in the pathogenesis of pterygium. *Curr Eye Res* 2013; 38:1191-7. [PMID: 24047084].
9. Ljubojevic V, Gajanin R, Amidzic L, Vujkovic Z. The expression and significance of p53 protein and Ki-67 protein in pterygium. *Vojnosanit Pregl* 2016; 73:16-20. [PMID: 26964379].
10. Apte RS, Chen DS, Ferrara N. VEGF in Signaling and Disease: Beyond Discovery and Development. *Cell* 2019; 176:1248-64. [PMID: 30849371].
11. Hoyama E, Viveiros MM, Shiratori C, de Oliveira DE, Pado-vani CR, Selva D, Schellini SA. Expression of vascular endothelial growth factor (VEGF) in macrophages, fibroblasts, and endothelial cells in pterygium treated with 5-Fluorouracil. *Semin Ophthalmol* 2015; 30:171-6. [PMID: 24171833].
12. Li J, Li N, Wang JF, Li N. Expressions of Bcl-2, Bax and Ki67 in the primary pterygium. *International Eye Science* 2018; 18:960-2. .
13. Wang Q, Jiang YM, Zhao J, Hou BJ, Lu M, Huang YF. Inhibitory effects of anti-vascular endothelial growth factor (VEGF) antibody MIL60 on alkali- induced corneal angiogenesis in rats. *Recent Advances in Ophthalmology* 2017; 37:1010-4. .
14. Fu YC, Xin ZM. Inhibited corneal neovascularization in rabbits following corneal alkali burn by double-target interference for VEGF and HIF-1 $\alpha$ . *Biosci Rep* 2019; 39:.
15. May D, Itin A, Gal O, Kalinski H, Feinstein E, Keshet E. Ero1-L alpha plays a key role in a HIF-1-mediated pathway to improve disulfide bond formation and VEGF secretion under hypoxia: implication for cancer. *Oncogene* 2005; 24:1011-20. [PMID: 15592500].
16. Lukiw WJ, Ottlecz A, Lambrou G, Grueninger M, Finley J, Thompson HW, Bazan NG. Coordinate activation of HIF-1 and NF-kappaB DNA binding and COX-2 and VEGF expression in retinal cells by hypoxia. *Invest Ophthalmol Vis Sci* 2003; 44:4163-70. [PMID: 14507857].
17. Ye XW, Zhang XP, Liu F. CSB modulates the competition between HIF-1 and p53 upon hypoxia. *Mathematical biosciences and engineering MBE* 2019; 16:5247-62. [PMID: 31499711].
18. Yuan J, Zhang F, Niu R. Multiple regulation pathways and pivotal biological functions of STAT3 in cancer. *Sci Rep* 2015; 5:17663-[PMID: 26631279].
19. Fleming JD, Giresi PG, Lindahl-Allen M, Krall EB, Lieb JD, Struhl K. STAT3 acts through pre-existing nucleosome-depleted regions bound by FOS during an epigenetic switch linking inflammation to cancer. *Epigenetics Chromatin* 2015; 8:7-[PMID: 25784959].
20. Hu YS, Han X, Liu XH. STAT3: A Potential Drug Target for Tumor and Inflammation. *Curr Top Med Chem* 2019; 19:1305-17. [PMID: 31218960].
21. Pawlus MR, Wang L, Hu CJ. STAT3 and HIF1alpha cooperatively activate HIF1 target genes in MDA-MB-231 and RCC4 cells. *Oncogene* 2014; 33:1670-9. [PMID: 23604114].
22. Zhu M, Liu X, Wang Y, Chen L, Wang L, Qin X, Xu J, Li L, Tu Y, Zhou T, Sang A, Song E. YAP via interacting with STAT3 regulates VEGF-induced angiogenesis in human retinal microvascular endothelial cells. *Exp Cell Res* 2018; 373:155-63. [PMID: 30342005].
23. Nubile M, Curcio C, Lanzini M, Calienno R, Iezzi M, Mastropasqua A, Di Nicola M, Mastropasqua L. Expression of CREB in primary pterygium and correlation with cyclin D1, ki-67, MMP7, p53, p63, Survivin and Vimentin. *Ophthalmic Res* 2013; 50:99-107. [PMID: 23838680].
24. Zhao XR, Zhang MC, Xie HT, Ji N, Ma XQ. Expression of mTOR in Primary Pterygium and its Correlation with alpha-Smooth Muscle Actin. *Eur J Ophthalmol* 2017; 27:664-9. [PMID: 28623647].
25. Nakada S, Kuboki S, Nojima H, Yoshitomi H, Furukawa K, Takayashiki T, Takano S, Miyazaki M, Ohtsuka M. Roles of Pin1 as a Key Molecule for EMT Induction by Activation of STAT3 and NF-kappaB in Human Gallbladder Cancer. *Ann Surg Oncol* 2019; 26:907-17. [PMID: 30610554].
26. Wang T, Lin F, Sun X, Jiang L, Mao R, Zhou S, Shang W, Bi R, Lu F, Li S. HOXB8 enhances the proliferation and metastasis of colorectal cancer cells by promoting EMT via STAT3 activation. *Cancer Cell Int* 2019; 19:3-[PMID: 30622439].
27. Zeng YT, Liu XF, Yang WT, Zheng PS. REX1 promotes EMT-induced cell metastasis by activating the JAK2/STAT3-signaling pathway by targeting SOCS1 in cervical cancer. *Oncogene* 2019; 38:6940-57. [PMID: 31409905].
28. de Jong PR, Mo JH, Harris AR, Lee J, Raz E. STAT3: An Anti-Invasive Factor in Colorectal Cancer? *Cancers (Basel)* 2014; 6:1394-407. [PMID: 24995503].

Articles are provided courtesy of Emory University and the Zhongshan Ophthalmic Center, Sun Yat-sen University, P.R. China. The print version of this article was created on 26 July 2020. This reflects all typographical corrections and errata to the article through that date. Details of any changes may be found in the online version of the article.