

Surgical Technique

Metal markers for radiographic visualization of rotator cuff margins: A new technique for radiographic assessment of cuff repair integrity

Deepak N. Bhatia, Joe F. De Beer¹

ABSTRACT

Surgically repaired rotator cuff repairs may re-tear in the post-operative follow-up phase, and periodic imaging is useful for early detection. The authors describe a simple surgical technique that provides a visible clue to the tendon edge on an anteroposterior radiograph of the shoulder. The technique involves arthroscopic or mini-open radio-opaque tagging of the tendon edge using a metal marker, and followed by a double-row rotator cuff repair using suture anchors. Serial post-operative radiographs may then be used to monitor the position of the marker. Progressive or marked displacement of the marker suggests a failure of cuff repair integrity and should be evaluated further.

Key words: Arthroscopic repair, double-row repair, rotator cuff, shoulder surgery

INTRODUCTION

Rotator cuff tendon tears occur frequently, and surgical repair of the torn tendons is often necessary to relieve symptoms and restore function. Approximately, 15-20% of the repairs may re-tear, and regular radiological monitoring may be necessary in post-operative period for early detection and treatment of these failed repairs.^[1,2] We describe a simple technique of radio-opaque marking of the rotator cuff margins using metal markers during surgical repair of the tears; the markers can be monitored on simple radiographs, and on sonography, and failure in cuff repair integrity may be diagnosed at an early stage.

SURGICAL TECHNIQUE

The technique can be performed using both mini-open and arthroscopic techniques. The patient is positioned in the beach-chair position, and a standard posterior portal is used to evaluate the tear pattern and associated lesions.

If a mini-open technique is used, a 2-inch incision is used along Langers' lines, and the deltoid muscle is split between its anterior and middle segments. The torn rotator cuff tendons are exposed, and the frayed edges are debrided. The footprint of the tendons along the greater tuberosity is prepared, and medial and lateral row anchors are placed. Medial sutures are passed in a mattress configuration through the tendons, and lateral sutures are passed as simple sutures, or in a Mason-Allen configuration.

Prior to suture knot tying, the healthy tendon edge is marked with a metal marker. The marker may be prepared using a metal wire that may be passed through the tendon edge and twisted around to form a closed loop; this is possible when a mini-open deltoid-splitting approach is utilized. Alternately, titanium hemostatic clips may be used; these may be clamped over the tendon edge using special forceps, and this may be performed as an arthroscopic procedure. Secure placement of the marker

Access this article online

Website:

www.internationalshoulderjournal.org

DOI:

10.4103/0973-6042.109898

Quick Response Code:



Department of Orthopaedic Surgery, Seth GS Medical College, and King Edward VII Memorial Hospital, Parel, Mumbai, India, ¹Cape Shoulder Institute, Suite no. 4, Medgroup Anlin House, 43 Blouelie Crescent, Platteklouf, PO box 15741, Panorama 7506, Cape Town, South Africa

Address for correspondence:

Dr. Deepak N. Bhatia,
Department of Orthopaedic Surgery,
Seth GS Medical College, and King
Edward VII Memorial Hospital,
Parel, Mumbai - 400 012, India.
E-mail: thebonesmith@gmail.com

Please cite this article as: Bhatia DN, De Beer JF. Metal markers for radiographic visualization of rotator cuff margins: A new technique for radiographic assessment of cuff repair integrity. *Int J Shoulder Surg* 2013;7:37-9.

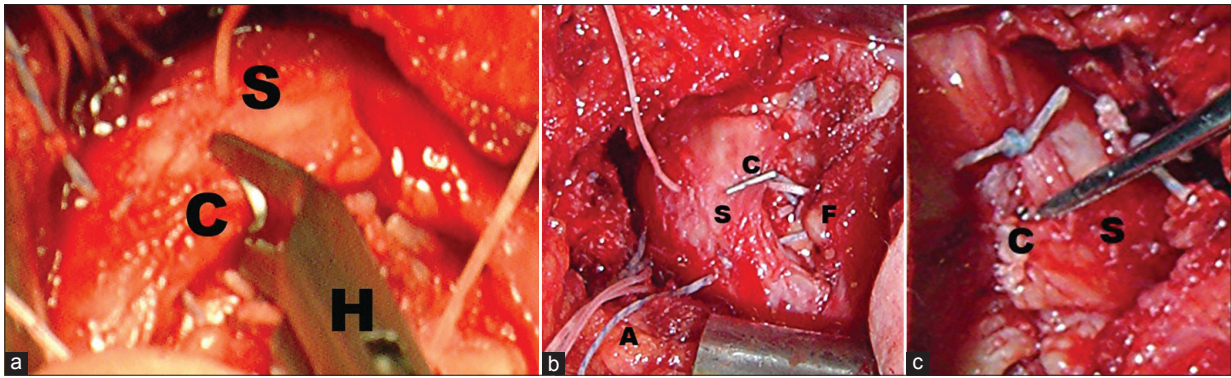


Figure 1: Intraoperative images show the technique of radio-opaque marking of the torn cuff tendon. (a) A special instrument is used to grasp the titanium clip during the procedure, (b) The position of the clip is shown prior to tying the medial and lateral row sutures, (c) The final position of the clip is shown after tying the sutures from the medial and lateral row anchors. (C: Clip, S: Supraspinatus, H: Grasping forceps, F: Rotator cuff footprint, A: Sutures from anchors)

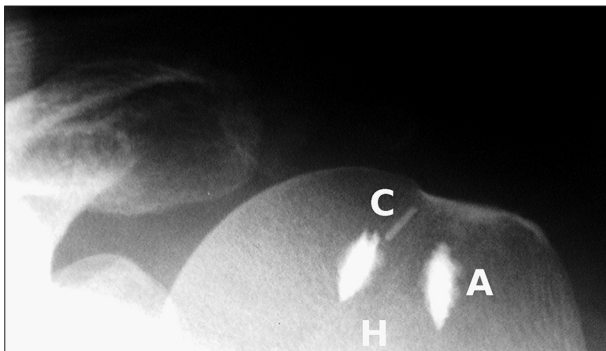


Figure 2: Immediate post-operative radiograph demonstrates the position of the metal marker (C) relative to the anchors (A) and humeral head (H)

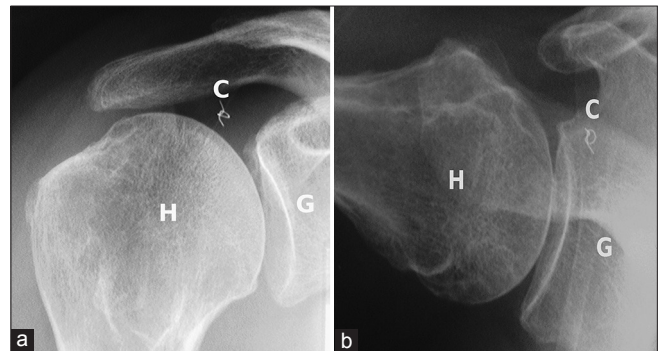


Figure 3: Anteroposterior (a) and axillary-lateral radiographs (b) show the medialized position of the metal marker (C), and are suggestive of failure of repair. (H: Humeral head, G: Glenoid)

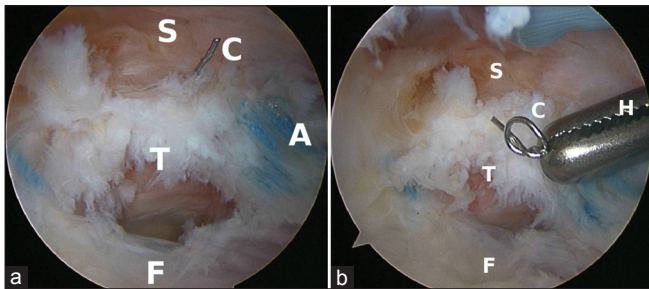


Figure 4: (a) Arthroscopic evaluation of a failed cuff repair shows the torn tendon (T) of the supraspinatus (S), and the metal marker (C) is seen attached to the torn edge of the cuff. (F: Cuff footprint, A: Sutures from anchors), (b) Arthroscopic retrieval of the metal marker (C) is shown prior to final repair. (F: Cuff footprint, A: Sutures from anchors, S: Supraspinatus, T: Cuff tear)

is crucial to prevent post-operative dislodgement, and it is useful to test the security with a probe. Thereafter, the medial and lateral sutures are tied; the double-row repair configuration adds to the fixation of the marker, and this is now securely placed between the tendon and the rotator cuff footprint [Figure 1a-c].

The post-operative rehabilitation protocol is similar to that of a double-row rotator cuff repair.^[1] In the immediate post-operative

period, an anteroposterior shoulder radiograph is obtained with the shoulder in neutral rotation and the arm by the side, and the position of the metal marker is documented for future reference [Figure 2]. Thereafter, a simple anteroposterior radiograph may be obtained at any time in the post-operative and follow-up visits to evaluate the position of the marker. The usual protocol is to obtain a true anteroposterior radiograph at 3 weeks and 6 weeks after surgery to detect early failures of repair that may be diagnosed in this period. Thereafter, 3-6 monthly radiographs or sonography may be performed to monitor cuff integrity. The follow-up radiographs are compared to the immediate post-operative radiograph, and displacement of the marker from the medial edge of the greater tuberosity footprint is measured. Significant displacement of the marker on early radiographs or progressive displacement on successive radiographs is indication for further evaluation and treatment [Figure 3a and b]. Revision surgery for failed repairs has shown that the marker remains attached to the torn tendon, and is easily retrieved without additional damage to the cuff [Figure 4a and b].

DISCUSSION

Surgically repaired rotator cuff repairs may fail to heal or re-tear in the post-operative and rehabilitation periods, and regular periodic imaging is useful to detect these failures.^[3]

Magnetic resonance imaging is the ideal modality; however, this may not be available readily and costs involved are often prohibitive. Ultrasonography is non-invasive, and may be the preferred mode of regular imaging of rotator cuff repairs; however, ultrasonography is operator dependent, and useful in experienced hands.^[4,5] The radiographic technique described here is simple, and re-tears can be detected on simple radiographs that may be obtained readily. Further studies are necessary to analyze the utility and cost-effectiveness of this technique in comparison to other modalities.

REFERENCES

1. Huijsmans PE, Pritchard MP, Berghs BM, van Rooyen KS, Wallace AL, de Beer JF. Arthroscopic rotator cuff repair with double-row fixation. *J Bone Joint Surg Am* 2007;89:1248-57.
2. Strauss EJ, McCormack RA, Onyekwelu I, Rokito AS. Management of failed arthroscopic rotator cuff repair. *J Am Acad Orthop Surg* 2012;20:301-9.
3. Kluger R, Bock P, Mittlböck M, Krampla W, Engel A. Long-term survivorship of rotator cuff repairs using ultrasound and magnetic resonance imaging analysis. *Am J Sports Med* 2011;39:2071-81.
4. Ok JH, Kim YS, Kim JM, Yoo TW. Learning curve of office-based ultrasonography for rotator cuff tendons tears. *Knee Surg Sports Traumatol Arthrosc.* 2012 Jun 27. [Epub ahead of print].
5. de Beer J, Bhatia DN. Shoulder sonography: Diagnostic and interventional utility. *Int J Shoulder Surg* 2010;4:51-4.

Source of Support: Nil, **Conflict of Interest:** None declared.