

Case Report

COVID-19 presenting with spontaneous massive pneumomediastinum in a three-month-old child

V. Sinclair,¹  I. Sharieff,² B. Gaskell² and A. McKechnie³

1 Specialty Trainee, 2 Specialty Doctor, 3 Consultant, Department of Anaesthesia, Lewisham and Greenwich NHS Trust, London, UK

Summary

A three-month-old child presented to our district general hospital with acute respiratory distress. He was found to have massive spontaneous pneumomediastinum and extensive surgical emphysema overlying the neck. Tracheal intubation using the GlideScope® was difficult, and the patient's trachea was ultimately intubated with a direct laryngoscope. Computed tomography revealed bilateral lung consolidation and reverse transcriptase-polymerase chain reaction swab was positive for SARS-CoV-2. There was no other precipitating factor to explain the presence of pneumomediastinum. The patient was treated with pleural and mediastinal drains, required five days of mechanical ventilation on a paediatric intensive care unit and subsequently made a full recovery. We outline our initial differential diagnosis, airway management plan, and propose a mechanism for the development of spontaneous pneumomediastinum in this case. We suggest that clinicians should consider pneumomediastinum as a potential cause of surgical emphysema, particularly in the context of COVID-19, even in infants. To our knowledge, this is the first reported case of COVID-19 in this age group with spontaneous pneumomediastinum as the presenting feature.

Correspondence to: Vita Sinclair

Email: vita.sinclair1@nhs.net

Accepted: 26 June 2021

Keywords: paediatrics: airway management; respiratory distress syndrome: effects (paediatrics)

Twitter: @Admckdoc

Introduction

Most children with SARS-CoV-2 infection are asymptomatic, or have mild symptoms which can include fever, dry cough and mild upper respiratory congestion [1]. It is less common for infections to progress to lower respiratory tract involvement [1]. Indeed, it is suggested that the younger the child the less aggressive the clinical course of COVID-19, although this trend may not extend to neonates [2].

Pneumomediastinum has been described as a rare but increasingly reported complication of COVID-19 in adults, particularly in the context of positive pressure ventilation [3]. Pneumomediastinum has been reported in a nine-year-old child with SARS-CoV-2 after several days of mechanical ventilation following emergency neurosurgery [4]. The precise mechanism of spontaneous pneumomediastinum in COVID-19 is unknown but its occurrence may be an indicator of worsening or severe disease [5].

Report

A three-month-old child, born at term, presented with several hours history of difficulty breathing and neck swelling with five prior days of fever and reduced appetite but no cough. There was no history of trauma and the child was previously well, with vaccinations received as scheduled and no known COVID-19 contact. His weight was estimated at 5.5 kg.

On examination, respiratory rate was 70 breaths per minute and peripheral oxygen saturation was 67%, increasing to 90–94% with supplemental oxygen via a non-rebreather mask at a rate of 15 L.min⁻¹. His head was held in extension and crepitus was palpable over his anterior neck and chest. There was no stridor, chest wall movements were symmetrical and breath sounds were diminished bilaterally. A chest radiograph demonstrated extensive surgical emphysema and the presence of pneumomediastinum. Pneumothoraces could not be excluded on the plain radiograph.

A plan was made for urgent tracheal intubation. The patient was transferred to the operating theatres, the off-site ear, nose and throat (ENT) surgeon called to attend, and the regional paediatric transfer team mobilised.

An emergency briefing was held and a plan made according to the paediatric Difficult Airway Society (DAS) algorithm. Inhalational induction of anaesthesia was decided upon to allow laryngeal assessment with spontaneous ventilation before administration of neuromuscular blocking agents. In the event of a cannot intubate cannot oxygenate scenario, the ENT surgeon would attempt percutaneous cannula cricothyroidotomy.

Intra-osseous access was obtained after failed intravenous cannulation. General anaesthesia was induced with sevoflurane and while still spontaneously breathing, a GlideScope® (Verathon Inc, Bothell, Washington, USA) video laryngoscope with an angulated LoPro S1 blade was inserted. A complete view of the vocal cords was obtained and rocuronium 1 mg.kg⁻¹ was administered. Intubation of the patient's trachea was attempted with a 3-mm internal diameter cuffed tracheal tube. Difficulty aligning the pre-formed angulated stylet with an oedematous glottic opening resulted in oxygen desaturation, necessitating a period of facemask ventilation. A standard laryngoscope with a Miller size 1 blade was then used to obtain a Cormack-Lehane grade 2b view of the glottis. Tracheal intubation was successful at the first attempt with this device by the consultant anaesthetist.

Computed tomography (CT) imaging of the chest, neck and head confirmed extensive surgical emphysema of the neck and thorax, massive pneumomediastinum and bilateral patchy upper lobe consolidation (Fig. 1). The patient was transported to a tertiary paediatric intensive care unit (PICU), where mediastinal and pleural drains were inserted. Reverse transcriptase-polymerase chain reaction swab testing for SARS-CoV-2 was positive but blood tests were unremarkable. Medical treatment included once daily dexamethasone for seven days and the empiric initiation of broad-spectrum antibiotic therapy. Antibiotics were stopped on the fourth day after blood, sputum and bronchoalveolar lavage samples were negative for bacterial growth. A high concentration of inspired oxygen and inhaled nitric oxide were necessary for two days. The patient's trachea was extubated on the fifth day and the patient discharged home four days later. At six-week follow-up, the patient remained well with no obvious sequelae.

Discussion

This case presented multiple challenges including airway management and diagnosis. Potential difficult airway, given the swelling around the neck, was the main anaesthetic concern. Furthermore, due to the surgical emphysema, ultrasound imaging of the neck was not possible and airway rescue techniques such as percutaneous cannula cricothyroidotomy or surgical tracheostomy may have been technically difficult even for experienced practitioners.

The patient's airway was ultimately secured by direct laryngoscopy after unsuccessful videolaryngoscopy despite an optimal view. Randomised control trials have demonstrated a superior first pass intubation rate with videolaryngoscopy as compared to direct laryngoscopy in the paediatric population [6]. Anecdotally, however, we can report that even operators experienced in adult GlideScope® use can find the same device difficult in the neonate or infants and choice of blade can be significant. In particular, the acute angulation of the LoPro blades can hinder, rather than help, some of these tracheal intubation attempts under optimal glottic view due to misalignment between the camera axis and the orolaryngotracheal axis. Of note, at the time of this case, our institution did not have access to straight videolaryngoscope blades. The manufacturer now does produce paediatric straight blades which, according to emerging data, may have a greater success rate in children under 5 kg [7].

A further point of interest in this case was the absence of a clear explanation for the child's clinical and radiological findings at first presentation. Diagnoses considered included spontaneous pneumothorax, bacterial pneumonia, obstructive bronchitis, foreign body aspiration, congenital pulmonary airway malformation and COVID-19. With these in mind, an additional concern was the potential for increased air leak and tension pneumomediastinum or tension pneumothorax once positive pressure ventilation had been established. Our institution does not have a paediatric thoracic service. We therefore prepared for cannula decompression and chest drains if required, with the support of paediatrician and ENT surgeon colleagues. Computed tomography imaging was helpful in detailing the pneumomediastinum and pneumothoraces, such that the decision could be

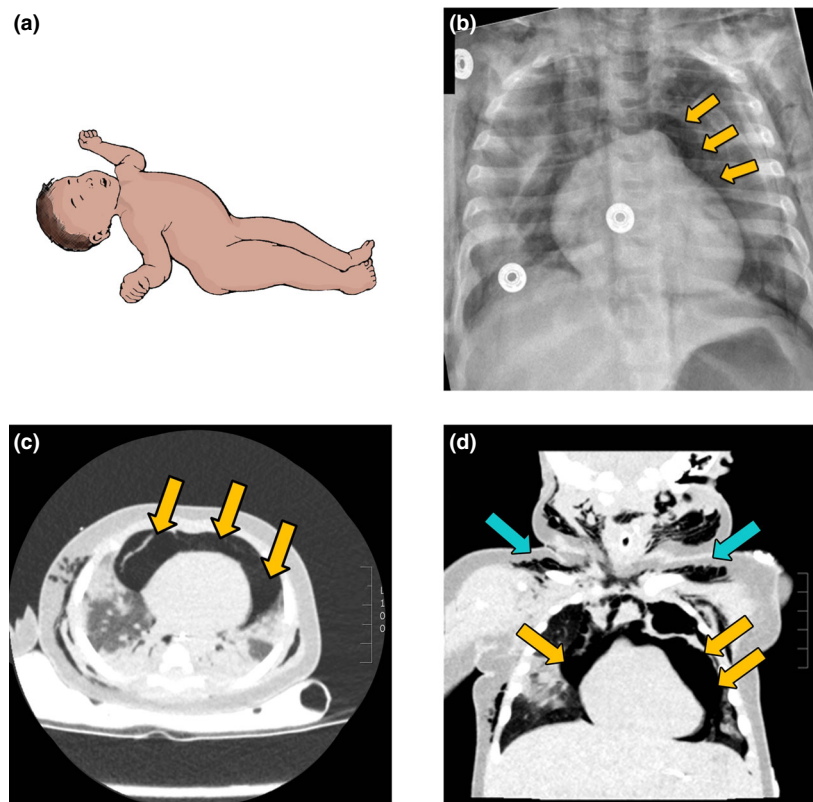


Figure 1 (a) Posture of the child on admission with neck extended due to accumulation of surgical emphysema. (b) Chest radiograph showing extensive surgical emphysema and pneumomediastinum. (c) Non-contrast chest computed tomography (transverse) demonstrating massive pneumomediastinum (yellow arrows), consolidated lung and thoracic wall surgical emphysema. (d) Coronal computed tomography illustrating supraclavicular surgical emphysema (blue arrows) and pneumomediastinum (yellow arrows).

made to delay drain insertion until arrival at the paediatric tertiary centre, where mediastinal and chest drains were inserted at the same time.

Pneumomediastinum can occur spontaneously or secondary to other pathology. Most commonly, it is associated with trauma such as damage to the oesophagus or bronchial tree [2]. However, pneumomediastinum is becoming an increasingly recognised, though still rare, complication of COVID-19. In the adult population, there are now multiple published case series of pneumomediastinum and subcutaneous emphysema in self-ventilating adults with COVID-19 [3–5]. In the paediatric population, a small body of literature exists on pneumomediastinum and subcutaneous emphysema in self-ventilating children with other viral illnesses, the proposed mechanism being a Valsalva manoeuvre associated with excessive coughing [8]. Our patient had no history of coughing. However, COVID-19 has been shown to cause diffuse alveolar damage [9] and therefore a potential mechanism may be alveolar rupture followed by air dissection along the bronchovascular sheaths and into the mediastinum, known as the Macklin effect [10].

The infant's family members were asymptomatic at the time of presentation and subsequently tested negative for SARS-CoV-2. However, this patient presented to us at a time when community transmission of the B.1.1.7 variant in our local population was very high. We propose that spontaneous pneumomediastinum is a rare but potentially catastrophic complication of severe COVID-19 lung disease in this age group. Clinicians should consider this diagnosis in the context of otherwise unexplained surgical emphysema, particularly in the context of high community transmission of SARS-CoV-2. If tracheal intubation is required, preparations for difficult airway management and subsequent tension pneumomediastinum should be undertaken.

Acknowledgements

Published with the written consent of the patient's mother. No external funding or competing interests declared.

References

1. Götzinger F, Santiago-García B, Noguera-Julían A, et al. COVID-19 in children and adolescents in Europe: a multinational, multicentre cohort study. *Lancet Child and Adolescent Health* 2020; **4**: 653–61.
2. Leung C. The younger the milder clinical course of COVID-19: even in newborns? *Pediatric Allergy and Immunology* 2020; **32**: 358–62.
3. Volpi S, Ali JM, Suleman A, Ahmed RN. Pneumomediastinum in COVID-19 patients: a case series of a rare complication. *European Journal of Cardio-Thoracic Surgery* 2020; **58**: 646–7.
4. Carroll AG, Quinn N, Byrne C, Kassab G, Whelan S, Collieran GC. Pneumomediastinum in a child with severe COVID-19. *British Journal of Radiology* 2021; **7**: 20200062.
5. Zhou C, Gao C, Xie Y, Xu M. COVID-19 with spontaneous pneumomediastinum. *Lancet Infectious Diseases* 2020; **20**: 510.
6. Marcia-Marcinkiewicz AG, Kovatsis PG, Hunyady A, et al. First-attempt success rate of video laryngoscopy in small infants (VISI): a multicentre, randomised controlled trial. *Lancet* 2020; **396**: 10266.
7. Peyton J, Park R, Staffa SJ, et al. A comparison of videolaryngoscopy using standard blades or non-standard blades in children in the Paediatric Difficult Intubation Registry. *British Journal of Anaesthesia* 2021; **126**: 331–9.
8. Emiralioğlu N, Özcan HN, Oğuz B, et al. Pneumomediastinum, pneumorrhachis and subcutaneous emphysema associated with viral infections: report of three cases. *Pediatrics International* 2015; **57**: 1038–40.
9. Mason RJ. Pathogenesis of COVID-19 from a cell biology perspective. *European Respiratory Journal* 2020; **55**: 2000607.
10. Macklin MT, Macklin CC. Malignant interstitial emphysema of the lungs and mediastinum as an important occult complication in many respiratory diseases and other conditions: interpretation of the clinical literature in the light of laboratory experiment. *Medicine* 1944; **23**: 281–358.