

Research article

Preliminary experience of autologous free myocutaneous flap combined with free dermal graft in the treatment of refractory empyema with bronchopleural fistula

Lei Wang^a, Zhongliang He^{a,*}, Chun Zhang^b^a Department of Cardiothoracic Surgery, Tongde Hospital of Zhejiang Province, Hangzhou, Zhejiang 310012, China^b Department of Traumatology and Orthopedic Surgery, Tongde Hospital of Zhejiang Province, Hangzhou, Zhejiang 310012, China

HIGHLIGHTS

- Surgical treatment of refractory empyema.
- Autologous free dermal graft combined with free myocutaneous flap in the treatment of refractory bronchopleural fistula with empyema.
- Application of free myocutaneous flap in patients with empyema.

ARTICLE INFO

Keywords:

Chronic empyema
Bronchopleural fistula
Myocutaneous flap
Dermal graft

ABSTRACT

Objectives: To explore the effects of autologous free dermal graft combined with free myocutaneous flap on bronchopleural fistula (BPF) with empyema, we summarized and analyzed two cases.

Methods: Two patients with refractory empyema and BPF were treated with autologous free dermal graft combined with free myocutaneous flap. The treatment included debridement of empyema, rib resection drainage, repair of bronchopleural fistula, and free vastus lateralis myocutaneous flap transplantation to eliminate the empyema. After the free dermal graft was harvested from the healthy skin around the incision, it was inserted into the fistula and sutured with the surrounding pleural tissue. The keys to the operation lies in the anastomosis of the lateral circumflex femoral artery (LCFA), vein and nerve that supply the vastus lateralis muscle flap to the thoracodorsal vessels and nerves. After surgery, the empyema, air leakage, and the survival of the myocutaneous flap were observed.

Results: There was no disease recurrence after follow-up for seven and six months, respectively. Re-examination of the chest computed tomography (CT) or magnetic resonance imaging (MRI) indicated that the abscess cavity had disappeared. No necrosis of the myocutaneous flap was observed after surgery.

Conclusion: The application of autologous free dermal graft combined with free vastus lateralis myocutaneous flap transplantation is effective in the treatment of patients with bronchopleural fistula with refractory chronic empyema, and the clinical effect is satisfactory.

1. Introduction

Bronchopleural fistula (BPF) refers to the fistula formed between the alveoli, bronchi at various levels, and pleural cavity due to various reasons, usually occurring after lobectomy. Although BPF is relatively rare after lobectomy, the incidence is still reported to be 0.6% [1, 2]. With the prolongation of the disease course, patients are prone to refractory hydropneumothorax, respiratory failure, chronic empyema, and even

death [3]. Owing to the existence of chronic abscess cavity that cannot be easily eliminated, treatment of BPF is difficult, especially in patients with empyema, cartilage and other necrotic tissues, where local infections are difficult to be controlled. It continues to be a problem for clinicians to completely cure the refractory BPF with empyema [4, 5]. Patients often have accompanying symptoms of systemic poisoning, such as cough, anemia, hypoproteinemia, and even hemoptysis, and require long-term drainage with a tube. Although there are various approaches to treat

* Corresponding author.

E-mail address: HezhongliangDr1@163.com (Z. He).<https://doi.org/10.1016/j.heliyon.2022.e11251>

Received 7 April 2022; Received in revised form 16 August 2022; Accepted 20 October 2022

2405-8440/© 2022 The Author(s). Published by Elsevier Ltd. This is an open access article under the CC BY-NC-ND license (<http://creativecommons.org/licenses/by-nc-nd/4.0/>).

BPF with empyema, it remains a challenge to solve the disease fundamentally. During the treatment period, the choice of surgical methods and endoscopic intervention may positively influence the treatment of individualized conditions. In any case, the goal is to control the infection, block the BPF, and effectively eliminate the abscess cavity [6].

Presently, in China, the treatment of BPF mostly focuses on non-surgical treatments, such as fistula closure with the endoscopic bronchial stent and injection of the sclerosing agent. However, it is very difficult to completely cure the refractory BPF with empyema by conservative treatment. The repair of BPF using an autologous free dermal graft may still be in the nascent stage due to the lack of literature and related data. The objective of the present case report was to summarize and analyze two patients with refractory BPF and empyema who were treated with autologous free dermal graft combined with free myocutaneous flap, and to evaluate the safety and effectiveness of this surgery.

2. Materials and methods

A retrospective analysis was performed on two patients with BPF and refractory empyema, who received surgery at the Cardiothoracic Surgery and Orthopedics Repair and Reconstruction Center of Tongde Hospital of Zhejiang Province. Autologous free dermal graft combined with free myocutaneous flap was used in the treatment of disease. The patient characteristics are presented in Tables 1 and 2. This study was approved by the Ethics Committee of Tongde Hospital of Zhejiang Province (PRO2022-041). Informed consent was obtained from all individual patients included in the study.

3. Treatment details

3.1. Case-1

The patient was a young woman of age 35 years. One and a half years ago, she was admitted to a local hospital for multiple bullae in both lungs and pneumothorax, and underwent bullectomy in the right upper lung at the same time. Two weeks after the operation, she developed cough, sputum, and fever. Purulent exudates appeared in her chest tube, which continued to leak air. Since pneumothorax also appeared in the left lung, drainage tubes were left in the thoracic cavity on both sides. She had a history of old pulmonary tuberculosis, which had subsequently been cured, and exhibited poor lung function. The chest computed tomography (CT) indicated hydropneumothorax in the right pleural cavity, simple pneumothorax in the left pleural cavity, and localized drainage tubes in both thoracic cavities (Figure 1A). Based on her clinical symptoms and the findings of imaging, she was diagnosed to have BPF with empyema after right upper bulla resection and left spontaneous pneumothorax. After admission, the patient's left pneumothorax was cured by replacing the drainage tube. Bronchoscopy was performed, which confirmed that there were two fistulas with a diameter of about 3 mm at the upper-right bronchus stump. The patient's right empyema with fistula was treated by a covered bronchial stent closure, debridement, thoracoplasty, pedicled latissimus dorsi combined with serratus anterior muscle flap transfer and tamponade. The pathogen identified by pus culture was *Mycobacterium* spp. The effect of operation and interventional treatment was not good. The bronchial stent fell off and empyema recurred two weeks after operation. We discussed and agreed that the root cause was air leakage and infection. Meanwhile, the pedicled muscle flap also showed partial atrophy after the operation. After multidisciplinary consultation, the free dermal graft combined with free myocutaneous flap was ultimately

selected for the surgery. Chest CT and magnetic resonance imaging (MRI) were used to evaluate the size and shape of the pus cavity before operation. Computed tomography angiography (CTA) was used to determine whether the thoracodorsal vessels and lower limb vessels were abnormal.

Surgical procedures: After anesthesia, the patient was placed in a semi-recumbent position. When selecting the thoracic incision, it was necessary to ensure that the empyema could be completely debrided and the thoracodorsal vessels were easily to harvest. The incision was usually made along the anterior edge of the latissimus dorsi under the armpit (Figure 1B), and then the thoracodorsal vessels and nerve were separated in turn (Figure 1C). After sufficient debridement, the size of the abscess cavity was measured to be about 60 ml, healthy skin around the incision was selected, and the subcutaneous and epidermal tissues were removed to make two pieces of dermis grafts with a size of about 0.4 cm × 1.0 cm (Figure 2A). when the fistulas of the bronchial stump were completely exposed, the free dermal grafts were inserted into the two fistulas (it needs to ensure that the dermal surface can fully contact with the muscle flap). Around the fistula, the edge of the dermal graft exposed in the thoracic cavity were sequentially sutured with the surrounding pleural tissue with 9-0 Prolene thread (Figure 2B). Finally, ensure that the fistula is completely filled without air leakage (Figure 2C). Later, the line connecting the right anterior superior iliac spine with the outer side of the patella was selected as the incision of the lower limb thigh flap. The exit point of the first perforator of the descending branch of the lateral circumflex femoral artery (LCFA) was taken as the center, and a flap skin paddle was designed according to the size of the chest wall defect wound (Figure 3A). Starting from the inside of the flap, the skin, subcutaneous tissue, and deep fascia were incised layer-by-layer to expose the muscle tissue. The rectus femoris and vastus lateralis muscle were bluntly separated, and the descending branches of the LCFA and accompanying vein and nerve were separated. Ligation of the branches was distributed at the distal end of the vastus lateralis muscle to completely free the muscle, its vascular pedicle, and nerve. The vascular pedicle was about 3 cm long. Finally, the pedicle was cut according to the length required by the recipient area, and a myocutaneous flap of a size of about 20 cm × 12 cm, composed of skin, subcutaneous tissue, fascia, and vastus lateralis muscle was obtained, with the descending branch of the LCFA as the pedicle. The size of the skin paddle was about 5 cm × 3 cm (Figure 3B). After the myocutaneous flap was transplanted to the recipient area and the residual cavity was filled, the descending branch of the lateral circumflex femoral artery, vein, and nerve, and the thoracodorsal artery, vein, and nerve were sutured respectively under the microscope using a 9-0 prolene thread (Figure 3C). Suture between dermal graft and muscle flap was also performed to enhance the vascularization to dermal graft. After the operation, the flap was sutured to normal skin around the chest without tension (Figure 4A), and the drainage tube and drainage skin were placed. The postoperative treatment consisted of postoperative anti-infection, anti-spasm, anti-coagulation, and other treatments. The survival of myocutaneous flap was closely monitored after operation.

The postoperative process went smoothly, and she was discharged from the hospital after complete recovery. Postoperative chest MRI showed that the muscle flap completely filled the abscess cavity (Figure 4B). During the 7-month follow-up, there was no obvious recurrence of BPF and empyema.

3.2. Case-2

The patient was a young man of age 21 years with a history of multiple bullae in the right lung with pneumothorax. Two and a half years

Table 1. Characteristics of patients.

Case	Age (years)	Sex	Diagnosis	Location of bronchopleural fistula	Air leakage duration (years)	Preoperative air leakage management
1	35	Male	Right empyema with air leakage	Right upper lobe	2.5	Drainage with tube
2	21	Female	Right empyema with air leakage	Right upper lobe	1.5	Drainage with tube

Table 2. Postoperative clinical data of patients.

Case	Type of bacteria cultured	Initial size of empyema cavity (mL)	Intraoperative bleeding (mL)	Operation time (h)	Length of stay (months)	Follow-up (months)
1	Mycobacterium	60	100	5.5	6.5	7
2	Stenotrophomonas maltophilia	180	300	6.2	1.8	6

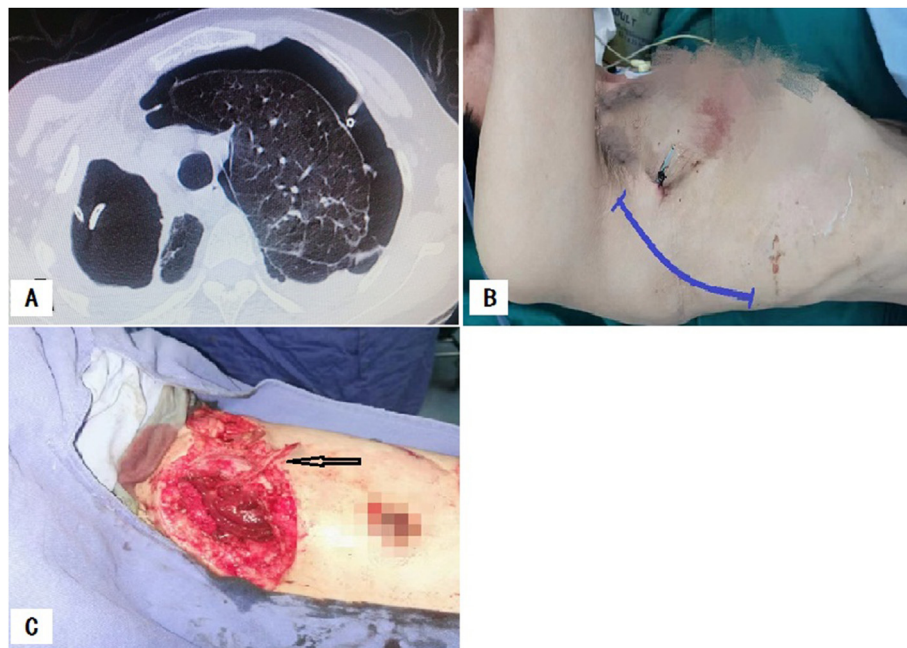


Figure 1. Preoperative and intraoperative images of case-1. A. The chest computed tomography at admission showed left pneumothorax and right hydro-pneumothorax with drainage tubes placed in the thoracic cavity on both sides. B. Design of chest incision before operation. C. The thoracodorsal vessels and nerves were completely separated along the anterior edge of latissimus dorsi.

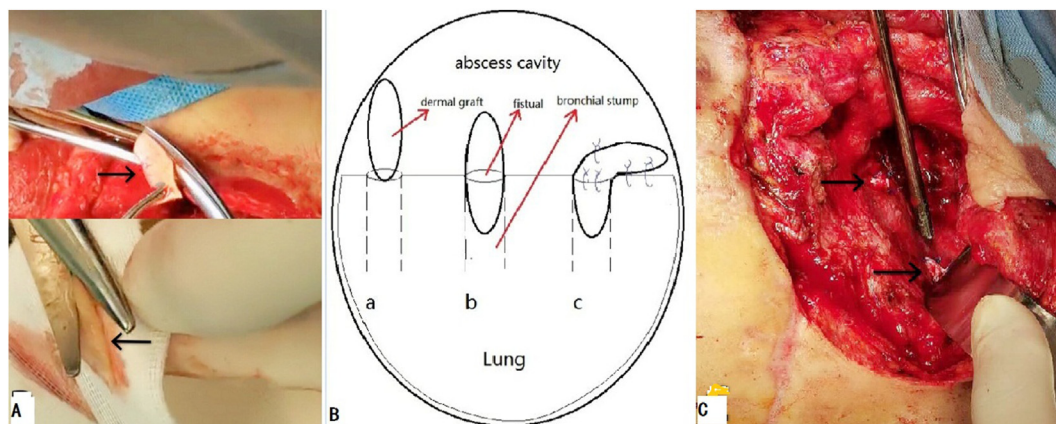


Figure 2. Application of intraoperative free dermal graft. A. The incised skin tissue was made into a suitable dermal graft. B. Operation chart: a. Fully expose the fistula of the bronchial stump, and vertically insert the free dermal graft into the fistula. b. The fistula was fully filled with dermal graft. c. Around the fistula, the edge of the dermal graft exposed in the thoracic cavity were sequentially sutured with the surrounding pleural tissue with 9-0 Prolene thread. C. The two fistulae located at the stump of the right upper lung bronchus were completely repaired with free dermal graft, without obvious air leakage (black arrow).

ago, he was admitted to a local hospital and received surgical treatment. On the third day after the operation, purulent exudates appeared in the drainage tube of the chest cavity. His main symptoms were intermittent cough and low fever. The chest CT showed an abscess in the upper right chest, a gas-liquid plane in the chest cavity, a reduction in the thoracic volume, and a thickening of the pleura (Figure 5A). Based on these observations, the patient was diagnosed to have the right BPF with empyema.

Surgical procedures: After active pre-operative preparation, using the position of the original drainage tube as the appropriate incision plane, 2 mm BPF could be seen on the pleural surface near the top of the abscess cavity after removing the 3rd, 4th, and 5th ribs along with part of the thickened pleura, and the volume of the abscess cavity was about 180 mL. Intraoperative debridement, flushing, and the removal of pus and necrotic tissue in the thoracic cavity were performed, and two drainage tubes were placed in the thoracic cavity after operation. The

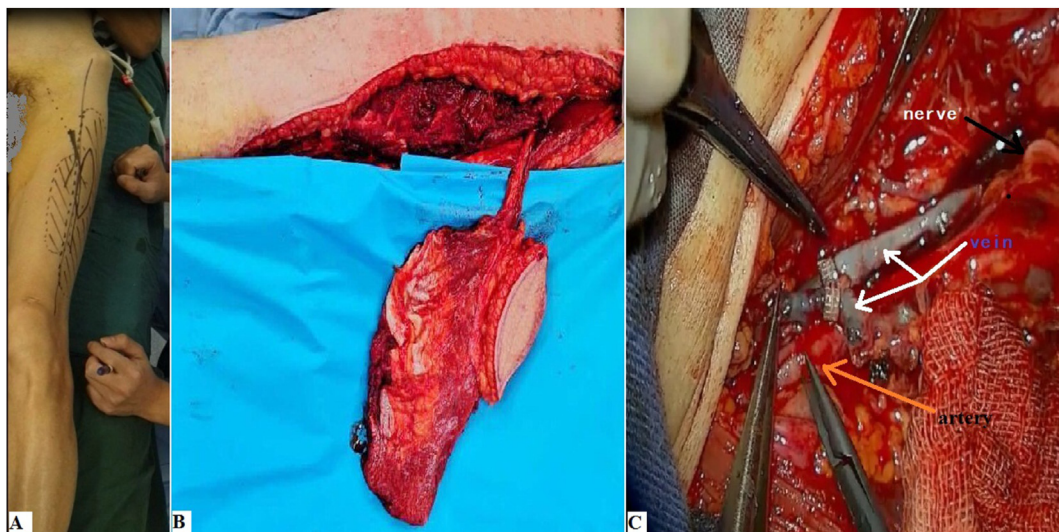


Figure 3. Preoperative and intraoperative images of case-1. A. Design of incision on the body surface of lower limb. B. Free vastus lateralis musculocutaneous flap with vascular pedicle harvested during operation. C. Vascular and nerve anastomosed during operation.

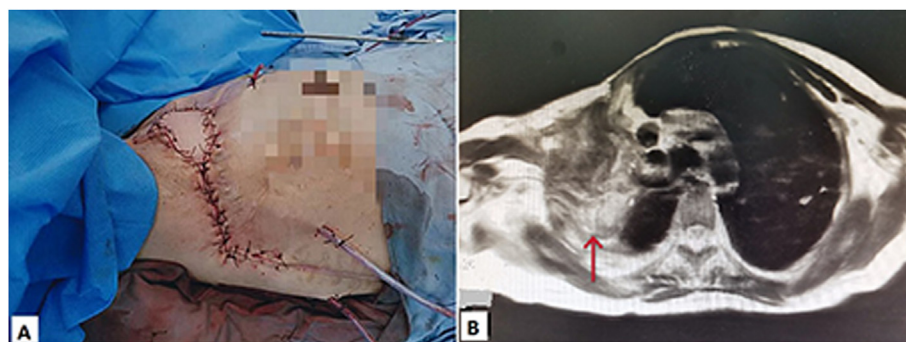


Figure 4. Postoperative images of case-1. A. After surgery, the myocutaneous flap was sutured to normal skin around the chest without tension. B. Postoperative MRI showed the muscle flap completely filled the abscess cavity and the empyema disappeared (red arrow).

identified bacterium in the postoperative pus culture was *Maltophilia stenotrophomonas*.

When the initial infection of the patient was basically controlled after the first-stage operation, and the bacterial culture of the drainage fluid was negative, we combined the first patient's successful experience in repairing the fistula with a dermal graft to evaluate whether the same approach was similarly effective. The patient received the second-stage operation. The patient was placed in the 45° lateral decubitus position according to the location of the abscess cavity and the harvest of myocutaneous flap from the lower limb. The residual necrotic tissue in the abscess cavity after the first-stage operation was fully removed, and the abscess cavity was repeatedly washed with a large amount of warm

normal saline, hydrogen peroxide, and diluted iodophor water to ensure the freshness of the wound surface. After the surgical field was re-disinfected, the original thoracic incision on the affected side was appropriately extended, and the thoracodorsal artery, vein and nerve were freed along the anterior edge of the latissimus dorsi muscle as the recipient blood vessels. According to the size of the fistula, healthy skin around the incision was selected and made into a dermal graft with a size of about 0.3 cm × 0.8 cm. The incision of the lower limb was the same as that described above. The skin, subcutaneous tissue and deep fascia were cut layer by layer along the inner edge of the flap to fully expose the muscle group. Finally, a 25 cm × 16 cm myocutaneous flap was harvested, which was pedicled with the descending branch of the lateral

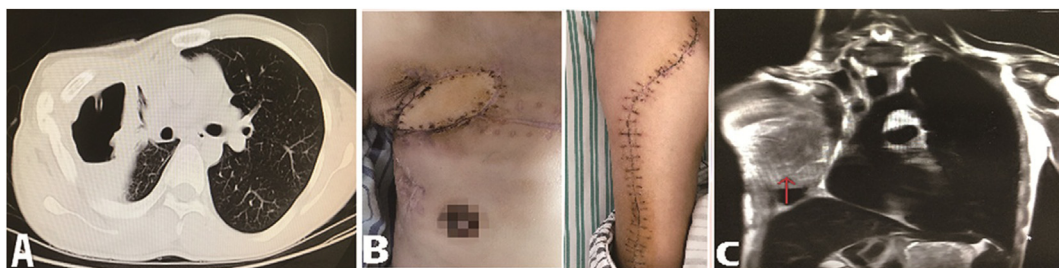

Figure 5. Clinical images of case-2. A. The chest computed tomography at admission showed right hydropneumothorax with drainage tube placed in the right thoracic cavity. B. The myocutaneous flap was active, and the incision healed well after surgery. C. The chest magnetic resonance imaging indicated that the empyema cavity and bronchopleural fistula were successfully blocked (red arrow).

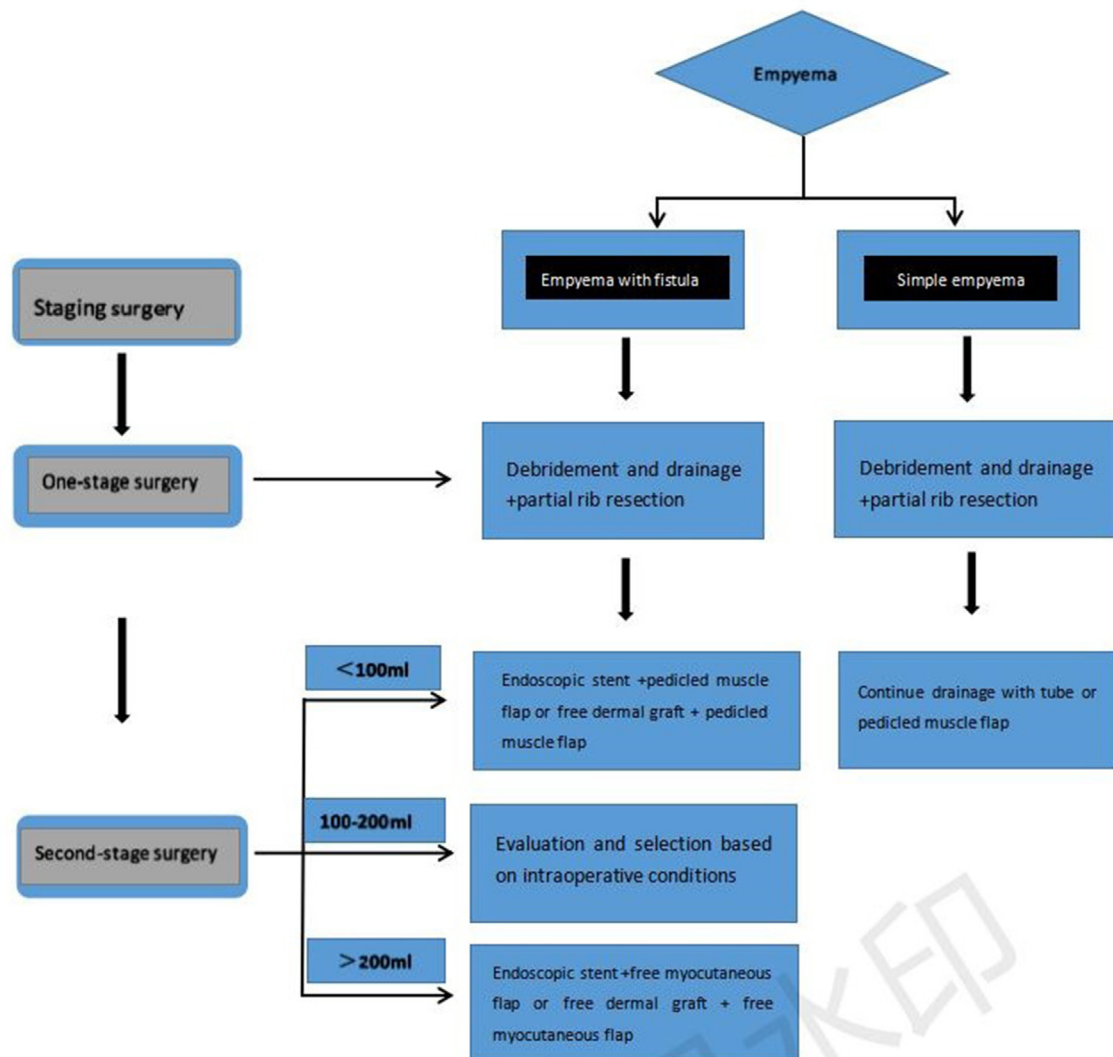


Figure 6. The staging operation flowchart was used to design treatment plans according to the different conditions of the patients.

circumflex femoral artery and composed of skin, subcutaneous tissue, fascia and vastus lateralis muscle. The size of the skin paddle was about 6 cm × 4 cm. The suture of the lateral circumflex femoral artery, vein and nerve with the thoracodorsal artery, vein and nerve was completed under the microscope. A closed chest drainage tube and three subcutaneous drainage tubes were placed.

After 1.8 months of hospitalization, he was discharged from the hospital, and the incision recovered well (Figure 5B). Re-examination of chest MRI showed no recurrence of empyema and disappearance of BPF (Figure 5C). After six months of follow-up, his living ability returned to normal.

4. Results

We applied autologous free dermal graft and free vastus lateralis musculocutaneous flap to treat refractory bronchopleural fistula with empyema, and the clinical effect was satisfactory. The follow-up time of these two patients was 7 months and 6 months respectively. Postoperative chest CT or MRI showed that the activity of free myocutaneous flap was good. The abscess cavity disappeared and the empyema did not recur. They could participate in daily activities and work, their knee joint function was normal, and their quality of life was significantly improved.

5. Discussion

BPF is a serious complication after lung resection and leads to adverse effects, including intractable empyema and residual lung pneumonia with the progress of the disease. BPF itself adversely affects the quality of life and survival time of patients, which is also considered to be a challenge for thoracic surgeons. Presently, the etiology and mechanism of BPF with empyema remains poorly understood. Comprehensive analysis of multiple factors has indicated that the occurrence of BPF can be summarized as a major risk factor as well as a secondary risk factor [7, 8]. These risk factors may include: a) the manual suture technique implemented by the clinician on the bronchial stump; b) excessive removal of the lymph nodes around the bronchial stump, causing the blood supply around the stump to be blocked; c) excessively long bronchial stump remaining after lung resection; d) the continued presence of tumor cells in the bronchial stump; e) long-term mechanical ventilation after major surgery; f) advanced age and poor nutritional status; g) exposure to high-dose chemotherapy or radiotherapy before or after surgery [9, 10, 11]. Recent studies have demonstrated that pneumonectomy bears a significantly higher risk of BPF than lobectomy. This may be attributed to the fact that there is an increased risk of avascular necrosis of the bronchial stump or accumulation of secretions, leading to bacterial overgrowth and colonization and poor nutritional status [12, 13]. Clinical

studies have reported that appropriate treatment is highly important for patients showing BPF with empyema. The timeliness of the treatment is mainly reflected in avoiding persistent infection of the pleural cavity as much as possible [4, 14, 15]. The common assessment methods are chest CT and bronchoscopy. The patients transitioning from the acute phase to the chronic phase are often accompanied by chronic wasting with obvious symptoms of systemic poisoning and symptoms such as cough, anemia, hypoproteinemia, and hemoptysis.

Several BPF patients with empyema were admitted in our department, who were treated with a pedicled muscle flap or free myocutaneous flap. Regarding the choice of surgical methods, we have observed that abscesses of volume less than 100 mL could be treated with pedicled muscle flap, those of volume between 100 mL and 200 mL could be treated with pedicled muscle flap, free myocutaneous flap, or a combination of the two treatments according to intra-operative conditions, and abscess of volume more than 200 mL could be treated with free myocutaneous flap (Figure 6). Generally speaking, the treatment options for patients with refractory BPF with empyema include conservative treatment, endoscopic treatment, and surgical treatment, of which the conservative treatment mainly involves adequate chest drainage and supportive treatment [16]. Endoscopic treatment often involves bronchoscopy occlusion, which may be more practical for most patients. However, it is difficult to treat patients with BPF, such as bronchial dislocation, severe infection in the pleural cavity, and larger fistulae, with poor efficacy of the treatment [17]. What should we do if we encounter this type of refractory BPF with empyema and a large abscess cavity? The data indicated that after full closed thoracic drainage of empyema, closure of the fistula is a key factor for the success of the subsequent operation [12]. On the other hand, our treatment plans should also take the locations of fistula and abscess cavity into consideration. If the visual field exposure of fistula is poor during the surgery, it may be difficult to be repaired by the free dermal graft. The two patients analyzed in this study both had upper lobe BPF, the location of the fistula under the surgical field of view was suitable for repair.

Generally, free dermal grafts are mainly used to repair skin and mucous membrane defects caused by burns and wounds but are relatively rarely utilized in the repair of BPF, as evident from the availability of only a few clinical reports [18, 19]. Autologous free dermal grafts (de-epidermized) have their unique advantages, including good flexibility and contractility, strong anti-infective ability, and abundance of surrounding capillaries [20]. After the repair of the fistula, the air leakage was significantly reduced, and the curative effect exceeded expectations. After completing the repair of the fistula, we again selected free myocutaneous flaps to fill the abscess cavity. With a recent increase in the number of cases receiving tissue flaps to treat empyema, its therapeutic effect has also been unanimously recognized by thoracic surgeons [21]. It retains the shape of the thorax and does not significantly affect the respiratory and circulatory function. Furthermore, the free myocutaneous flap does not require skin grafting due to chest wall skin defects. After the operation, the color of the flap can be observed in time to evaluate the blood supply.

Currently, the chronic empyema has been frequently treated with pedicled muscle flaps, while the free myocutaneous flaps have rarely been used [16, 22], which may be due to the operation involving microscopic vascular anastomosis, surgical difficulty, and greater trauma. Pedicled muscle flaps are not applicable if the patient suffers from refractory BPF with empyema and if part of the muscle group has been severed due to previous thoracotomy or when the abscess cavity is large [23]. The free myocutaneous flap can reach almost any position in the pleural cavity and can fill the contaminated cavity. In some cases, free myocutaneous flaps can also be combined with pedicled muscle flaps, pedicled pericardium slices, or pedicled omentum to treat complex empyema [24, 25]. We generally choose the thoracodorsal artery and vein to anastomose with the lateral circumflex femoral artery and vein of the free myocutaneous flap. If the thoracodorsal arteries and veins are destroyed, and intercostal vessels, intramammary vessels, and transverse

cervical vessels can be selected [4]. During the operation, it is necessary to prevent the tension of the vascular pedicle and the edge of the myocutaneous flap after anastomosis, which may affect the blood supply and activity of the free myocutaneous flap. In order to prevent further atrophy of the muscle group after operation, we usually choose to anastomose the thoracodorsal nerve and the lateral femoral muscle cutaneous nerve [26].

6. Conclusions

The autologous free dermal graft combined with free myocutaneous flaps is an effective surgical treatment for some patients with refractory BPF with empyema. Perhaps, the number of cases in which we have applied this method to treat complicated empyema is low, and even the position of some patients with pleural fistula is not suitable for repair or is irreparable, but we had only selected the suitable cases, and the patients had recovered well in the short and mid-term. Thus, it is necessary to further clinically test this procedure on a larger patient population.

Declarations

Author contribution statement

Lei Wang: Conceived and designed the experiments; Performed the experiments; Analyzed and interpreted the data; Contributed reagents, materials, analysis tools or data; Wrote the paper.

Zhongliang He and Chun Zhang: Conceived and designed the experiments; Performed the experiments; Analyzed and interpreted the data; Contributed reagents, materials, analysis tools or data.

Funding statement

This research did not receive any specific grant from funding agencies in the public, commercial, or not-for-profit sectors.

Data availability statement

Data included in article/supp. material/referenced in article.

Declaration of interest's statement

The authors declare no conflict of interest.

Additional information

No additional information is available for this paper.

Acknowledgements

None.

References

- [1] M. Kashima, K. Yamakado, H. Takaki, et al., Complications after 1000 lung radiofrequency ablation sessions in 420 patients: a single center's experiences, *AJR Am. J. Roentgenol.* 197 (4) (2011) W576–580.
- [2] T. de Baere, L. Tselikas, D. Woodrum, et al., Evaluating cryoablation of metastatic lung tumors in patients-safety and efficacy: the ECLIPSE trial-interim analysis at 1 year, *J. Thorac. Oncol.* 10 (10) (2015) 1468–1474.
- [3] M. Slade, Management of pneumothorax and prolonged air leak, *Semin. Respir. Crit. Care Med.* 35 (6) (2014) 706–714.
- [4] M.D. Walsh, A.D. Bruno, M.W. Onaitis, et al., The role of intrathoracic free flaps for chronic empyema, *Ann. Thorac. Surg.* 91 (3) (2011) 865–868.
- [5] M. Deshpande, A. Kamath, K. Allinson, D. Peat, W. Parry, A 76-year-old lady with chronic cough and a discharging chest wall sinus, *Thorax* 66 (8) (2011) 733, 738–739.
- [6] Z.H. He, C. Zhang, L. Shen, et al., Transplantation of free lateral thigh myocutaneous flap for the treatment of postoperative intractable chronic empyema, *Chin. J. Thorac. Cardiovasc. Surg.* 32 (7) (2016) 421–422.

- [7] C. Deschamps, A. Bernard, F.C. Nichols 3rd, et al., Empyema and bronchopleural fistula after pneumonectomy: factors affecting incidence, *Ann. Thorac. Surg.* 72 (1) (2001) 243–247, discussion 248.
- [8] M. Di Maio, F. Perrone, C. Deschamps, G. Rocco, A meta-analysis of the impact of bronchial stump coverage on the risk of bronchopleural fistula after pneumonectomy, *Eur. J. Cardio. Thorac. Surg.* 48 (2) (2015) 196–200.
- [9] F.J. Algar, A. Alvarez, J.L. Aranda, A. Salvatierra, C. Baamonde, F.J. López-Pujol, Prediction of early bronchopleural fistula after pneumonectomy: a multivariate analysis, *Ann. Thorac. Surg.* 72 (5) (2001) 1662–1667.
- [10] P. Laperuta, F. Napolitano, A. Varella, R.M. Di Crescenzo, A. Cortese, V. Di Crescenzo, Post-pneumonectomy broncho-pleural fistula successfully closed by open-window thoracostomy associated with V.A.C. therapy, *Int. J. Surg.* 12 (Suppl 2) (2014) S17–s19.
- [11] G. Cardillo, L. Carbone, F. Carleo, et al., The rationale for treatment of postresectional bronchopleural fistula: analysis of 52 patients, *Ann. Thorac. Surg.* 100 (1) (2015) 251–257.
- [12] L. Fuso, F. Varone, D. Nachira, et al., Incidence and management of post-lobectomy and pneumonectomy bronchopleural fistula, *Lung* 194 (2) (2016) 299–305.
- [13] A. De Palma, M. Maruccia, F. Di Gennaro, Right thoracotomy approach for treatment of left bronchopleural fistula after pneumonectomy for tuberculosis, *Gen. Thorac. Cardiovasc. Surg.* 68 (12) (2020) 1539–1542.
- [14] E. Matros, J.J. Disa, Uncommon flaps for chest wall reconstruction, *Semin. Plast. Surg.* 25 (1) (2011) 55–59.
- [15] Y. Wu, Z. He, C. Zhang, et al., Free vastus lateralis muscle flap transplantation for postoperative chronic empyema: retrospective analysis of eight case series, *Ann. Palliat. Med.* 10 (5) (2021) 5046–5054.
- [16] Z. He, Z. Liu, L. Shen, et al., Treatment of chronic postoperative empyema by free vastus lateralis musculocutaneous flap transplantation, *Chin. J. Thorac. Cardiovas. Surg.* 36 (8) (2020) 502–504.
- [17] X. Han, M. Yin, L. Li, et al., Customized airway stenting for bronchopleural fistula after pulmonary resection by interventional technique: single-center study of 148 consecutive patients, *Surg. Endosc.* 32 (10) (2018) 4116–4124.
- [18] B. Karatan, K. Yamak, Use of single-layer artificial dermal template in patients with trauma and burns, *J. Wound Care* 4 (1) (2022) S16–S23.
- [19] F. Castagnetti, S. Coiro, M. Foroni, et al., A pure autologous dermal graft and dermal flap pocket in prepectoral implant reconstruction after skin-reducing mastectomy: a one-stage autologous reconstruction alternative to acellular dermal matrices, *Aesthetic Plast. Surg.* (2022).
- [20] H.C. Chen, L.H. Teng, C.I. Yen, et al., Selection of site for harvesting dermal grafts as a spacer in the correction of eyelid retraction, *Aesthetic Plast. Surg.* (2021).
- [21] H. Zhongliang, S. Lifeng, X. Weihua, et al., Effective treatment of bronchopleural fistula with empyema by pedicled latissimus dorsi muscle flap transfer: two case report, *Medicine* 99 (2020) 41, e22485.
- [22] C. Andreotti, C.D. Menna, A. Andrioli, et al., Multi-modal treatment for post pneumonectomy bronchopleural fistula associated with empyema, *Ann. Thorac. Surg.* 106 (6) (2018) e337–e339.
- [23] C. Lu, Z. Feng, D. Ge, et al., Pedicle muscle flap transposition for chronic empyema with persistent bronchopleural fistula: experience of a single clinical center in China, *Surg. Today* 46 (10) (2016) 1132–1137.
- [24] X. He, Z. He, L. Shen, G. Chen, X. He, Free musculocutaneous flap transfer for refractory chronic empyema with chest wall sinus in a 43-year-old male with hemophilia A, *J. Thorac. Dis.* 10 (6) (2018) E416–e419.
- [25] X. Hong, Z. He, L. Shen, X. He, Free vastus lateralis musculocutaneous flap transfer for radiation-induced chest wall fistula combined with osteomyelitis: two case report, *Medicine* 98 (22) (2019) e15859.
- [26] H.M. Oberhofer, S.S. Samant, C.C. Swan, et al., Objective comparison of donor-site morbidity following full and thoracodorsal nerve-preserving split latissimus dorsi flaps, *Plast. Reconstr. Surg.* 149 (5) (2022) 966e–971e.