

Mandibular dimensional changes and skeletal maturity

PRIYA SUBRAMANIAM, PREMILA NAIDU

Abstract

Aim: Growth and development of the human face provides a fascinating interplay of form and function. Among the various facial bones, the mandible plays a very important role during various growth-modification therapies. These treatment modalities will yield a better result in less time if properly correlated with skeletal maturity. It is very essential to know where the site of growth occurs and also the time when it occurs or ceases to occur. This study was conducted to assess the mandibular dimensions at various stages of skeletal maturation. **Materials and Methods:** The subjects included 6 to 18-year-old children who were grouped according to their middle phalanx of the third finger stages of skeletal maturity. Lateral cephalographs were taken and, from their cephalometric tracings, linear and angular measurements of the mandible were made. The values obtained were subjected to statistical analysis. **Results:** Results showed that the mandibular height, length and symphysis thickness increased with skeletal maturity. An increase in angles SNB (Sella, Nasion, Supramentale) and L1-MP (Long axis lower incisors- Mandibular plane) and a decrease in the gonial angle and ANB (Subspinale, Nasion, Supramentale) angle were observed. **Conclusion:** The study showed a significant correlation between mandibular growth and skeletal maturity.

Keywords: Cephalogram, growth, mandible, skeletal maturity.

Introduction

Growth and development of the human face provides a fascinating interplay of form and function. The mosaic of morphogenetic pattern, as it is influenced by epigenetic and environmental forces, requires an understanding of many factors.^[1] Among the various facial bones, the mandible is unique as it is the only movable component of mastication suspended by various muscles and ligaments. Although the mandible receives a variety of functional forces during the eruption of permanent teeth, it continues to perform sophisticated movements required for mastication as well as speech. Considerable attention is paid to mandibular growth because it is reported that this bone enlarges the most during adolescence. Timing of orthodontic treatment with mandibular growth is particularly very important, reducing

the demands made on changes in tooth position and the potential iatrogenic damage of prolonged appliance wear.^[1]

It is known that many treatment modalities will yield a better result in less time if properly correlated with patient's growth period.^[2] Assessment of skeletal maturity is an integral part of interceptive diagnosis and treatment planning. A clinically relevant and reliable method is assessment of skeletal maturity.^[3] Bone age is determined by radiographs, relating the appearance and development of certain bones with their maturational stages. The events of growth and development must be correlated with the maturational level of each individual in order to identify the skeletal pattern and the residual growth and to decide on a proper treatment plan.^[4]

It is important for pediatric dentists to understand the mandibular changes occurring in a child according to skeletal maturity. Hence, this study was conducted to assess the mandibular dimensions during different stages of skeletal maturation. It also aimed at correlating these dimensional changes in the mandible with the various stages of skeletal maturity.

Materials and Methods

Subjects for the study were children, aged 6–18 years, visiting the Department of Pedodontics and Preventive Dentistry, The Oxford Dental College, Hospital and Research Centre, Bangalore. Ethical clearance to conduct the study was obtained from the ethical committee of the institution.

Following the recording of case history and clinical

Department of Pedodontics, The Oxford Dental College, Hospital and Research Centre, Bangalore, India.

Correspondence: Dr. Priya Subramaniam
Department of Pedodontics, The Oxford Dental College,
Hospital and Research Centre, Bommanahalli, Hosur Road,
Bangalore, India. E-mail: drpriyapedo@yahoo.com

Access this article online	
Quick Response Code: 	Website: www.contempclindent.org
	DOI: 10.4103/0976-237X.76387

examination, 631 subjects were selected according to the following inclusion criteria:

- Children having only Angle's class I molar relation, who were neither undergoing nor were receiving any orthodontic or orthopedic treatment.
- Children with bimaxillary protrusion, cleft lip and/or palate and temporomandibular joint disorders were excluded.
- Children with handicapping conditions, including medically compromised children and children on long-term medication, were also not included.
- The nature of the investigation was explained to the parents of the children who were selected and their written consent was obtained prior to the study. Parents of only 302 children gave consent for participation in the study.

Recording of the middle phalanx of the third finger (MP3) stage

An intraoral periapical radiograph film was used to record the MP3 using the standard radiographic machine (Villa – Sistem Medicali Explore, Italy), with the exposure parameter set at 70 Kvp, 8m A and 0.4 s, and a no. 2 size Kodak E speed IOPA film [Carestream Health, Inc, 150 verena street, Rochester, New York 14608, USA] (32 mm x 41 mm). The patient was instructed to place his or her hand with the palm down on a flat table with the third finger straight and on the long axis of the standard periapical dental X-ray film in such a way that the middle phalanx was located in the center of the film. The cone of the dental X-ray machine

was positioned in light contact with the middle phalanx perpendicular to the dental X-ray film.^[3] The radiographs was interpreted for five stages of MP3 as given by Hagg and Taranger.^[5]

Based on the stage of skeletal maturity observed, a total of 250 children formed the study group. They were divided into five groups, such that each group had an equal number of children, who were also matched for gender. For each child, a lateral cephalogram was taken using a cephalostat (Panmea Proline 2002cc, Finland) and radiographic film (Kodak X o mat China) of size 8 x 10 inches. The exposure parameters were 72 Kvp, 10 mA and 1.2 s and the source to mid-sagittal plane distance was maintained at 60 inches. Cephalometric tracings were carried out for three linear and six angular measurements according to Tsai.^[6] The cephalometric landmarks used are shown in Table 1. The linear and angular measurements are shown in Figure 1 and Table 2.

The data obtained were subjected to descriptive statistical analysis. Analysis of variance was used to determine the significance of the linear parameters between the

Table 1: The cephalometric landmarks

- N: Nasion (the most anterior point on the nasofrontal suture)
- S: Selle (the center of the cavity outlined by sella turcica)
- Me: Menton (the most inferior point on the mandibular symphysis)
- Articulare (the point of the intersection of the inferior surface of the cranial base and the averaged posterior surface of the mandible)
- A: Subspinale (the most concave point on the maxillary alveolus)
- B: Supramentale (the most concave point on the mandibular alveolus)
- Pog: Pogonion (the most anterior point on the mandibular symphysis)
- GoL: Lower gonion (the most inferior point on the mandible at the angle)
- GoP: Posterior gonial (the most posterior point on the mandible at the angle)
- D: Point D (the most posterior point on the mandible at the symphysis)
- Gn: Gnathion (the most inferior and anterior point on the mandible at the symphysis)
- Po: Porion (the most superior point on the ear rod)
- Or: Orbitale (the most inferior point on the orbit)
- L1: Lower incisor edge (the point on the lower incisor edge)
- L1R: Lower incisor root apex (the point on the lower incisor root apex)

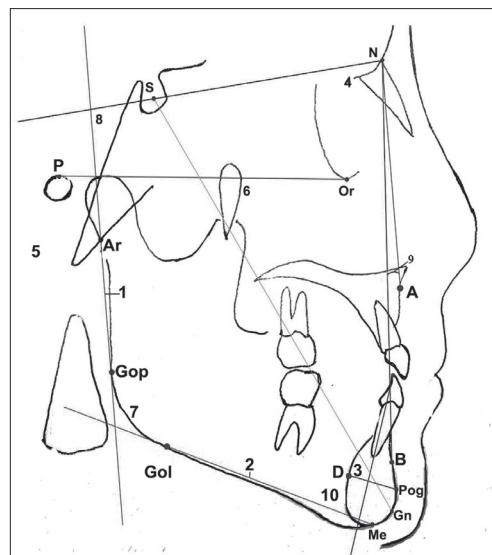


Figure 1: Linear and angular measurements

Table 2: Linear and angular measurements

- Mandibular ramus height (the distance between Ar and GoP)
- Mandibular body length (the distance between GoL and Me)
- Symphysis thickness (the distance between pog and D)
- Angle SNB (the angle of SN and NB)
- Angle SN-MP (the angle of SN and GoL-Me)
- Y-axis (the angle of Po-Or and SN-Gn)
- Gonial angle (the angle of Ar-GoP and GoL and Me)
- Ramus inclination (the angle of SN and Ar-GoP)
- Angle ANB (the angle of AN and NB)
- Angle L1-MP (the angle of L1-L1R and GoL-Me)

Table 3: Comparison of the mandibular dimensions between males and females

Mandibular dimensions		Stages of skeletal maturity					
		Presence of epiphysis	Equal length of epiphysis and diaphysis	Capping of epiphysis to diaphysis	Capping of ends of epiphysis to diaphysis	Fusion of ends of epiphysis to diaphysis	All case
Mandibular height (mm)	Males	34.24 ± 3.80	36.38 ± 3.32	36.22 ± 3.32	39.60 ± 4.34	46.31 ± 3.93	
	Females	33.22 ± 3.35	32.16 ± 2.59	36.12 ± 3.64	40.27 ± 5.16	44.66 ± 4.85	
	<i>P</i> -value	0.317	<0.001**	0.920	0.620	0.197	
Mandibular length (mm)	Males	63.80 ± 3.57	63.92 ± 4.69	69.54 ± 3.64	69.52 ± 4.33	74.75 ± 4.58	68.22 ± 5.81
	Females	56.86 ± 3.63	59.48 ± 3.66	64.20 ± 4.68	65.42 ± 3.56	71.36 ± 4.75	63.48 ± 6.44
	<i>P</i> -value	<0.001**	0.001**	<0.001**	0.001**	0.014*	<0.001**
Symphysis thickness (mm)	Males	14.92 ± 1.66	15.08 ± 1.74	15.38 ± 1.64	15.18 ± 1.36	17.00 ± 1.72	15.64 ± 1.77
	Females	16.02 ± 3.40	14.84 ± 1.59	15.96 ± 1.67	15.46 ± 1.92	16.76 ± 1.48	15.80 ± 2.19
	<i>P</i> -value	0.154	0.490	0.222	0.451	0.602	0.492
SNB angle (degrees)	Males	75.52 ± 9.72	78.92 ± 2.65	77.64 ± 10.23	79.16 ± 3.06	82.19 ± 2.94	78.60 ± 6.94
	Females	78.00 ± 2.40	76.52 ± 3.36	79.08 ± 2.47	80.75 ± 4.60	81.02 ± 2.04	79.08 ± 3.51
	<i>P</i> -value	0.229	0.006**	0.806	0.310	0.243	0.695
SN-MP angle (degrees)	Males	34.36 ± 5.07	30.48 ± 3.73	32.88 ± 10.49	28.98 ± 6.28	27.54 ± 5.94	30.87 ± 7.03
	Females	33.24 ± 3.95	34.40 ± 4.19	31.12 ± 4.67	30.21 ± 4.33	29.60 ± 3.75	31.70 ± 4.51
	<i>P</i> -value	0.189	0.001**	0.617	0.289	0.172	0.079
Y-axis (degrees)	Males	61.84 ± 4.26	61.37 ± 3.15	63.56 ± 3.94	61.18 ± 4.27	63.77 ± 3.84	62.32 ± 3.99
	Females	59.80 ± 3.02	59.68 ± 2.93	62.08 ± 2.66	64.50 ± 3.86	60.56 ± 3.27	61.34 ± 3.62
	<i>P</i> -value	0.063	0.061	0.159	0.012*	0.004**	0.020*
Gonial angle (degrees)	Males	126.12 ± 6.66	121.69 ± 4.61	122.00 ± 4.19	120.64 ± 5.36	121.92 ± 8.37	122.47 ± 6.19
	Females	123.30 ± 12.96	127.28 ± 2.85	125.44 ± 4.24	121.42 ± 4.49	118.24 ± 11.49	123.12 ± 8.75
	<i>P</i> -value	0.838	<0.001**	0.004**	0.696	0.176	0.020*
Ramus inclination (degrees)	Males	86.16 ± 4.58	86.60 ± 4.48	85.44 ± 4.17	88.56 ± 4.41	89.20 ± 4.73	87.93 ± 4.68
	Females	88.00 ± 4.84	88.50 ± 4.22	89.00 ± 3.69	87.96 ± 6.04	86.08 ± 4.13	87.20 ± 4.64
	<i>P</i> -value	0.126	0.121	0.002**	0.640	0.048*	0.153
L1-MP angle (degrees)	Males	104.04 ± 5.16	103.35 ± 4.26	104.12 ± 5.90	103.84 ± 6.57	102.96 ± 4.14	103.66 ± 5.22
	Females	99.96 ± 5.89	101.32 ± 5.77	102.12 ± 4.37	105.67 ± 7.92	103.80 ± 6.07	102.59 ± 6.36
	<i>P</i> -value	0.007**	0.137	0.102	0.317	0.567	0.038*
ANB angle (degrees)	Males	5.24 ± 1.48	4.35 ± 1.47	3.82 ± 1.18	2.84 ± 1.07	2.98 ± 1.59	3.85 ± 1.62
	Females	4.89 ± 1.53	4.50 ± 1.23	3.32 ± 1.73	3.18 ± 0.91	3.24 ± 1.36	3.82 ± 1.54
	<i>P</i> -value	0.357	0.582	0.074	0.232	0.600	0.710

*Moderately significant 0.01 < *P* ≤ 0.05 **Highly significant *P* ≤ 0.01**Table 4: Correlation between mandibular dimensions and skeletal maturity**

Parameters	Male		Female	
	R-value	<i>P</i> -value	R-value	<i>P</i> -value
Mandibular height	0.684	<0.001**	0.717	<0.001**
Mandibular length	0.668	<0.001**	0.769	<0.001**
Symphysis thickness	0.393	<0.001**	0.143	0.113
SNB angle	0.274	0.002**	0.417	<0.001**
SN-MP angle	-0.302	0.001**	-0.374	<0.001**
Y-axis	0.129	0.153	0.244	0.006**
Gonial angle	-0.216	0.015	-0.261	0.003**
Ramus inclination	-0.130	0.150	0.240	0.007**
L1-MP angle	0.044	0.628	0.258	0.004**
ANB angle	-0.534	<0.001**	-0.426	<0.001**

**Highly significant *P* ≤ 0.01, R-value: 0.5–0.7: large correlation, 0.7–0.9: Very large correlation, 0.9–1.0: Nearly perfect correlation, s1: Perfect correlation

different stages and Kruskal Wallis test was used to find the significance of the angular measurements between the

different stages. Student's *t*-test (two-tailed, independent) was used to determine the significance of the linear measurements between males and females and Mann-Whitney *U*-test was used to find the significance of angular measurements between males and females.

Results

Males showed a greater mandibular height at all stages of skeletal maturity, except in stage H. A highly significant difference was found between males and females in stage FG (Equal length of Epiphysis and Diaphysis). Similarly, a significantly greater mandibular length was observed in males. Symphysis thickness was found to be higher only in stages F, G and H of females. A significant difference in angle SNB was observed between males and females.

Angle Sella Nasion- Mand plane was found to be significantly higher in females at stage FG. In comparison, the mean values

of the Y-axis were observed to be lower in females, except in stage H, wherein a significantly higher value was seen. Females showed significantly greater gonial angles when compared with males in stages FG and G. Females showed a lower value of ramus inclination in all the stages except stage H and stage I. In stage G, it was noted that the ramus inclination for males was 89° and for females, this was 85.44°. This difference was highly significant. Females showed a significantly lesser value of L1-MP only in stage F. There was no significant difference in angle ANB between males and females [Tables 3 and 4].

Discussion

Knowledge on facial growth and development is essential because various treatment modalities, such as rapid palatal expansion and myofunctional therapy, take place during the growth period.^[4]

Growth of the mandible has unique characteristics of size and time of peak growth velocity. It also plays a major role in the development of the anteroposterior relationship between the mandible and the maxilla.^[7] To understand mandibular growth better, and to apply this knowledge clinically, it is important to study the changes occurring in the mandible during the various stages of skeletal maturity. A simple, yet practical and economical, indicator of skeletal maturity is the use of MP3 stages as recorded on an intraoral periapical radiograph.^[3]

As reported^[7] earlier, it was observed that the mandibular ramus height and length in both sexes demonstrated a progressive increase in dimensions during all stages of skeletal maturity. The increase in the height and length was significant at puberty and thereafter. This reiterates the key role of the ramus in placing the corpus and dental arch into an ever-changing fit, with the growing maxilla and face's limitless structural variation. This is provided by critical remodeling and adjustment in the ramus alignment.^[8] One feature of mandibular growth is an accentuation of chin prominence. This was reflected by the overall increase in symphysis thickness in our study.

Angle SNB determines the anteroposterior position of the mandible in relation to the anterior cranial base. In our study, females showed a significant increase in angle SNB from pre-pubertal stage to puberty. On an average, females showed a slightly higher angle SNB. These observations can be attributed to earlier general and facial growth in females.

Angle SN-MP (Sella Nasion- Mand plane) gives the inclination of the mandible to the anterior cranial base. The mean value of angle SN-MP is 32°. An age-dependent decrease from 36° to 31° has been observed between the ages of 6 and 16 years.^[9] In our study, angle SN-MP showed a total decrease of 7° and 4° in males and females, respectively. The 15° internal rotation and 11°–12° external and backward rotation could

be responsible for this decrease. According to Proffit, one of the features of internal rotation of the mandible is variation between individuals.^[10] This could explain the slightly higher decrease seen in males.

In our study, there was a cumulative increase in the Y-axis in both sexes, suggestive of vertical growth exceeding horizontal growth of the mandible. This is in accordance with other south Indian studies.^[11,12] The value of the Y-axis needs to be evaluated at an early age, especially in those children who exhibit severe vertical problems.^[10] However, any treatment initiated at this stage should proceed because vertical growth continues into the adolescent and post-adolescent stages.

Gonial angle and ramus inclination express the form of the mandible with reference to the relation between body and ramus and cranial base, respectively. The large gonial angle observed during childhood gradually decreases with increasing age due to uprighting of the ramus.^[10] In our study also there was a significant reduction in gonial angle over the various stages of observation in both males and females. Ramus inclination was observed to decrease with skeletal maturity in females, whereas an overall increase was seen in males. Although the mandible of both males and females grows in the same direction, such differences could be due a change in the shape of the gonion. This suggests that there is more bone deposition on the posterior border than on the lower border of the gonion in males.

The rotational pattern of jaw growth influences the magnitude and direction of tooth eruption as well as the ultimate anteroposterior position of the incisor teeth. The normal internal rotation of the mandible carries the jaw upward in front. Due to the internal jaw rotation, the incisors are uprighted and the molars migrate further mesially during growth than do the incisors. In our study, an obtuse lower incisor mandibular plane angle was observed at all levels of skeletal maturity in both genders. The wide angle denotes protrusion of the mandibular incisors, as was also observed in South Kanara children.^[11] In another study on Japanese children, the angle L1-MP decreased, probably due to changes caused by mandibular growth and lingual tipping of the lower incisors to compensate for the forward growth of the mandible.^[7] According to Nanda, the vertical and anteroposterior positions of the incisors are affected by short face and long face individuals.^[13] During the development of occlusion, the permanent lower incisors erupt lingually and then position themselves more labially. This could explain the increase in lower incisor mandibular plane angle in our study. Also, according to Rakosi, this angle increases from 88° at 6 years to 94° at 12 years.^[9]

Riedel introduced angle ANB, which has become the most commonly used parameter in orthodontics and helps in assessing the relationship of maxillary and mandibular bases in the sagittal plane.^[14] In our study, this angle showed a

gradual decrease from pre-puberty to post-pubertal stages in both males and females. As reported in earlier studies, this reduction is attributed to the age-related reduction in sagittal distance.^[8,9]

The knowledge about changes in the mandible is incomplete without knowing its correlation with skeletal maturity. It is important in identifying the most efficient starting point for orthodontic treatment along the progressive path of adolescent growth.^[15] Although a significant association between skeletal maturity and facial growth has been demonstrated, correlation between skeletal maturity and specific components of craniofacial growth has been found to be less.^[16] In our study, females showed a better correlation between skeletal maturity and growth changes in the mandible. A variable degree of correlation was observed between different parameters and skeletal maturity. This finding can be due to the variable correlation strength between the mandibular growth velocity and the skeletal maturity observed in previous studies.

The present study shows that there is a significant correlation between mandibular growth and skeletal maturity. It thus confirms the findings of previous studies^[10,17] that skeletal maturity assessment provides a more valid basis than chronological age for grouping individuals. Studies on further classification of subjects based on maturity levels would be a useful means of identifying the child's position along the progressive path of growth. Maturity level is used to associate an individual's maturational age with the chronological age, and indicates whether the development is average, advanced or delayed.^[15] Future studies on skeletal maturity and facial growth can be performed using longitudinal data.

References

1. Swain G. Current concepts of orthodontics. USA: Saunders

- Publication; 2nd ed. 1975.
2. Buschang, Martins J. Childhood and adolescent changes of skeletal relationships. *Angle Orthod* 1998;68:199-208.
 3. Madhu S, Hegde AM, Munshi AK. The developmental stages of the middle phalanx of the third finger (MP3): A sole indicator in assessing the maturity? *J Clin Pediatr Dent* 2002;27:149-56.
 4. Gomes AS, Lima EM. Mandibular growth during adolescence. *Angle Orthod* 2006;76:786-9.
 5. Hagg U, Taranger J. Skeletal stages of hand and wrist as indicators of pubertal growth spurt. *Acta Odontol Scand* 1980;38:187-200.
 6. Tsai H. A study of growth changes in the mandible from deciduous to permanent dentition. *J Clin Pediatr Dent* 2003;27:137-42.
 7. Mitani H, Sato K. Comparison of mandibular growth with other variables during puberty. *Angle Orthod* 1992;62:217-22.
 8. Enlov DH. Facial growth. USA: W.B Saunders Publications; Philadelphia, 3rd ed. 1990.
 9. Rakosi T. An Atlas and Manual of Cephalometric Radiography . Arizona, Wolfe Publishing. 3rd ed. 1997.
 10. Proffit W. Contemporary orthodontics. 3rd ed. UK: Mosby Publication; 2000.
 11. Abraham K, Tandon S. Selected cephalometric norms in South Kanara children. *J Indian Soc Pedo Prev Dent* 2000;18:94-102.
 12. John KK, Ashima V. Tweed's analysis on normal occlusion and class II and class III malocclusion in adults from Kerala. *J Dent Assoc* 1991;62:179-81.
 13. Nanda R, Nanda RS. Cephalometric study of the dentofacial complex of North Indians. *Angle Orthod* 1969;39:22-8 .
 14. Lux J, Burden D, Conrad C, Komposch G. Age related changes in sagittal relationship between the maxilla and mandible. *Eur J Orthod* 2005;27:568-78.
 15. Sidlauskas A, Zillinskaite L, Svalkauskiene V. Mandibular pubertal growth spurt prediction. Part one: Method based on hand wrist radiographs. *Stomatolgia* 2005;7:16-20.
 16. Flores B, Nebbe MP. Use of skeletal maturation based on hand-wrist radiographic analysis as a predictor of facial growth: A systematic review. *Angle Orthod* 2004;74:118-24.
 17. Hussam M, Kader A. The reliability of dental X-ray film in assessment of MP3 stages of the pubertal growth spurt. *Am J Orthod Dentofac Orthop* 1998;114:427-9.

Source of Support: Nil, Conflict of Interest: None declared.

Author Help: Reference checking facility

The manuscript system (www.journalonweb.com) allows the authors to check and verify the accuracy and style of references. The tool checks the references with PubMed as per a predefined style. Authors are encouraged to use this facility, before submitting articles to the journal.

- The style as well as bibliographic elements should be 100% accurate, to help get the references verified from the system. Even a single spelling error or addition of issue number/month of publication will lead to an error when verifying the reference.
- Example of a correct style
Sheahan P, O'leary G, Lee G, Fitzgibbon J. Cystic cervical metastases: Incidence and diagnosis using fine needle aspiration biopsy. *Otolaryngol Head Neck Surg* 2002;127:294-8.
- Only the references from journals indexed in PubMed will be checked.
- Enter each reference in new line, without a serial number.
- Add up to a maximum of 15 references at a time.
- If the reference is correct for its bibliographic elements and punctuations, it will be shown as CORRECT and a link to the correct article in PubMed will be given.
- If any of the bibliographic elements are missing, incorrect or extra (such as issue number), it will be shown as INCORRECT and link to possible articles in PubMed will be given.