

Combined special capsular tension ring and toric IOL implantation for management of post-DALK high regular astigmatism with subluxated traumatic cataract

Asim Kumar Kandar

We report a case of 18-year-old male who has undergone phacoemulsification with implantation of toric IOL (AcrySof IQ SN6AT9) after fixation of lens capsule with Cianni's capsular

Department of Ophthalmology, Vasan Eye Care Hospital, Puducherry, India

Correspondence to: Dr. Asim Kumar Kandar, Department of Ophthalmology, Cataract, Cornea and Refractive Surgery Services, Vasan Eye Care Hospital, No. 1, Villupuram Main Road, Puducherry - 605 005, India. E-mail: asimkk.aiims@gmail.com

Manuscript received: 21.07.13; Revision accepted: 17.02.14

tension ring (CTR) for subluxated traumatic cataract with high astigmatism after deep anterior lamellar keratoplasty (DALK). He underwent right eye DALK for advanced keratoconus four years earlier. He had history of trauma one year later with displaced clear crystalline lens into anterior chamber and graft dehiscence, which was repaired successfully. The graft survived, but patient developed cataract with subluxated lens, for which phacoemulsification with implantation of toric IOL was done. Serial topography showed regular corneal astigmatism of -5.50 diopter (K_1 42.75 D @130°, K_2 48.25 D @40°). At 10-month follow-up, the patient has BCVA 20/30 with + 0.75 DS/- 1.75 DC @ 110°. The capsular bag is quite stable with well-centered IOL. Combination of Cianni's ring

Access this article online

Quick Response Code:



Website:

www.ijo.in

DOI:

10.4103/0301-4738.138294

with toric IOL could be a good option to manage such complex cases.

Key words: Capsular tension ring, DALK, post-keratoplasty astigmatism, subluxated cataract, toric IOL

Management of post-keratoplasty cataract with high astigmatism consists of safe removal of cataract and effective treatment of astigmatism by various methods like spectacles, contact lenses, arcuate keratotomy with compression sutures or astigmatic keratotomy with femtosecond laser,^[1] photorefractive keratectomy, LASIK,^[2] intracorneal ring segments, and toric IOLs. At present, phacoemulsification with toric IOL implantation has become the preferred way to manage such cases.^[3-8] But, presence of lens capsule subluxation makes the situation more challenging. We have successfully managed such a case of post-DALK traumatic subluxated cataract and high astigmatism with the help of Cionni's ring (CTR) and toric IOL implantation. According to PubMed search, this is the first of its kind where Cionni's ring and toric IOL have been implanted in post-DALK high corneal astigmatism.

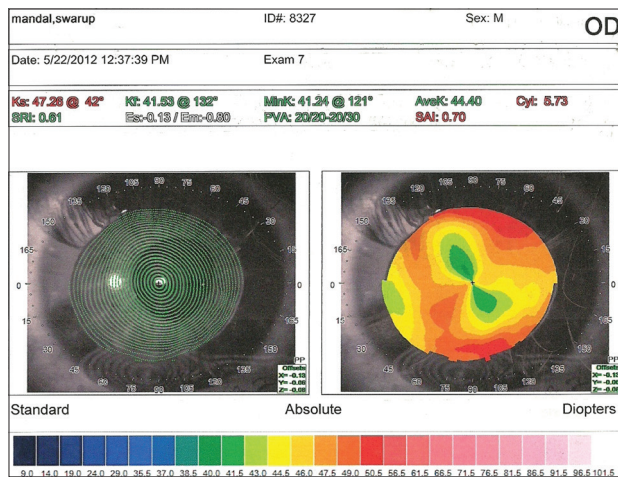


Figure 1: Topography of right eye showing regular astigmatism of 5.73 diopter at 42° axis

Case Report

Initially, a 14-year-old male was diagnosed with bilateral advanced keratoconus with apical scarring in right eye. The patient underwent successful deep anterior lamellar keratoplasty (DALK) using Anwar's big-bubble technique in right eye, gaining BCVA of 20/30. After one and half years, he sustained blunt injury to the operated eye that led to graft dehiscence and partial subluxation of crystalline lens into anterior chamber. Emergency lens removal was avoided. Instead, it was retained by formation of anterior chamber with viscoelastic, thus pushing the lens back into its original position. The graft dehiscence was sutured with 10-0 nylon. At the end of surgery, viscoelastic was removed and the anterior chamber was formed with air. The graft survived, and the secondary sutures were removed after one year. There was progressive loss of vision due to development of cataract in the subluxated lens. To see the stability of astigmatism, serial topography was performed over a period of one and half years, which showed regular astigmatism of approximately-5.50 diopter around 40° axis [Figs. 1 and 2].

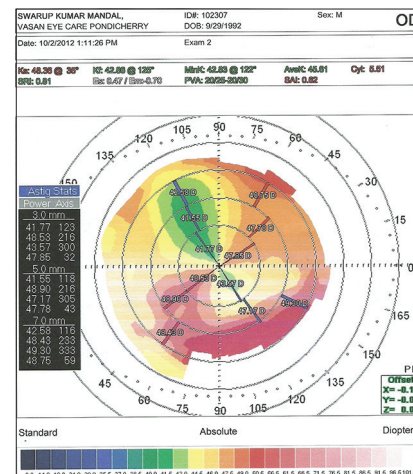


Figure 2: Topography of right eye after five months showing astigmatism of 5.51 diopter at 35° axis

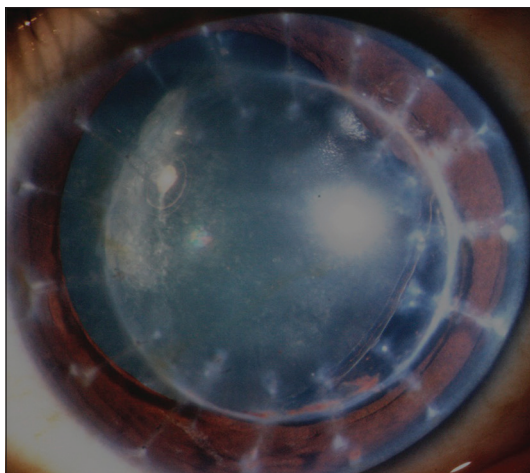


Figure 3: Superior temporal subluxation of lens with posterior subcapsular cataract and scar marks of sutures and graft-host junction

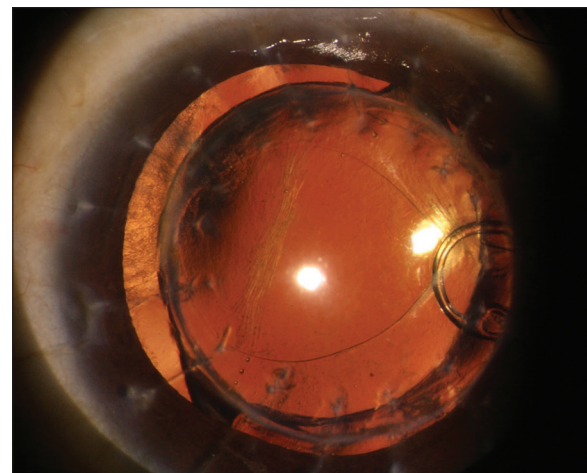


Figure 4: Visible Cionni's ring hook with well centered toric IOL (AcrySof IQ SN6AT9) *in situ* with toric marks. Preexisting posterior capsule fibrosis is also noted

On examination, patient had BCVA of 20/200 OD and BCVA of 20/40 OS with RGP contact lens. Slit-lamp examination of the right eye revealed clear corneal graft with mild interface haze of DALK and scar marks of sutures and graft-host junction. The lens showed visible subluxation of about 180° superior-temporally and posterior subcapsular cataract with mild fibrosis of posterior capsule [Fig. 3]. The keratometry readings were taken from IOL Master (K_1 42.61 D @131° and K_2 48.42 D @41°), Topography (K_1 42.85 D @125° and K_2 48.36 @35°), and manual keratometry (K_1 42.75 D @130° and K_2 48.25 D @40°). All the keratometry values were corroborating well, and spherical power of IOL suggested by IOL Master was + 19.50 D. Manual keratometry reading was considered for toric IOL, and according to Alcon Toric IOL power calculator, the lens suggested was AcrySof IQ SN6AT9 (19.50 D SE and Cyl: 6.00 D @41°) with residual cylinder power of 1.62 D @ 41° (SIA: 0.30 D and IL: 150°).

The patient underwent phacoemulsification after placement of markings for toric IOL, with special surgical considerations for the corneal graft. Upright reference markings were applied to avoid supine cyclo-torsion. Intraoperatively, 2.8 mm limbal incision was made at 150°, and axis of IOL placement was marked at 41° using Mendez ring and Nuijts toric axis marker. Graft endothelium was coated with Viscoat, Alcon Lab (3% sodium hyaluronate +4% chondroitin sulfate). A Hoffman reverse pocket was made at limbus near subluxation area for fixation of Cionni's ring.^[9] Well-centered, approximately 5-mm continuous curvilinear capsulorhexis was completed. Subluxated capsule was held by iris hooks and gentle multi-quadrant hydro dissection was done followed by lens aspiration. Cionni's ring was fixed with 9-0 prolene using rail-road technique (the floss is smoothed down with a tapestry needles, and floss strands lay side-by-side like the rails of a railroad track). All precautions were taken to position the hooks of Cionni's ring at center of subluxation, thus distributing the force of 9-0 prolene evenly and having a perfectly stable capsule. IOL was implanted within capsular bag, and axis was aligned at 41°. Hoffman pocket was closed with fibrin glue. For perfect centration of toric IOL, stability of the capsular bag is most important. We made sure that the hook of Cionni's ring is placed at the center of subluxation, thus distributing the force of 9-0 suture evenly and having a perfectly stable capsule. Care was taken to avoid sudden decompression of the anterior chamber throughout the surgery.

Postoperative period was uneventful, and at six weeks, BCVA was 20/30 with + 0.75 DS/-1.75 DC at 110°. At 10-month follow-up, the patient is maintaining BCVA of 20/30 with stable capsule and no significant rotation of toric IOL [Fig. 4].

Discussion

Toric IOL has become a standard management option for correction of post-keratoplasty cataract with high astigmatism.^[3-8]

Use of capsular tension ring (CTR) to stabilize the lens capsule bag complex and toric IOL implantation have been reported only in two occasions before. Rekas *et al.* has reported a case of megalocornea and co-existing corneal astigmatism with nuclear sclerotic cataract where corneal astigmatism was corrected by implanting an AcrySof toric intraocular lens (IOL). The IOL was stabilized by suturing it to a CTR and placing the IOL-CTR complex into lens capsule and aligned

with the steep meridian of corneal astigmatism with good outcome.^[9]

Amm and Halberstadt reported use of CTR due to intraoperative zonular subluxation in a case of their experiences of toric PMMA IOL in three patients with cataracts and high astigmatism after keratoplasty.^[4]

In our case, there were two challenges: Correction of astigmatism as well as lens capsule fixation to provide stability to the toric IOL. As the astigmatism is regular and stable on serial topography, we planned to go for permanent solution. LASIK was not considered suitable because of history of graft dehiscence, and the astigmatism was quite high (-5.50 D). Toric IOL was a preferred option. Other options were to go for spherical IOL followed by RGP contact lens. Spherical IOL wouldn't induce any aberration and possibility of better visual quality, but more important issue was to take care of high astigmatism. Although patient was using RGP lens in other eye, we did not consider it to be a preferred option for this eye because of long-term implications. Instead, toric IOL is a proved technology for post-keratoplasty astigmatism. We preferred AcrySof IQ toric IOL because of its superior long-term rotational stability.^[10] The residual astigmatism was managed easily with the help of spectacle. Another challenge was proper fixation of lens capsule as it was a case of post-traumatic subluxation with mild fibrosis in posterior capsule. It was managed successfully with the help of Cionni's capsular tension ring (CTR). Other options for fixing subluxated lens capsule would be capsular tension segment (CTS) combined with CTR. Sometimes, Cionni's ring with double hooks may be a preferred choice, especially when the subluxation is progressive in nature like Marfan's syndrome, pseudoexfoliation etc., We preferred single hook Cionni's ring because of moderate subluxation of 180° and non-progressive in nature.

Due to adequate size and shape of capsulorhexis and the subluxation non-progressive in nature, the stability of Toric IOL is good at 10-month follow-up.

In conclusion, our case is the first example of its kind where even if multiple challenges are present, they have been managed successfully with single intervention of phacoemulsification followed by lens capsule fixation with CTR and effective astigmatism management with AcrySof IQ Toric IOL.

References

1. Bahar I, Levinger E, Kaiserman I, Sansanayudh W, Rootman DS. IntraLase-enabled astigmatic keratotomy for postkeratoplasty astigmatism. *Am J Ophthalmol* 2008;146:897-904.e1.
2. Busin M, Zambianchi L, Garziona F, Maucione V, Rossi S. Two-stage laser *in situ* keratomileusis to correct refractive errors after penetrating keratoplasty. *J Refract Surg* 2003;19:301-8.
3. Rekas M, Pawlik R, Kluś A, Różycki R, Szaflik JP, Ołdak M. Phacoemulsification with corneal astigmatism correction with the use of a toric intraocular lens in a case of megalocornea. *J Cataract Refract Surg* 2011;37:1546-50.
4. Amm M, Halberstadt M. Implantation of toric intraocular lenses for correction of high post-keratoplasty astigmatism. *Ophthalmologie* 2002;99:464-9.
5. Feizi S, Zare M. Current approaches for management of postpenetrating keratoplasty astigmatism. *J Ophthalmol* 2011;2011:708736.
6. de Sanctis U, Eandi C, Grignolo F. Phacoemulsification and

- customized toric intraocular lens implantation in eyes with cataract and high astigmatism after penetrating keratoplasty. *J Cataract Refract Surg* 2011;37:781-5.
7. Gupta N, Ram J, Chaudhary M. AcrySof toric intraocular lens for post-keratoplasty astigmatism. *Indian J Ophthalmol* 2012;60: 213-5.
 8. Scoria V, Lucisano A, Beltz J, Busin M. Combined Descemet-stripping automated endothelial keratoplasty and phacoemulsification with toric intraocular lens implantation for treatment of failed penetrating keratoplasty with high regular astigmatism. *J Cataract Refract Surg* 2012;38:716-9.
 9. Hoffman RS, Fine IH, Packer M. Scleral fixation without conjunctival dissection. *J Cataract Refract Surg* 2006;32:1907-12.
 10. Mendicuti J, Irigoyen C, Aramberri J, Ondarra A, Montés-Micó R. Foldable toric intraocular lens for astigmatism correction in cataract patients. *J Cataract Refract Surg* 2008;34:601-7.

Cite this article as: Kandar AK. Combined special capsular tension ring and toric IOL implantation for management of post-DALK high regular astigmatism with subluxated traumatic cataract. *Indian J Ophthalmol* 2014;62:819-22.

Source of Support: Nil. **Conflict of Interest:** None declared.