



OPEN ACCESS

## CASE REPORT

# Giant cell tumour of the middle phalanx of the middle finger

Nath Adulkasem,<sup>\*</sup> Dumnoensun Pruksakorn

Orthopaedics Surgery, Chiang Mai University, Chiang Mai, Thailand

**Correspondence to**

Dr Dumnoensun Pruksakorn, dumnoensun@hotmail.com

Accepted 9 March 2019

**SUMMARY**

Giant cell tumour (GCT) of bones in the hand is very rare, only 2% of all hand tumours, but unacceptably high recurrence rates (up to 90%) have been reported by several authors. Diagnosis can be challenging due to its rarity and enchondroma-mimicking characteristics. We report on a case of GCT of the middle phalanx of the left middle finger in a 49-year-old woman who underwent middle phalanx resection and reconstruction with bone grafting. At the 1-year follow-up, no evidence of recurrence was detected and the patient was pain-free.

**BACKGROUND**

Giant cell tumour (GCT) of bones is one of the most common benign bone tumours and usually involves the metaphysis-epiphysis region of long bones, especially the distal femur, although occurrences in other regions have been reported.<sup>1</sup> The hand is one of the rarest sites for bone GCT, but it has a high recurrence rate and can easily be misdiagnosed.<sup>2,3</sup> Careful examination, complete investigation and optimum follow-up scheduling are key to avoiding a misdiagnosis.

**CASE PRESENTATION**

A healthy, active, 49-year-old woman initially presented to our team in January 2017 with a history of pain, tenderness and swelling in the left middle finger following a minor trauma to her right hand 1 year previously. She denied any history of constitutional symptoms. Physical examination showed a swollen and tender mass with firm consistency at the middle phalanx of the middle finger of the left hand. Range of motion of the adjacent joints (distal interphalangeal and proximal interphalangeal joints) was preserved and capillary refill time was normal.

**INVESTIGATIONS**

Plain radiography showed a geographic osteolytic lesion on the shaft of the middle phalanx of the left middle finger with a well-defined sclerotic border; no periosteal reaction or fracture line were seen (arrow, [figure 1](#)). The long-term onset of clinical symptoms with occasional pain was compatible with repeated fracture and healing of the sclerotic rim. MRI was requested for local extension and primary carcinoma identification. Evaluation showed a hypointense solid intramedullary lesion with hyperintense surrounding soft tissue. Enchondroma with pathological fracture was considered

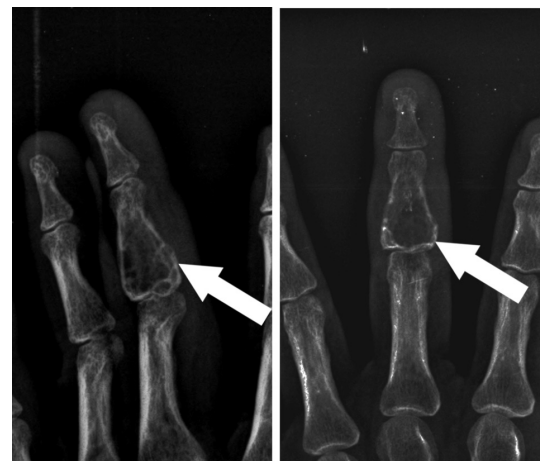
the most likely diagnosis, and the patient was scheduled for follow-up in 6 months. At that 6-month follow-up, the patient showed no improvement in the swelling or pain. A plain radiograph showed progression of an expansile osteolytic lesion with articular involvement (arrow, [figure 2](#)) indicating an aggressive tumour with cortical extension and articular involvement. Repeat chest radiographs showed no evidence of pulmonary metastasis. An incisional biopsy was performed in July 2017, 6 months after the initial visit. Histopathology was compatible with giant cell bone tumour and was classified as Campanacci stage III.

**DIFFERENTIAL DIAGNOSIS**

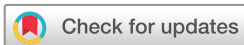Based on the Initially benign characteristics and epidemiology, there was a differential diagnosis at the 6-months follow-up. Based on radiography and the history of progression, GCT, chondrosarcoma (secondary to enchondroma) and acrometastasis were considered due to the tumour's aggressiveness.

**TREATMENT**

Middle phalanx resection and interphalangeal joint arthrodesis with iliac bone graft were performed following the diagnosis. Since the lesion involved nearly the entire middle phalanx with some local invasion, tumour resection was chosen rather than the standard extended curettage to help insure there was no residual tumour. No immediate complications were observed. Since there was no evidence

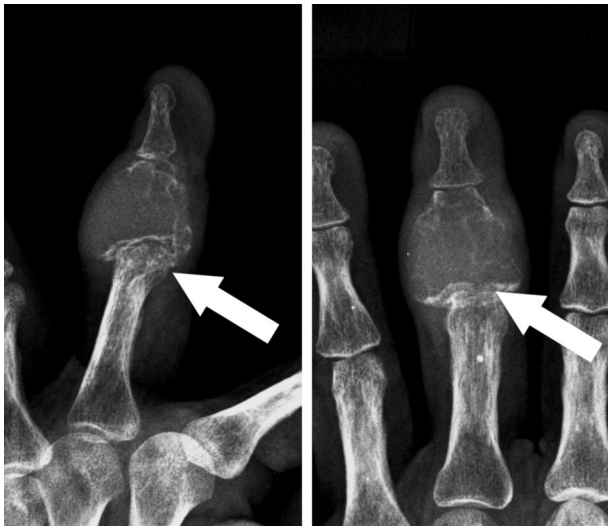

**Figure 1** First visit: a well-defined geographic lesion with sclerotic border resembling enchondroma was described.



© BMJ Publishing Group Limited 2019. Re-use permitted under CC BY-NC. No commercial re-use. See rights and permissions. Published by BMJ.

**To cite:** Adulkasem N, Pruksakorn D. *BMJ Case Rep* 2019;**12**:e229076. doi:10.1136/bcr-2018-229076



**Figure 2** Six-months follow-up: an expansile geographic osteolytic lesion was identified by radiographic study.

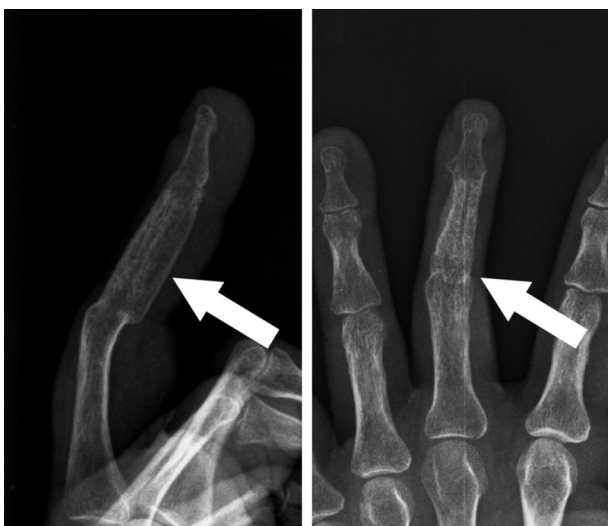of metastasis, no systemic treatments were scheduled for this patient.

#### OUTCOME AND FOLLOW-UP

At the 1-year follow-up, the patient's middle phalanx was pain-free with some functional attenuation due to phalangeal fusion. A plain radiograph revealed a union of the middle phalanx with no sign of GCT recurrence (figure 3).

#### DISCUSSION

GCT of bone is one of the most common benign or locally aggressive bone tumours, especially in the epiphysis region.<sup>2</sup> Peak incidence of GCT occurs in the third and fourth decades of life.<sup>4</sup> GCT in the hand has been noted as a rare location, with only 2% of reported cases.<sup>2,3</sup> Early radiographic signs can resemble enchondroma and are likely to be misdiagnosed by general practitioners or even by orthopaedists. However, the aggressive behaviour, for example, the progressiveness and painfulness, can help distinguish GCT from other benign tumours. Additionally, more rapid growth and a higher recurrence rate



**Figure 3** One-year follow-up: radiographic view of fused middle finger with no sign of recurrence.

are observed in GCT in the hand region compared with conventional types.<sup>3</sup> Clinical presentation includes pain with or without signs of inflammation. Since the natural history of this tumour is quite benign, most cases will have insidious and progressive localised pain.<sup>5</sup> Range of motion can be limited if the lesion lies adjacent to a joint. Some cases, however, present with a pathological fracture but with no prior history.<sup>5,6</sup> Once GCT of bone is suspected, plain radiography is the easiest and should be the first means of investigation. Radiography can highlight the expanding zone of radiolucency, usually in the end of a long bone between the metaphysis and the epiphysis. The lesions can be either well or poorly marginated without a sclerotic border. Periosteal reaction is rarely seen.<sup>1</sup> Campanacci described three grades of disease using radiological findings. At the higher grade, a positive correlation with aggressiveness and high recurrence rate has been reported. Grade I is defined as having a well-defined margin with thin rim. In grade II, lesions involve a larger area and extend to the cortical layer without the breakage which is the defining feature of grade III.<sup>7</sup>

MRI is the tool of choice for investigating GCT since it is capable of demonstrating the extent of the lesion as well as identifying any extraosseous lesions. CT is also useful in structural evaluation. The thin sclerotic rim, visible in a CT scan, helps distinguish GCT from malignancy. To date, even with the most advanced techniques, imaging of features in GCT of bone in the hand is not sufficiently specific; images of GCT can resemble many other kinds of bone lesions, especially enchondroma which are more common in the hand region. For that reason, tissue diagnosis is mandatory.<sup>1,7</sup> Gross pathology characteristics of GCT of bone usually include a dark brown colour and soft to firm consistency with an area of fibrosis and osteoid production. Blood-filled cystic lesions can be seen. The histopathological hallmark of GCT of bone is the classic multinucleated giant cells of the osteoclast from which osteoclastoma derives its name. Mitotic activity can be seen without nuclear atypia. Clinical presentation, imaging and tissue examination results should be correlated in making a diagnosis. A chest radiograph should be routinely requested as a preoperative requirement, and to check for pulmonary metastasis. CT can also help detect such lesions. Extended curettage with a high-speed burr is currently the treatment of choice for GCT.<sup>8</sup> In addition, multiple modalities of cavity adjuvant treatment are now widely used to achieve adequate local control, with a 6%–25% recurrence rate.<sup>8–10</sup> Thermal adjuvants include freezing, eg, with liquid nitrogen, and heating, eg, with polymethyl methacrylate and argon beam cauterisation. Cytotoxic agents can be used as chemical adjuvants, eg, phenol.<sup>1</sup> En bloc resection is reserved as the treatment of last resort in cases of uncontrolled recurrence.<sup>11</sup>

The local recurrence rate is highest in the first 24 months following treatment, ranging from 4% to 30%.<sup>12</sup> Follow-up should be scheduled with serial physical examination and imaging of the surgical site as well as a routine chest radiograph. GCT of bone in the hand region has been recognised as having a higher recurrence rate compared with more usual sites.<sup>7,13</sup> Treatment protocol, however, remains the same as for GCT of bone at the more common sites. Recurrence rates in the hand area have been reported to be as high as 20%–90% in some series.<sup>3,13</sup> Several authors have reported success in recurrent cases with management using intralesional curettage with adjuvants, excision and reconstruction or ray amputation.<sup>3,14</sup> In the present case, tumour resection and bone grafting were performed because adequate extended curettage could not be accomplished in such a small site. Regular follow-ups were scheduled. No

signs of recurrence were detected at the first year follow-up. Due to the high rate of recurrence, regular close follow-up should be conducted. Systemic control can also be beneficial in both unresectable and metastatic cases. Monthly denosumab administration has shown promising results, with significant improvement in both gross and histopathological evaluations.<sup>15 16</sup> Although intravenous bisphosphonate also reduces both systemic and local recurrences, denosumab was shown to be more effective in a phase III trial, making it the preferred choice.<sup>16</sup>

Clinical approaches to treating bone and soft tissue tumours should be based on clinical presentation, epidemiology and imaging as well as histopathology to obtain an accurate diagnosis before deciding on a course of treatment. However, as a practical matter, in many cases suspect benign lesions are not able to receive a complete investigation due to limited available resources. That makes this a most challenging situation, especially for a general orthopaedist who may lack experience in interpreting rare events such as this. This case report is an example of appropriate initial management. Symptoms duration, patient age and radiographic findings are important initial clues that can help narrow down the differential diagnosis. In this case, at the first visit a radiographic study showed a confined geographic osteolytic lesion in the shaft of the middle phalanx of the left middle finger without articular involvement. In combination with the insidious clinical symptoms, the radiological findings were most compatible with enchondroma, the most common benign tumour of the phalanges.<sup>17</sup> However, other rare bone tumours, including acrometastasis of carcinoma, must be considered as a differential diagnosis. Therefore, a shorter follow-up period of 2–6 weeks after the initial presentation is strongly recommended for general orthopaedists facing a suspected 'benign bone lesion'. Non-progression of the lesion at follow-up can indicate a slow progressing pathology. Aggressive behaviour of a benign lesion or other malignant lesion would be illustrated by progression in the radiographic study. A delay in progression detection of 1–2 months could change the entire direction of management. Action to detect metastatic lesions during the initial examination should be considered in patients older than 45 years due to the high prevalence of metastatic bone lesion in that age group.<sup>18</sup> In

such cases, complete physical examination and simple laboratory investigations should be standard procedure.

Short term follow-up with plain radiographic study and MRI is recommended for non-tissue diagnosis of benign-like bony lesions. However, tissue diagnosis should be performed if there are any suspicious clinical progression or imaging studies.

**Acknowledgements** I would like to express my thanks to Dr Lamar Robert for English language editing and review.

**Contributors** NA: conception and design, literature review, manuscript drafting, image processing, submitting. DP: conception and design, surgeon, patient contact, critically for important intellectual content.

**Funding** The authors have not declared a specific grant for this research from any funding agency in the public, commercial or not-for-profit sectors.

**Competing interests** None declared.

**Patient consent for publication** Obtained.

**Provenance and peer review** Not commissioned; externally peer reviewed.

**Open access** This is an open access article distributed in accordance with the Creative Commons Attribution Non Commercial (CC BY-NC 4.0) license, which permits others to distribute, remix, adapt, build upon this work non-commercially, and license their derivative works on different terms, provided the original work is properly cited and the use is non-commercial. See: <http://creativecommons.org/licenses/by-nc/4.0/>

## REFERENCES

- Biermann JS. *Musculoskeletal Tumour S. OKU 3: orthopaedic knowledge update*, 1:12014.
- Averill RM, Smith RJ, Campbell CJ. Giant-cell tumors of the bones of the hand. *J Hand Surg Am* 1980;5:39–50.
- Patel MR, Desai SS, Gordon SL, et al. Management of skeletal giant cell tumors of the phalanges of the hand. *J Hand Surg Am* 1987;12:70–7.
- Arslan G, Karaali K, Cubuk M, et al. Giant cell tumor of the fourth metacarpal bone. *Clin Imaging* 2000;24:139–42.
- Azar FM, Canale ST, Beaty JH, et al. *Campbell's operative orthopaedics*, 2017.
- Gruenewald N, Demos TC, Lomasney LM, et al. The case. Giant-cell tumour. *Orthopedics* 2006;29:167–71.
- Turcotte RE. Giant cell tumor of bone. *Orthop Clin North Am* 2006;37:35–51.
- Becker WT, Dohle J, Bernd L, et al. Local recurrence of giant cell tumor of bone after intralesional treatment with and without adjuvant therapy. *J Bone Joint Surg Am* 2008;90:1060–7.
- Lin WH, Lan TY, Chen CY, et al. Similar local control between phenol- and ethanol-treated giant cell tumors of bone. *Clin Orthop Relat Res* 2011;469:3200–8.
- Algawahmed H, Turcotte R, Farrokhvar F, et al. High-speed burring with and without the use of surgical adjuvants in the intralesional management of giant cell tumor of bone: a systematic review and meta-analysis. *Sarcoma* 2010;2010:1–5.
- Yu XC, Xu M, Song RX, et al. Long-term outcome of giant cell tumors of bone around the knee treated by en bloc resection of tumor and reconstruction with prosthesis. *Orthop Surg* 2010;2:211–7.
- Cho HS, Park IH, Han I, et al. Giant cell tumor of the femoral head and neck: result of intralesional curettage. *Arch Orthop Trauma Surg* 2010;130:1329–33.
- Ropars M, Kaila R, Cannon SR, et al. Primary giant cell tumours of the digital bones of the hand. *J Hand Surg Eur Vol* 2007;32:160–4.
- Raskin KA, Schwab JH, Mankin HJ, et al. Giant cell tumor of bone. *J Am Acad Orthop Surg* 2013;21:118–26.
- Blay J, Chawla SP, Martin Broto J, et al. Denosumab safety and efficacy in giant cell tumor of bone (GCTB): Interim results from a phase II study. *J Clin Oncol* 2011;29(15 suppl):10034.
- Xu SF, Adams B, Yu XC, et al. Denosumab and giant cell tumour of bone—a review and future management considerations. *Curr Oncol* 2013;20:e442–e7.
- Tang C, Chan M, Fok M, et al. Current management of hand enchondroma: a review. *Hand Surg* 2015;20:191–5.
- Phanphaisarn A, Patumanond J, Settakorn J, et al. Prevalence and survival patterns of patients with bone metastasis from common cancers in Thailand. *Asian Pac J Cancer Prev* 2016;17:4335–40.

## Learning points

- ▶ Giant cell tumour (GCT) of bone in the hand region is rare and is likely to be misdiagnosed as the more common enchondroma.
- ▶ GCT of bone in the hand has a high recurrence rate.
- ▶ Complete physical examination and timely short-term follow-up is mandatory with benign-like lesions.
- ▶ Short term follow-up with a plain radiographic study and MRI is recommended for non-tissue diagnosis of benign-like bony lesions.
- ▶ Tissue diagnosis should be performed in cases where there is either suspicious clinical progression or suspicious imaging studies.

Copyright 2019 BMJ Publishing Group. All rights reserved. For permission to reuse any of this content visit <https://www.bmj.com/company/products-services/rights-and-licensing/permissions/>  
BMJ Case Report Fellows may re-use this article for personal use and teaching without any further permission.

Become a Fellow of BMJ Case Reports today and you can:

- ▶ Submit as many cases as you like
- ▶ Enjoy fast sympathetic peer review and rapid publication of accepted articles
- ▶ Access all the published articles
- ▶ Re-use any of the published material for personal use and teaching without further permission

For information on Institutional Fellowships contact [consortiasales@bmjgroup.com](mailto:consortiasales@bmjgroup.com)

Visit [casereports.bmj.com](http://casereports.bmj.com) for more articles like this and to become a Fellow