

Incidental detection of prostate-specific antigen-negative metastatic prostate cancer initially presented with solitary pulmonary nodule on fluorodeoxyglucose positron emission tomography/computed tomography

Ezgi Basak Erdogan, Nur Buyukpinarbasili¹, Sedat Ziyade², Tolga Akman³, Hacı Mehmet Turk⁴, Mehmet Aydin

Departments of Nuclear Medicine, ¹Pathology, ²Thoracic Surgery and ³Urology and ⁴Division of Medical Oncology, Faculty of Medicine, Bezmialem Vakif University, Turkey

ABSTRACT

A 71-year-old male patient with solitary pulmonary nodule underwent fluorodeoxyglucose positron emission tomography/computed tomography (FDG PET/CT) showing slightly increased FDG uptake in this nodule. In addition, PET/CT detected hypermetabolic sclerotic bone lesions in the right second rib and 7th thoracic vertebrae, which were interpreted as possible metastases, and mildly increased FDG uptake in the prostate gland highly suspicious of malignancy. The patient's prostate-specific antigen (PSA) level was within normal range (3.8 ng/dL). The histopathological examination of the lung nodule and right second rib lesion proved metastases from prostate cancer, then the prostate biopsy-confirmed prostate adenocarcinoma. The unique feature of this case is to emphasize the importance of performing PET/CT for solitary pulmonary nodule in detecting PSA-negative metastatic prostate cancer. This case indicated that it should be kept in mind that, even if the PSA is negative, a lung metastasis of prostate cancer may be an underlying cause in patients evaluated for solitary pulmonary nodule by FDG PET/CT.

Keywords: Fluorodeoxyglucose positron emission tomography/computed tomography, prostate cancer, solitary pulmonary nodule

INTRODUCTION

Solitary pulmonary nodule is focus of increased density, smaller than 3 cm, round or oval shaped, surrounded by lung parenchyma on chest radiograph or computed tomography (CT). Solitary pulmonary nodule is a challenging clinical problem, and generally detected as incidental. Because of its high malignancy rate (about 40–60%), further evaluation is important to distinguish benign nodules from malignant.^[1] Malignant pulmonary nodules may represent an early-stage lung cancer or a metastatic tumor focus. Fluorodeoxyglucose positron

emission tomography/computed tomography (FDG PET/CT) is commonly used for the differentiation of malignant nodules from benign nodules that were initially detected by radiography or CT. Furthermore, possible other extrapulmonary primary tumors and its metastases can be identified on whole-body PET/CT. Because of low affinity of prostate cancer to FDG, contrary to more specific PET agents such as ¹⁸F- or ¹¹C-coline, the use of FDG PET/CT is limited for prostate cancer. However, some prostate cancers can be detected incidentally on FDG PET/CT studies applied for other oncological indications. FDG uptake in the prostate gland can be seen in some conditions including prostatitis, benign prostatic hyperplasia, and malignancy. In our patient who underwent FDG PET/CT for metabolic characterization of solitary pulmonary nodule, hypermetabolic lesions were detected in lung, skeleton and prostate. These findings suggested to us metastatic prostate cancer. The lung nodule and the rib lesion were verified histopathologically as metastasis from prostate cancer in this prostate-specific antigen (PSA)-negative patient.

Access this article online

Quick Response Code:



Website:
www.ijnm.in

DOI:
10.4103/0972-3919.151655

Address for correspondence:

Dr. Ezgi Basak Erdogan, Department of Nuclear Medicine, Faculty of Medicine, Bezmialem Vakif University, Adnan Menderes Bulvari, Vatan Caddesi, 34093 Fatih, Istanbul, Turkey. E-mail: erdogan_ezgi@yahoo.com.tr

CASE REPORT

Fluorodeoxyglucose PET/CT was performed for metabolic characterization on a 71-year-old male patient who had been detected to have lung nodule in the upper lobe of his right lung in thoracic CT that he underwent because of chest pain. The patient fasted for at least 4 h before the injection of FDG. In order to provide a better assessment of the gastrointestinal tract, oral iodinated contrast was used. His plasma glucose level was 130 mg/dL. PET/CT scan was obtained after intravenous injection of 370 MBq (10 mCi) ^{18}F -FDG, and standard whole-body scan was obtained (vertex to the upper thigh) on a Biograph 16 PET/CT scanner (Siemens Medical Solutions, Knoxville, TN, USA). A well-circumscribed nodule with 0.8 cm in diameter in the anterior segment of the upper lobe of the right lung, showing a slightly increased FDG uptake standardized uptake value (SUVmax 2.1) was seen [Figure 1]. PET/CT also showed hypermetabolic sclerotic lesion with a moderately increased FDG uptake (SUVmax 5.0) at the lateral portion of the right second rib, and another hypermetabolic sclerotic lesion at the left side of the vertebral body of T7 with a mildly increased FDG uptake (SUVmax 3.8), and a focus of minimally increased FDG uptake at the right 4th rib without any accompanying CT lesion [Figure 2]. Besides, two incidental foci of mildly increased FDG uptake in the anterior and left posterolateral of the prostate gland (SUVmax 3.9 and 3.5, respectively) were observed [Figure 2]. In addition, minimally increased FDG uptake (SUVmax 2.4) in the right anterolateral side was noticed. PSA value immediately after PET/CT scan was measured as 3.83 ng/ml (normal range: 0–4 ng/dL). In differential diagnosis, metastatic prostate cancer with low PSA level or nonspecific hypermetabolic lesions were considered. In a multidisciplinary discussion, firstly, the pulmonary nodule was decided to be evaluated histopathologically. A wedge resection of the nodule in the right lung was applied, and a mass lesion arising from the right 2nd rib was resected. Adenocarcinoma infiltration was detected in both tissues.

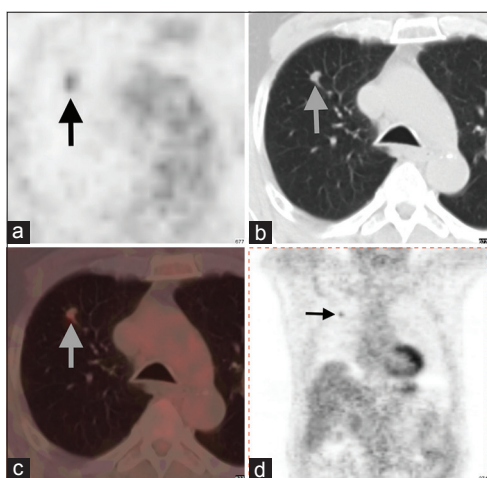


Figure 1: A slightly hypermetabolic nodule in the right lung (arrows) on positron emission tomography/computed tomography (PET/CT) with axial PET (a), CT (b) and fusion (c), and coronal PET (d) slices

In the immunohistochemical examination, prostate cancer markers such as prostate-specific acid phosphates, PSA and the polyclonal carcinoembryonic antigen staining were positive and the other organ markers such as thyroid transcription factor-1, cytokeratin 7 and 20 were negative in the both foci of cancer. Therefore, these lesions were established as metastases of prostate adenocarcinoma. At the investigation of the patient, urological complaints such as nocturia and frequent urination were defined. Upon this, transrectal ultrasonography (TRUS)-guided prostate biopsy was performed in 12 quadrants, and prostate adenocarcinoma has been detected in 6 quadrants of them. Gleason score was 7 (3 + 4). Adenocarcinoma was detected in the 4th and 12th quadrants in which more intense FDG uptake were seen on PET/CT, while atrophy and hyperplasia were shown in the 10th quadrant in which there was minimally increased FDG uptake. Then, multiple osteoblastic lesions consistent with metastases were detected by bone scan with $^{99\text{m}}\text{Tc}$ -methylene diphosphonate [Figure 3].

DISCUSSION

Prostate cancer is the most common type of cancer in men.^[2] In the routine examination of prostate cancer, generally TRUS, CT and magnetic resonance imaging are used. Although FDG PET/CT is widely applied in oncology, its success is limited in prostate cancer because of variable FDG uptake and tumor differentiation.^[3]

Incidental FDG uptake in prostate gland is rarely seen with a rate of 1.2–1.5% among all routine PET/CT scans for various indications; and approximately 5–12% of these increased FDG uptake is reported to be associated with cancer.^[4,5] In the literature, the mean SUVmax value in the incidental prostate cancer was 5.7 ± 5.1 , which is similar to the value in our case (3.9). Among the patients who had increased FDG uptake in the prostate gland, the average PSA values in benign and malignant groups were found as 3.2 and 49.7 ng/ml, respectively.^[6] This finding was not compatible with our case whose PSA was in a normal range. Serum PSA level increases with the increment of the production of PSA in the malignant prostate epithelial cells, or with any damage to disrupt the structure of these cells. In addition, PSA levels may be low in some cases of prostate cancer.^[6] For this reason, serum PSA levels are not always reliable in the differentiation of malignancy from benign lesions of the prostate gland.

It has been reported that the probability of prostate cancer is more likely in patients who had focal FDG uptake localized peripherally than that of centrally on PET/CT images.^[7] In our case, all the hypermetabolic foci were located peripherally in the prostate gland.

There are some studies indicating that poorly differentiated prostate cancer had higher FDG uptake than low-grade prostate

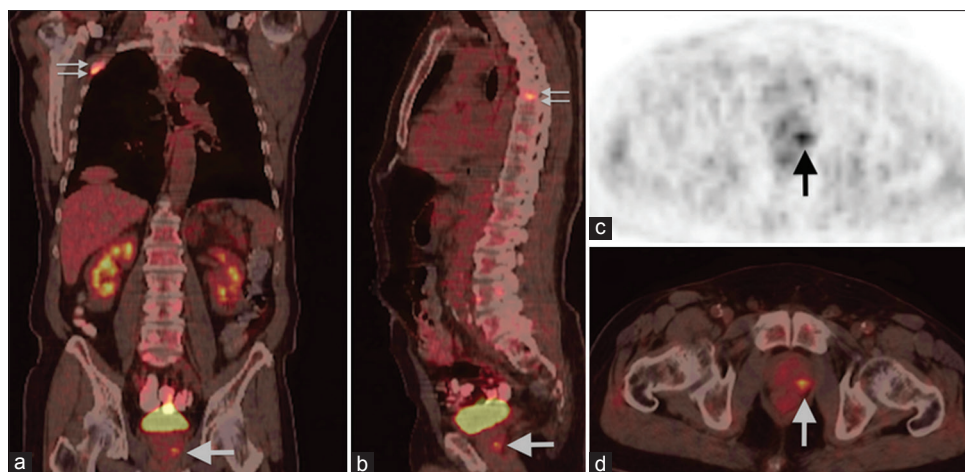


Figure 2: Coronal and sagittal fusion (a and b), and axial positron emission tomography (PET) and fusion (c and d) slices of PET/computed tomography demonstrating hypermetabolic focus in the left peripheral zone of the prostate gland (arrows), and increased fluorodeoxyglucose uptake in the right 2nd rib and 7th thoracic vertebrae

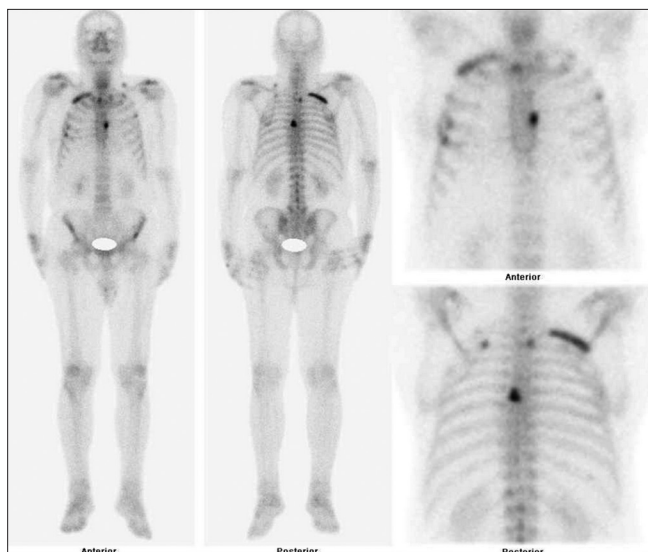


Figure 3: Whole-body bone scan with ^{99m}Tc-methylene diphosphonate showing increased uptake in the right 2nd rib, left 2nd and 3rd ribs, left scapula, T7th vertebrae and left iliac wing (slightly) consistent with metastatic foci

cancer, and FDG uptake correlated directly with Gleason score.^[8,9] However, Gleason score and PSA levels have also been reported to be higher in poorly differentiated prostate cancer.^[10,11] In our case, PSA value was in normal range, and FDG uptake was moderately high, while Gleason score was not as high as that of poorly differentiated tumors, which were usually expected to be over 7.^[9]

A relationship between FDG uptake and androgen receptor was reported. It has been shown that androgen hormone induced expression of glucose transporter-1 and hexokinase in androgen receptor-positive prostate cancer cells.^[12,13] According to this, androgen-positive cells may have higher FDG uptake and FDG uptake in these cells may be less after surgical castration or anti-androgen treatment.^[14] In our case, the androgen receptor was negative, but FDG uptake was positive.

In summary, we reported a patient who underwent FDG PET/CT to evaluate solitary pulmonary nodule. PET/CT demonstrated slightly increased FDG uptake in the lung nodule, and also hypermetabolic sclerotic bone lesions and hypermetabolic foci in the prostate gland suggesting a metastatic prostate cancer, which was then proven histopathologically in our PSA-negative patient. Therefore, it should be kept in mind that metastatic prostate cancer may initially present with solitary pulmonary nodule. Also, this case emphasizes the necessity of careful examination of FDG uptake in the prostate gland to exclude malignancy, even if PSA is within normal ranges.

REFERENCES

1. Erasmus JJ, Connolly JE, McAdams HP, Roggli VL. Solitary pulmonary nodules: Part I. Morphologic evaluation for differentiation of benign and malignant lesions. *Radiographics* 2000;20:43-58.
2. Center MM, Jemal A, Lortet-Tieulent J, Ward E, Ferlay J, Brawley O, et al. International variation in prostate cancer incidence and mortality rates. *Eur Urol* 2012;61:1079-92.
3. Stewart GD, Gray K, Pennington CJ, Edwards DR, Riddick AC, Ross JA, et al. Analysis of hypoxia-associated gene expression in prostate cancer: Lysyl oxidase and glucose transporter-1 expression correlate with Gleason score. *Oncol Rep* 2008;20:1561-7.
4. Hwang I, Chong A, Jung SI, Hwang EC, Kim SO, Kang TW, et al. Is further evaluation needed for incidental focal uptake in the prostate in 18-fluoro-2-deoxyglucose positron emission tomography-computed tomography images? *Ann Nucl Med* 2013;27:140-5.
5. Han EJ, H O J, Choi WH, Yoo IR, Chung SK. Significance of incidental focal uptake in prostate on 18-fluoro-2-deoxyglucose positron emission tomography CT images. *Br J Radiol* 2010;83:915-20.
6. Constantinou J, Feneley MR. PSA testing: An evolving relationship with prostate cancer screening. *Prostate Cancer Prostatic Dis* 2006;9:6-13.
7. Minamimoto R, Uemura H, Sano F, Terao H, Nagashima Y, Yamanaka S, et al. The potential of FDG-PET/CT for detecting prostate cancer in patients with an elevated serum PSA level. *Ann Nucl Med* 2011;25:21-7.
8. Melchior SW, Fichtner J, Jones J, Gillitzer R, Hohenfellner M, Kreitner F, et al. Changes in flurodeoxyglucose (FDG) uptake measured by positron emission tomography (PET) in prostate cancer (CaP) patients following androgen withdrawal. *J Urol* 1999;161:297.
9. Oyama N, Akino H, Suzuki Y, Kanamaru H, Sadato N, Yonekura Y, et al. The increased accumulation of [18F] fluorodeoxyglucose in untreated prostate cancer. *Jpn J Clin Oncol* 1999;29:623-9.

10. Gao HW, Li YL, Wu S, Wang YS, Zhang HF, Pan YZ, *et al.* Mass screening of prostate cancer in a Chinese population: The relationship between pathological features of prostate cancer and serum prostate specific antigen. *Asian J Androl* 2005;7:159-63.
11. Stenman UH, Abrahamsson PA, Aus G, Lilja H, Bangma C, Hamdy FC, *et al.* Prognostic value of serum markers for prostate cancer. *Scand J Urol Nephrol Suppl* 2005;216:64-81.
12. Clavo AC, Brown RS, Wahl RL. Fluorodeoxyglucose uptake in human cancer cell lines is increased by hypoxia. *J Nucl Med* 1995;36:1625-32.
13. Moon JS, Jin WJ, Kwak JH, Kim HJ, Yun MJ, Kim JW, *et al.* Androgen stimulates glycolysis for de novo lipid synthesis by increasing the activities of hexokinase 2 and 6-phosphofructo-2-kinase/fructose-2,6-bisphosphatase 2 in prostate cancer cells. *Biochem J* 2011;433:225-33.
14. Kukuk D, Reischl G, Raguin O, Wiehr S, Judenhofer MS, Calaminus C, *et al.* Assessment of PET tracer uptake in hormone-independent and hormone-dependent xenograft prostate cancer mouse models. *J Nucl Med* 2011;52:1654-63.

How to cite this article: Erdogan EB, Buyukpinarbasili N, Ziyade S, Akman T, Turk HM, Aydin M. Incidental detection of prostate-specific antigen-negative metastatic prostate cancer initially presented with solitary pulmonary nodule on fluorodeoxyglucose positron emission tomography/computed tomography. *Indian J Nucl Med* 2015;30:268-71.

Source of Support: Nil. **Conflict of Interest:** None declared.