

Received: 2019.01.01

Accepted: 2019.02.28

Published: 2019.06.19

Comparison Between Submucosal Tunneling Endoscopic Resection (STER) and Other Resection Modules for Esophageal Muscularis Propria Tumors: A Retrospective Study

Authors' Contribution:

Study Design A

Data Collection B

Statistical Analysis C

Data Interpretation D

Manuscript Preparation E

Literature Search F

Funds Collection G

ABCDEF **Mingyue Zhang***

ABCDEF **Shuang Wu***

AEFG **Hong Xu**

Department of Gastroenterology, The First Hospital of Jilin University, Changchun, Jilin, P.R. China

Corresponding Author:

Source of support:

* Mingyue Zhang and Shuang Wu are co-first authors for this paper

Hong Xu, e-mail: chxuhong@163.com

Departmental sources

Background:

Surgery has been considered to be the primary approach for resection of esophageal muscularis propria tumors. With the development of endoscopic technology, new techniques such as endoscopic submucosal dissection (ESD) and submucosal tunneling endoscopic resection (STER) have emerged for resecting these lesions. Previous studies have demonstrated that STER might be an intriguing alternative. This study aimed to evaluate the clinical value of STER by comparing it to other resecting modules.

Material/Methods:

Clinical outcome and data were retrospectively collected from patients with esophageal muscularis propria tumors who underwent resection either endoscopically or thoracoscopically. The clinical data were statistically analyzed.

Results:

A total of 137 patients were enrolled. They were divided into 3 groups: a STER group (27 patients), an ESD group (42 patients), and a thoracoscopic enucleation (TE) group (68 patients). There were no significant differences among the 3 groups in gender, age, pathological type of tumors, or major adverse events ($P > 0.05$). However, the STER group had the shortest duration of hospitalization and the lowest cost ($P < 0.05$). Furthermore, the STER group was superior in operation time and the location of tumors to the TE group. Moreover, STER outperformed ESD in the resection of large tumors ($P < 0.05$). Although STER had the lowest en bloc resection rate, no recurrence or metastasis was noted during a mean follow-up of 22.14 months (range 3 to 60 months).

Conclusions:


STER is a feasible, safe, and effective approach for the resection of esophageal muscularis propria tumors ≤ 40 mm. We recommend STER as a potent alternative for these tumors.

MeSH Keywords:

Endoscopy • Gastrointestinal Neoplasms • Thoracoscopy

Full-text PDF:

<https://www.medscimonit.com/abstract/index/idArt/914908>

 3109

 5

 1

 36



Background

Recently, more and more esophageal muscularis propria (MP) tumors are detected owing to the widespread use of gastrointestinal (GI) endoscopy and endoscopic ultrasonography (EUS) [1]. Although most of the lesions are benign [2], some patients may be concerned about them or subject to relevant symptoms. The most common symptom is dysphagia, followed by chest tightness and pain [3]. In addition, some tumors of this sort, especially the large ones and mesenchymal neoplasms (including gastrointestinal stromal tumors, GIST), do have malignant potential [1,4]. Therefore, the treatment of esophageal muscularis propria tumors is beneficial.

In the past, surgery, including thoracoscopic enucleation (TE), was primarily applied to remove esophageal submucosal tumors (SMTs) originating from the MP layer [5]. Novel endoscopic therapeutic approaches such as endoscopic submucosal dissection (ESD) shed light on the treatment of esophageal MP tumors [6]. ESD is an interventional procedure for the removal of gastrointestinal lesions that uses a high-frequency electric knife and other equipment to dissect or resect lesions and the surrounding mucosal tissue to achieve complete resection. ESD is noted for its minimal invasiveness, but this technique still has some risks of complications, such as perforation and massive bleeding [7,8]. Although most of the perforations and bleeding are endoscopically manageable, secondary infection and gastrointestinal fistula can occur [9].

With constant advances in endoscopic technique, a new technique, called submucosal tunneling endoscopic resection (STER), has gained popularity for use in resecting upper GI SMTs, especially tumors originating from the MP layer. It maintains the integrity of the normal mucosa and submucosa that cover the SMT and fully exposes and easily dissects the SMT by creating a submucosal tunnel between the submucosal and MP layers. This module was originally described by Sumiyama et al. [10] and later modified by Inoue et al. as an endoscopic therapy for achalasia, and was called peroral endoscopic myotomy (POEM) [11]. Then, Chinese scholars invented the STER technique on the basis of POEM and employed it to excise esophageal mucosal tumors for the first time, at Shanghai Zhongshan Hospital in September 2010 [12]. Recently, a growing number of studies have assessed the value of STER, and this technique has been widely applied for endoscopic resection of esophageal SMTs from the MP layer [13,14]. However, its safety and efficacy need to be further assessed. Therefore, in this study, we retrospectively evaluated the application of STER by comparing it with other resecting modules such as ESD and TE.

Material and Methods

Patients

This was a single-center, retrospective study conducted in China. We retrieved the data of all patients with esophageal SMT originating from the MP layer who underwent either endoscopic or thoracoscopic resection at the First Hospital of Jilin University from November 1, 2011 to July 31, 2018. We collected demographic data, as well as information on the size, location, and histopathology of tumors, en bloc and complete resection rate, recurrence, duration of surgery, days of hospitalization, total cost, and major adverse events.

Operation procedure

STER and ESD were performed as standard operating procedure [15–17]. Patients were put under general anesthesia. Carbon dioxide (CO²) insufflators were used during the procedures. Other equipment and accessories included a hybrid knife, a dual knife, an insulation-tip (IT) knife, an injection needle, and hemostatic clips. The main procedure of STER was as follows: (a) submucosal injection; (b) a longitudinal mucosal incision over 2 cm was made, and then a submucosal tunnel was created; (c) the tumor was dissected; and (d) several clips were used to close the mucosal entry (Figure 1). Briefly, the key steps of ESD were: (a) marking dots; (b) submucosal injection; (c) submucosal dissection; and (d) closure of defects when necessary. During the both procedures, endoscopic hemostasis was performed with argon plasma coagulation (APC), an IT knife, and hot biopsy forceps or hemoclips if bleeding occurred, and metal clips were used to occlude perforations if the occurred.

In the TE procedure, patients were put under general anesthesia, and lesions were removed thoracoscopically as standard operating procedure.

Postoperative management

All patients were given prophylactic antibiotics on the day of the operation and fasted for 3 days. Proton pump inhibitors (PPIs) and intravenous nutrition were given during the period, followed by a liquid diet for 3 days and a normal diet was gradually resumed. The treatment duration above could be prolonged according to the status of the patients. For patients in the TE group, chest X-rays were taken to check for complications such as pneumothorax.

Pathological evaluation

After excision, the specimens were fixed in 10% buffered formalin. Then, they were embedded with paraffin and sectioned

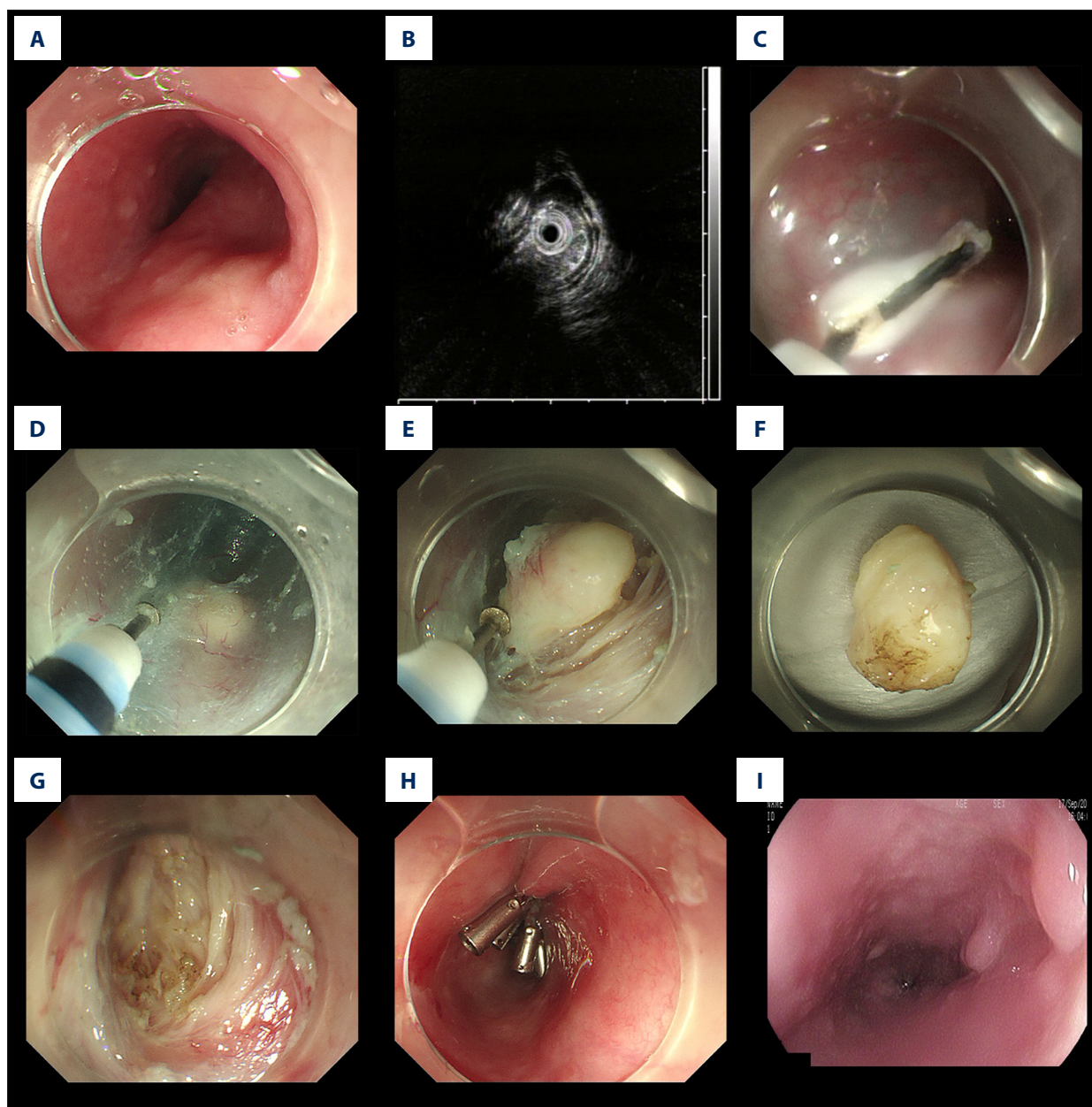


Figure 1. Case illustration of submucosal tunneling endoscopic resection. (A) Endoscopic view of a submucosal tumor located in the middle esophagus. (B) Endoscopic ultrasound view of the lesion, showing the tumor originating from the muscularis propria. (C) Submucosal injection at 5 cm to the tumor and making a mucosal incision over 2 cm. (D) Creating a submucosal tunnel to the lesion. (E) Exposure of the entire tumor. (F) Complete dissection of the tumor. (G) The surface after resection was clean without bleeding. (H) Closure of the tunnel entry with clips. (I) Endoscopic view at 3-month follow-up after operation, showing a scar at the mucosal entry.

for pathologic examination. Immunohistochemical staining was performed when the pathological type of the tumor was difficult to determine. An en bloc resection was defined as complete removal of the tumor into a single non-fragmented piece. Complete resection (R0 resection) was defined as complete tumor removal with negative margins established [18].

Follow-up

All patients were followed up by endoscopy at 3, 6, and 12 months during the first year after the initial procedure and then once a year thereafter in order to assess the healing of the incision and to check for residual and recurrent tumors. Tumor recurrence, defined as a tumor with the same pathological

Table 1. Characteristics of 137 patients and esophageal muscularis propria tumors.

| Characteristic | STER | ESD | TE | p-Value |
|----------------------------------|---------------------|--------------------|--------------------|---------|
| Age, y, mean ±SD, (range) | 49.93±10.40 (29–63) | 51.87±9.13 (31–68) | 52.26±9.76 (25–77) | 0.566 |
| Sex, n | | | | 0.338 |
| Male | 18 | 23 | 34 | |
| Female | 9 | 19 | 34 | |
| Tumor size,mm, mean ±SD, (range) | 16.67±7.07 (8–40) | 7.38±4.55 (2–20) | 21.26±12.64 (2–20) | 0.000 |
| Tumor Location, n (%) | | | | 0.022 |
| Upper esophagus | 1 (3.70) | 4 (9.52) | 0 (0) | |
| Middle esophagus | 15 (55.56) | 26 (61.91) | 54 (79.41) | |
| Lower esophagus | 11 (40.74) | 12 (28.57) | 14 (20.59) | |
| Histopathology, n (%) | | | | 0.773 |
| Leiomyoma | 25 (92.60) | 39 (92.86) | 63 (92.65) | |
| GIST | 1 (3.70) | 2 (4.76) | 1 (1.47) | |
| Schwannoma | 1 (3.70) | 1 (2.38) | 4 (5.88) | |
| Total, n | 27 | 42 | 68 | / |

SD – standard deviation; GIST – gastrointestinal stromal tumors; STER – submucosal tunneling endoscopic resection; ESD – endoscopic submucosal dissection; TE – thoracoscopic enucleation.

type, was found at the operation location or 1 cm surrounding the location over 6 months after surgery.

Statistical analysis

All analyses were performed with SPSS 20.0 software (SPSS Inc., Chicago, IL, USA). Continuous data are expressed as mean ± standard deviation (SD) with ranges, and categorical data are represented as rate or composition ratio. Continuous data were assessed by the *t* test or analysis of variance (ANOVA) and categorical data were assessed by Pearson's chi-square test, continuity correction chi-square test, or Fisher's exact test, as appropriate. *P*<0.05 was considered statistically significant.

Results

Clinicopathologic characteristics

In this comparison study, a total of 137 patients with SMTs in the esophagus MP layer were enrolled and divided into 3 groups: a STER group, an ESD group, and a TE group. Patient clinicopathologic characteristics are described in Table 1. Mean age of the patients was 51.35 years (range 25 to 77 years) and the male/female ratio was 75/62. There were no significant differences among the 3 groups in age or gender (*p*>0.05). The mean diameter was 16.67 mm (range 8–40 mm) in the STER group, 7.38 mm (range 2–20 mm) in the ESD group,

and 21.26 mm (range 5–80 mm) in the TE group. There was 1 tumor localized in the upper esophagus, 15 in the middle esophagus, and 11 in the lower esophagus in the STER group; in the ESD group, there were 4 in the upper esophagus, 26 in the middle esophagus, and 12 in the lower esophagus; and in the TE group there were 0, 54, and 14, respectively. The differences among the 3 groups in tumor size and tumor location were significant (*p*<0.05). There was no significant difference among the 3 groups in histopathology types of tumors (*p*>0.05).

Therapeutic outcomes

In this study, en bloc resection was achieved in 81.48% (22 of 27) of patients in the STER group, 95.24% (40 of 42) of the patients in the ESD group, and in 100% of patients in the TE group; the rate of en bloc resection of STER was significantly lower than that of ESD and TE (*p*<0.05). All tumors achieved complete resection and there were no recurrences in the 3 groups.

The operating duration of STER (median 84.05 minutes, range 32 to 174 minutes) was significantly shorter than TE (median 140.16 minutes, range 28 to 390 minutes), while longer than ESD (median 57.59 minutes, range 24 to 226 minutes) (*p*<0.05). STER was associated with the shortest duration of hospitalization (median 9.05 days, range 4 to 19 days) and the least cost (median 3726.59 yuan, range 2198.67 to 5259.52 yuan) compared with ESD and TE (*p*<0.05) (Table 2).

Table 2. Outcomes after resection of esophageal muscularis propria tumors in patients.

| Outcome | STER | ESD | TE | p-Value |
|---|---|---|---|---------|
| ER, n/N, (%) | 22/27 (81.48) | 40/42 (95.24) | 68/68 (100.00) | 0.001 |
| Complete resection, n/N, (%) | 27/27 (100.00) | 42/42 (100.00) | 68/68 (100.00) | / |
| Recurrence, n/N, (%) | 0 (0.00) | 0 (0.00) | 0 (0.00) | / |
| Operating duration, min, mean \pm SD, (range) | 84.05 \pm 45.50 (32–174) | 57.59 \pm 47.87 (24–226) | 140.16 \pm 66.23 (28–390) | 0.000 |
| Major adverse events, n/N, (%) | 1/27 (3.70) | 3/42 (7.14) | 6/68 (8.82) | 0.687 |
| Hospitalization duration, d, mean \pm SD, (range) | 9.05 \pm 2.95 | 10.74 \pm 3.39 | 14.79 \pm 7.12 | 0.000 |
| Cost, USD, mean \pm SD, (range) | 3726.59 \pm 724.37 (2198.67–5259.52) | 4993.30 \pm 910.37 (3663.50–6765.53) | 8725.89 \pm 3427.98 (4175.16–26733.02) | 0.000 |
| Total, n | 27 | 42 | 68 | / |

ER – en bloc resection; SD – standard deviation; STER – submucosal tunneling endoscopic resection; ESD – endoscopic submucosal dissection; TE – thoracoscopic enucleation.

Risk factors for en bloc resection and long duration of surgery

Based on statistical analysis of the en bloc resection rate, we found that the tumor size, location, and resection module were the significant factors (Table 3). Other factors, such as age, sex, treatment time, and histopathology, were not significant.

We found that resection module was the only risk factors for long duration of surgery. Other factors (e.g., age, sex, treatment time, tumor size, tumor location, and histopathology) were not associated with the duration of surgery (Table 4).

Complications and follow-up results

There was no significant difference among the 3 groups in the occurrence of major adverse events ($p > 0.05$). Fewer cases in the STER group developed fever than in the other 2 group (Table 5). There was 1 case of dyspnea in the TE group. No perforation, delayed bleeding, or other severe complications occurred during or after procedures. No complication needed surgical intervention. With a mean follow-up period of 22.14 months (range 3 to 60 months), all of the patients were free from local recurrence and metastasis during the study period.

Discussion

Management of SMTs originating from the MP layers remains a controversial topic [19]. In the past, open or thoracoscopic surgery was performed to remove SMTs, even without accurate orientation. However, surgery always results in severe surgical trauma, delayed recovery, and serious postoperative

complications such as anastomotic hemorrhage and thoracic abscess, which adversely affect the patient's quality of life post-operatively. With the development of endoscopy technology, more and more endoscopic modules have been used in clinical practice because of their advantages, such as minor trauma, low cost, short duration of surgery, and shorter hospitalization [20]. STER has been successfully applied to patients with esophageal SMTs from MP layers [21]. By creating a tunnel between the submucosal and MP layers, STER preserves mucosal integrity and prevents leakage of gas and liquid, reducing the rates of perforation and infection [5].

Based on the data in our study, STER showed a higher completion rate, shorter hospitalization duration, lower cost, and lower complication rate, confirming that STER has advantages over ESD and TE. STER has been recommended as a standard resection module in a Chinese consensus report [22] and it has been accepted and applied by a growing number of Chinese surgeons. Our study further demonstrates the safety and efficacy of this module and may increase awareness and use in areas where STER is relatively underused, such as in Western countries and Japan. Despite these advantages, some unfavorable and secondary findings in our study need to be further discussed.

In our study, the maximal diameter of SMTs in the STER group was 40 mm, while the TE group had significantly larger tumors (average diameter of 21.26 mm, range 5–80 mm). It seemed that STER was less effective for large tumors compared to TE. However, the application of STER for tumors >40 mm has been previously reported in many studies. Kumbhari et al. [23] resected a giant esophageal leiomyoma (60 \times 28 \times 22 mm) by STER. Tan et al. [24] reported a case of a 52-mm esophageal leiomyoma en bloc resected by STER. Wang et al. [25] reported

Table 3. Multivariate analysis on risk factors of en bloc resection in esophageal muscularis propria tumors.

| Characteristics | ER (%) | PR (%) | En bloc resection (n=130) | | |
|-------------------------|------------|----------|---------------------------|--------------|---------|
| | | | OR | 95%CI | P-value |
| Age, y | | | 1.877 | 0.403–8.728 | 0.422 |
| ≤55 (n=79) | 76 (96.2) | 3 (3.8) | | | |
| >55 (n=58) | 54 (93.1) | 4 (6.9) | | | |
| Sex | | | 0.467 | 0.087–2.493 | 0.373 |
| Male (n=75) | 70 (93.3) | 5 (6.7) | | | |
| Female (n=62) | 60 (96.8) | 2 (3.2) | | | |
| Treatment time, y | | | 1.776 | 0.332–9.498 | 0.502 |
| 2012–2015 (n=56) | 54 (96.4) | 2 (3.6) | | | |
| 2016–2018 (n=81) | 76 (93.8) | 5 (6.2) | | | |
| Tumor size, mm | | | 5.344 | 1.094–26.094 | 0.038 |
| ≤30 (n=118) | 114 (96.6) | 4 (3.4) | | | |
| >30 (n=20) | 17 (85.0) | 3 (15.0) | | | |
| Tumor Location, n (%) | | | 0.160 | 0.028–0.916 | 0.040 |
| Upper esophagus (n=5) | 4 (80.0) | 1 (20.0) | | | |
| Middle esophagus (n=95) | 89 (93.7) | 6 (6.3) | | | |
| Lower esophagus (n=37) | 37 (100) | 0 (0) | | | |
| Histopathology, n (%) | | | 1.835 | 0.559–6.020 | 0.317 |
| Leiomyoma (n=127) | 121 (95.3) | 6 (4.7) | | | |
| GIST (n=4) | 4 (100) | 0 (0) | | | |
| Schwannoma (n=6) | 5 (83.3) | 1 (16.7) | | | |
| Resection module | | | 7.263 | 1.774–29.736 | 0.006 |
| TE (n=68) | 68 (100) | 0 (0) | | | |
| ESD (n=42) | 40 (95.2) | 2 (4.8) | | | |
| STER (n=27) | 22 (81.5) | 5 (18.5) | | | |

ER – en bloc resection; PR – piecemeal resection; OR – odds ratio; CI – confidence interval; GIST – gastrointestinal stromal tumors; TE – thorascopic enucleation; ESD – endoscopic submucosal dissection; STER – submucosal tunneling endoscopic resection.

a maximum diameter of 45 mm in their retrospective study. Therefore, the fact that STER has comparative capability of resecting SMTs to TE has been confirmed. The seemingly lower effectiveness of STER in our study may be due to the limited number of cases.

STER was employed for tumors with an average diameter of 16.67 mm (ranged 8–40 mm), which was larger than that in the ESD group (average diameter of 7.38 mm, range 2–20 mm), indicating that STER is a more effective endoscopic module in the resection of large SMTs than ESD. Our search of PubMed and Web of Science yielded no relevant articles on comparing resection capability between STER and ESD. We attribute the

advantage of STER to its protective tunnel, which ensures the safety and improves the resection capability.

In our study, we found that the middle segment of the esophagus was where most esophageal SMTs developed. As a result, most of resections target this segment, as shown in Table 1. Sufang Tu et al. [26] has also revealed that esophageal SMTs of MP layer are most commonly detected in the middle segment of the esophagus. However, Ling-Jia Sun et al. [27] found that even more esophageal leiomyomas were located in the lower esophagus. However, this study had more inclusion criteria, and some of the leiomyomas arose from muscularis mucosae. We believe that this explains the disagreement of their results with our study.

Table 4. Multivariate analysis on risk factors of long operating duration in esophageal muscularis propria tumors.

| Characteristics | Long (≥90 min [%]) | Short (<90 min [%]) | Long Operating Duration (n=66) | | |
|-------------------------|-----------------------|------------------------|--------------------------------|-------------|---------|
| | | | OR | 95%CI | P-value |
| Age, y | | | 0.708 | 0.322–1.557 | 0.390 |
| ≤55 (n=79) | 40 (50.6) | 39 (49.4) | | | |
| >55 (n=58) | 26 (44.8) | 32 (55.2) | | | |
| Sex | | | 1.511 | 0.694–3.287 | 0.298 |
| Male (n=75) | 32 (42.7) | 43 (57.3) | | | |
| Female (n=62) | 34 (54.8) | 28 (45.2) | | | |
| Treatment time, y | | | 0.783 | 0.348–1.762 | 0.555 |
| 2012–2015 (n=56) | 33 (58.9) | 23 (41.1) | | | |
| 2016–2018 (n=81) | 33 (40.7) | 48 (59.3) | | | |
| Tumor size, mm | | | 1.759 | 0.582–5.318 | 0.317 |
| ≤30 (n=118) | 56 (47.5) | 62 (52.5) | | | |
| >30 (n=20) | 10 (50.0) | 10 (50.0) | | | |
| Tumor Location, n (%) | | | 1.900 | 0.833–4.334 | 0.127 |
| Upper esophagus (n=5) | 1 (20.0) | 4 (80.0) | | | |
| Middle esophagus (n=95) | 47 (49.5) | 48 (50.5) | | | |
| Lower esophagus (n=37) | 18 (48.6) | 19 (51.4) | | | |
| Histopathology, n (%) | | | 0.610 | 0.236–1.577 | 0.308 |
| Leiomyoma (n=127) | 63 (49.6) | 64 (50.4) | | | |
| GIST (n=4) | 1 (25.0) | 3 (75.0) | | | |
| Schwannoma (n=6) | 2 (33.3) | 4 (66.7) | | | |
| Resection module | | | 0.262 | 0.147–0.469 | 0.000 |
| TE (n=68) | 53 (77.9) | 15 (22.1) | | | |
| ESD (n=42) | 3 (7.1) | 39 (92.9) | | | |
| STER (n=27) | 10 (37.0) | 17 (63.0) | | | |

OR – odds ratio; CI – confidence interval; GIST – gastrointestinal stromal tumors; TE – thoroscopic enucleation; ESD – endoscopic submucosal dissection; STER – submucosal tunneling endoscopic resection.

Table 5. complication rate after resection of esophageal muscularis propria tumors in patients.

| Complication | STER | ESD | TE | p-Value |
|------------------------|------------|-----------|-----------|---------|
| Moderate fever, n, (%) | 1 (100.00) | 2 (66.67) | 3 (50.00) | |
| High fever, n, (%) | 0 (0.00) | 1 (33.33) | 2 (33.33) | |
| Dyspnea, n, (%) | 0 (0.00) | 0 (0.00) | 1 (16.67) | |
| Total, n | 1 | 3 | 6 | 0.846 |

STER – submucosal tunneling endoscopic resection; ESD – endoscopic submucosal dissection; TE – thoroscopic enucleation.

En bloc resection can facilitate optimal pathology. Therefore, the en bloc resection rate was assessed in this study. STER revealed an en bloc resection rate of 81.48% (22/27) for esophageal SMTs arising from MP layers in our study, which was much lower than with ESD (95.24%) and TE (100%). However, this does not confirm the inferiority of STER. A previous review, of more than 20 studies with over 700 patients found that en bloc resection was achieved in >85% of patients, which was higher than in our study [28]. Furthermore, some studies have reported a 100% rate of en bloc resection [21,29]. The reasons for our lower en bloc rate may be as follows. Hasty and premature use of snares before the tumor was totally exposed might result in incomplete resection. Surgeon seniority and experience may play a role. In our study, some novice operators performed STER, leading to a relatively lower en bloc resection rate. SMTs with larger size and irregular shape achieved higher piecemeal resection rate according to a previous study [30]. In our study, tumors with diameters >3.0 cm were more prone to piecemeal resection, which was consistent with previous studies [31]. In addition, location of tumors might be another factor. According to the statistical analysis in our study, we found that tumors located in the upper and middle esophagus were more inclined to piecemeal resection (Table 3). In our opinion, size and location of tumors may be the risk factors for piecemeal resection. Due to the unavailability of all tumors' shape, we failed to work on the correlation between shape of tumors and en bloc resection rate.

According to some earlier studies [4,9,13,30,32], there are several tips that may facilitate an en bloc resection, such as anesthesia methods, appropriate size and shape of the tunnel orifice, appropriate width and length of the tunnel, pre-treatment of the exposed vessel, adequate preoperative evaluation of tumors, and experienced operators. These tips might elevate the rate of en bloc resection and may be adopted by us in our medical practice.

Regarding duration of surgery, TE was longer than both STER and ESD, which was similar to other studies [14, 20]. When comparing STER and ESD, STER took slightly longer. Few studies have compared STER and ESD in terms of duration of surgery. It appears that the size of tumors might make a difference. It was reported that larger size was a risk factor that extends duration of surgery [31]. In our study, size of tumors in the STER group was significantly larger than that in the ESD group, which explained the longer duration of surgery. On the other hand, different resection modules presented with significant different duration of surgery (Table 4). Generating submucosal tunnels could extend the procedure duration, resulting in longer time for STER than ESD. However, generating the tunnel improves safety and decreases complications [33].

Gas-related and inflammation-related complications were the major complications for STER according to previous study,

such as subcutaneous emphysema, pneumothorax, and pleural effusion [19]. While in our study, only 1 patient developed moderate fever and mucosal nonunion. The complication rate of STER was lower than for TE and ESD, in spite of an insignificantly statistical difference. Compared to previous studies, we also found a lower complication rate. The low complication rate in our study may result from factors as follow: (a) The application of carbon dioxide insufflator, which is absorbed rapidly and exhaled through the lungs, for reducing not only the potential risk of subcutaneous emphysema, pneumothorax, or pneumoperitoneum, but also the risk of an air embolism [10]; (b) Appropriate incision site. It was reported that a distance of 5 cm from the resection site to tumors shows the greatest leak resistance achievable, compared with direct linear incision and balloon dilation [34]. In our study, we followed this method. (c) Prophylactic administration of antibiotics before procedures and PPIs after procedures. As reported, PPI and antibiotics may help to prevent postoperative bleeding and *Helicobacter pylori* (Hp) infection [35,36]; (d) Instead of fasting for 1–2 days as in other studies [4,21], our patients fasted for 3 days and gradually returned to normal diet, which effectively reduced the risk of infection; (e) Other factors, including prophylactic and prompt hemostasis, complete closures of the defect, optimized gastrointestinal preparation, and adherence to aseptic principles. The low complication rate indicates that STER, as a novel resection module, is not inferior to other well-established modules such as ESD and TE. It could be a potent alternative. What's more, in our study, we found that STER had the shortest hospitalization duration and the lowest hospital cost when compared with ESD and TE, indicating that STER is more conducive to postoperative recovery and is more economical.

The strength of our study was that we analyzed the advantages of STER by comparing it with other methods. However, there are several limitations in our study. First, this was a retrospective study in a single center with a relatively small sample size, resulting in a potential bias. Therefore, prospective, multicenter, randomized controlled trials (RCT) with large sample sizes are required to validate the results. Second, there is an incomplete collection of detailed information such as the shape of tumors. Finally, the follow-up time in the present study was relatively short, and thus lacks high reliability. Longer follow-up is required for the assessment of long-term outcomes.

According to our study and literature review, a guideline might be suggested, which would refer esophageal SMTs as an indication of STER, especially for ≤40 mm SMTs originating from the MP layer. The standard protocol of STER, as in this study, might also be included in the guidelines. However, there are still some controversies over the application of STER such as the postoperative administration of antibiotics, and application of STER in upper esophageal SMTs. There is need for an official guideline that publicizes and standardizes the adoption of

this advanced endoscopic module in the treatment of esophageal SMTs.

Conclusions

In conclusion, STER is a feasible, safe, and effective alternative to resection of esophageal muscularis propria tumors.

References:

- Nishida T, Kawai N, Yamaguchi S, Nishida Y: Submucosal tumors: Comprehensive guide for the diagnosis and therapy of gastrointestinal submucosal tumors. *Dig Endosc*, 2013; 25(5): 479–89
- Zhou DJ, Dai ZB, Wells MM et al: Submucosal tunneling and endoscopic resection of submucosal tumors at the esophagogastric junction. *World J Gastroenterol*, 2015; 21(2): 578–83
- Luh SP, Hou SM, Fang CC, Chen CY: Video-thoracoscopic enucleation of esophageal leiomyoma. *World J Surg Oncol*, 2012; 10: 52
- Wang H, Tan Y, Zhou Y et al: Submucosal tunneling endoscopic resection for upper gastrointestinal submucosal tumors originating from the muscularis propria layer. *Eur J Gastroenterol Hepatol*, 2015; 27(7): 776–80
- Du C, Chai N, Linghu E et al: Treatment of cardiac submucosal tumors originating from the muscularis propria layer: Submucosal tunneling endoscopic resection versus endoscopic submucosal excavation. *Surg Endosc*, 2018; 15: 1–9
- Goto O, Uraoka T, Horii J, Yahagi N: Expanding indications for ESD: Submucosal disease (SMT/carcinoid tumors). *Gastrointest Endosc Clin N Am*, 2014; 24(2): 169–81
- Chan SM, Yeung B, Chiu PW: DDW 2016 review: Advances in therapeutic upper gastrointestinal endoscopy. *Dig Endosc*, 2017; 29(2): 145–48
- Jain D, Desai A, Mahmood E, Singhal S: Submucosal tunneling endoscopic resection of upper gastrointestinal tract tumors arising from muscularis propria. *Ann Gastroenterol*, 2017; 30(3): 262–72
- Du C, Linghu E: Submucosal tunneling endoscopic resection for the treatment of gastrointestinal submucosal tumors originating from the muscularis propria layer. *J Gastrointest Surg*, 2017; 21(12): 2100–9
- Sumiyama K, Gostout CJ, Rajan E et al: Submucosal endoscopy with mucosal flap safety valve. *Gastrointest Endosc*, 2007; 65(4): 688–94
- Inoue H, Minami H, Kobayashi Y et al: Peroral endoscopic myotomy (POEM) for esophageal achalasia. *Endoscopy*, 2010; 42(4): 265–71
- Xu MD, Yao LQ: [Clinical value of tunnel endoscopy for the treatment of esophagogastric diseases.] *Zhonghua Wei Chang Wai Ke Za Zhi*, 2012; 15(7): 659–61 [in Chinese]
- Tan Y, Lv L, Duan T et al: Comparison between submucosal tunneling endoscopic resection and video-assisted thoracoscopic surgery for large esophageal leiomyoma originating from the muscularis propria layer. *Surg Endosc*, 2016; 30(7): 3121–27
- Chai N, Du C, Gao Y et al: Comparison between submucosal tunneling endoscopic resection and video-assisted thoracoscopic enucleation for esophageal submucosal tumors originating from the muscularis propria layer: A randomized controlled trial. *Surg Endosc*, 2018; 32(7): 3364–72
- Chen H, Xu Z, Huo J, Liu D: Submucosal tunneling endoscopic resection for simultaneous esophageal and cardia submucosal tumors originating from the muscularis propria layer (with video). *Dig Endosc*, 2015; 27(1): 155–58
- Li QL, Chen WF, Zhang C et al: Clinical impact of submucosal tunneling endoscopic resection for the treatment of gastric submucosal tumors originating from the muscularis propria layer (with video). *Surg Endosc*, 2015; 29(12): 3640–46
- Meng FS, Zhang ZH, Shan GD et al: Endoscopic submucosal dissection for the treatment of large gastric submucosal tumors originating from the muscularis propria layer: A single center study. *Z Gastroenterol*, 2015; 53(7): 655–59
- Li Z, Gao Y, Chai N et al: Effect of submucosal tunneling endoscopic resection for submucosal tumors at esophagogastric junction and risk factors for failure of en bloc resection. *Surg Endosc*, 2018; 32(3): 1326–35
- Song S, Wang X, Zhang S et al: Efficacy and complications of submucosal tunneling endoscopic resection for upper gastrointestinal submucosal tumors and exploration for influencing factors. *Z Gastroenterol*, 2018; 56(4): 365–73
- Meng FS, Zhang ZH, Hong YY et al: Comparison of endoscopic submucosal dissection and surgery for the treatment of gastric submucosal tumors originating from the muscularis propria layer: A single-center study (with video). *Surg Endosc*, 2016; 30(11): 5099–107
- Xu MD, Cai MY, Zhou PH et al: Submucosal tunneling endoscopic resection: A new technique for treating upper GI Submucosal tumors originating from the muscularis propria layer. *Gastrointest Endosc*, 2012; 75(1): 195–99
- Zhou P, Zhong Y, Li Q et al: [Chinese consensus on endoscopic diagnosis and management of gastrointestinal submucosal tumor (Version 2018)] *Zhonghua Wei Chang Wai Ke Za Zhi*, 2018; 21(8): 841–52 (in Chinese)
- Kumbhari V, Saxena P, Azola A et al: Submucosal tunneling endoscopic resection of a giant esophageal leiomyoma. *Gastrointest Endosc*, 2015; 81(1): 219–20
- Tan Y, Liu D: En bloc submucosal tunneling endoscopic resection for a giant esophageal leiomyoma. *Gastrointest Endosc*, 2015; 82(2): 399
- Wang L, Ren W, Zhang Z et al: Retrospective study of endoscopic submucosal tunnel dissection (ESTD) for surgical resection of esophageal leiomyoma. *Surg Endosc*, 2013; 27(11): 4259–66
- Tu S, Huang S, Li G et al: Submucosal tunnel endoscopic resection for esophageal submucosal tumors: A multicenter study. *Gastroenterol Res Pract*, 2018; 2018: 2149564
- Sun LJ, Chen X, Dai YN et al: Endoscopic ultrasonography in the diagnosis and treatment strategy choice of esophageal leiomyoma. *Clinics*, 2017; 72(4): 197–201
- Tan Y, Huo J, Liu D: Current status of submucosal tunneling endoscopic resection for gastrointestinal submucosal tumors originating from the muscularis propria layer. *Oncol Lett*, 2017; 14(5): 5085–90
- Liu BR, Song JT, Kong LJ et al: Tunneling endoscopic muscularis dissection for subepithelial tumors originating from the muscularis propria of the esophagus and gastric cardia. *Surg Endosc*, 2013; 27(11): 4354–59
- Mao XL, Ye LP, Zheng HH et al: Submucosal tunneling endoscopic resection using methylene-blue guidance for cardiac subepithelial tumors originating from the muscularis propria layer. *Dis Esophagus*, 2017; 30(3): 1–7
- Chen T, Zhou PH, Chu Y et al: Long-term outcomes of submucosal tunneling endoscopic resection for upper gastrointestinal submucosal tumors. *Ann Surg*, 2017; 265(2): 363–69
- Song S, Feng M, Zhou H et al: Submucosal tunneling endoscopic resection for large and irregular submucosal tumors originating from muscularis propria layer in upper gastrointestinal tract. *J Laparoendosc Adv Surg Tech A*, 2018; 28(11): 1364–70
- Lv XH, Wang CH, Xie Y: Efficacy and safety of submucosal tunneling endoscopic resection for upper gastrointestinal submucosal tumors: A systematic review and meta-analysis. *Surg Endosc*, 2017; 31(1): 49–63
- von Delius S, Gillen S, Doundoulakis E et al: Comparison of transgastric access techniques for natural orifice transluminal endoscopic surgery. *Gastrointest Endosc*, 2008; 68(5): 940–47
- Kataoka Y, Tsuji Y, Sakaguchi Y et al: Bleeding after endoscopic submucosal dissection: Risk factors and preventive methods. *World J Gastroenterol*, 2016; 22(26): 5927–35
- Huh CW, Youn YH, Jung da H et al: Early attempts to eradicate *Helicobacter pylori* after endoscopic resection of gastric neoplasm significantly improve eradication success rates. *PLoS One*, 2016; 11(9): e0162258

With some advantages over other resection approaches, such as high effectiveness, shorter hospitalization, low cost, and fewer complications, STER could be the best option for resection of esophageal SMTs ≤ 40 mm originating from the MP layer.

Conflict of interest

None.