



Oncology

A rare case of urachal inflammatory myofibroblastic tumor

Rose George^{a,1}, Daniel Swerdloff^{b,1}, Mahmut Akgul^a, Tipu Nazeer^a, Badar M. Mian^{b,*}^a Department of Pathology, Albany Medical Center, Albany, NY, 12208, USA^b Department of Urology, Albany Medical Center, Albany, NY, 12208, USA

ARTICLE INFO

Keywords:

Inflammatory myofibroblastic tumor (IMT)
 Urachal
 Genitourinary
 Anaplastic lymphoma kinase (ALK)

ABSTRACT

Inflammatory myofibroblastic tumors (IMT) of the urachus is a rare neoplastic condition characterized by proliferation of spindle cell, likely derived from myofibroblasts or fibroblasts, with acute and chronic inflammatory infiltrate. Urachal IMT present with abdominal/pelvic pain and urinary symptoms. These often manifest as abdominal mass involving adjacent structures. We describe a case of young female with urachal IMT that was excised with a wide margin to ensure complete removal of all adjacent affected tissue using robotic-assisted laparoscopic approach. Immunohistochemical evidence of ALK and ALK gene rearrangement were confirmed in this tumor which are diagnostic of IMT.

Introduction

Inflammatory myofibroblastic tumors (IMT), previously known as inflammatory or fibromyxoid pseudotumor, is a low-grade neoplasms that mimics certain malignant features such as local growth and invasion of adjacent structures. IMT has been reported in various organ systems, with the lungs and orbits representing the most frequent sites.¹ IMT of the genitourinary (GU) tract is quite uncommon, where the urinary bladder is most frequently involved while the urachal IMT is exceedingly rare. To our knowledge, only 8 cases of urachal IMT have been described in the literature. We describe a case of a young woman who presented with abdominal/pelvic pain, initially diagnosed and managed as pelvic inflammatory disease (PID) and urinary tract infection, but ultimately was found to have a urachal mass.

Case presentation

A 27-year-old African American female who presented to the hospital with complaints of lower midline abdominal and pelvic pain radiating to her vagina and dysuria. Initially, she was diagnosed and treated for *gardnerella vaginalis* and *trichomonas* infection. After one month, she presented again to the emergency room with worsening abdomino-pelvic pain. On examination, the pain was centered in lower abdomen, with some rebound tenderness. Due to her recent history, PID was suspected and she was started on antibiotics. Although she remained afebrile, abdominal pain progressively worsened despite

antibiotics over the next 2 days. Due to the pain which was out of proportion to the physical findings, and non-resolution of her symptoms, additional work up was initiated. An abdominal ultrasound, showing a heterogeneous mass, approximately 3.2 × 2.5 × 2.6 cm, was followed by a computed tomography scan of the abdomen and pelvis with contrast. The CT scan demonstrated a peripherally enhancing mixed solid/cystic mass superior/anterior to the bladder, which was suspicious for a urachal cystic mass or abscess (Fig. 1). Percutaneous needle aspiration and drainage was attempted, yielding only a small amount of serous fluid with non-contributory fluid analysis. At this point, plan was made for robotic-assisted laparoscopic excision of this symptomatic mass of unclear etiology.

Due to urinary symptoms and proximity of mass to the bladder, cystoscopy and transurethral resection of a suspicious area at the dome. Frozen section assessment did not reveal any abnormal neoplastic or proliferative process in the urothelium or detrusor muscle. We then proceeded to perform robotic-assisted excision of the mass using laparoscopic port configuration similar to that used for other pelvic procedures. The mass was clearly seen at the anterior abdominal wall, involving the urachus and the left umbilical artery (Fig. 2 A, B). Upon dissection, the entire area was firm, fibrotic and without easily discernable tissue planes, requiring sharp dissection throughout. The mass including urachus and surrounding abnormal tissue was excised widely, along with a 3–4 cm wide partial cystectomy at dome of the bladder due to the firmness and dense adherence of the mass to the perivesical tissue (Fig. 2 C, D). The bladder was closed with 3-0 polyglactin

* Corresponding author. Department of Urology, 23 Hackett Blvd., Albany, NY, 12208, USA.

E-mail address: mianb@amc.edu (B.M. Mian).¹ Equal contribution to the manuscript.<https://doi.org/10.1016/j.eucr.2021.101575>

Received 1 January 2021; Received in revised form 13 January 2021; Accepted 16 January 2021

Available online 20 January 2021

2214-4420/© 2021 The Authors.

Published by Elsevier Inc.

This is an open access article under the CC BY-NC-ND license

<http://creativecommons.org/licenses/by-nc-nd/4.0/>.

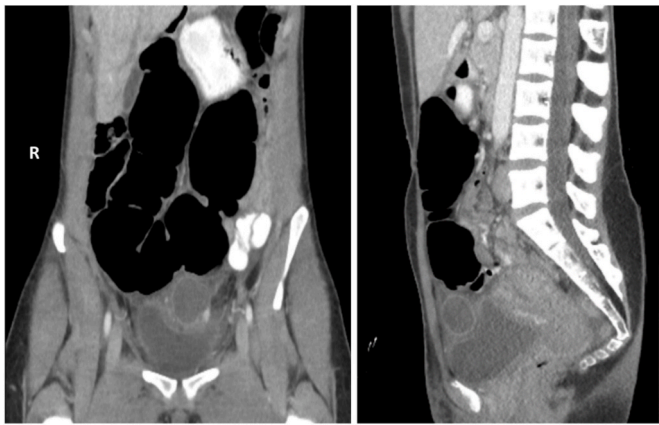


Fig. 1. CT Scan showing a mixed cystic, solid mass superior to the bladder, with stranding around the bladder and anterior abdominal wall.

suture applied in a running fashion. The patient was discharged on post-operative day 2 with a Foley catheter for bladder drainage for 7 days. She has remained asymptomatic for 5 months since surgery.

On gross examination, the specimen was a $6.6 \times 5.5 \times 2.4$ cm tan-pink, firm, irregular mass with surrounding fibrofatty tissue, with centrally friable tan-brown cut surface noted after sectioning. Microscopic examination of the mass revealed spindled myofibroblastic proliferation arranged in haphazard irregular growth pattern, interspersed with a prominent mixed inflammatory infiltrate. The spindle cells have eosinophilic cytoplasm with vesicular nuclei, and moderate nuclear pleomorphism (Fig. 3A). The spindle cells have eosinophilic cytoplasm with vesicular nuclei, and moderate nuclear pleomorphism (Fig. 3B). Mitotic figures were estimated at 7 per 50 high-power fields with a few atypical mitotic figures. Immunohistochemical work-up revealed that the tumor cells were negative for CD34 but focally positive for SMA with “tram-track” pattern expression (Fig. 3C). DOG-1 and S100 were also negative.

Ki67 proliferation index was 10–20% (Fig. 3D). Most tumor cells expressed ALK1 (Fig. 3E). Subsequently, fluorescence in situ hybridization analysis was performed using the Vysis ALK break apart probes confirmed *ALK* gene rearrangement in 36% of the cells (Fig. 3F).

Discussion

IMT is amongst the rare tumors which may develop at any anatomic sites throughout the various organ systems. These tumors predominantly exhibit spindle cell morphology, likely derived from myofibroblasts or fibroblasts, and have at times been mistaken for smooth muscle sarcomas. Reports suggest that these can occur at any age ranging from infant to the elderly. The etiology and pathophysiology of IMT are unclear but it is thought to be related to trauma, inflammation, viral or bacterial infections. There is an association between IMT and certain chromosomal aberrations such as chromosome 2 in the *ALK* gene region 2p23.² Immunostaining for ALK is quite specific, but not very sensitive, for diagnosis of IMT, and lack of ALK immunoreactivity does not exclude IMT.³ Documentation of the *ALK* gene rearrangement by FISH or other molecular techniques is preferred over protein expression assessment.

To our knowledge, only 8 cases of IMT have been described in the literature.⁴ The age range of these cases was 3 years–77 years, with 4 cases presenting before age 18, and 6 cases noted in males. Typical presenting symptoms include abdominal and/or pelvic pain and sometimes lower urinary tract symptoms including dysuria or hematuria. Wide and complete excision of the mass including any surrounding tissues or organs which may be involved in the tumor process is essential. Most cases of urachal IMT excision have included a partial excision of the bladder, which was also required in the present case.⁵ IMT (including urachal) are rarely metastatic and long-term follow up is not necessary after complete excision of the involved tissues, especially in cases positive for *ALK* gene rearrangement.

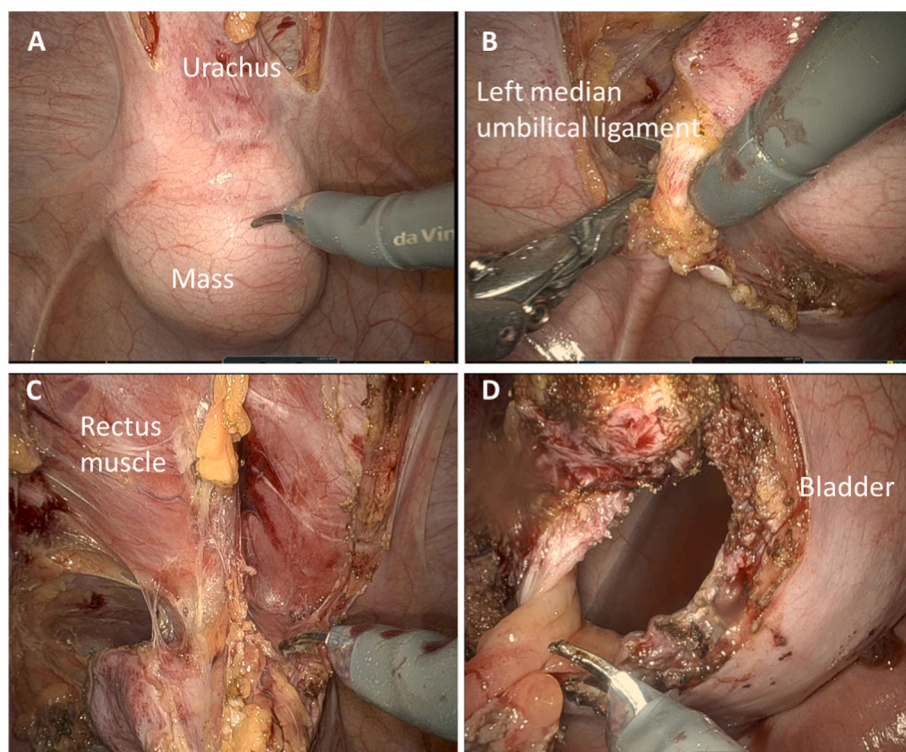


Fig. 2. Urachal mass with involvement of left medial umbilical ligament and anterior abdominal wall (A, B). Wide excision of the mass along with the entire urachus, surrounding peritoneum, and soft tissue, left medial umbilical and dome of the bladder (C, D).

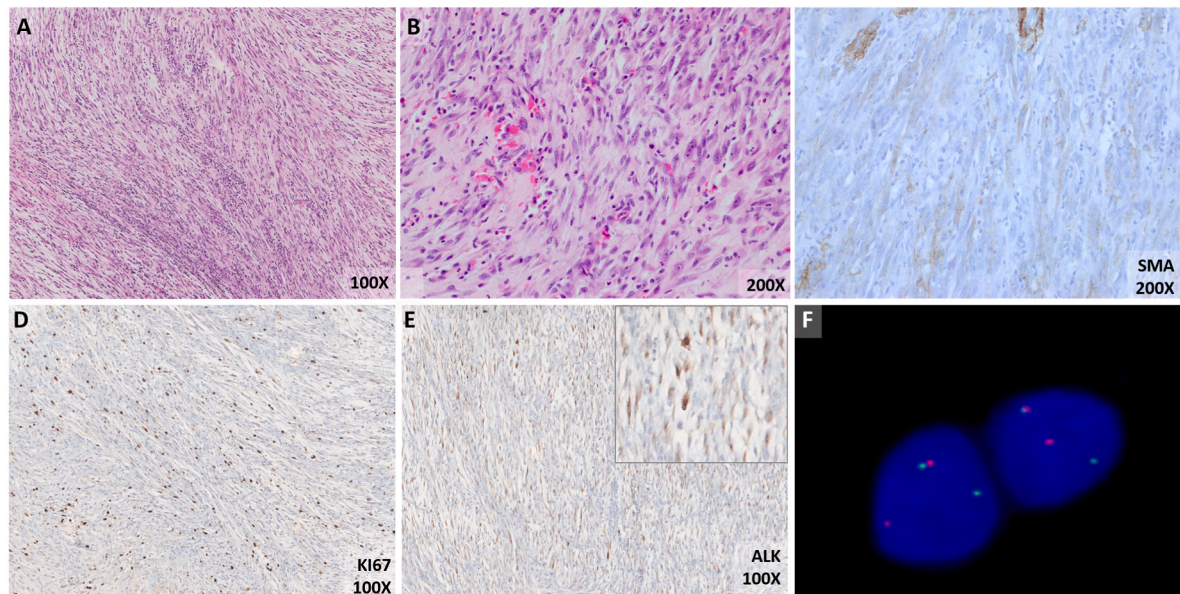


Fig. 3. Low (A, 100X) and high (B, 200X) images of the inflammatory myofibroblastic tumor with haphazard proliferation of plump spindle cells with eosinophilic cytoplasm and intermixed acute and chronic inflammatory infiltrate. Smooth muscle actin (SMA) exhibits characteristic “tram-track” staining pattern (C, 200X). Moderate (D, 100X) or high Ki67 proliferation index can be misleading. ALK protein expression (E, 100X; inset 400X) is specific in these tumors, although ALK gene rearrangement by fluorescent in situ hybridization (F) is considered gold standard if ALK gene alteration is present. (For interpretation of the references to colour in this figure legend, the reader is referred to the Web version of this article.)

Conclusion

Urachal inflammatory myofibroblastic tumor typically present with non-specific symptoms and can be mistaken for other pelvic or GU disorders or infection. ALK gene rearrangement is highly diagnostic of IMT. These tumors can exhibit locally invasive phenotype and, thus, complete surgical excision of the mass and adjacent structures is essential.

Funding source

This research did not receive any specific grant from funding agencies in the public, commercial, or not-for-profit sectors.

References

1. Patnana M, Sevrukov AB, Elsayes KM, Viswanathan C, Lubner M, Menias CO. Inflammatory pseudotumor: the great mimicker. *AJR Am J Roentgenol.* 2012;198(3): W217–W227.
2. Griffin CA, Hawkins AL, Dvorak C, Henkle C, Ellingham T, Perlman EJ. Recurrent involvement of 2p23 in inflammatory myofibroblastic tumors. *Canc Res.* 1999;59(12): 2776–2780.
3. Antonescu CR, Suurmeijer AJ, Zhang L, et al. Molecular characterization of inflammatory myofibroblastic tumors with frequent ALK and ROS1 gene fusions and rare novel RET rearrangement. *Am J Surg Pathol.* 2015;39(7):957–967.
4. Wang K, Zhou H, Lu Y, et al. ALK-negative urachal inflammatory myofibroblastic tumor in an elderly female: a case report. *Medicine (Baltim).* 2018;97(51), e13619.
5. Nascimento AF, Dal Cin P, Cilento BG, Perez-Atayde AR, Kozakewich HP, Nosé V. Urachal inflammatory myofibroblastic tumor with ALK gene rearrangement: a study of urachal remnants. *Urology.* 2004;64(1):140–144.