

A Spectacular Endoscopic Anatomy of the Pituitary Gland and the Circle of Willis in a Living Person

The circle of Willis is a ring-like vascular network at the base of the brain that connects cerebral arteries, the basilar artery, and carotid arteries and provides blood supply to the brain.¹ The pituitary gland is located at the base of the brain in the sella turcica (pituitary fossa) of the sphenoid bone.² In inferior view of the brain, both the circle of Willis and the pituitary gland structures can be seen. It is not typically possible to observe such a spectacular anatomy of the pituitary gland and the circle of Willis in a living person. However, these structures can be seen through endoscopic surgery of suprasellar arachnoid cysts (SSCs) due to their proximity to the pituitary gland.³

SSCs are rare and benign but pose a diagnostic challenge.⁴ They can result in hydrocephalus through occlusion of the aqueduct and the third ventricle.⁵ SSCs in different age groups have different clinical presentations.⁶ Although recent studies recommend a treatment approach based on a simple classification of these cysts,⁴ the most recommended treatment is the surgical strategy. An urgent endoscopic third ventriculostomy procedure can improve the symptoms by decreasing the intracranial pressure and creating a normal cerebrospinal fluid flow. Besides, one of the standard minimally invasive therapeutic approaches for SSCs is stereotaxis.⁷ During surgery, due to the creation of cystic and clear space as a result of the endoscopic removal of SSC, it is possible to observe such spectacular skull base structures.

The images shown in figure 1 were captured during an endoscopic surgery in a 3-year-old girl suffering from a delay in the development path and increasing head circumference. She was referred to the tertiary referral pediatric neurosurgery ward (Nemazee Hospital, Shiraz, Iran) in 2017. Following a magnetic resonance imaging (MRI) scan, the patient was diagnosed with SSCs. Figure 1 shows spectacular skull base structures such as the pituitary gland, pituitary stalk, branches of the circle of Willis, and the sellar region.

The study was approved by the Ethics Committee of Shiraz University of Medical Sciences and a written informed consent was obtained from the child's parents.

Conflict of Interest: None declared.

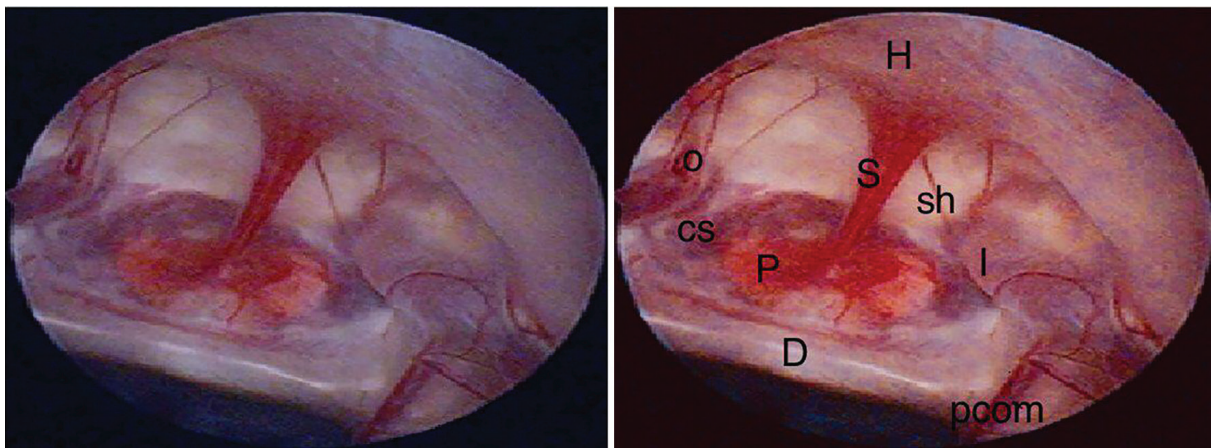


Figure 1: The inferior view of the brain illustrating skull base structures. H: Hypothalamus; S: The stalk of hypophysis; P: Pituitary gland; D: Dorsum sella; CS: Cavernous sinus; sh: Superior hypophyseal artery; O: Ophthalmic artery; I: Internal carotid artery; pcom: Posterior communicating artery

Please cite this article as: A Spectacular Endoscopic Anatomy of the Pituitary Gland and the Circle of Willis in a Living Person. Iran J Med Sci. 2019;44(1):81-82.

Mohammad Sadegh Masoudi^{1,2}, MD; Seyed Hossein Owji³, MD

¹Department of Neurosurgery, Shiraz University of Medical Sciences, Shiraz, Iran;

²Trauma Research Center of Aja university of Medical Sciences, Tehran Iran;

³Student Research Committee, School of Medicine, Shiraz University of Medical Sciences, Shiraz, Iran

Correspondence:

Seyed Hossein Owji, MD;
Student Research Committee, School of Medicine, Zand Street, Postal code: 71348-45794, Shiraz, Iran
Tel: +98 917 0005290
Fax: +98 71 32122970
Email: owji_h@sums.ac.ir
Received: 9 June 2018
Revised: 23 July 2018
Accepted: 19 August 2018

References

- 1 Krishnaswamy A, Klein JP, Kapadia SR. Clinical cerebrovascular anatomy. *Catheter Cardiovasc Interv.* 2010;75:530-9. doi: 10.1002/ccd.22299. PubMed PMID: 20049963.
- 2 Larkin S, Ansorge O. Development And Microscopic Anatomy of The Pituitary Gland. In: De Groot LJ, Chrousos G, Dungan K, Feingold KR, Grossman A, Hershman JM, et al., editors. *Endotext.* Massachusetts: South Dartmouth (MA); 2000.
- 3 Fenstermaker R, Abad A. Imaging of Pituitary and Parasellar Disorders. *Continuum (Minneapolis, Minn).* 2016;22:1574-94. doi: 10.1212/CON.0000000000000380. PubMed PMID: 27740989.
- 4 Andre A, Zerah M, Roujeau T, Brunelle F, Blauwblomme T, Puget S, et al. Suprasellar Arachnoid Cysts: Toward a New Simple Classification Based on Prognosis and Treatment Modality. *Neurosurgery.* 2016;78:370-9. doi: 10.1227/NEU.0000000000001049. PubMed PMID: 26445374.
- 5 Crimmins DW, Pierre-Kahn A, Sainte-Rose C, Zerah M. Treatment of suprasellar cysts and patient outcome. *J Neurosurg.* 2006;105:107-14. doi: 10.3171/ped.2006.105.2.107. PubMed PMID: 16922071.
- 6 Gui SB, Wang XS, Zong XY, Zhang YZ, Li CZ. Suprasellar cysts: clinical presentation, surgical indications, and optimal surgical treatment. *BMC Neurol.* 2011;11:52. doi: 10.1186/1471-2377-11-52. PubMed PMID: 21586175; PubMed Central PMCID: PMC3119168.
- 7 Guzel A, Trippel M, Ostertage CB. Suprasellar arachnoid cyst: a 20- year follow-up after stereotactic internal drainage: case report and review of the literature. *Turk Neurosurg.* 2007;17:211-8. PubMed PMID: 17939110.