

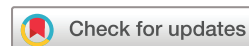Tumoral melanosis mimicking residual melanoma in the setting of talimogene laherparepvec treatment

Song Y Park ,¹ Austin R Green,² Rouba Hadi,³ Coley Doolittle-Amieva,⁴ Jennifer Gardner,^{1,4} Ata S Moshiri^{1,2,4}

To cite: Park SY, Green AR, Hadi R, *et al.* Tumoral melanosis mimicking residual melanoma in the setting of talimogene laherparepvec treatment. *Journal for ImmunoTherapy of Cancer* 2022;**10**:e005257. doi:10.1136/jitc-2022-005257

► Additional supplemental material is published online only. To view, please visit the journal online (<http://dx.doi.org/10.1136/jitc-2022-005257>).

Accepted 11 October 2022



© Author(s) (or their employer(s)) 2022. Re-use permitted under CC BY-NC. No commercial re-use. See rights and permissions. Published by BMJ.

¹Division of Dermatology, Department of Medicine, University of Washington, Seattle, Washington, USA

²Department of Laboratory Medicine and Pathology, University of Washington, Seattle, Washington, USA

³Department of Pathology, Billings Clinic, Billings, Montana, USA

⁴Fred Hutchinson Cancer Center, Seattle, Washington, USA

Correspondence to

Dr Ata S Moshiri;
amoshiri@uw.edu

ABSTRACT

Talimogene laherparepvec (T-VEC) has become an increasingly popular treatment option for surgically non-resectable, recurrent melanoma, usually of cutaneous metastases. The complete response (CR) rate has been reported to be ~20% with a median of ~9 months to achieve it. In real-world practice, decrease of tumor size often occurs rapidly within the first 2–3 months, while improvement of the pigmentation takes several more months. Such clinical observation of lasting pigmentation could be explained by tumorous melanosis—a histopathological term referring to the presence of a melanophage-rich inflammatory infiltrate without remaining viable tumor cells. Herein, we report six patients with metastatic cutaneous melanoma who were treated with T-VEC. Biopsies were performed after observing clinical responses in the injected tumors. Pathological evaluation demonstrated non-viable or absent tumor tissue with tumorous melanosis in all cases. To accurately assess response to therapy and potentially decrease unnecessary additional T-VEC treatments, serial biopsy of ‘stable’ lesions should be considered to assess the presence or absence of viable tumor.

BACKGROUND

Talimogene laherparepvec (T-VEC) became the first oncolytic virus approved by the Food and Drug Administration for local injection of unresectable metastatic melanoma. As a genetically modified herpes simplex virus-1, T-VEC has a novel mechanism of action achieved via several genomic modifications to attenuate neurovirulence, increase specificity for cancer cells, enhance antigen presentation, and stimulate the immune response by insertion of the gene for human granulocyte-macrophage colony-stimulating factor (GM-CSF).¹

The randomized open-label phase III trial comparing T-VEC to GM-CSF injections, known as Oncovex^{GM-CSF} Pivotal Trial in Melanoma (OPTiM), demonstrated a superior and significant durable response rate (complete response (CR) plus partial response (PR) lasting ≥6 months) in the T-VEC arm (19.3% vs 1.4%) as its primary endpoint.^{2,3} CR and

PR were achieved in 16.9% and 14.6%, respectively, and median time to CR for those who achieved it was 8.6 months. Of note, assessment of treatment response in these studies has largely relied on clinical observation of changes in size and pigmentation with no interim pathological assessment in most cases.

While remnant pigmentation is an important component of response assessment, it is important to note that clinically suspicious pigmented macules or papules may represent tumorous melanosis, a histopathological term referring to the presence of melanin-laden macrophages in the absence of viable tumor cells. This phenomenon has been recognized by pathologists, but it has been rarely reported in the setting of cancer immunotherapy. Only two case reports to date have detailed its occurrence in the setting of T-VEC therapy.^{4,5} Additionally, a separate small study detailed the use of quantitative immunofluorescence as a novel diagnostic method in two patients post-T-VEC treatment to distinguish CD68+ macrophages with cytoplasmic SOX-10 costaining likely representing phagocytosed nuclear melanoma fragments from viable melanoma cells with nuclear SOX-10 expression.⁶ No significant data have been collected regarding the frequency of tumorous melanosis or its time of onset (ie, time of complete pathological response), including large-scale data reported in OPTiM (tumorous melanosis was, in fact, not mentioned). Several additional isolated case reports have been published detailing tumorous melanosis in association with other immunotherapies, including ipilimumab,⁷ pembrolizumab,^{8,9} and dabrafenib/trametinib.¹⁰ A single case series consisting of 10 patients with tumorous melanosis was also recently published, though none were treated with T-VEC.¹¹

Here we report our experience with six cases of tumorous melanosis following successful T-VEC therapy, in which follow-up biopsies suggest that complete pathological response in a majority of cases occurs significantly sooner than clinically apparent response. To our knowledge, this is the largest case series reporting such findings. We provide a detailed timeline of the clinical courses for our patients, which could serve as a practical guideline for clinicians treating patients with intratumoral therapies.

CASE SUMMARIES

Among 15 patients treated with T-VEC for melanoma in our institute between 2017 and 2021, we identified 6 patients for whom we performed serial biopsies including post-treatment specimens confirming tumorous melanosis.

The [table 1](#), [figure 1](#) and the online supplemental figure provide a summary of the clinical characteristics and responses with T-VEC therapy in our cohort. All patients included in this study provided informed consent for their clinical data to be used for medical research.

Among the six patients, five had cutaneous melanoma which was refractory to multiple lines of treatment including immune checkpoint inhibitor (ICI). One patient (case 6) elected for T-VEC injection before ICI for the unresectable but localized superficial tumors on her thigh. One patient (case 5) received concurrent pembrolizumab and T-VEC therapy to control distant metastasis.

All patients had T-VEC therapy for 4–23 months until the remaining lesion was surgically removed (case 2), or pathological CR was achieved. Disease burden varied from two to innumerable dermal or subcutaneous nodules. The size of tumors ranged between 1.0mm to 1.6cm. Clinical responses, such as decreasing size of the papular lesions, were typically observed within 2–3 months from the beginning of T-VEC injection. However, complete resolution of pigmentation was delayed by many months in the majority of tumors.

We performed biopsies of five cases when elevated tumors decreased to macular lesions without change in size or pigmentation for several months. In one case (case 2), increased size of the injected tumor prompted surgical excision, which demonstrated no viable tumor cells in pathology. Of note, while the anatomically increased size of the tumor was reported, the maximum standardized uptake value (SUV_{max}) of the lesion decreased from the previous scan at the time of the excision. The transient increase of tumor size was thus deemed to represent pseudoprogession.

Pathological evaluation of those pigmented macular lesions demonstrated fibrosis, inflammation, and varying degrees of pigment-laden melanophages (ie, tumorous melanosis) and no residual viable melanoma in all cases. They were carried out between 4 months and 23 months from the initial treatment, which preceded clinical resolution of disease.

No patient developed regrowth or recurrent melanoma of the injected lesions as of the time of this report. Two patients developed new in-transit metastatic tumors 5 and 2 months after the last dose of T-VEC (case 3 and 5, respectively). All patients experienced grade 1 flu-like symptoms after injections, which tended to decrease in subsequent cycles. No grade 3 or higher adverse events were reported. Patients' underlying conditions, including Crohn's disease, immune-related adverse events from previous treatment, and chronic kidney disease, did not aggravate with T-VEC injection. One patient (case 4), who also was treated with multiple lines of systemic treatment, developed multiple myeloma 34 months after the last injection of T-VEC.

COMMENT

The treatment of metastatic melanoma has evolved considerably over recent years to include a variety of agents. Among them, T-VEC therapy has demonstrated promising results, especially in treating cutaneous or superficial metastatic melanoma. However, practical data to guide clinicians, such as the variable timing and patterns of responses and toxicity, has rarely been reported.

Typically, clinical assessment of treatment response is made based on tumor size and remnant pigmentation. Despite the understandability of this approach, novel treatments have shown atypical response patterns such as pseudoprogession—a transient increase in tumor size due to inflammation that precedes diminution—especially in melanoma.¹²

For superficial tumors being assessed by size and color, the evaluation could be challenging due to tumorous melanosis, the presence of melanophage-rich cells without the remaining viable tumor. Indeed, tumorous melanosis has been recognized as a mimicker of metastatic disease in the clinical setting and has been described in patients who received immunotherapy.^{8 10 11} Rare reports of this phenomenon have been documented in patient groups undergoing T-VEC therapy.^{13 14} To date, moreover, little has been described regarding time course and extent of tumorous melanosis.

The clinical impression remains the primary deciding factor for therapeutic considerations. A substantial decrease in lesion size is interpreted as a promising, but still incomplete, response. Routine biopsies of lesions to evaluate residual disease is not common practice. In our cohort of six patients, we recognized that visible lesions post injection are not necessarily indicative of residual melanoma. In all six patients, scout biopsies of clinically apparent residual tumor masses after T-VEC therapy simply demonstrated prominent tumorous melanosis with no morphological evidence of viable melanoma, confirmed by immunohistochemical stains in all cases. Histologically, the excisions contained prominent fibrosis with variably dense lymphohistiocytic inflammation and pigment incontinence. These features are evidence of a substantial host response.

Table 1 Summary of patient characteristics

	Sex/age	Date of primary diagnosis (site and stage*)	Date of metastases (site)	Prior treatment for metastatic disease	Underlying conditions	T-VEC treatment period (months)	T-VEC treated area (size)	Best clinical response by tumor size and color assessment†	Biopsy confirmation of CR (months after initial treatment)	PFS/OS (months)
Case 1	M/50	May 2018 (R leg, pT4a pN3b M0, IIID)	May 2019 (in-transit, distal lymph nodes)	Ipilimumab and nivolumab	Crohn's disease, hypophysitis and colitis from ICI	November 2019–June 2020 (7 months)	Numerous R leg lesions (0.1–1.0 cm)	PR: papular lesions flattened within 3 months, but pigmented papules and macules persisted	April 2020 (5 months), June 2020 (7 months)	9/9
Case 2	M/59	November 2015 (R arm, pT3b pN0 M0, IIB)	January 2020 (in-transit)	Excision and nivolumab	CKD from ICI	January 2020–June 2020 (5 months)	Two R arm nodules (1.0–1.5 cm)	PD: two apparently smaller nodules grew and coalesced into a single pigmented, protuberant nodule prompting excision	June 2020 (6 months)‡	7/7
Case 3	M/43	March 2008 (L leg, TX pN0 M0)	July 2019 (in-transit)	Excision and pembrolizumab	Type 1 DM from ICI	August 2019–December 2019 (4 months)	Two L leg nodules (1 cm)	PR: papular lesions flattened within 3 months, but pigmented papules and macules persisted	December 2019 (4 months)	9§/12
Case 4	M/57	July 2010 (R leg, pT3a pN2 M0, IIB)	10/2011 (in-transit)	Excision, ipilimumab, vemurafenib, dabrafenib, pembrolizumab and IL-12	None	August 2016–January 2017 (5 months)	Numerous R leg lesions (<1 cm)	PR: papular lesions flattened within 2 months, but pigmented papules and macules persisted	December 2016 (4 months), January 2017 (5 months)	48/48¶
Case 5	M/41	2001 (pT4b, IIIC)	2/2007 (in-transit)	Excision, intralesional IFN, isolated limb perfusion with melphalan, CD4 T-cell infusion, ipilimumab, pembrolizumab and IL-12	Colitis from ICI	October 2016–August 2018 (10 months, with pembrolizumab March 2018–November 2019)	Seven L leg lesions (0.3–1.6 cm)	PR: large subcutaneous nodules decreased within 3 months, but pigmented papules and macules persisted for 22 months	August 2018 (22 months)	12**/46
Case 6	F/81	September 2016 (pT3a pN1c M0, IIB)	May 2018 (in-transit)	None	CKD	August 2018–July 2020 (23 months)	~10L leg lesions (1.0–1.5 cm)	PR: large papule started to decrease after first dose, but the lesion persisted as a stable pigmented macule for 6 months	July 2020 (23 months)	24/24

*American Joint Committee on Cancer Staging, Eighth Edition.

†All patients achieved pathological CRs.

‡Excision of the lesion was performed.

§Patient developed a new in-transit metastatic tumor 5 months after last dose of T-VEC in May 2020, which was excised with clear margins.

¶Patient was diagnosed with multiple myeloma 36 months after last dose of T-VEC in May 2020. Of note, he was treated with multiple other systemic treatments previously. It is unclear if the diagnoses are associated with prior treatments including T-VEC.

**Patient developed a new in-transit metastatic tumor 2 months after last dose of T-VEC in October 2018, which was treated with excision.

CKD, chronic kidney disease; CR, complete response; F, female; ICI, immune checkpoint inhibitor; IL, interleukin; L, left; M, male; OS, overall survival; PD, progressive disease; PFS, progression-free survival; PR, partial response; R, right; T-VEC, Talimogene laherparepvec.

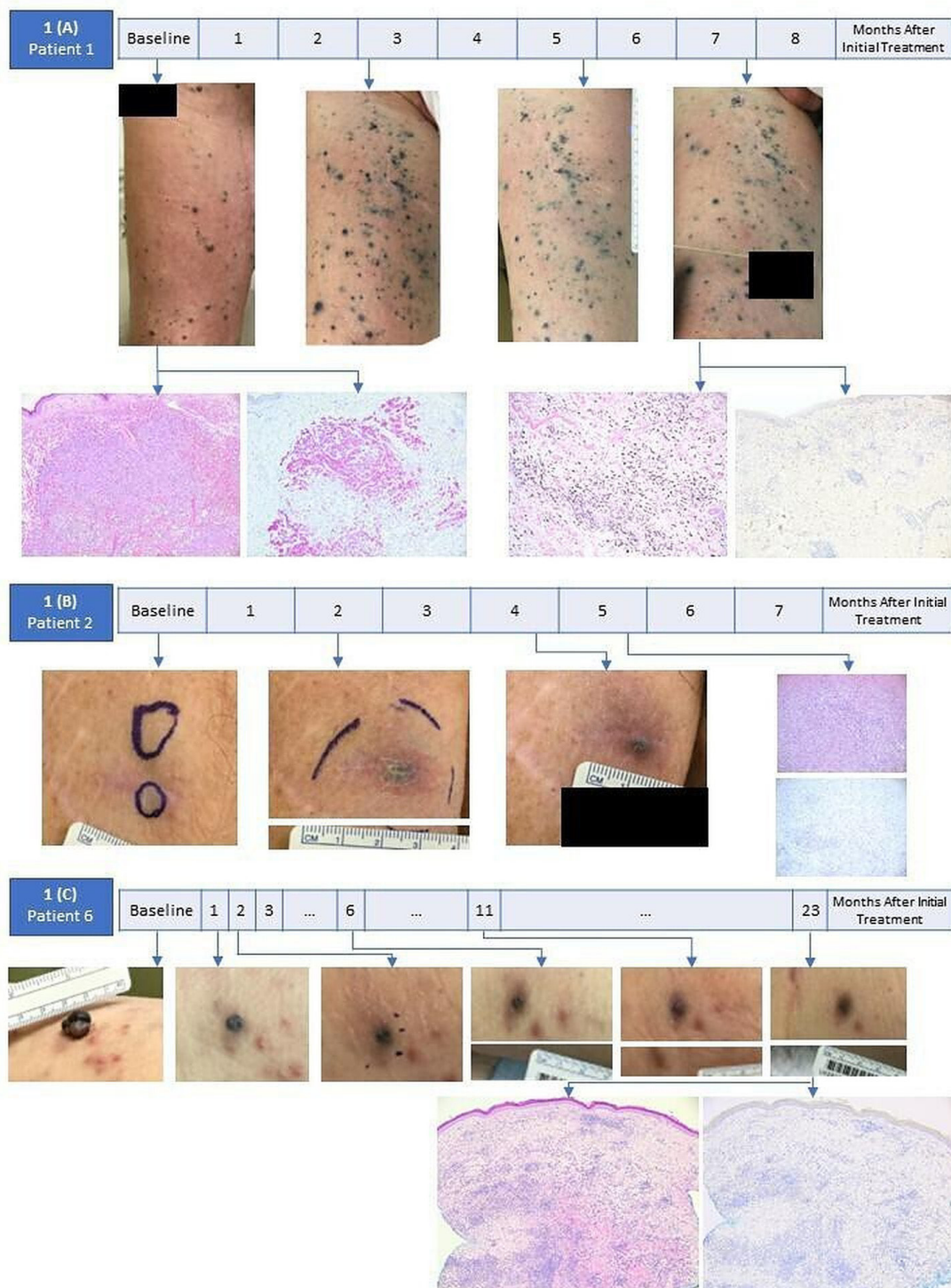


Figure 1 Serial clinical and pathological responses of representative patients. (A) Patient 1 had pigmented papules before treatment, which flattened 3 months after the first injection. Note that the number of lesions increased for the first 3 months of treatment, while the overall size and height of the lesions decreased. Histopathological findings of the patient's earlier biopsy were those of an atypical, epithelioid proliferation of malignant cells with strong Melan-A red expression, which are overall compatible with malignant melanoma. Additional biopsy post-treatment however demonstrated prominent fibrosis and mixed inflammation with abundant pigmented histiocytes (melanophages). A Melan-A red stain was only focally positive, highlighting cytoplasmic contents of histiocytes. (B) Two apparent subcutaneous nodules of patient 2 coalesced into a single, larger nodule over the course of treatment. The size of the nodule increased over 5 months, which was interpreted as a treatment failure. Histopathological findings were remarkable for dermal fibrosis and numerous melanophages. A Melan-A red stain was only focally positive, highlighting cytoplasmic contents of histiocytes. (C) Patient 3 had marked shrinkage one exophytic nodule after her first treatment dose. Remnant pigmented papules and subsequently macules persisted for more than 23 months of treatment, which on biopsy ultimately showed similar features to the prior two patients. There was fibrosis with mixed inflammation, focal cytoplasmic Melan-A red expression in melanophages, and no evidence of residual melanoma.

In managing patients with advanced disease who require non-surgical treatments, it is thus crucial to recognise that residual tumor mass can be seen post treatment, consisting of only a dense and reactive inflammatory response. It should be noted that biopsies were only performed in this series of cases due to the ambiguous or worrisome clinical setting; thus, we could not accurately assess the incidence of tumorous melanosis in our entire T-VEC cohort.

Our findings emphasize the important contribution of periodic histopathological assessment. The findings also highlight that, in some cases, biological response to therapy may precede and occasionally contradict the assessment of clinical response. The responding tumor in one of our patients showed decreased fluorodeoxyglucose (FDG) uptake and tumorous melanosis in the setting of increasing size of the lesion. As such, assessing metabolic activities of the tumor by FDG-positron emission tomography (PET) could assist the response assessment in select cases. Thus, consideration for biopsy and/or FDG-PET to assess treatment response in select cases with stable tumor size and/or residual pigmentation may aid in preventing unnecessary extended therapy.

Our study is limited by the retrospective, observational nature of data, as well as the small size of our cohort. Potential future studies will be needed to further evaluate the kinetics and pathophysiology of tumorous melanosis, specifically addressing time from initiation of therapy and the course of response progression in a controlled prospective cohort, which will include assessment of true incidence of tumorous melanosis. Lastly, elucidating the precise roles of the immune cells in tumorous melanosis will be an important next step to further our understanding of the tumor microenvironment and to identify potentially useful biomarkers.

Contributors SYP, ARG, RH, and ASM authored the primary draft of the manuscript, and compiled and analyzed key information and data. ASM, ARG, and RH performed histological analyses of the tumor. ASM, JG and CD-A provided treatment for our study subjects and assisted in information acquisition and analysis. ASM provided senior oversight and helped compile the data and prepare the manuscript. All authors read and approved of the manuscript.

Funding The authors have not declared a specific grant for this research from any funding agency in the public, commercial or not-for-profit sectors.

Competing interests None declared.

Patient consent for publication Not applicable.

Provenance and peer review Not commissioned; externally peer reviewed.

Supplemental material This content has been supplied by the author(s). It has not been vetted by BMJ Publishing Group Limited (BMJ) and may not have been peer-reviewed. Any opinions or recommendations discussed are solely those

of the author(s) and are not endorsed by BMJ. BMJ disclaims all liability and responsibility arising from any reliance placed on the content. Where the content includes any translated material, BMJ does not warrant the accuracy and reliability of the translations (including but not limited to local regulations, clinical guidelines, terminology, drug names and drug dosages), and is not responsible for any error and/or omissions arising from translation and adaptation or otherwise.

Open access This is an open access article distributed in accordance with the Creative Commons Attribution Non Commercial (CC BY-NC 4.0) license, which permits others to distribute, remix, adapt, build upon this work non-commercially, and license their derivative works on different terms, provided the original work is properly cited, appropriate credit is given, any changes made indicated, and the use is non-commercial. See <http://creativecommons.org/licenses/by-nc/4.0/>.

ORCID iD

Song Y Park <http://orcid.org/0000-0003-4366-1821>

REFERENCES

- Raman SS, Hecht JR, Chan E. Talimogene laherparepvec: review of its mechanism of action and clinical efficacy and safety. *Immunotherapy* 2019;11:705–23.
- Andtbacka RHI, Kaufman HL, Collichio F, et al. Talimogene Laherparepvec improves durable response rate in patients with advanced melanoma. *J Clin Oncol* 2015;33:2780–8.
- Harrington KJ, Andtbacka RH, Collichio F, et al. Efficacy and safety of talimogene laherparepvec versus granulocyte-macrophage colony-stimulating factor in patients with stage IIIB/C and IVM1a melanoma: subanalysis of the phase III OPTiM trial. *Oncol Targets Ther* 2016;9:7081–93.
- Danesh M, Faulkner-Jones B, Desai A, et al. Extensive pigment incontinence mimicking persistent melanoma after Talimogene Laherparepvec therapy. *JAMA Dermatol* 2019;155:496–7.
- Rizzo JM, Fecher LA, Chan MP, et al. Metastatic melanoma with diffuse melanosis histologically after stable response to talimogene laherparepvec therapy. *JAAD Case Rep* 2018;4:379–81.
- Audrey-Bayan C, Trager MH, Gartrell-Corrado RD, et al. Distinguishing melanophages from tumor in melanoma patients treated with talimogene laherparepvec. *Melanoma Res* 2020;30:410–5.
- Staser K, Chen D, Solus J, et al. Extensive tumoral melanosis associated with ipilimumab-treated melanoma. *Br J Dermatol* 2016;175:391–3.
- Bari O, Cohen PR. Tumoral melanosis associated with Pembrolizumab-Treated metastatic melanoma. *Cureus* 2017;9:e1026.
- Woodbeck R, Metelitsa AI, Naert KA. Granulomatous tumoral melanosis associated with pembrolizumab therapy: a Mimicker of disease progression in metastatic melanoma. *Am J Dermatopathol* 2018;40:523–6.
- Laino A, Shepherd B, Atkinson V, et al. Tumoral melanosis associated with combined BRAF/MEK inhibition (dabrafenib/trametinib) in metastatic melanoma. *JAAD Case Rep* 2018;4:921–3.
- Jurgens A, Guru S, Guo R, et al. Tumoral melanosis in the setting of targeted immunotherapy for metastatic Melanoma-A single institutional experience and literature review. *Am J Dermatopathol* 2021;43:9–14.
- Jia W, Gao Q, Han A, et al. The potential mechanism, recognition and clinical significance of tumor pseudoprogression after immunotherapy. *Cancer Biol Med* 2019;16:655–70.
- Pinard A, Guey S, Guo D, et al. The pleiotropy associated with de novo variants in CHD4, CNOT3, and SETD5 extends to moyamoya angiopathy. *Genet Med* 2020;22:427–31.
- Shwe S, Yamamoto M, Linden KG, et al. Tumoral melanosis and separate granulomatous inflammation due to Talimogene Laherparepvec. *Am J Dermatopathol* 2022;44:541–3.