

OBSERVATIONS

Difficult Management of Glucose Homeostasis in a 21-Month-Old Child With Type 1 Diabetes and Unknown Glutaric Aciduria Type I: A Case Report

A 21-month-old boy with previously diagnosed type 1 diabetes was admitted to our unit, presenting with glycometabolic failure (pH 7.30; base excess -11.9 mmol/L; blood glucose 17.3 mmol/L; HbA_{1c} 10.4% [90 mmol/mol]; glycosuria; and ketonuria). During physical examination he was dehydrated and pale and presented with axial hypotonia with hyposthenia, poor head control, hypotonic legs, and hyporeflexia. His neurological clinical status became compromised after the diagnosis of type 1 diabetes when he was 15 months old. During hospitalization, the management of blood glucose homeostasis was difficult because of a high level of glycemic variability. Hypo- and hyperglycemic episodes were associated with acute encephalopathic crises characterized by hypotonia, dyskinetic movements, difficulty swallowing, and episodes of opisthotonus with no loss of consciousness. For better control of blood glucose, subcutaneous insulin treatment was stopped (he was being treated with a basal-bolus scheme using rapid and long-acting insulin analogs) and intravenous insulin was started; a sensor was positioned for continuous glucose monitoring. This therapy improved his clinical status and reduced the glucose variability and the number of encephalopathic crises.

On the basis of the clinical characteristics, mitochondrial encephalopathy was suspected. The patient underwent several biochemical (creatinine kinase, creatine phosphokinase, antinuclear and anti-extractable nuclear antigens antibodies) and instrumental (electroencephalography and electromyography) examinations, with no pathological results. Urinary

organic acids and lactic acid were measured; muscular biopsy and brain magnetic resonance imaging were performed. Histological examination found a myopathy with accumulation of lipids. The analysis of urinary organic acids revealed high levels of glutaric acid and 3-hydroxyglutaric acid. T2-weighted and fluid-attenuated inversion recovery magnetic resonance images of the brain showed white matter signal abnormalities in different regions (primarily in the posterior periventricular and peritrigonal regions) and a bilateral striatal system (caudate nuclei and putamina), as typically happens in glutaric aciduria type I (GA-I) (Fig. 1).

GA-I is an autosomal recessive neuro-metabolic disorder (1–3). It is caused by mutations in the glutaryl-CoA dehydrogenase gene localized on chromosome 19p13.2. Glutaryl-CoA dehydrogenase is a key mitochondrial enzyme in the catabolic pathways of the amino acids L-tryptophan and L-lysine (4). Biochemically, GA-I is characterized by an accumulation of glutaric acid and 3-hydroxyglutaric acid, which can be detected in body fluids (plasma, urine) and tissues. Intracellular accumulation of glutaric acid may cause direct mitochondrial toxicity within neurons and the disruption of the Krebs cycle. It is clinically characterized by a peculiar neurological presentation. Acute encephalopathic crises are precipitated by “trigger” factors, such as immunization, febrile illness, and gastroenteritis that are likely to induce catabolic state (5).

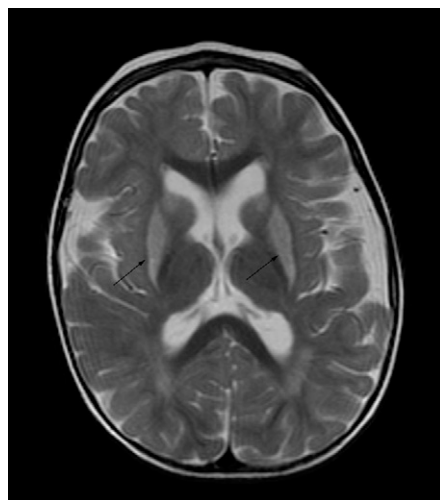


Figure 1—Brain magnetic resonance imaging. The arrows show the hyperintense signal of the caudate nuclei and putamina, as typically happens in patients with GA-I.

We are not aware of any case report describing the association of GA-I and type 1 diabetes. Glucose homeostasis plays a crucial role in the evolution of GA-I. The peculiar association of encephalopathic crises with hypoglycemic events underlines the importance of tailoring insulin therapy to the metabolic needs of the individual patient. In a patient like the one described here, early diagnosis and a specific low-lysine diet in combination with extremely careful insulin management through the use of an insulin pump and continuous glucose monitoring could contribute to making GA-I a treatable condition.

MARCO MARIGLIANO, MD¹
GENAN ANTON, MD¹
ALBERTO SABBION, MD¹
ANITA MORANDI, MD¹
GRAZIA MORANDI, MD²
DANIELA DEGANI, MD²
CLAUDIO MAFFEIS, MD¹

From the ¹Regional Center for Pediatric Diabetes, Clinical Nutrition and Obesity, Department of Life and Reproduction Sciences, University of Verona, Verona, Italy; and the ²Unit of Pediatrics, Department of Life and Reproduction Sciences, University of Verona, Verona, Italy.

Corresponding author: Marco Marigliano, marco.marigliano@univr.it.

DOI: 10.2337/dc13-0724

© 2013 by the American Diabetes Association. Readers may use this article as long as the work is properly cited, the use is educational and not for profit, and the work is not altered. See <http://creativecommons.org/licenses/by-nc-nd/3.0/> for details.

Acknowledgments—No potential conflicts of interest relevant to this article were reported.

M.M. contributed to the discussion and wrote the manuscript. G.A. researched data and contributed to the discussion. A.S. and A.M. contributed to the discussion. G.M. and D.D. researched data and contributed to the discussion. C.M. reviewed and edited the manuscript. C.M. is the guarantor of this work and, as such, had full access to all the data in the study and takes responsibility for the integrity of the data and the accuracy of the data analysis.

References

1. Lindner M, Kölker S, Schulze A, Christensen E, Greenberg CR, Hoffmann GF. Neonatal screening for glutaryl-CoA dehydrogenase deficiency. *J Inher Metab Dis* 2004;27: 851–859

2. Goodman SI, Markey SP, Moe PG, Miles BS, Teng CC. Glutaric aciduria; a “new” disorder of amino acid metabolism. *Biochem Med* 1975;12:12–21
3. Goodman SI, Stein DE, Schlesinger S, et al. Glutaryl-CoA dehydrogenase mutations in glutaric acidemia (type I): review and report of thirty novel mutations. *Hum Mutat* 1998;12:141–144
4. Zschocke J, Quak E, Guldberg P, Hoffmann GF. Mutation analysis in glutaric aciduria type I. *J Med Genet* 2000;37:177–181
5. Kölker S, Garbade SF, Greenberg CR, et al. Natural history, outcome, and treatment efficacy in children and adults with glutaryl-CoA dehydrogenase deficiency. *Pediatr Res* 2006;59:840–847