

SYSTEMATIC REVIEW

Delving Inside the Enigmatic Central Neurocytoma: Electronic Hospital Database Retrieval

Rami Y. Alqroom¹, Khraisat Wesam², Krashan Hanada², Qabaha Anan², Al-Zoubi Mohamad¹, Arabiyat Lamees³, Nserat Rima⁴, Malabeh Qamar⁵, Al Shurbaji Faisal¹, Elayyan Maher¹, Al-Kadasi Wagdy¹, Amer A. Al Shurbaji¹

¹Neurosurgery Department, King Hussein Medical Center, Royal medical services, Amman-Jordan

²Anesthesia Department, King Hussein Medical Center, Royal medical services, Amman-Jordan

³Plastic Surgery Department, Farah Medical Center, Royal medical services, Amman-Jordan

⁴Pathology Department at Princess Iman Research and Laboratory Sciences Center, Amman, Jordan

⁵Radiology Department, King Hussein Medical Center, Royal medical services, Amman, Jordan

Corresponding author: Alqroom Rami, MD. FACS. Neurosurgery department, KHMC. Royal Medical Services, Amman, Jordan. Tel.: 00962797017870. E-mail: dr.alqroomrami@gmail.com. ORCID ID: <http://www.orcid.org/0000-0001-7338-8243>.

doi: 10.5455/aim.2020.28.146-151

ACTA INFORM MED. 2020 JUN 28(2): 146-151

Received: Jun 2, 2020

Accepted: Jun 29, 2020

© 2020 Rami Y. Alqroom, Khraisat Wesam, Krashan Hanada, Qabaha Anan, Al-Zoubi Mohamad, Arabiyat Lamees, Nserat Rima, Malabeh Qamar, Al Shurbaji Faisal, Elayyan Maher, Al-Kadasi Wagdy, Amer A. Al Shurbaji

This is an Open Access article distributed under the terms of the Creative Commons Attribution Non-Commercial License (<http://creativecommons.org/licenses/by-nc/4.0/>) which permits unrestricted non-commercial use, distribution, and reproduction in any medium, provided the original work is properly cited.

ABSTRACT

Introduction: Central neurocytomas (CNCs) appear as a rare benign intraventricular lesions involving <0.5% of primary brain tumors. There are no consensus guidelines for the optimal management strategy, so that this entity still enigmatic. **Aim:** This review aims to highpoint the entity of central neurocytoma in patients managed by our department and the unique surgical considerations, to review the epidemiology and demographics in patients treated in our institution. **Methods:** This retrospective analysis was conducted by reviewing tall patients managed at King Hussein Medical Center (KHMC) and their medical records. Patient reports were retrieved from the electronic hospital database for a 14-year period (2004 _ 2018). The review was permitted by the Royal Medical Services Institutional ethics committee. As this study was a retrospective chart review, the requirement for consent was waived. **Results:** Study revealed 33- patients who had Central neurocytoma as the underlying cause for admission. Of the final population 42.4% of the patients were males. Mean age at diagnosis was 29.48±9.78 years. Two cases were extra-ventricular, to cases were anaplastc. Only one patient developed recurrence. **Conclusion:** We have one the large series of Central neurocytomas in literature. They are benign and total resection is feasible. New adjuvant therapies are flourishing. Supplementary studies are required clarify the cardinal factors responsible for its pathogenesis; diagnosis; and to consolidate management approaches protocol.

Keywords: central neurocytoma; maximum safe resection; benign tumor; intraventricular; extra- ventricular neurocytoma.

1. INTRODUCTION

Central neurocytomas (CNCs) are a rare benign neuroectodermal, intraventricular tumors consisting 0.25–0.5% of primary brain lesions in young adults, commonly found in the supratentorial ventricles. Extra ventricular neurocytoma location is exceptionally rare [1-3]. According to the World Health Organization (WHO) 2016, Categorized as grade II [4]. Central neurocytomas even though are benign nevertheless recurrence can be perceived. Central neurocytomas mandates a surgical intervention with a gross-total resection which is modality of paramount currently. Anaplastic CNCs can be rarely seen [5, 6].

2. AIM

This review aims to highpoint the entity of central neurocytoma in pa-

tients managed by our department and the unique surgical considerations, additionally, to review the epidemiology and demographics in patients treated in our institution, also to highlight the new horizons of management flourishing nowadays.

3. PATIENTS AND METHODS

This retrospective analysis was carried out by reviewing all consecutive patients and their medical records in whom central neurocytoma had been diagnosed and managed at King Hussein medical center (KHMC). Patient's reports were retrieved from the electronic hospital database during a 14-year period (2004–2018). Diagnosis was based on clinical symptoms, radiological findings and confirmed by histopathological tests. All patients' data were recorded including the

	Age	Sex	Approach	Biopsy results	Resection extent
1	58 y	Male	Transcortical	WHO II with Anaplastic transformation	Subtotal - Conventional RXT
2	20 y	Female	Transcortical	WHO II	Gross Total Resection
3	30 y	Female	Transcallosal	WHO II	Gross Total Resection
4	31y	Female	Transcallosal	WHO II	Gross Total Resection
5	27y	Female	Transcallosal	WHO II	Gross Total Resection
6	27y	Male	Transcallosal	WHO II	Gross Total Resection
7	35y	Male	Posterior Fossa	Cerebellar liponeurocytoma	Gross Total Resection
8	40y	Female	Transcortical	WHO II with atypical features	Gross Total Resection
9	35y	Female	Transcallosal	WHO II	Gross Total Resection
10	18y	Female	Transcallosal	WHO II	Gross Total Resection
11	36y	Male	Transcallosal	WHO II	Gross Total Resection
12	43y	Male	Transcallosal	WHO II	Gross Total Resection
13	23y	Female	Transcortical	WHO II	Gross Total Resection
14	23y	Male	Transcallosal	WHO II	Gross Total Resection
15	22y	Female	Transcortical	WHO II	Gross Total Resection
16	23y	Male	Transcortical+	WHO II with atypical features	Gross Total Resection with RXT
17	21y	Female	Transcallosal	WHO II	Gross Total Resection
18	20y	Male	Transcortical	WHO II	Gross Total Resection
19	20y	Female	Transcortical	WHO II	Gross Total Resection
20	30y	Male	Transcortical	WHO II with atypical features	Subtotal - Conventional RXT
21	28y	Female	Transcallosal	WHO II	Gross Total Resection
22	23y	Male	Transcortical+	WHO II with atypical features	Subtotal – Conventional RXT
23	42y	Male	Transcortical	WHO II with atypical features	Subtotal – Conventional RXT
24	25y	Male	Transcortical	WHO II	Gross Total Resection
25	21y	Female	Transcortical	WHO II	Gross Total Resection
26	18y	Female	Transcortical	WHO II	Gross Total Resection
27	30y	Female	Transcallosal	WHO II with atypical features	Subtotal – Gamma Knife
28	31y	Female	Transcortical	WHO II with anaplastic transformation	Subtotal – Conventional RXT
29	23y	Female	Transcortical	WHO II	Gross Total Resection
30	32y	Female	Transcortical	WHO II Extraventricular	Gross Total Resection
31	24y	Male	Transcallosal	WHO II	Gross Total Resection
	27y	Male	Transcallosal	WHO II	Gross Total Resection
33	57y	Female	Transcortical	WHO II Extraventricular	Gross Total Resection

+ Patients underwent 2-stages surgery

Table. I: Demographic data analyzed

comprehensive history encompassing patient demographics (age and gender), presenting complaints, clinical and neurological findings, intraoperative findings, pre- and postoperative imaging, histopathological diagnosis and postoperative complications. The mean clinical follow up period was 57 months. One of two surgical approaches (transcortical and transcallosal) was utilized for accessing and resecting the tumors depending on the location, size and direction of extension of the tumor and regardless of the degree of ventricular dilatation. If the tumor was midline with no extension into the ventricular horns the transcallosal approach was used, while if the tumor was eccentrically placed or extended into a ventricular horn the transcortical approach was used. The study was approved by the Royal Medical Services Institutional ethics committee (6/3/2020). As this study is a retrospective chart analysis, hence the prerequisite for consent was waived.

4. RESULTS

Our cohort consisted of 33-adult patients operated for pathologically confirmed intracranial neurocytoma. Of the final population 42.42% of the patients were males, analysis revealed female to male ratio of 1.36:1. Mean age

at diagnosis was 29.48 ± 9.78 years, ranging from 18-58 years [Table.I]. The mean clinical follow up after clinical diagnosis was 57 months (ranging between 34-168 months). Tumor locations were intraventricular in 31 cases and only two case were extra-ventricular.

Clinically, most common presenting symptoms were headache and blurring of vision (90.91%) which were observed in 30-patients, papilledema was found in 20-patients (60.61%) and one patient presented with diplopia. No significant motor weakness was noted at presentation although many of the tumors were considerably large in size at presentation. Patients were scheduled for elective surgery within one week of presentation, one patient required ventricular shunt placement preoperatively due to the presence of severely dilated ventricles and decreased level of consciousness.

Approximately half of the cases were operated using a transcortical approach and the other half using a transcallosal approach, the decision of the approach was undertaken on the basis of location of the tumor from the midline and not based on dilation of ventricles as mentioned earlier. In 27-cases gross total resection was achieved, while in 6-cases only subtotal resection could be achieved. Study showed 25-cases with typical his-

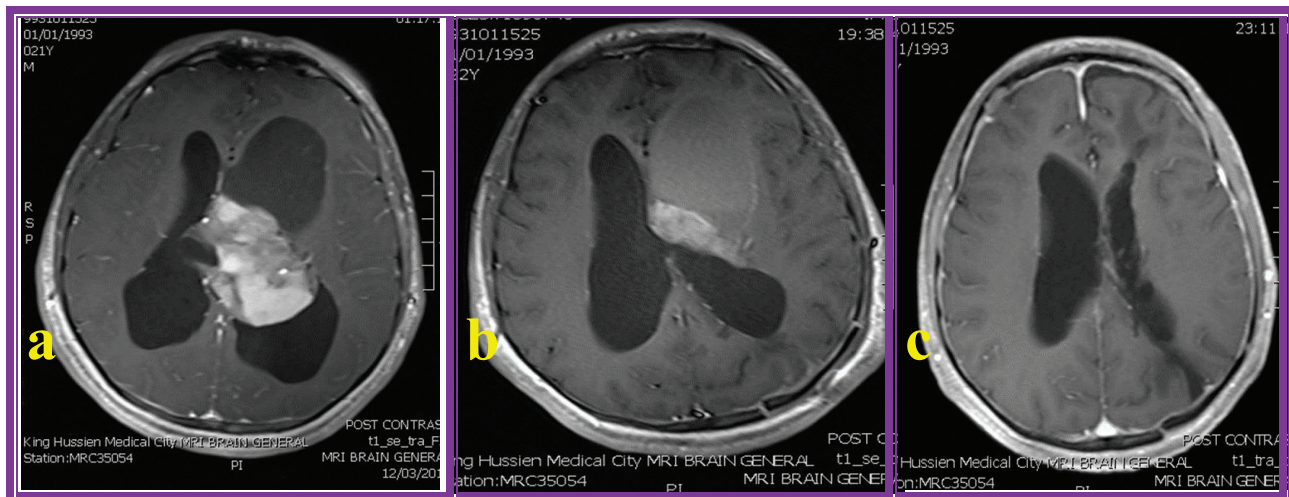


Figure.1: Radiological Images of a Patient underwent 2-stages surgery, a) Pre-operative images, b) Radiological images after the first surgery, c) Post-operative images after the second surgery.

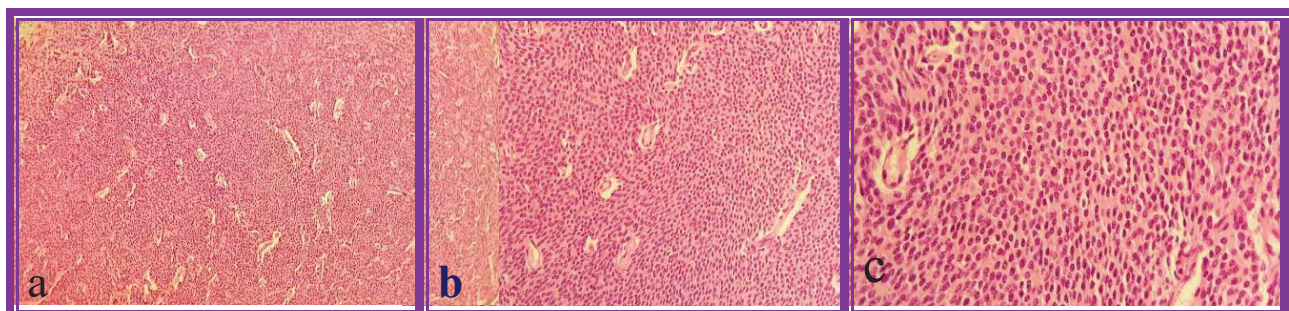


Figure.2: a-c from low to high power view, showing monotonous bland cells with modest cytoplasm, often empty appearing "halo" resembling oligodendroglioma, salt and pepper chromatin, embedded in eosinophilic fibrillar matrix with rare Homer Wright rosettes

topathological features and in 6- cases presented with atypical features, also 2-cases had anaplastic transformation. One case revealed a cerebellar central liponeurocytoma and one case was right frontal extra-ventricular. In two cases, intra-operative bleeding made the dissection difficult and the operations achieve maximal safe resection with postoperative follow up for growth in order to determine the need for a second stage operation. External ventricular drain was needed in twelve cases at the end of the operation due to excessive bleeding encountered intraoperatively and in order to avoid hydrocephalus, of the 12-cases with the external ventricular drainage only five cases needed a ventriculo-peritoneal shunt due to the presence of hydrocephalus after trial of external ventricular drainage closure. Six cases had atypical central neurocytomas, who after gross total resection received adjuvant radiotherapy. Only one patient developed recurrence. Two patients had 2-stages surgery (Fig.1)

5. DISCUSSION

Central neurocytomas are neuroectodermal tumors arising mainly from the septum pellucidum in the lateral ventricle, that originate from bi-potential progenitor cells in the periventricular matrix, where there are many stem or precursor cells in the sub-ependymal or sub-ventricular zone. Reports showed proofs for both glial and neuronal differentiation in many tumors [4, 7, 8]. Macroscopically central neurocytomas have a well

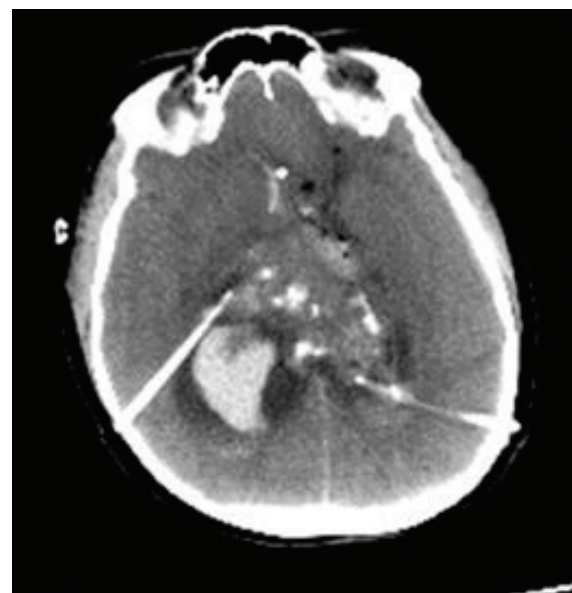


Figure.3: showing a brain CT scan for a patients presented with acute hydrocephalus, patient underwent bilateral ventriculo-peritoneal shunt insertion, then prepared for elective surgery.

circumscribed and demarcated border, a greyish lobulated nodular mass with highly vascularized regions and sometimes show areas of hemorrhage, the gritty feel experienced by surgeons is attributed to the presence of micro-calcifications. On light microscope the tumors typically consist of small to medium sized uniform neuronally differentiated and mitotically inactive cells with

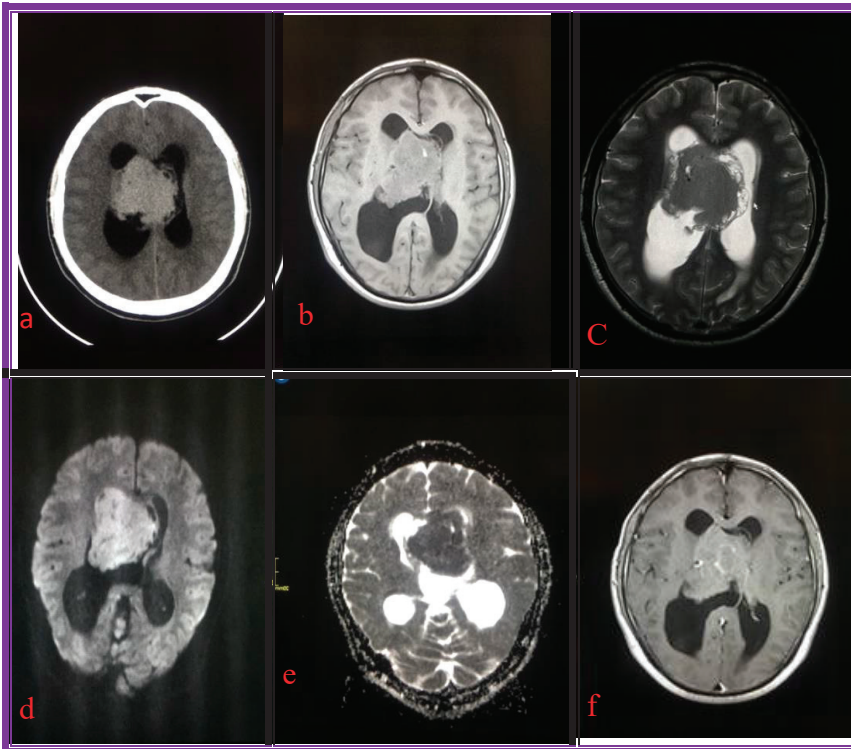


Figure.4: showing the radiological examination and findings in case of central neurocytoma: a) axial brain CT shows large hyper-dense soft tissue mass contains peripheral cystic consonants in the body of the RT lateral ventricle, the lesion shows no calcifications; b) axial T1 : the lesion appears isointense with central small hemorrhagic component, the lesion is attached to the septum pellucidum which appears bowed to the left side; c) axial T2 : heterogeneously isointense with peripheral cystic components giving the lesion bubbly appearance, the lesion contains small signal void peripherally. Significant dilatation of the lateral ventricle with minimal transependymal edema; d & e) diffusion study and ADC map shows mild restriction with low ADC value; f) axial T1 post contrast: mild hetero-geneous contrast enhancement. The lesion abuts the head of the RT caudated nucleus with no extra-ventricular extension.

round nuclei, stippled chromatin and inconspicuous nucleoli, scant cytoplasm intermingled with areas of anuclear and less dense fibrillary matrix, with polygonal cells and perinuclear “ halos” that resemble those seen in oligodendroglioma (Fig. 2), making oligodendrogliomas the main micro morphological differential diagnosis [9-11]. Thus, cultured cells could be subdivided into many types; a neuronal type with positive staining for filament proteins; secretory granules, with an undifferentiated cell type plus an increased nuclear-cytoplasm ratio; and astrocytic small round astrocytic cell with intermediate filaments that stain positive for GFAP 27. Importantly, IDH mutations and 1p19q co-deletion are absent –which are characteristic diagnostic parameters of oligodendrogliomas [12]. Central neurocytomas defined histopathologically ‘atypical’ when anaplastic features of increased mitotic activity, microvascular proliferation and necrosis observed, any central neurocytomas showing a Ki-67 proliferation index of ≥ 2 or 3% is reported atypical [9]. Increased rates of recurrence are associated with high mitotic count of ≥ 3 % [5, 13-15]. Our study revealed six cases of atypical CNCs.

Patients with central neurocytomas orig-

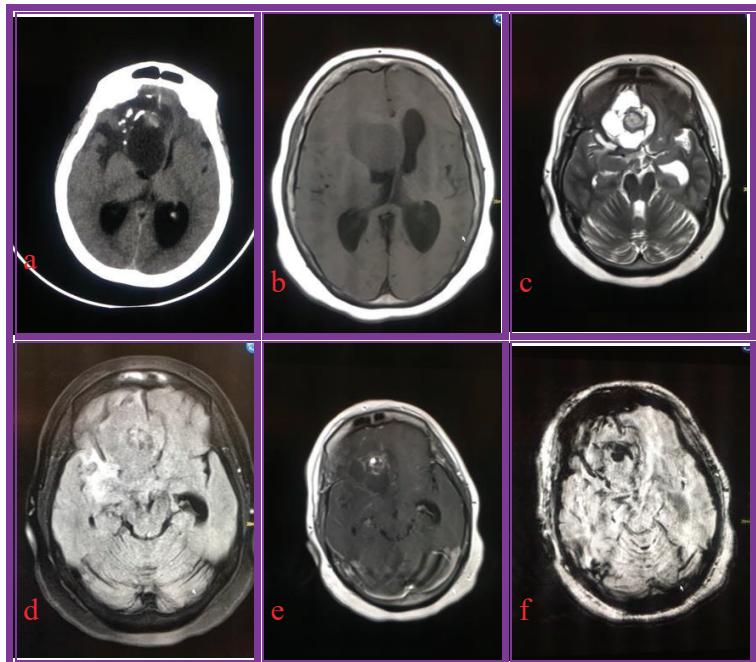


Figure.5: Showing a case of extra-ventricular neurocytoma: a) axial brain CT: Right inferior frontal cystic lesion with hyperdense hemorrhagic solid component centrally and peripheral calcifications mimicking oligodendroglioma; b) axial T1 precontrast: the intraparenchymal lesion appears hypointense compressing the frontal horn of the right lateral ventricle, with shift of midline structures to the left; c) Axial T2: heterogeneous hypointense small solid nodule surrounded by large cystic component; d) Axial FLAIR: The lesion is surrounded by moderate peritumoral vasogenic edema; e) SWI: blooming artefact in the central solid component suggestive of internal hemorrhage; f) T1 axial post contrast demonstrate heterogeneous mild enhancement in the solid component.

inate in the ventricular system or extra-ventricular present with clinical signs and symptoms that allied to one of two general classes: Those that result from the tumor mass effects, and those attributable to obstructive hydrocephalus. The presence of a mass in the region immediately neighboring the foramen of Monro results in increased intracranial pressure and compression on surrounding structures. However, the neurocytomas might found in an extra-ventricular location (cerebral, cerebellar, brainstem, or spinal parenchyma) with correlated clinical presentation. Radiologically, tumor appears on brain CT hypodense compared to white matter, with areas of punctate calcifications and cysts especially in the larger tumors, and rarely hemorrhage within it, post contrast shows mild-to-moderate contrast enhancement (Fig. 3). While, on magnetic resonance imaging, it appears heterogeneous and isointense to grey matter on T1WI with mild to moderate contrast enhancement. They are hyperintense on T2WI and FLAIR se-

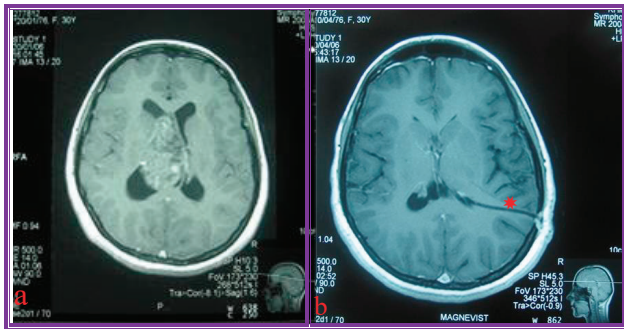


Figure.6: Showing the Axial cut for a patient underwent gross total resection of central neurocytoma, a) pre-operative image, b) post-operative image, demonstrating a V-P shunt applied for post-operative hydrocephalus.

quences with prominent flow voids and cystic areas that give central neurocytoma a bubbly appearance. Calcifications and hemorrhage could be identified on the GE/SWI sequences (Fig. 4). Strong choline peaks are evident on MR spectroscopy and some studies report the presence of a glycine peak [16]. In our review 30-cases presented with signs and symptoms of increased intracranial pressure, the other three cases discovered incidentally. Literature showed about 70% of affected individuals are between the age group of 20 and 40 years, No racial profile was identified and no gender predilection has been described, with a male-to-female ratio of 1.02:1[17]. In our analysis patients ages were between 18-years and 58-years, mean age at diagnosis was 29.48 ± 9.78 years. Also we identified 2-cases of extra-ventricular neurocytomas (Fig. 5). Of the final cohort 42.42% of the patients were males, with a female-to-male ratio of 1.36:1.

The pillar of central neurocytoma treatment is to achieve total and safe resection when feasible, which can be conducted either through the available approach: transcallosal or transcortical, however, the approach has to be tailored according to anatomy and severity of hydrocephalus. The profits and jeopardies of each approach such as postoperative seizures and neuropsychological consequences should be considered during decision-making [18]. According to our analysis twenty-seven patients underwent gross total resection (GTR) and six patients underwent subtotal resection (STR). The surgical corridors utilized to tackle CNs in this study included a transcortical approach in 18-cases and an inter-hemispheric transcallosal approach in 14-cases. There were no differences in terms of functional outcomes or initial extent of resection according to the surgical approach used. In terms of complications encountered; analysis showed Infection in 2-cases, transient Hemiparesis in 6-cases in which recovery achieved within 1 week – 6 months. Post-operative hydrocephalus managed in 5-cases by inserting a permanent ventriculo-peritoneal shunt (Fig. 6). While, behavioral changes and transient memory loss noticed in 3-cases and 7-cases respectively. Mortality reported in 2-cases. The literature advocate that the use of adjuvant radiotherapy in not indicated after gross total resection, however, it can be offered for residual/recurrent tumor, though it remains matter of controversy [1, 8, 14, 15, 18, 19]. In our center we follow the

same guidelines.

Central neurocytoma aggregate data after several reports in literature will continue to shape treatment paradigms. Central neurocytoma still enigmatic in many terms: origin, histopathological diagnosis and adjuvant therapies needed. The advances in molecular field; radiological advances and emerging chemotherapies in the evolving genomic landscape of cancer merits additional actionable therapeutic targets and further study.

6. CONCLUSION

Central neurocytoma is a rare benign neuroepithelial tumor of unknown cells of origin, that usually demonstrates in a relatively young population, increased intracranial pressure due to the slow increase in size of the tumor are the cardinal clinical presentation. The foremost treatment goal is to achieve early safe surgical excision of the tumor and the route of approach should be tailored according to the location of the tumor from midline and associated hydrocephalus, staged surgeries may be needed with different approaches utilized in very large tumors extending in the anteroposterior dimensions. External ventricular drainage is advocated post-operatively; especially if there was excessive bleeding into the ventricular system during removal of the tumor. Safe maximal resection is the rule and total resection showed promising results in establishing cure and preventing recurrence. Regular follow-up of the patient with imaging is needed to determine if there is recurrence in which case radiotherapy could be instituted if another surgery is not feasible to remove the recurrence or residual mass. The flourishing treatment modalities seem to be promising.

- **Ethical Approval:** We declare that this study has been approved by the Ethics Committee of Royal Medical Services (No. 6/3/2020).
- **Informed Consent:** Patient's informed consent was waived as this is a retrospective study.
- **Authors contribution:** Each author gave substantial contributions to the conception or design of the work in acquisition, analysis, or interpretation of data for the work. Each author had a part in article preparing for drafting or revising it critically for important intellectual content, and each author gave final approval of the version to be published and agreed to be accountable for all aspects of the work in ensuring that questions related to the accuracy or integrity of any part of the work are appropriately investigated and resolved.
- **Conflict of Interest Statement:** The authors declare that the research was conducted in the absence of any commercial or financial relationships that could be construed as a potential conflict of interest.
- **Conflicts of Interest Disclosure:** The authors declare that they have no conflicts of interest.
- **Financial support and sponsorship:** The authors has no relevant funding to disclose.

REFERENCES

1. Mahavadi AK, Patel PM, Kuchakulla M, Shah AH, Eichberg D, Luther EM, et al. Central Neurocytoma Treatment Modalities: A Systematic Review Assessing the Outcomes of Combined Maximal Safe Resection (MSR) and Radiotherapy with Gross Total Resection. *World neurosurgery*. 2020; S1878-8750(20)30132-7.

2. Wu L, Deng X, Yang C, Zhao L, Yang T, Xu Y. Primary spinal neurocytoma involving the medulla oblongata: two case reports and a literature review. *Neurologia Medico-chirurgica*. 2014; 54(5): 417-422.
3. Hassoun J, Gambarelli D, Grisoli F, Pellet W, Salamon G, Pellissier JF, Toga M. Central neurocytoma. An electron-microscopic study of two cases. *Acta Neuropathol*. 1982; 56: 151-156.
4. Komura S, Akiyama Y, Suzuki H, Yokoyama R, Mikami T, Mikuni N. Far-anterior Interhemispheric Transcallosal Approach for a Central Neurocytoma in the Lateral Ventricle. *Neurologia Medico-chirurgica*. 2019; 59(12): 511-516.
5. Vasiljevic A, François P, Loundou A, et al.: Prognostic factors in central neurocytomas: a multicenter study of 71 cases. *Am J Surg Pathol*. 2012; 36: 220-227.
6. Rades D, Fehlaue F, Lamszus K, et al.: Well-differentiated neurocytoma: what is the best available treatment? *Neuro Oncol*. 2005; 7: 77-83.
7. Von Deimling A, Kleihues P, Saremaslani P, et al.: Histogenesis and differentiation potential of central neurocytomas. *Lab Invest*. 1991; 64: 585-591.
8. Qian H, Lin S, Zhang M, Cao Y. Surgical management of intraventricular central neurocytoma: 92 cases. *Acta Neurochir (Wien)*. 2012; 154: 1951-1960.
9. Smith A, Smirniotopoulos J, Horkanyne-Szakaly I. From the Radiologic Pathology Archives: Intraventricular Neoplasms: Radiologic-Pathologic Correlation. *Radiographics*. 2013; 33(1): 21-43.
10. Li Y, Ye XF, Qian G, Yin Y, Pan QG. Pathologic features and clinical outcome of central neurocytoma: analysis of 15 cases. *Chin J Cancer Res*. 2012; 24(4): 284-290.
11. Choudhari KA, Kaliaperumal C, Jain A, Sarkar C, Soo M, Rades D, Singh J. Central neurocytoma: A multi-disciplinary review. *British Journal of Neurosurgery*. 2009; 23(6): 585-595.
12. Schild SE, Scheithauer BW, Haddock MG, Schiff D, Burger PC, Wong WW, et al. Central neurocytomas. *Cancer*. 1997; 79:790-795.
13. Louis DN, Perry A, Reifenberger G. et al. The 2016 World Health Organization Classification of tumors of the central nervous system: a summary. *Acta Neuropathol*. 2016; 131(6): 803-820.
14. Leenstra J, Rodriguez FJ, Frechette CM. et al. Central neurocytoma: management recommendations based on a 35-year experience. *Int J Radiat Oncol Biol Phys*. 2007; 67(4): 1145-1154.
15. Johnson MO, Kirkpatrick JP, Patel MP, Desjardins A, Randazzo DM, Friedman HS, et al. The role of chemotherapy in the treatment of central neurocytoma. *CNS oncology*. 2019; 8(3): Cns41.
16. Chen CL, Shen CC, Wang J, Lu CH, Lee HT. Central neurocytoma: A clinical, radiological and pathological study of nine cases. *Clin Neurol Neurosurg*. 2008; 110:129-136.
17. Chandshah MI, Sadashiva N, Konar S, Devi BI. Central Neurocytoma Presenting with Bleed and Obstructive Hydrocephalus: A Rare Presentation. *Asian journal of neurosurgery*. 2019; 14(3): 919-921.
18. Barani IJ, Raleigh DR, Larson D. The management of central neurocytoma: Radiotherapy. *Neurosurg Clin N Am*. 2015; 26: 45-56.
19. Wang M, Zhou P, Zhang S, Liu X, Lv L, Wang Z, et al. Clinical Features, Treatment, and Long-term Outcomes of Central Neurocytoma: A 20-Year Experience at a Single Center. *World neurosurgery*. 2018; 109: e59-e66.