

# Indication for hypertrophy posterior longitudinal ligament removal in anterior decompression for cervical spondylotic myelopathy

Chengrui Bai, MD<sup>a</sup>, Kanghua Li, MD<sup>b</sup>, Ai Guo, MD<sup>a</sup>, Qi Fei, MD<sup>a</sup>, Dong Li, MD<sup>a</sup>, Jinjun Li, MD<sup>a</sup>, Bingqiang Wang, MD<sup>a,\*</sup>, Yong Yang, MD<sup>a,\*</sup>

## Abstract

The retrospective study aimed to investigate the indication for hypertrophy posterior longitudinal ligament (HPLL) removal in anterior decompression for cervical spondylotic myelopathy (CSM). A total of 138 consecutive patients with CSM were divided into 2 groups with developmental cervical stenosis (DCS) (group S) and non-DCS (group N), according to the Pavlov ratio. These 2 groups were subdivided into 2 further subgroups, according to whether HPLL was removed or preserved: group SR (49 patients) and group SP (32 patients) in group S, group NR (21 patients) and group NP (36 patients) in group N. The modified Japanese Orthopedic Association score (mJOA), the modified recovery rate (mRR), quality of life (QoL), and relevant clinical data were used for clinical and radiological evaluation. The mJOA scores improved from  $7.3 \pm 2.2$  to  $15.0 \pm 1.8$  in the SR group and from  $7.9 \pm 2.3$  to  $14.2 \pm 1.5$  in the SP group ( $P = .036$ ), with postoperative QoL significantly higher in the SR group than the SP group. A reduction in the diameter of enlarged spinal canals occurred at a significantly faster rate in the SP group compared with the SR group ( $P = .002$ ). Multivariate regression analyses showed removal of HPLL correlated with mJOA scores (coefficient = 7.337,  $P = .002$ ), mRR (%) (coefficient = 9.117,  $P = .005$ ), PCS (coefficient = 12.129,  $P < .001$ ), and MCS (coefficient = 14.31,  $P < .001$ ) in the S group at 24 months postoperatively, while removal of HPLL did not correlate with clinical outcomes in the N group. The HPLL should, therefore, be removed when mobility was reduced and the spinal cord remained compressed after anterior decompression procedures in the patients with DCS. However, in non-DCS patients, it remains unclear as to whether removal of HPLL provides any clinical benefit, thus, HPLL removal may not be necessary.

**Abbreviations:** ACDF = anterior cervical discectomy and fusion, CSF = cerebrospinal fluid, CSM = cervical spondylotic myelopathy, DCS = developmental cervical stenosis, HPLL = hypertrophy posterior longitudinal ligament, MCS = mental component summary, mJOA = modified Japanese Orthopedic Association score, MRI = magnetic resonance imaging, mRR = modified recovery rate, PCS = physical component summary, QoL = quality of life.

**Keywords:** developmental cervical stenosis, hypertrophy posterior longitudinal ligament, Pavlov ratio, quality of life

## 1. Introduction

Anterior cervical discectomy and fusion (ACDF), described by Cloward in 1958,<sup>[1]</sup> is the most commonly utilized technique for the treatment of compressive cervical myelo-radiculopathy. Since

Editor: Bernhard Schaller.

BW and YY contributed equally to this work and considered co-corresponding authors.

**Ethics statement:** The study protocol was approved by our institution's ethics committee, and written informed consent was obtained from all participating patients.

The authors have no funding and conflicts of interest to disclose.

<sup>a</sup> Department of Orthopedics, Beijing Friendship Hospital Affiliated of Capital Medical University, Beijing, <sup>b</sup> Department of Orthopedics, Xiangya Hospital, Central South University, Changsha, China.

\* Correspondence: Yong Yang and Bingqiang Wang, Department of Orthopedics, Beijing Friendship Hospital Affiliated of Capital Medical University Beijing, 95 Yong'an Rd, Beijing 100050, China (e-mails: spineyangyong@sina.com, finewangbq@sina.com [YY] and finewangbq@sina.com [BW]).

Copyright © 2017 the Author(s). Published by Wolters Kluwer Health, Inc. This is an open access article distributed under the terms of the Creative Commons Attribution-Non Commercial License 4.0 (CCBY-NC), where it is permissible to download, share, remix, transform, and buildup the work provided it is properly cited. The work cannot be used commercially without permission from the journal.

Medicine (2017) 96:23(e7043)

Received: 12 February 2017 / Received in final form: 5 May 2017 / Accepted: 8 May 2017

<http://dx.doi.org/10.1097/MD.0000000000007043>

the initial application of this procedure, ACDF has been increasingly applied for the treatment of cervical spinal disorders following improvements in surgical techniques and instrumentation. However, controversy still exists as to whether hypertrophy posterior longitudinal ligaments (HPLLs) should be removed or preserved in ACDF procedures.<sup>[2]</sup> This debate has primarily arisen due to differences in management and that posterior longitudinal ligaments (PLL) are associated with complications in some patients. Specifically, the specific clinical indications for HPLL removal are still unknown during ACDF procedures. To date, studies are limited regarding the indication for the removal of HPLL in ACDF procedures for cervical spondylotic myelopathy (CSM) in patients with developmental cervical stenosis (DCS) or without DCS, which indicates congenital cervical vertebral canal stenosis. Therefore, in our retrospective study, the clinical and radiological outcomes of patients who underwent HPLL preservation were compared with patients with HPLL removal in order to elucidate the clinical indications for removal during ACDF procedures and to provide a standardized protocol based on HPLL mobility.

## 2. Methods

### 2.1. Participants

During the period between June 2009 and March 2013, a total of 159 consecutive patients with confirmed HPLL (1–2 levels) who underwent ACDF for CSM were selected and included in our

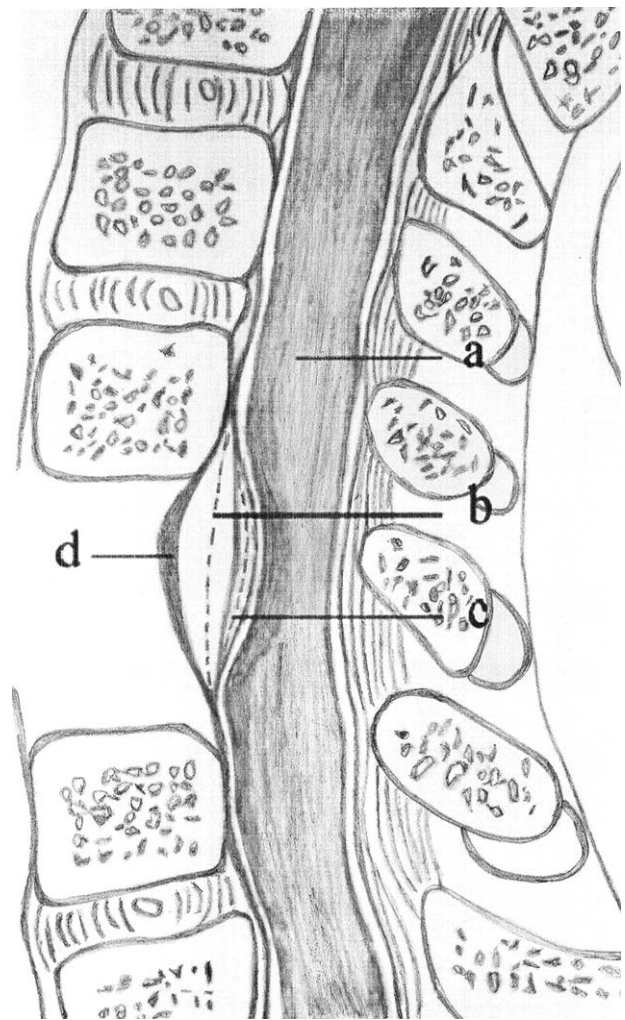
study. In our study, HPLL was defined as the abnormal thickening of PLL greater than 3.5mm and less than 5mm without any ossified or calcified fragments. The presence of thickened HPLL was confirmed by T2-weighted magnetic resonance imaging (MRI) scanning, demonstrating the presence of compressed segmental epidural bursa that is composed of dura mater, spinal cord, and cerebrospinal fluid (CSF). The exclusion criteria were as follows: patients with spondylosis, amyotrophy, tumors, rheumatoid arthritis, pyogenic spondylitis and comorbidities, central nerve system disorders, peripheral neuropathy, known psychiatric illnesses, ligamentum flavum hypertrophy or facet hypertrophy, ossification of posterior longitudinal ligament or calcification of posterior longitudinal ligament, and a history of previous cervical spine surgery or injury; patients with a spinal cord compressing rate greater than 30% measured by MRI according to the Takahashi classification system.<sup>[3]</sup>

We set criteria for DCS patients, defined as a Pavlov ratio<sup>[4,5]</sup>  $<0.75$ . The Pavlov ratio was defined as the ratio between the sagittal diameter of spinal canal and the diameter of the vertebral body in the same segment measured in T2-weighted MRI scanning.<sup>[5,6]</sup> According to the aforementioned criteria, the patients were divided into 2 groups accordingly: DCS (group S) and non-DCS (group N). In anterior decompression procedures based on the mobility of HPLL, the 2 groups of patients were subdivided into 2 further subgroups according to whether the HPLL was removed or retained, which was detected under the operating microscope and head lamp. By the judgment of the relative position between the HPLL and adjacent upper and lower vertebral posterior edge attachment line, we made a decision to remove or preserve the PLL: if the HPLL showed insufficient mobility and the spinal cord remained compressed by the HPLL after decompression procedures behind the adjacent upper and lower vertebral posterior edge attachment line, then the HPLL was removed. Otherwise, the HPLL was preserved, as shown in Fig. 1. A total of 21 patients (13.2%) were lost to follow-up (9 due to noncompliance, 7 due to relocation, and 5 due to unknown whereabouts). Follow-up information was available for 138 out of the 159 patients (86.8%). Consequently, patients included were divided into 4 groups: group SR (HPLL removal  $n=49$ , 32 males, 17 females,  $58.4 \pm 9.5$  years), group SP (HPLL preserved  $n=32$ , 20 males, 12 females,  $54.8 \pm 8.2$  years) (Table 1), group NR (HPLL removal  $n=21$ , 13 males, 8 females,  $61.5 \pm 11.8$  years), and group NP (HPLL preserved  $n=36$ , 18 males, 18 females,  $58.8 \pm 11.0$  years) (Table 1). The data of clinical demographics showed that there were no statistical differences ( $P > .05$ ) between group SR and group SP, and group NR and group NP (Table 1).

The study protocol was approved by our institution's ethics committee, and written informed consent was obtained from all participating patients.

## 2.2. Surgical procedures

All operations were performed by the same senior orthopedic surgeon in our spinal surgery department. ACDF procedures for CSM was performed as described in previous studies.<sup>[7,8]</sup> In order to expose the involved HPLL, we approached the procedure from a standard right-side anterior approach and removed any pathological structures, including degenerated discs, herniated intervertebral nuclei, and proliferative osteophytes. In the removal group, the HPLL was separated from the dura mater and meticulously resected. In the preserved group, the HPLL was preserved without specific management. The spinal cord was free



**Figure 1.** (A) Spinal cord, (B) adjacent upper and lower vertebral posterior edge attachment line. (C) If the hypertrophy posterior longitudinal ligament (HPLL) was still located behind the adjacent upper and lower vertebral posterior edge attachment line after decompression, and the spinal cord was still compressed by the HPLL, the ligament was removed. (D) If the ligament was sufficiently mobile to reach the front of the line, the spinal cord was free of compression, it was retained.

of compression after the procedures in all patients. During the discectomy procedure, the cartilage endplates were removed with curettage, and avoiding any additional damage to the endplate. The Caspar distractor was placed between adjacent vertebral bodies to perform distraction approximately 2 to 3 mm. A trial spacer was used to determine the appropriate implant size and type; a suitable polyether-ether-ketone cage (Medtronic Sofamor Danek USA Inc., Memphis, TN) packed with autologous local bone pieces taken from the operation site was placed safely into the intervertebral space. After implantation of the cage, a Caspar distractor was released. A titanium Codman plate (Johnson & Johnson) or zephir plate (Medtronic Sofamor Danek) or Orion plate (Medtronic Sofamor Danek) (Fig. 2) was fixed onto the adjacent vertebrae with screws. Postoperatively, the patients were allowed to mobilize with a soft neck collar after bed rest for several days. Collar supports were removed after 4 to 6 weeks in all patients. All patients were followed up at 1, 6, 12, 24 months postoperatively.

**Table 1****The demographics and operation data of group SR, SP, NR, and NP.**

Variable	Group SR (n=49)	Group SP (n=32)	P	Group NR (n=21)	Group NP (n=36)	P
Age, y	58.4±9.5	54.8±8.2	.069	61.5±11.8	58.8±11.0	.385
Gender (n, %)			.797			.384
Male	32 (65.3%)	20 (62.5%)		13 (61.9%)	18 (50.0%)	
Female	17 (34.7%)	12 (37.5%)		8 (38.1%)	18 (50.0%)	
Mean CR, %	23.6±5.0	21.7±6.3	.129	15.9±6.1	18.2±6.2	.169
Pavlov ratio	0.68±0.05	0.67±0.05	.311	0.85±0.07	0.86±0.11	.615
Mean duration of symptoms, mo	17.7±13.8	17.4±11.8	.917	23.0±13.1	24.0±13.9	.784
Operative segment (C4–C7)			.627			.890
Single segment	39 (79.6%)	24 (75.0%)		16 (76.2%)	28 (77.8%)	
Double segment	10 (20.4%)	8 (25.0%)		5 (23.8%)	8 (22.2%)	
Symptoms of radiculopathy	7 (14.3%)	4 (12.5%)	.974	4 (19.0%)	5 (13.9%)	.806
Symptoms of myelopathy	30 (61.2%)	20 (62.5%)		13 (61.9%)	22 (61.1%)	
Combined symptoms	12 (24.5%)	8 (25.0%)		4 (19.0%)	9 (25.0%)	
Plate type			.697			.804
Codman plate	23 (46.9%)	18 (56.3%)		11 (52.4%)	22 (61.1%)	
Zephir plate	12 (24.5%)	7 (21.9%)		4 (19.0%)	6 (16.7%)	
Orion plate	14 (28.6%)	7 (21.9%)		6 (28.6%)	8 (22.2%)	
Mean operating time, min	192.4±27.2	181.8±24.3	.073	195.7±15.5	187.6±25.8	.195
Mean bleeding, mL	382.5±73.9	367.1±84.8	.405	383.3±98.9	376.1±77.3	.760
Bone union						
3 mo	45 (91.8%)	29 (90.6%)	.850	17 (81.0%)	33 (91.7%)	.234
6 mo	46 (93.9%)	32 (100%)	.154	20 (95.2%)	34 (94.4%)	.897
12 mo	49 (100%)	32 (100%)	–	21 (100%)	36 (100%)	–

Group SR, HPLL removal group in developmental canal stenosis group; group SP, HPLL preservation group in developmental canal stenosis group; group NR, HPLL removal group in nondevelopmental canal stenosis group; group NP, HPLL preservation group in nondevelopmental canal stenosis group. Pavlov ratio, the sagittal diameter of the spinal canal/the sagittal diameter of the vertebral body on lateral X-rays. CR=the compressing rate of spinal cord, HPLL=hypertrophy posterior longitudinal ligament.

### 2.3. Clinical and radiological evaluation

Neurological function was evaluated using the Modified Japanese Orthopedic Association Cervical Spine Myelopathy Functional Assessment Scale, as described by Benzel et al.<sup>[9,10]</sup> The modified recovery rate (mRR) was calculated using the same formula as that applied for the original Japanese Orthopedic Association (JOA), changing the cumulative score from 17 to 18.<sup>[9,10]</sup>

$$\text{mRR}(\%) = \frac{\text{postoperative mJOA score} - \text{preoperative mJOA score}}{18 - \text{preoperative mJOA score}} \times 100\%$$

The Medical Outcomes Study 36-item short-form health survey with the score ranging from 0 to 100, including physical component summary (PCS) measure, mental component summary (MCS) measure,<sup>[11,12]</sup> was used for the assessment of the quality of life (QoL), with higher scores representing improved health. The Medical Outcomes Study 36-item short-form health survey is a health status questionnaire that was developed 2 decades ago to assess functional status and well-being,<sup>[11]</sup> which has since been applied in a variety of clinical settings.<sup>[13–15]</sup> The mean operating time, blood loss, and any associated complications were also evaluated and compared between groups. Radiological examinations (MRI, CT, and X-rays) were performed preoperatively. X-rays were performed every 3 months, and MRI and CT scans were performed every 12 months postoperatively for all patients. To determine intra- and interobserver variability, radiological measurements were carried out by 2 senior radiologists, who performed radiological evaluations independently for each patient. The anteroposterior median sagittal diameter of the cervical spinal canal was measured at the most stenotic operating vertebral level (Fig. 3) on sagittal T2-weighted MRI.<sup>[16]</sup> Bone fusion was defined when the following criteria were satisfied: no movement between the spinous processes; absence of a radiolucent gap between the graft

and the endplate; and presence of continuous bridging bony trabeculae across the graft-endplate interface (Fig. 4).

### 2.4. Statistical analysis

Data were expressed as means±standard deviation (SD) for quantitative variables. Qualitative data are represented as relative percentages. The Student *t* test and chi-square test were used for comparison of clinical and radiological data. Multivariate regression was used to analyze the clinical outcome effects of any independent variables. Multivariate regression was adjusted for age, gender, spinal cord compressing rate, mean duration of symptoms, pre- and postoperative sagittal diameter, pre- and postoperative modified Japanese Orthopedic Association score (mJOA), pre- and postoperative PCS, pre- and postoperative MCS, and surgical method (HPLL removing=1; HPLL retaining=0).<sup>[17]</sup> A *P*-value less than 0.05 (*P*<.05) was considered statistically significant. Statistical analysis was performed using SPSS statistical software package 15.0 for Windows (SPSS Inc., Chicago, IL).

## 3. Results

### 3.1. Clinical and radiological outcomes

The 138 patients were followed up for more than 24 months, and no deaths occurred in either group. The mJOA scores improved from 7.3±2.2 to 15.0±1.8 in the SR group and increased from 7.9±2.3 to 14.2±1.5 in the SP group (*P*=.036). Furthermore, an increase from 6.8±1.8 to 14.3±2.0 was observed in the NR group, and an increase from 7.4±2.1 to 13.5±1.4 in the NP group (*P*=.104). The mRR (%) between groups was significantly different (71.7±13.7 in SR vs 64.1±12.9 in SP, *P*=.014) and (64.3±13.3 in NR vs 58.6±12.2 in NP, *P*=.110). QoL including MCS and PCS in SR group was significantly higher than that in





**Figure 2.** Three different titanium anterior cervical fixing system. (A) Codman plate, (B) Zephir plate, and (C) Orion plate.

the SP group, but no significant difference was found between the NR and NP groups (Table 2).

Radiological examination showed that the sagittal median diameter of the cervical spinal canal in the SR group was significantly wider than that in the SP group ( $P=.002$ ) and no significant difference was found between the NR and NP groups ( $P=.151$ ). Reduction in the postoperative spinal canal diameter occurred at a significantly faster rate in the SP group when compared with the SR group ( $P=.002$ ). No significant difference was found in postoperative canal size between the NR and NP groups ( $P=.157$ ) (Table 2). There were no significant differences between groups in terms of operating time, bleeding, bone graft union, and complications (Tables 1 and 2).

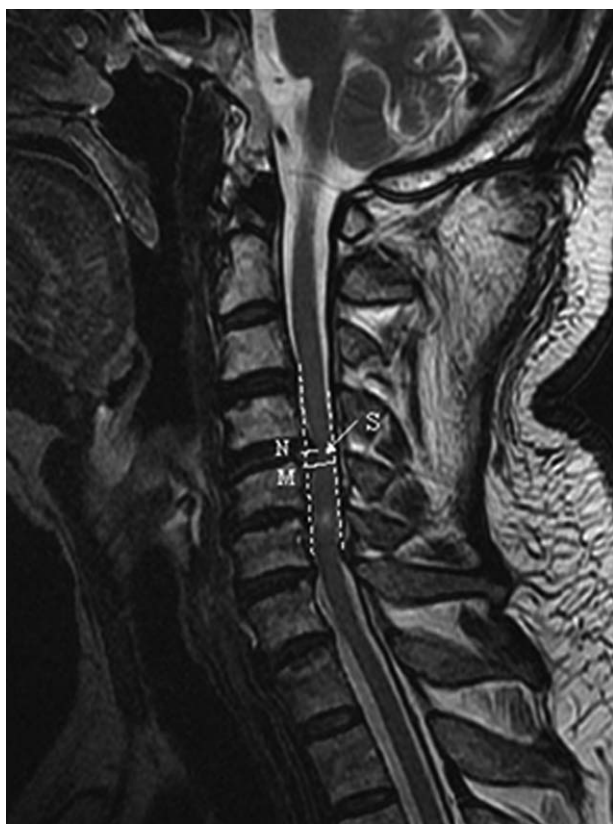In multivariable regression analyses, after multivariable adjustment for other covariates mentioned above in DCS patients, removal of HPLL also correlated with improvements in mJOA scores (coefficient=7.337,  $P=.002$ ), mRR (%) (coefficient=9.117,  $P=.005$ ), PCS (coefficient=12.129,  $P<.001$ ), and MCS (coefficient=14.31,  $P<.001$ ) (Tables 3–6) at 24 months postoperatively. However, removal of HPLL did not correlate with clinical outcomes at 24 months in non-DCS patients.

### 3.2. Intraoperative and postoperative complications

No spinal cord injuries occurred in either group. Hoarseness, dysphagia, wound infection, and epidural hematomas were found in 4 groups and were managed conservatively. Cervical instability and displacement of grafts and steel fixators were also present in some patients, which were treated conservatively with immobilization, neck collars, and orthoses. Seven cases in DCS patients and 5 cases in non-DCS patients demonstrated transient postoperative shoulder muscle weakness. No neurological deterioration developed in participants in our study and 3 patients developed CSF leakage in the SR and NR groups. This was accounted for due to significant adherence between HPLL and dura mater, resulting in damage to the latter during surgery. CSF leakage was treated conservatively. No statistical significance was found in the incidence of complications between groups (Table 2).

### 4. Discussion

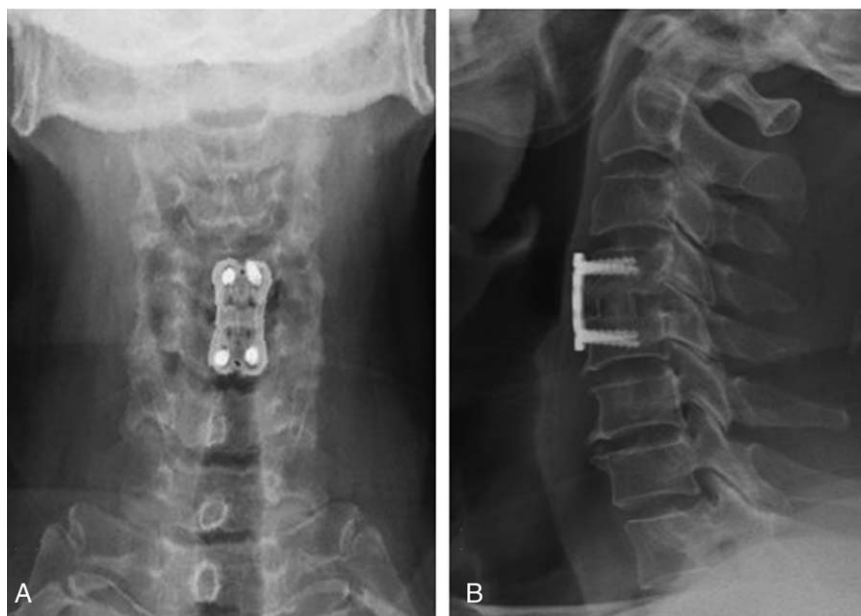
Although anterior decompression is a common and widely accepted surgical technique for cervical myelo-radiculopathy, it is still difficult to determine whether HPLL should be removed during ACDF procedures for CSM.<sup>[18]</sup> Some studies have



**Figure 3.** The definition and measurement of spinal cord compression. The compressing rate (CR) was defined as the thickness of the condensed spinal cord (N) divided by the anteroposterior diameter of the spinal cord (M) on the sagittal image on magnetic resonance imaging T2-weighted scanning preoperatively.  $CR = N/M \times 100\%$ . The CR and anteroposterior sagittal diameter of the spinal canal was measured at the most stenotic part of the spinal cord (S) on magnetic resonance imaging T2-weighted scanning.

reported that the PLL is fundamental in protecting the spinal cord and stabilizing the cervical spine.<sup>[2,19]</sup> However, Loughenbury et al<sup>[20]</sup> and Chen et al<sup>[21]</sup> demonstrated that the PLL also prevents protrusion of disc tissue into the spinal canal. PLL removal may lead to instability of the cervical spine and increase the risk of damage to the anatomical components of the cervical canal including the dura mater, spinal cord, nerve roots, and epidural vascular plexus.<sup>[12]</sup> Nevertheless, a clinical study conducted by Bai et al<sup>[17]</sup> has described the benefit of degenerative PLL removal in ACDF procedures for CSM. However, no definite indication was identified. Therefore, our study sought to identify the clinical indication for HPLL removal and to provide standardized removal in advance, based on HPLL mobility detected in ACDF for CSM patients.

The results of our study revealed that HPLL removal may not markedly influence cervical spine stability, bone graft union and the incidence of graft, and internal fixation displacement both in DCS and non-DCS patients (Table 2). However, postoperative reduction in spinal canal diameter in the group SP was significantly faster than that in the group SR in DCS patients, which may reduce the long-term beneficial therapeutic effects of anterior decompression. However, no significant difference was found between the NR and NP groups in non-DCS patients (Table 2). Similarly, our data from DCS patients demonstrated that postoperative mJOA scores and neurological mRR scores in the SR group were significantly higher than those found in the SP group. These findings were in accordance with previously published studies.<sup>[18,22]</sup> Sagittal T2-weighted MRI scans showed that the mean median sagittal diameter of the cervical spinal canal was significantly wider in the SR group compared with the SP group. These results indicated that decompression was more effective after removal of HPLL in DCS patients. Improved mJOA and mRR (Table 2) scores may have resulted from complete removal of HPLL. Compared with DCS patients, no significance was found in postoperative mJOA scores, neurological mRR scores, and the mean median sagittal diameter of the



**Figure 4.** The postoperative X-ray image of internal fixing plate system. (A) Postoperative A/P X-ray image. (B) Postoperative lateral X-ray image. The presence of bridging bony trabeculae at the graft-endplate interface, the radiolucent gap between the graft and the endplate, and the motion between the spinous processes found in postoperative X-ray figure can be used to evaluate the bone fusion condition.

**Table 2****The imaging, mJOA, SF-36, and complications of group SR, SP, NR, and NP.**

Variable	Group SR (n=49)	Group SP (n=32)	P	Group NR (n=21)	Group NP (n=36)	P
Sagittal diameter of the canal, mm						
Preoperative	8.20±1.44	8.31±1.39	.729	8.05±1.34	8.35±1.11	.382
Postoperative 24th, mo	12.15±1.10	11.32±1.21	.002	11.85±1.42	11.31±1.33	.151
Sagittal diameter decrease (%) than postoperative 12th, mo	8.63±4.18	10.84±3.98	.002	7.43±2.58	8.42±2.47	.157
mJOA						
Preoperative	7.3±2.2	7.9±2.3	.212	6.8±1.8	7.4±2.1	.291
Postoperative 24th, mo	15.0±1.8	14.2±1.5	.036	14.3±2.0	13.5±1.4	.104
mRR	71.7±13.7	64.1±12.9	.014	64.3±13.3	58.6±12.2	.110
SF-36 (PCS, MCS)						
PCS preoperative	40.4±3.2	41.0±2.9	.376	41.0±4.1	41.3±3.2	.751
PCS postoperative 24th, mo	70.3±4.8	64.8±9.1	.001	66.5±8.6	69.7±5.5	.095
MCS preoperative	40.1±3.0	39.5±3.2	.425	39.1±1.6	40.5±3.3	.072
MCS postoperative 24th, mo	68.6±7.1	64.5±10.3	.039	72.6±5.2	70.1±6.4	.148
Complications						
Dural tearing and CSF leakage	2 (4.1%)	0 (0%)	.247	1 (4.8%)	0 (0%)	.187
Transient muscle weakness (C5palsy)	4 (8.2%)	3 (9.4%)	.850	2 (9.5%)	3 (8.3%)	.878
Adjacent disc degeneration	7 (14.3%)	5 (15.6%)	.868	3 (14.3%)	6 (16.7%)	.812
Cervical instability	3 (6.1%)	2 (6.3%)	.981	1 (4.8%)	3 (8.3%)	.611
Graft and steel displacement	2 (4.1%)	3 (9.4%)	.333	1 (4.8%)	0 (0%)	.187
Hoarseness	3 (6.1%)	2 (6.3%)	.981	2 (9.5%)	2 (5.6%)	.572
Dysphagia	3 (6.1%)	1 (3.1%)	.543	1 (4.8%)	2 (5.6%)	.897
Infection	3 (6.1%)	1 (3.1%)	.543	2 (9.5%)	1 (2.8%)	.271
Epidural hematoma	2 (4.1%)	0 (0%)	.247	0 (0%)	1 (2.8%)	.441

Group SR, HPLL removal group in developmental canal stenosis group; group SP, HPLL preservation group in developmental canal stenosis group; group NR, HPLL removal group in nondevelopmental canal stenosis group; group NP, HPLL preservation group in nondevelopmental canal stenosis group. HPLL=hypertrophy posterior longitudinal ligament, MCS=mental component summary, PCS=physical component summary, mJOA=modified Japanese Orthopedic Association score, mRR=the modified recovery rate, SF-36=Medical Outcomes Study 36-item short-form health survey.

cervical spinal canal between the NR and NP groups at postoperative 24-month follow-up in non-DCS patients. In conclusion, mJOA and mRR scores, as well as the cervical spinal canal, did not benefit from removal of the HPLL in non-DCS patients (Table 2).

Postoperative recovery following ACDF procedures is affected by the presence of DCS.<sup>[23]</sup> In our study, diagnosis of DCS was based on the Pavlov ratio, which is a reliable determinant, instead of the true diameter of the cervical spinal canal.<sup>[24]</sup> A Pavlov ratio value less than 0.75 indicates cervical canal stenosis.<sup>[4,5]</sup> After multivariate adjustment for other covariates in DCS patients, removal of HPLL also correlated with higher mJOA scores, mRR and improved PCS and MCS ( $P < .05$ ) representing an improved QoL. These findings suggest that HPLL removal correlated with positive clinical outcomes in DCS patients (Tables 3–6) at 24-month follow-up. However, removal of HPLL did not correlate with outcomes in non-DCS patients, which indicated that the removal of HPLL did not influence mJOA and mRR scores or PCS and MCS at 24-month follow-up.

Although no significant differences in terms of blood loss and operating time were observed between groups, HPLL removing

procedures required more complicated techniques. Determining HPLL mobility after discectomy was important and required careful detection and surgical experience. The safety of removal procedures depends on low traumatic manipulation of the spinal cord and protection of the dura mater, nerve structures, and epidural vascular plexus.<sup>[18]</sup> The dura mater can adhere to the thickest portion of the HPLL in many patients, and the procedure to separate the HPLL from the dura mater should be performed carefully to avoid tearing of the dura.

CSF leakage is a well-known complication after removal of PLL in spinal canal decompression, and incidence varies from 4.5% to 32%.<sup>[18]</sup> This complication is often found in patients, together with the adhesion of PLL. Yamaura et al<sup>[25]</sup> reported that the use of the “floating method” for ossification of posterior longitudinal ligament removal could decrease the incidence of CSF leakage, but to date, no comparative studies between DCS and non-DCS patients have been carried out to investigate the clinical effects of spinal canal decompression. Some studies have reported the application of dura sac repair as a management alternative for the treatment of CSF leakage.<sup>[18,26]</sup> In the 3 cases of CSF leakage in the removal groups in our study, the dura sac

**Table 3****Multivariate regression analysis for independents and MCS of postoperation 24th mo.**

Variable	Coefficient	P
HPLL removing	14.31	<.001
Postoperative mJOA	3.20	.002
Postoperative PCS	0.251	.03

HPLL removing = 1, HPLL retaining = 0. HPLL = hypertrophy posterior longitudinal ligament, MCS = mental component summary, mJOA = modified Japanese Orthopedic Association score, PCS = physical component summary.

**Table 4****Multivariate regression analysis for independents and PCS of postoperation 24th mo.**

Variable	Coefficient	P
HPLL removing	12.129	<.001
Postoperative mJOA	3.383	.002
Postoperative MCS	0.264	.03

HPLL removing = 1, HPLL retaining = 0. HPLL = hypertrophy posterior longitudinal ligament, MCS = mental component summary, mJOA = modified Japanese Orthopedic Association score, PCS = physical component summary.

**Table 5****Multivariate regression analysis for independents and mJOA score of postoperation 24th mo.**

Variable	Coefficient	P
HPLL removing	7.337	.002
Age	0.04	.007
Preoperative mJOA	0.278	<.001
Postoperative MCS	0.04	.002
Postoperative PCS	0.04	.002

HPLL removing = 1, HPLL retaining = 0. HPLL = hypertrophy posterior longitudinal ligament, MCS = mental component summary, mJOA = modified Japanese Orthopedic Association score, PCS = physical component summary.

defect was repaired using the placement of a gelatin sponge. A small piece of muscle and fibrin glue, or the dura, was sutured directly onto the defect. Our study showed that removal of HPLL did not significantly increase the incidence of CSF leakage, with this procedure being safe, and effective for the management of CSF leakage.

Iatrogenic neurological injury is a concern for spinal surgeons. Preoperative planning and proper surgical technique helps minimize potential injury. Seven cases in DCS patients and 5 cases in non-DCS patients were found to have transient postoperative muscle weakness. This may have arisen due to C5 nerve root withdrawal,<sup>[27]</sup> which may not be caused by nerve injury and has no definite associations with HPLL removal. Fortunately, these symptoms resolved gradually over a few weeks, and no significant difference was observed between the removal and retaining groups, both in DCS and non-DCS group. Additionally, due to epidural vascular plexus injury, postoperative hematomas have been occasionally described,<sup>[28]</sup> and these were consistent with the findings in our study. Although no serious compressive spinal cord symptoms in our study were observed, attention should be paid in order to avoid epidural vascular plexus injury, as such complications are often serious.

Some limitations should also be noted in the present study. First, this was a single center retrospective study. Unlike prospective studies, the indication for HPLL removal is miscellaneous in a retrospective one. Second, follow-up at 24 months may not be a sufficient amount of time, meaning that the reliability of the conclusions drawn from our study may be questionable. Additionally, our study included only 138 patients without random allocation. Therefore, further multicenter prospective randomized controlled studies with longer follow-up durations and larger sample sizes are urgently required to address these issues.

Based on the present retrospective study, we were able to draw several conclusions from our findings.

In DCS patients, if the HPLL had reduced mobility, and the spinal cord remained compressed after decompression, the HPLL should be removed. Accordingly, removal of HPLL in such procedures appeared, from our findings, to be beneficial and provided more complete spinal cord decompression and improved postoperative outcomes. Furthermore, patients who underwent HPLL removal had an improved QoL at 24-month follow-up. Although these procedures were more complicated and required a more skillful approach, they were generally safe and effective.

However, in non-DCS patients, it remains unclear as to whether removal of HPLL provides any clinical benefit, thus, HPLL removal may not be necessary.

**Table 6****Multivariate regression analysis for independents and mRR postoperation 24th mo.**

Variable	Coefficient	P
HPLL removing	9.117	.005
Postoperative mJOA	2.872	.024

HPLL removing = 1, HPLL retaining = 0. HPLL = hypertrophy posterior longitudinal ligament, mJOA = modified Japanese Orthopedic Association score, mRR = the modified recovery rate.

## Acknowledgments

The authors thank the staff at the Department of Orthopedics and the Department of Research and Statistics, Beijing Friendship Hospital, Capital Medical University, and the Department of Orthopedics, Xiangya Hospital, Central South University, for their kind cooperation when conducting this study. The authors also thank the staff at Medjaden Bioscience Limited Company for their kindly writing assistance.

## References

- Cloward RB. The anterior approach for removal of ruptured cervical disks. *J Neurosurg* 1958;15:602–17.
- Humphreys SC, Hodges SD, Fisher DL, et al. Reliability of magnetic resonance imaging in predicting disc material posterior to the posterior longitudinal ligament in the cervical spine. A prospective study. *Spine* 1998;23:2468–71.
- Takahashi M, Sakamoto Y, Miyawaki M, et al. Increased MR signal intensity secondary to chronic cervical cord compression. *Neuroradiology* 1987;29:550–6.
- Wang Z, Leng J, Liu J, et al. Morphological study of the posterior osseous structures of subaxial cervical spine in a population from northeastern China. *J Orthop Surg Res* 2015;10:53.
- Pavlov H, Torg JS, Robie B, et al. Cervical spinal stenosis: determination with vertebral body ratio method. *Radiology* 1987;164:771–5.
- Yue WM, Tan SB, Tan MH, et al. The Torg–Pavlov ratio in cervical spondylotic myelopathy: a comparative study between patients with cervical spondylotic myelopathy and a nonspondylotic, nonmyelopathic population. *Spine* 2001;26:1760–4.
- Medow JE, Trost G, Sandin J. Surgical management of cervical myelopathy: indications and techniques for surgical corpectomy. *Spine* J 2006;6(6 Suppl):233S–41S.
- Ying Z, Xin W, Jing Z, et al. Cervical corpectomy with preserved posterior vertebral wall for cervical spondylotic myelopathy: a randomized control clinical study. *Spine* 2007;32:1482–7.
- Benzel EC, Lancon J, Kesterson L, et al. Cervical laminectomy and dentate ligament section for cervical spondylotic myelopathy. *J Spinal Disord* 1991;4:286–95.
- Yonenobu K, Abumi K, Nagata K, et al. Interobserver and intraobserver reliability of the Japanese orthopaedic association scoring system for evaluation of cervical compression myelopathy. *Spine* 2001;26:1890–5.
- Busija L, Osborne RH, Nilsdotter A, et al. Magnitude and meaningfulness of change in SF-36 scores in four types of orthopedic surgery. *Health Qual Life Outcomes* 2008;6:55.
- Roos EM, Toksvig-Larsen S. Knee injury and Osteoarthritis Outcome Score (KOOS)—Validation and comparison to the WOMAC in total knee replacement. *Health Qual Life Outcomes* 2003;1:17.
- Baron R, Elashaal A, Germon T, et al. Measuring outcomes in cervical spine surgery: think twice before using the SF-36. *Spine* 2006;31:2575–84.
- Coster W, Haley S, Jette A. Measuring patient-reported outcomes after discharge from inpatient rehabilitation settings. *J Rehabil Med* 2006;38:237–42.
- Schiavolin S, Broggi M, Visintini S, et al. Change in quality of life, disability, and well-being after decompressive surgery: results from a longitudinal study. *Int J Rehabil Res* 2015;38:357–63.
- Chiba K, Oqawa Y, Ishii K, et al. Long-term results of expansive open-door laminoplasty for cervical myelopathy—average 14-year follow-up study. *Spine* 2006;31:2998–3005.
- Bai CR, Wang BQ, Li KH, et al. Benefit of degenerative posterior longitudinal ligament removal during anterior decompression in cervical spondylotic myelopathy. *Orthopedics* 2015;38:e54–61.

- [18] Wang X, Chen Y, Chen D, et al. Removal of posterior longitudinal ligament in anterior decompression for cervical spondylotic myelopathy. *J Spinal Disord Tech* 2009;22:404–7.
- [19] Ivancic PC, Coe MP, Ndu AB, et al. Dynamic mechanical properties of intact human cervical spine ligaments. *Spine J* 2007;7:659–65.
- [20] Loughenbury PR, Wadhvani S, Soames RW. The posterior longitudinal ligament and peridural (epidural) membrane. *Clin Anat* 2006;19:487–92.
- [21] Chen TY, Crawford NR, Sonntag VK, et al. Biomechanical effects of progressive anterior cervical decompression. *Spine* 2001;26:6–13.
- [22] Mizuno J, Nakagawa H, Hashizume Y. Analysis of hypertrophy of the posterior longitudinal ligament of the cervical spine, on the basis of clinical and experimental studies. *Neurosurgery* 2001;49:1091–7.
- [23] Yu M, Tang Y, Liu Z, et al. The morphological and clinical significance of developmental cervical stenosis. *Eur Spine J* 2015;24:1583–9.
- [24] Chappell BW. Cervical spinal stenosis: determination with vertebral body ratio method. *Radiology* 1988;167:282.
- [25] Yamaura I, Kurosa Y, Matuoka T, et al. Anterior floating method for cervical myelopathy caused by ossification of the posterior longitudinal ligament. *Orthop Relat Res* 1999;359:27–34.
- [26] Cardoso MJ, Koski TR, Ganju A, et al. Approach-related complications after decompression for cervical ossification of the posterior longitudinal ligament. *Neurosurg Focus* 2011;30:1–5.
- [27] Sakaura H, Hosono N, Mukai Y, et al. C5 palsy after decompression surgery for cervical myelopathy: review of the literature. *Spine* 2003;28:2447–51.
- [28] Fountas KN, Kapsalaki EZ, Nikolakakos LG, et al. Anterior cervical discectomy and fusion associated complications. *Spine* 2007;32:2310–7.