

## Varicella-Zoster Radiculitis Mimicking Sciatica: A Diagnostic Dilemma

### Abstract

Varicella-zoster virus (VZV) presenting as a radicular pain in the thoracic region is not uncommon, but the presentation in the lumbar and thigh region is not frequently seen. Characteristic segmental vesicular–bullous rash in a dermatomal distribution associated with pain and allodynia is a prominent feature. The pain appears before rash. It is not uncommon for clinicians to misdiagnose radicular pain caused by VZV due to prolapsed disc. We report two patients who presented to us with complaints of back pain with leg radiculopathy that were initially treated for discogenic radiculopathy and rash was wrongly attributed to hot fomentation. This case report emphasizes the importance of including varicella-zoster radiculitis in the differential diagnosis of radicular pain and clinical examination of every rash. Physical examination is must if the patient complains of rash. Appropriate and timely diagnosis can prevent unnecessary investigations.

**Keywords:** Radiculitis, rash, varicella zoster

### Introduction

Varicella-zoster virus, progenitor of both varicella (chickenpox) and herpes zoster (HZ) commonly affects most individuals in their first or second decade of life. It lies dormant in the dorsal root ganglion of the affected nerve. The characteristic clinical presentation begins with neuropathic pain, itching, burning, and dysesthesias with segmental vesicular–bullous rash in a dermatomal distribution, a prominent feature.<sup>[1,2]</sup> In a few cases, associated debilitating features imitating radiculopathy in few dermatomal segments and variable responses to treatment are a cause for concern. Considering herpes as a differential in patients with dysesthetic pain or where the pain is disproportionate to radiological findings is essential as it has a profound effect on the functional status of the individual. This case report emphasizes the importance of including varicella-zoster radiculitis in the differential diagnosis of radicular pain in the leg and thigh and thorough clinical evaluation.

### Case Reports

#### Case 1

A 30-year-old male presented with severe back pain, buttock pain radiating to the

right anterior thigh of 7 days. Pain severity was 8/10 on visual analog scale, and there was associated dysesthesia over the affected dermatome. Neurological examination was normal, with no skin lesions. Magnetic resonance imaging (MRI) revealed a small disc bulge at L3-4 levels [Figure 1]. The diagnosis of radicular pain due to disc prolapse was made. Symptomatic treatment was started, including rest and neurotropic agents (Gabapentin).

A week later, the patient reported progressive worsening of symptoms and developed rash over the right thigh, which he attributed to hot fomentation. On examination, multiple nonitchy vesicular lesions were present over the right anteromedial thigh and also right paraspinal region near the posterior superior iliac spine [Figure 2]. The patient was immunocompetent and had no history of diabetes mellitus. Immunoglobulin M (IGM) and Immunoglobulin G (IGG) levels for varicella were found to be elevated. The rash was typical of varicella infection and oral acyclovir 800 mg five times a day was started for 7 days, for the infection and pregabalin (75 mg) was started for neuropathic pain. There was the symptomatic improvement, and at 3 weeks follow-up, complete relief was seen.

This is an open access journal, and articles are distributed under the terms of the Creative Commons Attribution-NonCommercial-ShareAlike 4.0 License, which allows others to remix, tweak, and build upon the work non-commercially, as long as appropriate credit is given and the new creations are licensed under the identical terms.

For reprints contact: WKHLRPMedknow\_reprints@wolterskluwer.com

**How to cite this article:** Mallepally AR, Mahajan R, Rustagi T, Marathe NA, Chhabra HS. Varicella-zoster radiculitis mimicking sciatica: A diagnostic dilemma. Asian J Neurosurg 2020;15:666-9.

Submitted: 01-Mar-2020

Revised: 24-Apr-2020

Accepted: 25-May-2020

Published: 28-Aug-2020

**Abhinandan Reddy Mallepally, Rajat Mahajan, Tarush Rustagi, Nandan Amrit Marathe, Harvinder Singh Chhabra,**

Spinal Services, Indian Spinal Injuries Centre, New Delhi, India

#### Address for correspondence:

Dr. Abhinandan Reddy Mallepally, Indian Spinal Injuries Centre, Sector C, Vasant Kunj, Delhi - 110 070, India. E-mail: mabhi28@gmail.com

#### Access this article online

Website: www.asianjns.org

DOI: 10.4103/ajns.AJNS\_75\_20

#### Quick Response Code:



## Case 2

A 45-year-old female presented with complaints of back pain and right leg pain. There was associated dysesthesia over the right anterolateral thigh and leg. MRI showed disc bulge at L4-5 compressing the nerve root to a mild extent [Figure 3]. The pain was attributed to the disc as it was reflecting the dermatomal distribution of pain. She complained of some rash at the initial presentation, which was again attributed to hot fomentation over anterolateral thigh [Figure 4]. Symptomatic treatment was initiated, consisting of pregabalin, anti-inflammatory medications, and rest. The patient returned to the clinic after 2 days complaining of progressive dysesthesia and increased vesicular rash. IGG and IGM levels for varicella were elevated. The diagnosis of HZ was confirmed based on the vesicular rash and dermatomal distribution of pain. She was then started on oral acyclovir 800 mg five times a day for a total of 7 days along with pregabalin (75 mg), and her symptoms decreased over the next 2 weeks. At follow-up of 3 weeks, the patient was symptom-free.

## Discussion

Varicella-zoster virus, a neurotropic virus, affects afferent sensory neurons causing primary sensory neuritis.<sup>[3]</sup> The

mechanism of re-activation leading to characteristic segmental cutaneous rash and dysesthetic pain is not known. Psychological stress, surgical stress, trauma, immunodeficiency, malignant conditions are few identifiable causes for reactivation.<sup>[4]</sup> The virus usually affects people beyond 50 years of age, with 20%–30% of the general population being affected. There is 80%–90% increased risk among immunodeficient cases.<sup>[5]</sup> Both cases in our series were immune-competent and had no comorbidities. This underscores the importance of including zoster radiculitis in even immune-competent patients. HZ presents with neuralgic pain, itching, burning, and dysesthesia with a unilateral segmental rash that appears proximally and spreads distally in a specific dermatome. The typical rash is with erythematous base, initially maculopapular progressing to vesicular eruptions, which generally resolve in few weeks after onset of prodromal symptoms.<sup>[2]</sup> When cervical or lumbar nerve roots are involved, symptoms may mislead the physician to diagnose a discogenic radiculopathy if not examined carefully as was seen in our cases.

In both cases, the initial diagnosis of discogenic pain was made based on clinical features corroborated by magnetic resonance (MR) image findings. The diagnosis was also confounded by the occurrence of rash following hot fomentation. If diagnosed, appropriate treatment can

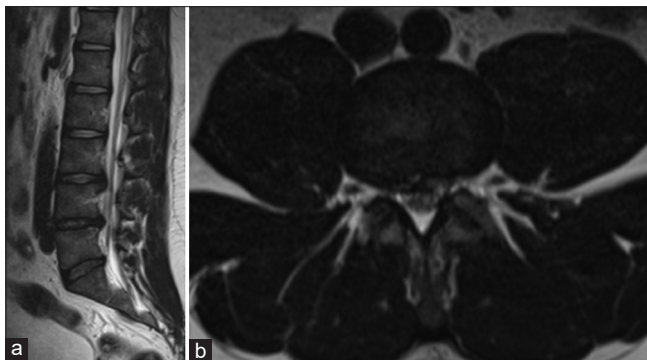

Figure 1: (a) Sagittal T2 weighted magnetic resonance imaging of the 30-year-old male showing mild disc bulge at L3-4 with mild compression of the nerve root on the right side (b) Axial T2 weighted magnetic resonance imaging of the 30-year-old male showing mild disc bulge at L3-4 with mild compression of the nerve root on the right side

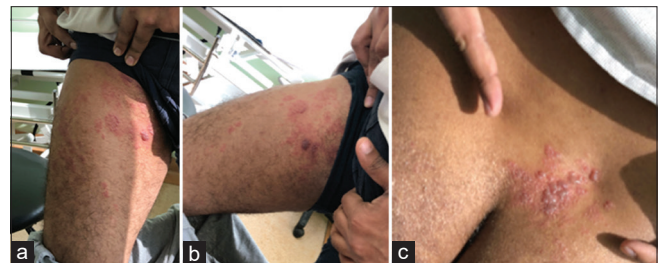

Figure 2: (a-c) Clinical picture of the 30-year-old male showing the classical vesicular eruptions on the anteromedial aspect of the thigh and right paraspinal region at posterior superior iliac spine

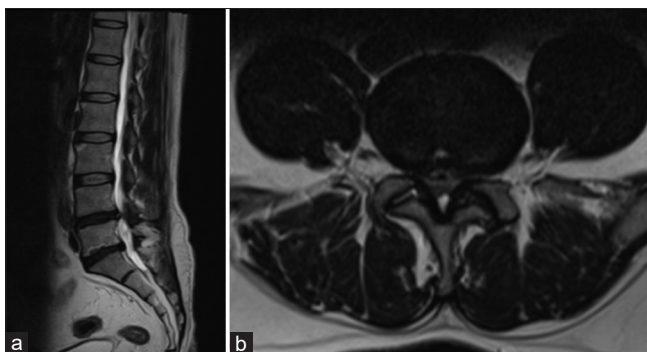


Figure 3: (a) Sagittal magnetic resonance images of the 45-year-old female showing mild disc bulges in L4-5 and L5-S1 with mild compression of the nerve root right more than the left at L4-5 level (b) Axial magnetic resonance images of the 45-year-old female showing mild disc bulges in L4-5 and L5-S1 with mild compression of the nerve root right more than the left at L4-5 level

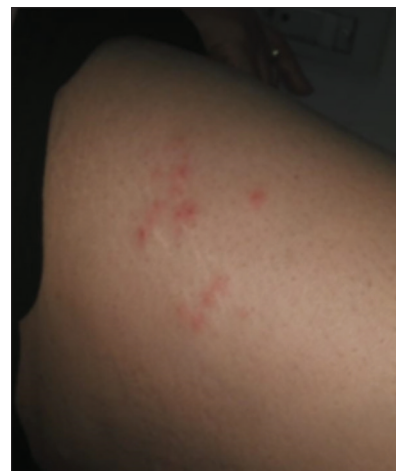

Figure 4: Anterolateral aspect of the right thigh of the 45-year-old female showing vesicular eruptions characteristic of herpes zoster

be started early and save the patient from unnecessary investigations. The pain in both the patients was not concordant with the MR imaging. The amount of disc bulge and nerve root compression was not correlating to the amount of pain and disability described and experienced by both the patients. Critical analysis of the MRI scans is paramount to consider differential diagnosis for radiculopathy. Patients, especially females, may not feel comfortable to openly describe and present the rash for the physical examination. It is important for physicians to counsel the patients for a detailed physical examination. Neuritis leads to burning, itching, and stabbing pain.<sup>[6]</sup> Allodynia in old patients is notably disabling. This characteristic feature of herpetic neuritis causes severe pain even with slightest stimulation like the light touch of clothing, as was seen in both of our patients. Radicular pain due to disc is lancinating and stabbing in nature and is usually not associated with allodynia. It is one of the most important features which should be asked from the patients and can differentiate it from radicular pain due to a herniated disc. It is especially important in the prodromal period when the rash has not appeared, and the only symptom is radicular pain. Oral acyclovir (800 mg five times a day for 7 days), famciclovir (500 mg every 8 h for 7 days) and valacyclovir (1 g three times a day for 7 days) decreases the intensity of pain and duration of chronic pain in older HZ patients when treated within 72 h of rash onset.<sup>[7]</sup> Pregabalin or gabapentin can also be given along with it to decrease the neuropathic pain.

Varicella-zoster causing sciatica has been reported previously in the literature [Table 1]. Morris and Peters in 1974 described a 74-year-old woman who had repeated episodes of dull pain in the right buttock and leg for 6 years.<sup>[8]</sup> Pain reached a peak within a few hours after onset followed in 2–4 days by a characteristic vesicular

rash. Lumbosacral X-rays were normal. In 1981, Clavel<sup>[9]</sup> reported a 44-year-old woman with sciatica due to a herniated lumbar disc complicated by the appearance of a zoster eruption over the same dermatome. She was administered dexamethasone for the radicular pain, and open laminectomy with discectomy was performed. Both these patients did not receive acyclovir as it was approved for medical use only in 1981.<sup>[10]</sup>

Montgomery *et al.*<sup>[11]</sup> in 2015 reported a 67-year-old woman who underwent surgical management with anterior cervical decompression and fusion at C5–C6 and C6–C7. Her preoperative radicular symptoms resolved, and myelopathic symptoms improved significantly in the immediate postoperative period. At 6-month follow-up, the patient presented with severe exacerbation of radicular symptoms in her left upper extremity. Symptoms were consistent with left C6 radiculopathy. Repeat cervical radiographs and MRI failed to demonstrate recurrent stenosis, pseudarthrosis, or adjacent-level changes. Shortly after, the patient developed erythematous vesicular rash extending from left shoulder to first and second digits. She was diagnosed with HZ in a left C6 nerve root distribution. She was started on valacyclovir and topical steroids and reported a progressive reduction in symptoms. Hackenberg *et al.*<sup>[12]</sup> reported a 62-year-old patient with lower back pain radiating into the right leg. MRI showed no degenerative lesions, but swelling of nerve root supplying the affected dermatome. For pain treatment, the patient received lumbar epidural infiltrations. During this treatment, the patient suddenly developed a vesicular skin rash. After the diagnosis of a lumbar HZ and an acyclovir treatment, the patient could be discharged in an ameliorated condition.

To conclude, it is important to keep HZ radiculitis in the differential diagnosis of radicular pain even in

**Table 1: Previously published literature reporting varicella zoster causing radiculopathy**

Author	Year	Clinical features	Imaging	Management
Morris <i>et al.</i>	1974	74 years lady, recurrent right sciatica over 6 years with vesicular rash, root tension signs negative	X-rays of lumbosacral spine revealed no abnormality	Symptomatic treatment for pain: Narcotic analgesics
Clavel	1981	44 years lady, bilateral lower limb radiculopathy, (R) EHL weakness, vesicular rash (L) ankle, nerve root tension signs positive	X-rays: Reduced L4-5-disc space Soluble-contrast radiculography: Block to passage of contrast at lower third of 4th lumbar vertebra	Dexamethasone for radiculopathy Wide laminectomy with discectomy at L4-5 level
Montgomery <i>et al.</i>	2015	67 years lady (post-ACDF) with C6 radiculopathy and vesicular rash at 6 months follow-up	Cervical radiographs and MRI: No signs of recurrent stenosis, pseudoarthrosis or adjacent-level changes	Valacyclovir and topical steroids
Hackenberg <i>et al.</i>	2015	62-year-old patient with lower back pain radiating into the right leg accompanied by numbness. For pain treatment, received lumbar epidural infiltrations. During this treatment patient developed a skin rash with grouped vesicular blisters	MRI scan of the lumbar spine : no degenerative discovertebral lesions, but a swelling of the nerve root supplying the affected dermatome	Pain therapy with ibuprofen 600 mg 3 times a day combined with a systemic antiviral treatment with acyclovir 800 mg oral 5 times a day for a period of 7 days

MRI – Magnetic resonance imaging; ACDF – Anterior cervical discectomy with fusion; EHL – Extensor hallucis longus

immunocompetent adults. The dysesthetic nature of pain differentiates it from discogenic radicular pain, which is lancinating in nature. Physical examination is must if the patient complains of rash. Appropriate and timely diagnosis can prevent unnecessary investigations and provide a timely cure.

#### Declaration of patient consent

The authors certify that they have obtained all appropriate patient consent forms. In the form the patient(s) has/have given his/her/their consent for his/her/their images and other clinical information to be reported in the journal. The patients understand that their names and initials will not be published and due efforts will be made to conceal their identity, but anonymity cannot be guaranteed.

#### Financial support and sponsorship

Nil.

#### Conflicts of interest

There are no conflicts of interest.

#### References

- Gupta SK, Helal BH, Kiely P. The prognosis in zoster paralysis. *J Bone Joint Surg Br* 1969;51:593-603.
- Liu Y, Wu BY, Ma ZS, Xu JJ, Yang B, Li H, *et al.* A retrospective case series of segmental zoster paresis of limbs: Clinical, electrophysiological and imaging characteristics. *BMC Neurol* 2018;18:121.
- Alsheklee A, Tay E, Buczek M, Shakir ZA, Katirji B. Herpes zoster with motor involvement: Discordance between the distribution of skin rash and localization of peripheral nervous system dysfunction. *J Clin Neuromuscul Dis* 2011;12:153-7.
- Hata A, Kuniyoshi M, Ohkusa Y. Risk of herpes zoster in patients with underlying diseases: A retrospective hospital-based cohort study. *Infection* 2011;39:537-44.
- Yawn BP, Saddier P, Wollan PC, St Sauver JL, Kurland MJ, Sy LS. A population-based study of the incidence and complication rates of herpes zoster before zoster vaccine introduction. *Mayo Clin Proc* 2007;82:1341-9.
- Gumina S, Candela V, Passaretti D, Villani C. Shoulder pain due to cervical radiculopathy: An underestimated long-term complication of herpeszoster virus reactivation? *Int Orthop* 2018;42:157-60.
- Cohen JI. Clinical practice: Herpes zoster. *N Engl J Med* 2013;369:255-63.
- Morris HH 3<sup>rd</sup>, Peters BH. Recurrent sciatica associated with herpes simplex. Case report. *J Neurosurg* 1974;41:97-9.
- Clavel ME. Symptomatic herpes zoster and sciatica. *Acta Neurochir* 1981;58:259-63.
- Ganesan A, Proudfoot J. Analogue-based drug discovery. In: Fischer J, Ganellin CR, editors. *Analogue-Based Drug Discovery*. Weinheim: Wiley-VCH; 2010.
- Montgomery JT, Lawrence BD, Brodke DS, Patel AA. Postoperative shingles mimicking recurrent radiculopathy after anterior cervical discectomy and fusion. *Global Spine J* 2015;5:219-23.
- Hackenberg RK, von den Driesch A, König DP. Lower back pain with sciatic disorder following L5 dermatome caused by herpes zoster infection. *Orthop Rev (Pavia)* 2015;7:6046.