

# Comparison of the Effectiveness of Ultrasound Imaging and Perioperative Measurement in the Diagnosis and Characterization of Incisional Hernia

Ayşegül Karadayı Buyukozsoy<sup>1</sup>, Emrah Karatay<sup>2\*</sup>, Mehmet Ali Gök<sup>3</sup>

<sup>1</sup>Departments of Radiology, Istanbul Kartal Dr. Lutfi Kırdar City Hospital, Istanbul, Turkey, <sup>2</sup>Department of Radiology, Marmara University Pendik Training and Research Hospital, Istanbul, Turkey, <sup>3</sup>Departments of General Surgery, Istanbul Kartal Dr. Lutfi Kırdar City Hospital, Istanbul, Turkey

## Abstract

**Background:** Incisional hernia (IH) is a common complication after abdominal surgery, and there is no gold standard imaging modality for its diagnosis. Although computed tomography is frequently used in clinical practice, it has limitations such as radiation exposure and relatively high cost. The aim of this study is to establish standardization and hernia typing by comparing preoperative ultrasound (US) measurements and perioperative measurements in IH cases. **Methods:** The patients who were operated for IH in our institution between January 2020 and March 2021 were reviewed, retrospectively. In result, 120 patients were included in the study, and the cases had preoperative US images and perioperative hernia measurements. IH was divided into three subtypes as omentum (Type I), intestinal (Type II), and mixed (Type III) according to the defect content. **Results:** Type I IH was detected in 91 cases, Type II IH in 14 cases, and Type III IH in 15 cases. When the diameters of IH types were compared for preoperative US and perioperative measurements, respectively, there was no statistical significance ( $P = 0.185$  and  $P = 0.262$ ). According to Spearman correlation, there was a positive very strong correlation between preoperative US measurements and perioperative measurements ( $\rho = 0.861$  and  $P < 0.001$ ). **Conclusion:** As stated by our results, US imaging can be performed easily and quickly, providing a reliable way to accurately detect and characterize an IH. It can also facilitate the planning of surgical intervention in IH by providing anatomical information.

**Keywords:** Defect content, hernia types, incisional hernia, perioperative measurement, ultrasound

## INTRODUCTION

Incisional hernia (IH) is a common complication after open abdominal surgery, and its prevalence has been reported to range 10%–30% in different series.<sup>[1,2]</sup> The various factors explaining the variability in IH rate include age, obesity, abdominal aortic aneurysms, and previous abdominal surgery.<sup>[2]</sup> Larger hernias are usually detected on physical examination, and IH detection may be difficult in obesity or small facial defects.<sup>[3]</sup> Its repair is sometimes complex and can lead to increased morbidity and failure rates. Besides, chronically incarcerated contents confuse the estimation of the true size of the fascial defect.<sup>[4]</sup> For these cases, surgeons may experience difficulties in the diagnosis, characterization, management, and follow-up process. It is considered important to use imaging modalities in the diagnosis of IH to obtain more reliable results.<sup>[3,4]</sup>

Some diagnostic modalities are used for the diagnosis of IH, including physical examination, ultrasound (US), computed tomography (CT), magnetic resonance imaging, and perioperative diagnosis. CT is the most commonly used imaging modality for the diagnosis and characterization of IH, especially in complex situations.<sup>[5]</sup> However, performing cross-sectional imaging in the supine position may result in clinically undetected hernias. Radiation exposure during the procedure also limits its use in IH.<sup>[6]</sup>

Therefore, noninvasive, economical and useful, multi-section, multi-angle, and multi-position ultrasonography scans have

**Address for correspondence:** Dr. Emrah Karatay,

Department of Radiology, Marmara University Pendik Training and Research Hospital, Fevzi Çakmak, Muhsin Yazıcıoğlu Cd No: 10 Pendik, 34899, Istanbul, Turkey.

E-mail: emrahkaratay1984@gmail.com

Received: 12-10-2021 Revised: 20-11-2021 Accepted: 14-03-2022 Available Online: 05-09-2022

### Access this article online

Quick Response Code:



Website:  
www.jmuonline.org

DOI:  
10.4103/jmu.jmu\_189\_21

This is an open access journal, and articles are distributed under the terms of the Creative Commons Attribution-NonCommercial-ShareAlike 4.0 License, which allows others to remix, tweak, and build upon the work non-commercially, as long as appropriate credit is given and the new creations are licensed under the identical terms.

For reprints contact: WKHLRPMedknow\_reprints@wolterskluwer.com

**How to cite this article:** Buyukozsoy AK, Karatay E, Gök MA. Comparison of the effectiveness of ultrasound imaging and perioperative measurement in the diagnosis and characterization of incisional hernia. J Med Ultrasound 2023;31:35-9.

started to be used in the detection of IH.<sup>[7]</sup> US imaging is being used with increasing frequency as a way to identify IH and as an alternative to CT for detecting recurrence during long-term follow-up of patients. The US offers several advantages over CT due to its lack of exposure to ionizing radiation, real-time results for the practitioner and patient, and the potential to detect hernias not easily visible on CT due to its dynamic nature.<sup>[7,8]</sup> It plays an important role in the diagnosis of IH with 95% sensitivity and 90% specificity.<sup>[9]</sup>

The US is an increasingly important guide to characterize hernias in surgical planning. The most common features collected on an US scan for preoperative evaluation appear to be the transverse dimensions of the hernia, hernia content, and vascularization of the intestinal loops wall.<sup>[10]</sup> Furthermore, a positive Valsalva maneuver during the procedure can be used as a diagnostic symptom.<sup>[11]</sup> Although a previous study provided critical baseline data supporting the use of US for IH, these weaknesses limit the generalizability and validity of the results. Although the ultrasonographic features of ventral hernias have been described, the reliability and validity of US in the diagnosis of ventral hernias has not been systematically studied extensively.<sup>[12]</sup> In addition, this study had disadvantages such that it included a limited number of patients for the performance of the US examination and only evaluated vascular surgery patients.<sup>[13]</sup> Due to the existing reasons, there are not enough US studies for comparing and typing in IH cases.<sup>[10-13]</sup>

In this study, we aimed to establish standardization and hernia typing by comparing preoperative US measurements and perioperative measurements in IH cases. Thus, we tried showing the effectiveness of using US in the diagnosis of IH cases.

## MATERIALS AND METHODS

### Study design

The institutional review board evaluated and approved this retrospective study, and each patient gave informed consent (IRB 21/198). Since human objects were available, the Declaration of Helsinki was adhered to throughout the study. All patients who were operated for IH in our institution between January 2020 and March 2021 were scanned, retrospectively. The cases who did not want to have laparoscopic IH repair surgery and did not want to be included, the presence of inguinal hernia, chronic-degenerative muscle disorder, use of myorelaxant or corticosteroid therapy, professional athletes, and age <18-year-old cases were excluded from the study. As a result, 120 patients age  $\geq$ 18-year-old who underwent IH surgery were detected and included in the study. Furthermore, all of these cases had preoperative US images and perioperative hernia measurements. Concomitantly, the included patients had height, weight, and body mass index (BMI) values.

### Ultrasound imaging and perioperative measurements

All preoperative US examinations were performed by an experienced radiologist. US-guided IH measurements

were made using a 4–15 MHz linear transducer (MyLab Seven, Genova, Italy). During imaging, patients were in the supine position with their hands raised above their heads. The US probe was placed on the skin without excessive compression of the skin surface during measurements. IH was divided into three subtypes as omentum (Type I), intestinal (Type II), and mixed (Type III) according to the defect content. For each patient, the maximum transverse diameter of the defect in millimeters (mm) was determined and noted [Figure 1]. Similarly, since the shape of the defects was irregular, the longest diameter of the defect was measured laparoscopically in millimeters. The maximum transverse diameter of the defect was measured by the surgeon during the operation, and typing was made according to the content [Figure 2].

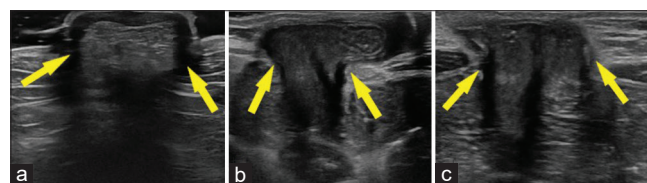
### Statistical analysis

SPSS 21<sup>st</sup> version software was used for data analysis (IBM, Armonk, NY, USA). Descriptive statistics were expressed as minimum, maximum, standard deviation, median, frequency, and ratio values. Kolmogorov–Smirnov test was applied to see whether the variables were normally distributed. Categorical variables in US imaging and perioperative groups were compared using Chi-square and Fisher's exact tests. Since there was no normal distribution, Mann–Whitney *U* and Kruskal–Wallis *H* tests were used in the analysis of gender, IH subtypes, and defect measurements. Spearman correlation was used to evaluate the relationship between preoperative US and intraoperative defect measurements. At the 95% confidence interval,  $P < 0.05$  was considered statistically significant.

## RESULTS

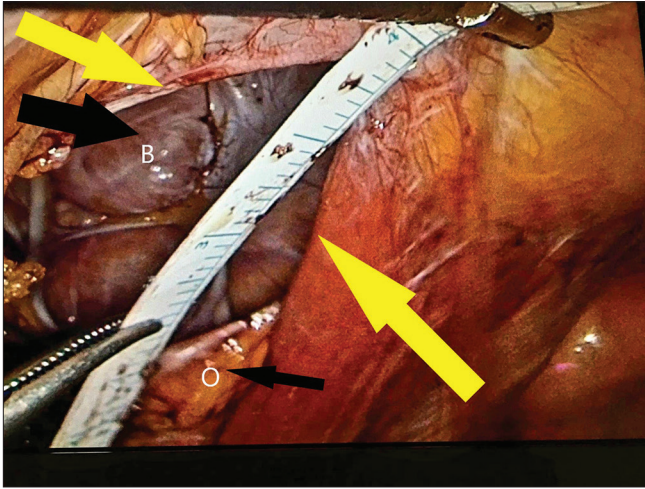
A total of 120 patients, 78 females and 42 males, were included in the study. The youngest case was 26 years old and the oldest case was 84 years old and both were male. The mean height was  $175.02 \pm 4.54$  mm in males and  $170.66 \pm 4.31$  mm in females. The mean weight for males was  $79.55 \pm 7.31$  kilograms (kg) and  $68.83 \pm 6.67$  kg for females. The mean BMI was calculated as  $26 \pm 2.42$  for males and  $23.83 \pm 2.74$  for females [Table 1]. No statistical significance was found when age, height, weight, and BMI were compared according to gender ( $P > 0.05$ ).

In this study, only an IH defect was present in each case. IH types were evaluated, respectively, and 76 males had Type I, 14 had Type II, and 12 had Type III defects. Fifteen females



**Figure 1:** According to the content of the defect in the ultrasound imaging of the anterior abdominal wall; (a) Type I (omentum), (b) Type II (intestine), and (c) Type III (mixed) incisional hernia are shown. The defect level is indicated by the yellow arrow

had Type I and three had Type III defects, and there was no Type II defect [Table 2]. When the relationship between IH



**Figure 2:** A Type II incisional hernia (intestinal content) with a diameter of approximately 3 cm in the perioperative laparoscopic measurement of the defect is presented by yellow arrows. The omentum (O) is indicated by a thin black arrow and the bowel (B) by a thick black arrow

types and gender was investigated, no statistically significance was found ( $P = 0.259$ ).

In preoperative US measurements for all cases, the transverse size of the defect was measured as a minimum 35 mm, a maximum 85 mm, and the mean  $58.62 \pm 13.91$  mm. In perioperative measurements for all cases, the transverse size of the defect was measured as a minimum 30 mm, a maximum 80 mm, and the mean  $60.52 \pm 13.24$  mm. The measurement method of the defect and the size distribution of IH types were summarized in Table 3. When the diameters of IH types were compared for preoperative US and perioperative measurements, respectively, there was no statistical significance between defect types ( $P = 0.185$  and  $P = 0.262$ ).

When the relationship between preoperative US measurements and perioperative measurements was evaluated using Spearman correlation, there was a positive very strong relationship ( $\rho=0.861$  and  $P < 0.001$ ).

## DISCUSSION

An IH is a protrusion of tissue and/or organs due to an operative defect of the abdominal walls, with an incidence

**Table 1: Demographics**

	Mean $\pm$ SD (minimum-maximum)			P
	Gender		Total (n=120)	
	Male (n=78)	Female (n=42)		
Age	52.97 $\pm$ 15.35 (26-84)	42.00 $\pm$ 5.24 (37-49)	51.33 $\pm$ 14.81 (26-84)	>0.05
Height (mm)	175.02 $\pm$ 4.54 (165-182)	170.66 $\pm$ 4.31 (165-175)	174.37 $\pm$ 4.75 (165-182)	>0.05
Weight (kg)	79.55 $\pm$ 7.31 (66-94)	68.83 $\pm$ 6.67 (62-80)	77.95 $\pm$ 8.16 (62-94)	>0.05
BMI	26 $\pm$ 2.42 (21-30)	23.83 $\pm$ 2.74 (21-29)	25.68 $\pm$ 2.58 (21-30)	>0.05
Defect US (mm)	56.85 $\pm$ 12.57 (34-84)	63.25 $\pm$ 17.01 (46-85)	58.62 $\pm$ 13.91 (34-85)	0.185
Defect perioperative (mm)	59.44 $\pm$ 12.43 (32-81)	65.16 $\pm$ 16.17 (45-82)	60.52 $\pm$ 13.24 (32-82)	0.262

BMI: Body mass index, US: Ultrasound, SD: Standard deviation

**Table 2: Incisional hernia and gender relationship**

Gender	IH types			Total, n (% within gender)
	Omentum (Type I), n (% within gender)	Intestinal (Type 2), n (% within gender)	Mixed (Type 3), n (% within gender)	
Male	76 (74.5)	14 (13.7)	12 (11.8)	102 (100)
Female	15 (83.3)	0	3 (16.7)	18 (100)
Total	91 (75.8)	14 (11.7)	15 (12.5)	120 (100)

IH: Incisional hernia

**Table 3: Defect measurements and incisional hernia types**

IH types	n	Mean $\pm$ SD (minimum-maximum)		P
		Defect preoperative US (mm)	Defect perioperative (mm)	
Omentum (Type I)	91	57.46 $\pm$ 13.96 (35-85)	59.64 $\pm$ 13.69 (30-80)	>0.05
Intestinal (Type II)	14	62.35 $\pm$ 9.78 (45-75)	63.57 $\pm$ 9.07 (50-68)	>0.05
Mixed (Type III)	15	62.2 $\pm$ 16.34 (40-75)	63 $\pm$ 13.73 (45-80)	>0.05
Total	120	58.62 $\pm$ 13.91 (35-85)	60.52 $\pm$ 13.24 (30-80)	>0.05

SD: Standard deviation, US: Ultrasound, IH: Incisional hernia

of up to 20% after abdominal surgery.<sup>[14]</sup> Although CT is the most commonly used imaging modality in the diagnosis of IH, the diagnosis of IH is most time difficult because there is no gold standard. In addition to exposure to ionizing radiation, omitting small hernias are negative features of CT.<sup>[15]</sup> The use of US is particularly suitable for the evaluation of the anterior abdominal wall, given its accessibility and ability to monitor structures in real time with the aid of physical maneuvers (e.g., Valsalva). The use of US imaging is thought to be useful in the characterization of hernias for preoperative planning and is being used more and more frequently.<sup>[16]</sup>

Beck *et al.* compared the efficacy of US and CT in the diagnosis of IH in 181 cases. The prevalence of IH in this population was 55%, and US examination showed high sensitivity (98%) and specificity (88%) in the diagnosis of hernia. It has been shown that US imaging can be an accurate alternative to CT scanning for diagnosing IHs, with additional benefits such as no radiation exposure and immediate bedside interpretation.<sup>[9]</sup> Similarly, Baucom *et al.* compared the efficacy of both imaging modalities in the diagnosis of IH. The mean surface area was calculated by measuring the maximum transverse and craniocaudal diameters on US imaging. Similar results were obtained using CT and US imaging in 94 cases, and US imaging was more successful in 15 cases with a hernia diameter  $\geq 10$  cm.<sup>[7]</sup>

den Hartog *et al.* compared the validity and reliability of ultrasonography with CT in the diagnosis of IH. The prevalence of IH was 60.0% with CT scan as the diagnostic method and 42.5% with US. Besides, the sensitivity of US examination when using CT as a comparison was 70.8%, the specificity was 100%.<sup>[13]</sup> Fang *et al.* evaluated 122 IH defects in 78 patients using an automated volume-scanning system on US. All IH cases were detected by the US, which is compatible with surgery. In result, the use of this application has been strongly recommended in the detection of IH.<sup>[17]</sup> Bloemen *et al.* followed 456 patients undergoing abdominal surgery at 6-month intervals for approximately 3 years. IH was detected in 103 patients, and physical examination was able to diagnose 82 of them. In the combined use of physical examination and US, all cases were diagnosed as IH. It has been stated that the combined application instead of physical examination alone can detect a significant number of asymptomatic hernias.<sup>[16]</sup>

Wang *et al.* evaluated the effect of the defect on the abdominal wall muscles with shear-wave elastography (SWE). SWE measurements were made from wall muscles in B-mode US images in 28 IH patients and 14 healthy controls, and the values were significantly higher in the hernia group.<sup>[18]</sup> Chaudhry *et al.* evaluated SWE in IH modeling on rats and demonstrated that it can be used in hernia diagnosis, and control after surgical mesh repair.<sup>[19]</sup>

There are limited studies in the literature on the evaluation of IH with US imaging.<sup>[16-19]</sup> Our study is the first reported in the literature to evaluate IH by separating subtypes. In previous studies, IH classification was not made according to the content

of the defect. Our study has one of the largest case series in the literature on US modality.<sup>[7,9,17]</sup> All cases were diagnosed with US, and a very strong positive correlation was found when the defect sizes were compared in preoperative US, and perioperative measurements ( $\rho = 0.861$ ). Unlike previous studies, both measurement methods were evaluated according to BMI, weight, and height.<sup>[12-16]</sup>

## Limitations

The first limitation is that all defect measurements are made by a single radiologist or surgeon.<sup>[16-19]</sup> The second limitation is the absence of Type II IH in female cases. Another limitation is the lack of a gold standard imaging method that can be compared in the diagnosis of IH.<sup>[7,9,13]</sup>

## CONCLUSION

US imaging provides a reliable way to accurately detect and characterize IH of the abdominal wall. According to our results, the US can be performed easily and quickly for the detection of IH without exposure to the radiation risk of CT. It can also facilitate the planning of surgical intervention in IH by providing anatomical information.

## Financial support and sponsorship

Nil.

## Conflicts of interest

There are no conflicts of interest.

## REFERENCES

- Heger P, Feißt M, Krisam J, Klose C, Dörr-Harim C, Tenckhoff S, *et al.* Hernia reduction following laparotomy using small stitch abdominal wall closure with and without mesh augmentation (the HULC trial): Study protocol for a randomized controlled trial. *Trials* 2019;20:738.
- Jairam AP, López-Cano M, Garcia-Alamino JM, Pereira JA, Timmermans L, Jeekel J, *et al.* Prevention of incisional hernia after midline laparotomy with prophylactic mesh reinforcement: A meta-analysis and trial sequential analysis. *BJS Open* 2020;4:357-68.
- Karampinis I, Lion E, Grilli M, Hetjens S, Weiss C, Vassilev G, *et al.* Correction to: Trocar site hernias in bariatric surgery—an underestimated issue: A qualitative systematic review and meta-analysis. *Obes Surg* 2020;30:2860.
- Kokotovic D, Bisgaard T, Helgstrand F. Long-term recurrence and complications associated with elective incisional hernia repair. *JAMA* 2016;316:1575-82.
- Saleh S, Plymale MA, Davenport DL, Roth JS. Risk-assessment score and patient optimization as cost predictors for ventral hernia repair. *J Am Coll Surg* 2018;226:540-6.
- Bosanquet DC, Ansell J, Abdelrahman T, Cornish J, Harries R, Stimpson A, *et al.* Systematic review and meta-regression of factors affecting midline incisional hernia rates: Analysis of 14,618 patients. *PLoS One* 2015;10:e0138745.
- Baucom RB, Beck WC, Phillips SE, Holzman MD, Sharp KW, Nealon WH, *et al.* Comparative evaluation of dynamic abdominal sonography for hernia and computed tomography for characterization of incisional hernia. *JAMA Surg* 2014;149:591-6.
- Cherla DV, Viso CP, Moses ML, Holihan JL, Ko TC, Kao LS, *et al.* Clinical assessment, radiographic imaging, and patient self-report for abdominal wall hernias. *J Surg Res* 2018;227:28-34.
- Beck WC, Holzman MD, Sharp KW, Nealon WH, Dupont WD, Poulouse BK. Comparative effectiveness of dynamic abdominal sonography for hernia vs. computed tomography in the diagnosis of

- incisional hernia. *J Am Coll Surg* 2013;216:447-511.
10. Kroese LF, Sneiders D, Kleinrensink GJ, Muysoms F, Lange JF. Comparing different modalities for the diagnosis of incisional hernia: A systematic review. *Hernia* 2018;22:229-42.
  11. Rosin D. Prevention of incisional hernia in midline laparotomy with onlay mesh: A randomized clinical trial. *World J Surg* 2014;38:2231-2.
  12. Young J, Gilbert AI, Graham MF. The use of ultrasound in the diagnosis of abdominal wall hernias. *Hernia* 2007;11:347-51.
  13. den Hartog D, Dur AH, Kamphuis AG, Tuinebreijer WE, Kreis RW. Comparison of ultrasonography with computed tomography in the diagnosis of incisional hernias. *Hernia* 2009;13:45-8.
  14. Ciscar A, Badia JM, Novell F, Bolívar S, Mans E. Incidence and risk factors for trocar-site incisional hernia detected by clinical and ultrasound examination: A prospective observational study. *BMC Surg* 2020;20:330.
  15. Björk D, Cengiz Y, Weisby L, Israelsson LA. Detecting incisional hernia at clinical and radiological examination. *Surg Technol Int* 2015;26:128-31.
  16. Bloemen A, van Dooren P, Huizinga BF, Hoofwijk AG. Comparison of ultrasonography and physical examination in the diagnosis of incisional hernia in a prospective study. *Hernia* 2012;16:53-7.
  17. Fang L, Chen L, Wang WP, Chen Y, Pang Y, Qiu ZY, *et al.* Diagnostic value of automated 3D ultrasound for incisional hernia. *Ultrasound Med Biol* 2014;40:1966-72.
  18. Wang X, He K, Zhu Y, Fu X, Huang Z, Ding R, *et al.* Use of shear wave elastography to quantify abdominal wall muscular properties in patients with incisional hernia. *Ultrasound Med Biol* 2020;46:1651-7.
  19. Chaudhry A, Fernandez-Moure JS, Shajudeen PS, Van Eps JL, Cabrera FJ, Weiner BK, *et al.* Characterization of ventral incisional hernia and repair using shear wave elastography. *J Surg Res* 2017;210:244-52.