



Available online at [www.sciencedirect.com](http://www.sciencedirect.com)

ScienceDirect

journal homepage: [www.e-jds.com](http://www.e-jds.com)



Original Article

# Prevention and early management of carotid blowout syndrome for patients receiving head and neck salvage boron neutron capture therapy (BNCT)

Tien-Li Lan <sup>a</sup>, Feng-Chi Chang <sup>b</sup>, Chun-Wei Wang <sup>c</sup>,  
Kazuyo Igawa <sup>d</sup>, Szu-Hsien Wu <sup>e</sup>, Wen-Liang Lo <sup>f\*</sup>,  
Yi-Wei Chen <sup>a\*\*</sup>

<sup>a</sup> Division of Radiotherapy, Department of Oncology, Taipei Veterans General Hospital, Taipei, Taiwan

<sup>b</sup> Department of Radiology, Taipei Veterans General Hospital, Taipei, Taiwan

<sup>c</sup> Division of Radiotherapy, Department of Oncology, Taiwan University Hospital, Taipei, Taiwan

<sup>d</sup> Neutron Therapy Research Center, Okayama University, Okayama, Japan

<sup>e</sup> Division of Plastic and Reconstructive Surgery, Taipei Veterans General Hospital, Taipei, Taiwan

<sup>f</sup> Division of Oral and Maxillofacial Surgery, Department of Stomatology, Taipei Veterans General Hospital, Taipei, Taiwan

Received 14 December 2020; Final revision received 28 December 2020

Available online 7 January 2021

## KEYWORDS

Boron neutron capture therapy;  
Carotid blowout syndrome;  
Head and neck cancer;  
Quality of life;  
Recurrence

**Abstract** *Background/purpose:* The incidence rate of oral and pharyngeal cancers in Taiwan has increased gradually over the past few decades. The standard treatment strategy for oral and pharyngeal cancers includes surgery or radiotherapy, with concurrent chemotherapy in certain types of tumors. Unfortunately, in-field recurrence is sometimes inexorable. Furthermore, re-irradiation of the recurrence site may cause severe complications due to the tolerance of normal tissue to radiation therapy. One fatal complication is carotid blowout syndrome (CBS). Boron neutron capture therapy (BNCT) is a new modality of radiation therapy, which is also mentioned as targeted radiotherapy. It is a feasible treatment that has the potential to spare normal tissue from being damaged by irradiation while simultaneously treating the primary tumor. In this presentation, we will share our experience with BNCT in treating recurrent head and neck cancers, as well as the prevention and management of CBS.

\* Corresponding author. Division of Oral and Maxillofacial Surgery, Department of Stomatology, Taipei Veterans General Hospital, No. 201, Sec. 2, Shi-Pai Rd., Taipei, 112, Taiwan.

\*\* Corresponding author. Division of Radiotherapy, Department of Oncology, Taipei Veterans General Hospital, No. 201, Sec. 2, Shi-Pai Rd., Taipei, 112, Taiwan.

E-mail addresses: [wlo@vghtpe.gov.tw](mailto:wlo@vghtpe.gov.tw) (W.-L. Lo), [chenyw@vghtpe.gov.tw](mailto:chenyw@vghtpe.gov.tw) (Y.-W. Chen).

<https://doi.org/10.1016/j.jds.2020.12.013>

1991-7902/© 2021 Association for Dental Sciences of the Republic of China. Publishing services by Elsevier B.V. This is an open access article under the CC BY-NC-ND license (<http://creativecommons.org/licenses/by-nc-nd/4.0/>).

**Materials and methods:** We evaluated 4 patients with head and neck cancers treated by BNCT in Taiwan. All patients had undergone surgery previously and had received postoperative concurrent chemoradiotherapy.

**Results:** The 4 patients in this study were diagnosed with head and neck malignancies. The median follow-up period after the first course of BNCT was 15.1 months. After BNCT, 2 patients developed impending CBS, and 1 of them died. The remaining 3 patients survived until the last date of follow-up.

**Conclusion:** Pre-BNCT carotid artery evaluation through computed tomography angiography and early intervention if necessary is crucial when treating patients with recurrent head and neck cancers by BNCT.

© 2021 Association for Dental Sciences of the Republic of China. Publishing services by Elsevier B.V. This is an open access article under the CC BY-NC-ND license (<http://creativecommons.org/licenses/by-nc-nd/4.0/>).

## Introduction

The incidence of oral and pharyngeal cancers in Taiwan has increased gradually over the past few decades. Annual newly diagnosed cases increased from 5458 in 2007 to 7797 in 2017, based on data released by the Ministry of Health and Welfare in Taiwan.<sup>1</sup> The standard treatment for oral and pharyngeal cancers includes surgery for early-stage or locally advanced tumors. Definitive radiotherapy with concurrent chemotherapy is also considered in certain types of tumors. For patients undergoing surgery, postoperative radiotherapy is also indicated if the pathology shows positive surgical margins, positive lymph node metastases with extranodal extension, or other adverse features if a higher rate of recurrence is expected.<sup>2</sup> Therefore, radiotherapy plays an irreplaceable role in the treatment of oral and pharyngeal cancers.

Boron neutron capture therapy (BNCT) is a new modality of radiation therapy. It is a binary treatment modality that includes intravenous injection of a boron-containing drug and neutron irradiation of the tumor site after adequate uptake of the boron-containing drug by the tumor. Following a neutron fission reaction due to neutron irradiation of the boron-10 particle, an  $\alpha$ -particle and a rebounding lithium particle are ejected. Based on previous studies, the length of the  $\alpha$ -particle, which is the main source of radiation damage, is approximately 9  $\mu\text{m}$ .<sup>3</sup> As we know, the average diameter of a single cell is approximately 10  $\mu\text{m}$ . We speculate that the radiation damage by BNCT is limited to the cells with a high boron-containing-drug uptake and that nearby normal tissue damage is minimized.

As mentioned above, most patients with head and neck cancers receive radiation therapy. Unfortunately, in-field recurrence is sometimes inexorable. Re-irradiation of the recurrence site may cause severe complications due to the normal tissue dose limitation caused by radiation therapy. One fatal complication is carotid blowout syndrome (CBS). Even though the incidence rate is relatively low for re-irradiated head and neck cancers (around 2–10%),<sup>4,5</sup> it is still one of the priority issues for which medical experts should take extra caution when making decisions for salvage treatment of recurrent tumors due to its high mortality rate. Previous studies have shown CBS related

mortality to range from 3% to 50%,<sup>5–7</sup> which is a wide range, considering the variable approaches and techniques available.<sup>8</sup> Thus, it has been a difficult issue regarding salvage treatment for recurrent head and neck cancers. BNCT, which was described in the previous paragraph, is a feasible treatment modality that has the potential to spare normal tissues from being damaged by irradiation, while simultaneously treating the primary tumor. In this article, we investigate the factors related to post-BNCT CBS and urge the importance of pre-BNCT carotid evaluation and intervention when necessary.

## Materials and methods

Following the first treatment of BNCT in Taiwan, Taipei Veterans General Hospital (TPEVGH) started treating using a Tsing-Hua Open Pool Reactor (THOR) as a reliable source of neutrons, which are required for the BNCT treatment.<sup>9</sup> As CBS is a life-threatening event that is highly related to previous treatment, computed tomography angiography (CTA) was performed for carotid artery evaluation, especially for patients with a history of radiotherapy. The type of CBS is categorized based on previous articles.<sup>10</sup> Threatened CBS (Type 1) is described with carotid artery exposure with image studies, or with areas of arterial wall disruption with vascular studies. Impending CBS (Type 2) involves limited bleeding episodes that can be controlled temporarily by applying pressure. Carotid system hemorrhage (Type 3) implies active bleeding or carotid rupture, which is crucial if immediate vascular intervention is not performed.

## Pre-BNCT preparation

BNCT is a binary method, with a boron-10 containing drug administered and ideally accumulated in the tumor. Thermal neutrons and epithermal neutrons produced by the nuclear reactor will then irradiate the tumor site. The tumor eradication effect of BNCT is mainly achieved by the boron capture reaction, as boron-10 nuclear fission generates an  $\alpha$ -particle ( $^4\text{He}$ ) and recoiling lithium ( $^7\text{Li}$ ), with energy of about 2.33 MeV deposited. Borono-L-phenylalanine (BPA), a boron-containing drug widely used in the field of BNCT, was designed to be the boron-10 carrier in this

study. It has the advantage of low toxicity, and with its structure being similar to that of L-tyrosine, it can be massively absorbed by the tumor through the L-type amino acid transporter 1, which is highly expressed on the surface of human tumors.

All patients received 4-borono-2-18F-fluoro-phenylalanine-positron emission tomography (FBPA-PET) before salvage BNCT was performed (Fig. 1). By binding radioisotope fluorine-18 to BPA, the distribution of F-BPA can be tracked, and thus we were able to calculate the relative concentration between the tumor, blood, and normal tissue by the standard uptake value (SUV).

### BNCT on-site treatment schedule

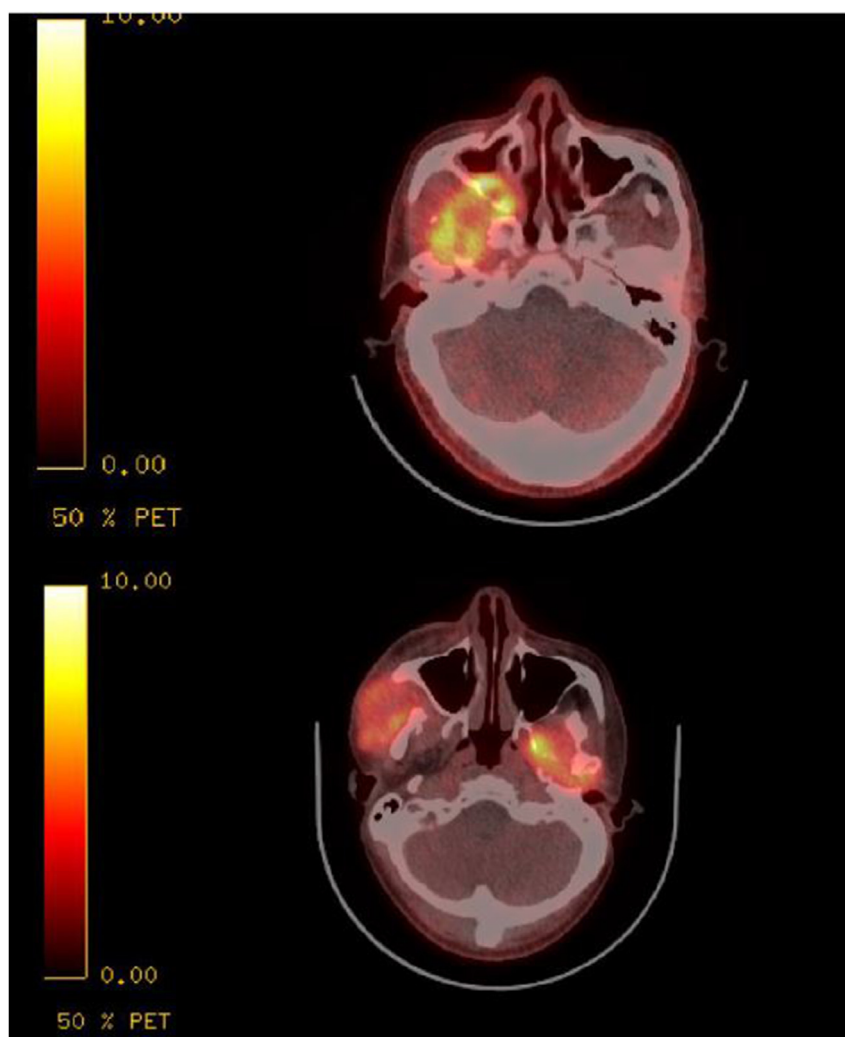
On the day of BNCT, the patient will be sent to the National Tsing Hua University Open Pool Reactor (THOR). THOR is a uranium-235 circulating pool reactor located in the compass of Tsing Hua University. The standard power of THOR is

approximately 2.0 MW, and the standard neutron flux meets the requirements of BNCT ( $>10^9$  n/cm<sup>2</sup>s). Before irradiation, the patient will receive continuous intravenous BPA infusion. The infusion rate is based on the experience of several Japanese studies,<sup>11</sup> which is 180 mg/kg of body weight per hour for 2 h before irradiation, and continued infusion with 90 mg/kg of body weight per hour during the irradiation time, around 30 min. With this infusion strategy, the serum BPA concentration likely ranges between 25 and 35 ppm.

All patients in our study were followed up until August 31, 2020, or the date the patient died. In our study, the primary outcome was whether the patient developed CBS, with impending CBS categorized as a positive finding.

### Patients

We evaluated 4 patients with head and neck cancers treated by BNCT in Taiwan. The patient profile is



**Figure 1** 4-borono-2-18F-fluoro-phenylalanine-positron emission tomography (FBPA-PET) image. Compared to fluorodeoxyglucose (FDG)-PET image, the normal brain has fewer uptake of the radioactive 18-F, which helps distinguish between the tumor and normal tissue. Tumor to normal tissue (TN) ratio and tumor to blood (TB) ratio will be obtained by this study, and the National Tsing Hua University Open Pool Reactor (THOR) planning system will calculate the dose distribution based on the dose constraint and treatment angle we define.

summarized in Table 1. All patients had undergone surgery previously and had received postoperative concurrent chemoradiotherapy. The pathology of all four primary tumors was squamous cell carcinoma. Further FBPA evaluation for calculation of tumor-to-blood ratio (TB ratio) and tumor-to-normal tissue ratio (TN ratio) was performed at the Department of Nuclear Medicine in TPEVGH. BNCT treatment was approved by the institutional review board (IRB) of TPEVGH and Taiwan's Food and Drug Administration (TFDA). A multidisciplinary discussion was conducted to evaluate the potential risks and benefits of the patients receiving BNCT.

## Results

The 4 patients in this study were diagnosed with head and neck malignancies. The median follow-up period after the first course of BNCT was 15.1 months (range, 5.6–36 months). After BNCT, 2 patients developed impending CBS, and 1 of them died (Fig. 2). The remaining 3 patients survived until the last date of follow-up (Table 4).

The second patient received 2 courses of external beam radiotherapy and 2 courses of BNCT. His history of head and neck cancer goes back to January 2011, when right cheek squamous cell carcinoma was discovered. A second primary diagnosis of right buccal squamous cell carcinoma was made in 2012, and a third primary diagnosis of lower gingiva squamous cell carcinoma in 2016. He had received two courses of concurrent chemoradiotherapy, first for the second primary right buccal tumor with 6600 cGy in 33 fractions, and second for the third primary lower gingiva tumor and left neck lymphadenopathy with 6000 cGy in 30 fractions. The accumulated dose to the right carotid artery was 8932 cGy. Fourth, primary carcinoma of the right zygomatic region was found in July 2017, but previous high-dose radiotherapy made it impossible for the patient to repeat further irradiation. He was then administered for salvage BNCT treatment. The first BNCT treatment was performed in September 2017. PET images three months after the BNCT showed marked regression of the tumor. Recurrent tumors were identified over the right tongue and oropharyngeal region in 2019. A second BNCT was then performed in May 2019. The dosage to the carotid artery through the 2 courses of BNCT was 6.69 GyE (Gray equivalent) and 6.79 GyE, respectively. Using an alpha to beta ratio of 3, the equivalent dose to 2 Gy per fraction (EQD2) was roughly 12.97 Gy and 13.29 Gy. This resulted in a total dose of over 11,550 cGy to the carotid artery. With the high

accumulated dosage to the carotid artery, the patient underwent bimonthly CTA for carotid artery evaluation. Impending CBS was noticed in November 2019, and embolization was performed to prevent further progression of CBS. Tri-monthly CTA was continued to evaluate carotid artery patency and tumor response to BNCT. On the date of the last follow-up in June 2020, CTA revealed that the tumor was in stable control, and 40% in-stent and proximal marginal restenosis was revealed.

The median age of the patients receiving BNCT for recurrent head and neck cancer was 58 years (range, 52–74 years). The medium tumor to blood ratio (TB ratio) was 4.01 (range, 2.67–5.2), including the six tumors irradiated in 4 patients). The medium tumor to normal tissue ratio (TN ratio) was 4.14 (range, 2.78–6.85) (Table 2). The medium dose to the tumor by previous external beam therapy was 8299 cGy (range 6600 to 12,600 cGy), with one patient receiving 2 courses of radiotherapy prior to BNCT. The mean dose to the carotid artery by external beam radiotherapy was 7390 cGy (range 6205–8932 cGy), including one patient receiving 2 courses of radiotherapy, and one patient not being able to be evaluated because they had received their previous treatment at another hospital (Table 3). The mean percentage of tumor encasement to the carotid artery was 63.75% (range 0%–100%), and 3 out of 4 patients developed CBS after BNCT. The mean interval from the previous radiotherapy to BNCT was 20.6 months (range, 6–35 months) for 5 BNCT treatments. The mean average BNCT dose to the primary tumor was 24.22 Gy-E (range 15.14–32.01 Gy-E) for 6 irradiated sites. The mean maximum dose to the carotid artery by BNCT was 7.22 Gy-E (range 6.69–7.7 Gy-E). Patients 1 and 2 received intervention after BNCT as vascular imaging showed impending CBS (Fig. 2), while for patients 3 and 4, interventions for the prevention of CBS before BNCT were done (Fig. 3).

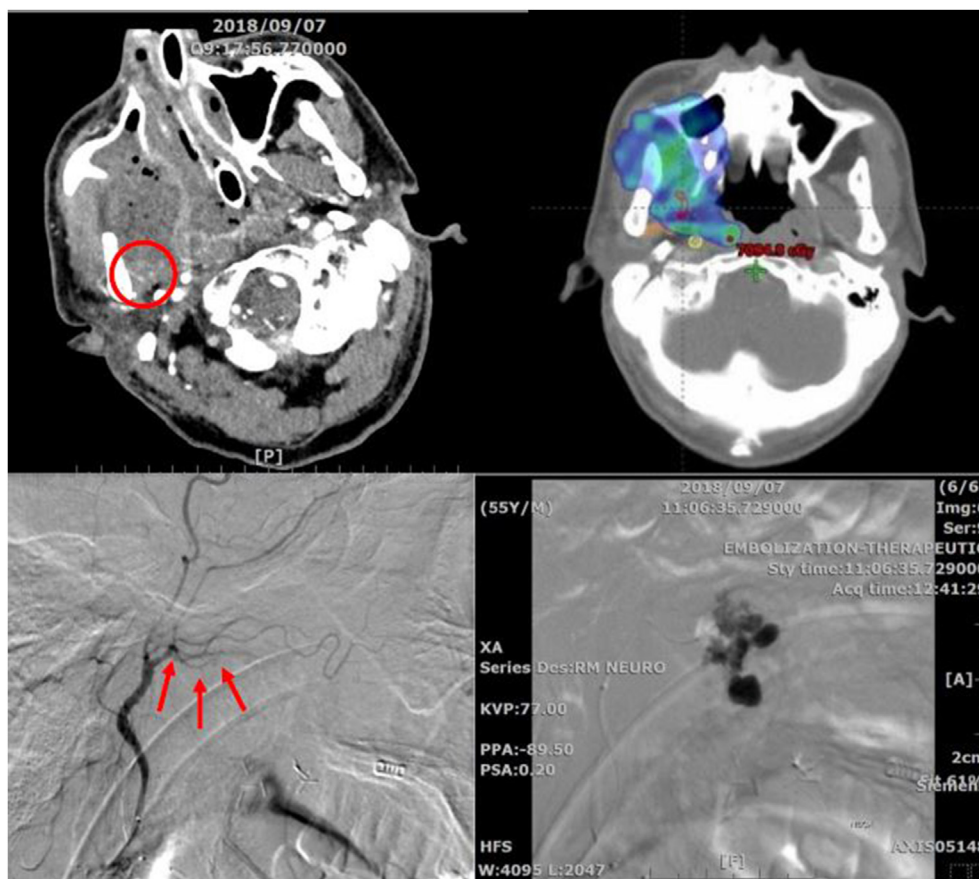
## Discussion

In March 2017, Taipei Veterans General Hospital triggered a partnership with the Nuclear Science and Technology Development Center of the National Tsing-Hua University. Since there was increasing interest in BNCT worldwide during that time, Taiwanese radiation oncology specialists clinched the opportunity to collaborate with Japanese clinicians and researchers, since Japan is the most experienced country not only by case numbers but also in conducting several basic studies about BNCT. As thermal neutrons and epithermal neutron beams are necessary in

**Table 1** Patient characteristics.

Patient No.	Age	Gender	Primary diagnosis	Histology	Previous treatment
1	54	M	Buccal	SqCC	OP + CCRT
2	52	M	Right zygomatic	SqCC	OP + CCRT
2	52	M	Right zygomatic	SqCC	OP + CCRT
3	74	M	Hypopharyngeal	SqCC	IC + CCRT + TLM + IT
4	52	M	Supraglottic	SqCC	OP + IC + CCRT + IT

M: Male, SqCC: squamous cell carcinoma, OP: operation, CCRT: concurrent chemoradiotherapy, IC: induction chemotherapy, TLM: transoral laser microsurgery, IT: immune therapy.



**Figure 2** (Left upper) Image study showed huge necrotic tumor in the right maxillary sinus and right masticator space. (Right upper) Contouring of the right internal carotid artery (Yellow), right external carotid artery (Orange), and right internal maxillary artery (Red). Showing previous high dose irradiated to the right internal maxillary artery and risk of carotid blowout syndrome (CBS). (Lower) Embolization procedure showed damaged right internal maxillary artery. Active vascular extravasation was noticed. 15% N-butyl cyanoacrylate (NBCA) mixture was injected for occlusion of the branch of internal maxillary artery.

**Table 2** BNCT parameters and previous radiotherapy summary.

Patient No.	TN ratio	TB ratio	RT dose to primary (cGy)	RT end date	BNCT date	BNCT dose to primary tumor (Dmean) (Gy-w)
1	5.00	3.07	6600	20180126	20180803	29.12
2	R 3.9 L 3.25	R 5.2 L 4.33	6600 + 6000 <sup>a</sup>	20120228/20161014 <sup>a</sup>	20170922	R31.62/L32.01
2	6.85	5.63	6600 + 6000 <sup>a</sup>	20120228/20161014 <sup>a</sup>	20190506	15.14
3	3.04	3.25	7000	20160519	20190426	17.82
4	2.78	2.67	6996	20180423	20191225	19.62

BNCT: boron neutron capture therapy, TN ratio: tumor to normal tissue ratio, TB ratio: tumor to blood ratio, RT: radiotherapy, R: right side, L: left side, Dmean: mean dose, Gy-w: total weighted dose.

<sup>a</sup> Patient 2 received 2 courses of radiotherapy both in the buccal region.

managing this binary treatment, the Tsing-Hua Open Pool reactor (THOR) was regarded as a perfect source of neutron irradiation. As of November 2020, with the collaboration of TPEVGH and THOR, more than 170 patients have received BNCT in Taiwan.

BNCT has recently gained attention in salvage treatment for recurrent head, neck, and brain tumors.<sup>12,13</sup> In Japan, BNCT has been approved as a standard treatment modality

and has been included in the national health insurance since May 2020. More and more BNCT specialist hospitals were built and are constantly leading development both in the number of patients treated and in basic research studies. The advantage of using BNCT as a salvage treatment is its binary feature. As the tumor has a higher uptake of the boron-containing drug compared to normal organs, BNCT is the ideal “targeted radiotherapy” that can be

**Table 3** Carotid artery dose and intervention.

Patient No.	Ratio of carotid artery circumference surrounded by tumor	Type of CBS	Type of intervention Date of intervention	RT dose to carotid artery (cGy) Date of the end of RT	BNCT dose to CA (Dmax) (Gy-w) Date of BNCT	RT to BNCT Interval (month)
1	100%	impending	Embolization 2018/9/27, 10/11	7032.6 2018/1/26	7.46 2018/8/3	6
2	0%	impending	Embolization of right ECA, stent on right ICA/CCA 2019/12/11	8932 (6554 + 2378) 2012/2/28 2016/10/14	6.69 (By TB 4.75) <sup>a</sup> 2017/9/22	11
2	0%	impending	Embolization of right ECA, stent on right ICA/CCA 2019/12/11	8932 (6554 + 2378) 2012/2/28 2016/10/14	6.79 2019/5/6	31
3	83%	None	prevention, embolization 2019/2/23	N/A 2016/5/19	7.48 2019/4/26	35
4	72%	impending	prevention, embolization 2019/12/24 Stent 2020/2/14, 3/6	6205 2018/4/23	7.7 2019/12/25	20

CBS: carotid blowout syndrome, ECA: external carotid artery, ICA internal carotid artery, CCA: common carotid artery, N/A: not applicable.

<sup>a</sup> Dose to carotid artery was not directly calculated during the first course of BNCT, and we estimated by using the TB ratio and calculated from the dose to primary tumor.

**Table 4** Patient follow up.

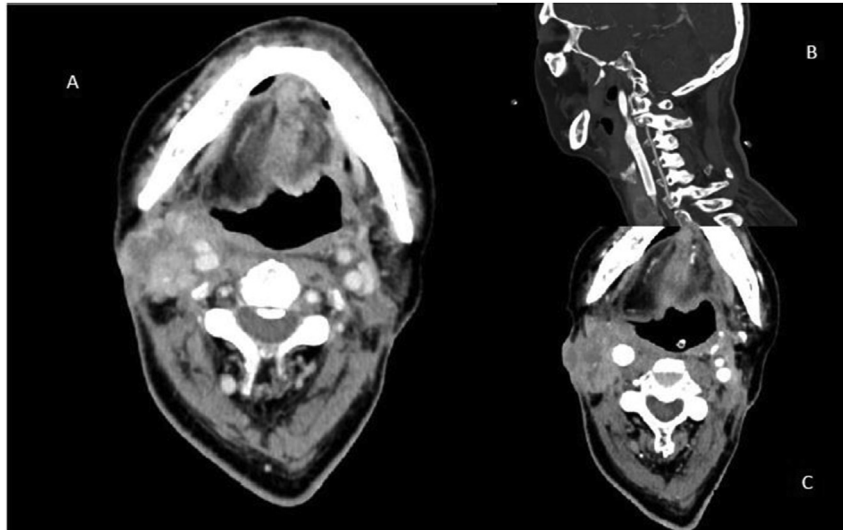
Patient No.	Patient expired date	Patient death related to CBS	Post BNCT follow up (months)
1	20190616	Yes	10.43
2	Alive	N/A	36
2	Alive	N/A	16.47
3	Alive	N/A	5.6
4	Alive	N/A	8.4

executed even with the previous treatment causing damage to the organs alongside. Since the treatment benefit is based on the concentration gradient between the tumor and the normal tissue, the development of boron-containing drugs is what BNCT researchers are focusing on.

While BNCT is ushering in the new radiotherapy era, complications caused by BNCT should also be taken into serious consideration. Carotid blowout syndrome, usually related to previous surgery or radiotherapy, is a fatal adverse effect that was not so infrequent from our experience. The rationale for developing CBS includes stripping of the carotid sheath during neck dissection, or radiation-induced free radical damage to the adventitial layer of the carotid artery.<sup>10</sup> The adventitial layer comprises approximately 80% of the blood supply to the walls of the carotid artery, and injuries to it may cause pseudoaneurysm formation or necrosis of the arterial wall. Even though CBS may not occur during the treatment duration, aggressive treatments are usually the leading cause of the event.

The importance of this review is that carotid artery evaluation was not regularly conducted before BNCT in most institutes. Previous Japanese studies have found that the incidence rate of CBS in patients who receive BNCT of the head and neck region is about 5%.<sup>14,15</sup> In a systemic review involving 27 published articles and more than 1500 patients with salvage re-irradiation for head and neck cancers, an incidence rate of 2.6% was reported, with 76% of the CBS episodes being fatal.<sup>4</sup> A multi-institutional study in Japan surveyed 72 patients with recurrent head and neck cancers with hypo-fractionated stereotactic body radiotherapy. 12 patients developed CBS (16.7%).<sup>16</sup> In this article, it was concluded that all of the patients who developed CBS had tumor invasion to the carotid artery of more than 180 degrees of the circumference. This finding is very useful when classifying the risk of CBS and the necessity for prevention. Of the 4 patients we reported with recurrent head and neck cancers receiving BNCT, 1 patient with total invasion of the carotid artery without carotid artery evaluation before BNCT developed CBS, and further embolization was not sufficient to cease disease progression, which eventually resulted in fatal carotid hemorrhage. Two patients received preventive embolization before BNCT treatment, and both were able to avoid life-threatening CBS. Based on our experience, we suggest that it is important to perform carotid artery evaluation before BNCT treatment.

In our institute, as we had the experience of CBS in the past, consultation for carotid artery evaluation before BNCT will be conducted routinely, and intervention should be arranged if the patient is at risk of developing CBS.<sup>17,18</sup> In our



**Figure 3** Contrast enhanced computed tomography (CT) image and post stent insertion contrast enhanced CT image of patient 3. (A) Tumor encasement of right carotid artery, high risk of CBS if aggressive treatment is planned. (B) Sagittal view of CT image after stent graft was successfully inserted. (C) Axial view showing the image after stent insertion.

experience, in routine pre-BNCT surveys, several cases of impending CBS due to damaged vasculature or pseudoaneurysms were accidentally revealed. Early embolization was then performed when the risk was still tolerable, and thus the patient had the chance of receiving BNCT in a more comfortable disease status. Although no huge data can be shown to prove the exact benefit of pre-BNCT carotid artery evaluation, we can potentially upregulate the limitation dose of the ipsilateral carotid artery and push the dose to the primary tumor to a higher level. This way, we can likely contribute to a higher response rate.

BNCT is a new modality for salvage treatment of recurrent head and neck cancers. However, CBS is a devastating adverse effect. Its risk is increased among patients who have previously undergone surgery or received radiotherapy as well as chemotherapy. We emphasize the importance of performing pre-BNCT carotid artery evaluation through CTA and early intervention if necessary. This may result in not only improved treatment safety but also higher dose tolerance to the treated area.

## References

1. Taiwan Ministry of Health and Welfare. *Cancer registry annual report of Taiwan*. 2017.
2. Petersen JF, Timmermans AJ, van Dijk B, et al. Trends in treatment, incidence, and survival of hypopharyngeal cancer: a 20-year population-based study in The Netherlands. *Eufos* 2018;275:181–9.
3. Locher GL. Biological effects and therapeutic possibilities of neutrons. *Am J Roentgenol Radium Ther* 1936;36:1–13.
4. McDonald MW, Moore MG, Johnstone PA. Risk of carotid blowout after reirradiation of the head and neck: a systematic review. *Int J Radiat Oncol Biol Phys* 2012;82:1083–9.
5. Cohen EE, Rosine D, Haraf DJ, et al. Phase I trial of tirapazamine, cisplatin, and concurrent accelerated boost reirradiation in patients with recurrent head and neck cancer. *Int J Radiat Oncol Biol Phys* 2007;67:678–84.
6. Heller KS, Strong EW. Carotid arterial hemorrhage after radical head and neck surgery. *Am J Surg* 1979;138:607–10.
7. Roh JL, Suh DC, Kim MR, et al. Endovascular management of carotid blowout syndrome in patients with head and neck cancers. *Oral Oncol* 2008;44:844–50.
8. Chiesa E, Betances R, Osorio V, et al. Carotid blowout syndrome in patients treated by larynx cancer. *Braz J Otorhinolaryngol* 2017;83:653–8.
9. Liu YH, Huang CK, Tsai PE, et al. BNCT epithermal neutron beam mapping by using indirect neutron radiography. *Nucl Technol* 2009;168:354–8.
10. Suárez C, Fernández-Alvarez V, Hamoir M, et al. Carotid blowout syndrome: modern trends in management. *Canc Manag Res* 2018;10:5617–28.
11. Ono K, Masunaga S, Kinashi Y. Neutron irradiation under continuous BPA injection for solving the problem of heterogeneous distribution of BPA. *Int Congr Ser* 2006:27–30.
12. Lan TL, Chou FI, Chen YW, et al. Using salvage boron neutron capture therapy (BNCT) for recurrent malignant brain tumors in Taiwan. *Appl Radiat Isot* 2020;160:109105.
13. Lee JC, Chuang KS, Chen YW, et al. Preliminary dosimetric study on feasibility of multi-beam boron neutron capture therapy in patients with diffuse intrinsic pontine glioma without craniotomy. *PLoS One* 2017;12:e0180461.
14. Aihara T, Hiratsuka J, Ishikawa H, et al. Fatal carotid blowout syndrome after BNCT for head and neck cancers. *Appl Radiat Isot* 2005;106:202–6.
15. Suzuki M, Kato I, Aihara T, et al. Boron neutron capture therapy outcomes for advanced or recurrent head and neck cancer. *J Radiat Res* 2014;1:146–53.
16. Yamazaki H, Ogita M, Himei K, et al. Carotid blowout syndrome in pharyngeal cancer patients treated by hypofractionated stereotactic re-irradiation using CyberKnife: a multi-institutional matched-cohort analysis. *Radiation Oncol* 2015;115:67–71.
17. Chang FC, Luo CB, Lirng JF, et al. Endovascular management of post-irradiated carotid blowout syndrome. *PLoS One* 2015;10:e0139821.
18. Lee CW, Yang CY, Chen YF, et al. CT angiography findings in carotid blowout syndrome and its role as a predictor of 1-Year survival. *Am J Neuroradiol* 2014;35:562–7.