

# Comparative study to evaluate bone loss during osteotomy using standard drill, bone trephine, and alveolar expanders for implant placement

Darpan Bhargava, Shaji Thomas, Ankit Pandey, Ashwini Deshpande, Sunil Kumar Mishra

Department of Implantology, Peoples University, Bhopal, Madhya Pradesh, India

## Abstract

**Statement of Problem:** Various osteotomy modalities seem to have an impact on the primary and secondary stability of the dental implant. The available literature lacks the comparison of various available osteotomy modalities used for the dental implant placement and its effects on the initial surgical bone removal.

**Purpose:** The purpose of this study is to compare and evaluate the osteotomy sites created using standard drill, bone trephine, and alveolar expanders for dental implant surgery.

**Materials and Methods:** The study was done on ten goat hemimandibles. Three osteotomy sites were prepared at the inferior border of the mandible using standard drill, trephine, and alveolar expander in each hemimandibles and the sites were subjected to cone-beam computed tomography (CBCT). The CBCT images obtained were compared for the amount of cortical bone and bone marrow loss at osteotomy sites in different techniques.

**Results:** The mean and standard deviation of loss of cortical bone with standard drills, trephines, and alveolar expanders was  $3.62 \pm 4.216 \times 10^{-2}$ ,  $3.6 \pm 4.681 \times 10^{-16}$  and  $3.15 \pm 7.071 \times 10^{-2}$ . At the middle-third region, the loss of marrow bone was  $3.38 \pm 7.88 \times 10^{-2}$ ,  $2.15 \pm 8.498 \times 10^{-2}$  and  $0.03 \pm 9.487 \times 10^{-2}$ , and at lower third region, it was  $2.3 \pm 4.714 \times 10^{-2}$ ,  $0.02 \pm 6.325 \times 10^{-2}$ , and 0.0, respectively.

**Conclusion:** CBCT images showed minimum bone loss with the use of alveolar expander which may be due to the lateral bone condensation rather the removal of the marrow. Trephine showed less marrow removal in comparison to the standard drill used for dental implant surgery.

**Keywords:** Alveolar expanders, dental implant, osteotomy, standard drill, trephine

**Address for correspondence:** Dr. Sunil Kumar Mishra, Department of Maxillofacial Prosthodontics and Implantology, Peoples College of Dental Sciences and Research Centre, Bhopal - 462 037, Madhya Pradesh, India.

E-mail: sunilmsr200@yahoo.co.in

**Received:** 03<sup>rd</sup> December, 2017, **Accepted:** 05<sup>th</sup> March, 2018

## INTRODUCTION

Stability of dental implants plays a crucial role for the successful osseointegration.<sup>[1]</sup> Primary stability of dental implants is influenced by quality and quantity of the bone,

implant morphology, surface texture of implant, and the surgical technique followed for implant placement.<sup>[2]</sup> Various surgical techniques are followed to increase the primary

Access this article online	
Quick Response Code:	Website: www.j-ips.org
	DOI: 10.4103/jips.jips_310_17

This is an open access journal, and articles are distributed under the terms of the Creative Commons Attribution-NonCommercial-ShareAlike 4.0 License, which allows others to remix, tweak, and build upon the work non-commercially, as long as appropriate credit is given and the new creations are licensed under the identical terms.

**For reprints contact:** reprints@medknow.com

**How to cite this article:** Bhargava D, Thomas S, Pandey A, Deshpande A, Mishra SK. Comparative study to evaluate bone loss during osteotomy using standard drill, bone trephine, and alveolar expanders for implant placement. J Indian Prosthodont Soc 2018;18:226-30.

stability of dental implants. The surgical techniques are preparing an undersized osteotomy site, implant placement without a surgical tap to prepare a threaded channel in the bone and by preventing lateral bone condensation with osteotomy instruments and countersinking.<sup>[3]</sup> Today, immediate loading of dental implants is very much popular and primary stability of implants at the time of insertion is a fundamental requirement for the successful osseointegration.<sup>[4]</sup>

Secure mechanical fastening of a dental implant with the surrounding bone provides clinically acceptable primary stability. The good implant primary stability at the time of implant surgery is positively associated with a successful implant integration (secondary stability) and a better long-term clinical outcome.<sup>[5]</sup> Javed *et al.*<sup>[6]</sup> suggested that both bone quality and quantity at the surgical site has its influence on the primary stability and overall success rate of dental implants. In general, judicious bone removal at the time of implant placement will offer better primary implant stability and thereby reliable osseointegration.

The present *in vitro* experimental study on animal model aims to evaluate the quantity of bone removed with the use of a standard drill, dental implant trephine, and alveolar bone expanders when used for creating the implant osteotomy for the placement of dental implants using cone-beam computed tomography (CBCT).

## MATERIALS AND METHODS

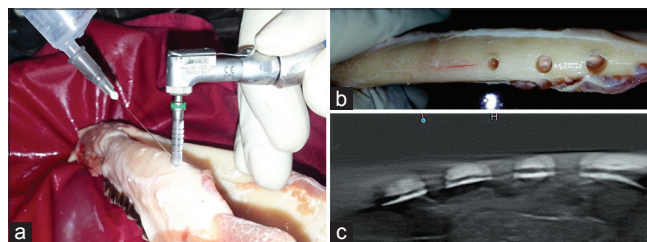
The prospective study was undertaken on the fresh goat mandible obtained from the goats slaughtered at the local butcher's shop for human consumption. The ethical clearance for the study was obtained from the Institutional Ethics Committee, People's College of Dental Sciences and Research Center, Bhopal. The study was performed on five goat mandibles within 1 h of the slaughter. The mandibles were hemisectioned and stabilized with the help of a handle on the table to prevent any movement during osteotomy. Three osteotomy sites at the lower border of mandible were created in each hemimandible. To standardize the procedure and to prevent any effects of osteotomy using one modality on the neighboring, an adequate care was taken to keep a safe distance 1.5 cm in between the different osteotomies. For the standard implant drill and bone trephines, an osteotomy site of 3.6 mm in diameter and 10 mm length was prepared. Since the nearest bone expander available was of 3.5 mm, osteotomy site of 3.5 mm in diameter and 10 mm in length was prepared with alveolar bone expander.

The sequential standard dental implant drills (Adin Dental Implant Systems Ltd.) run at 800 rpm on a reduction gear dental implant handpiece (20:1), powered by a standard physiodispenser with copious cold normal saline irrigation. The osteotomy site preparation started with a flame-shaped dental implant marking bur on the lower border of hemimandible followed by sequential drilling using progressive sized drills of diameters 2.0 mm, 2.8 mm, 3.2 mm, and finally with 3.6 mm to achieved a osteotomy site of 3.6 mm diameter with a depth of 10 mm (L10) [Figure 1a].

The sequential drilling with bone trephine (ARDS Implants) run at 800 rpm on a reduction gear dental implant handpiece (20:1), powered by a standard physiodispenser with copious cold normal saline irrigation. The osteotomy started with the pilot drill of 2 mm diameter to a depth 10 mm on the lower border of hemimandibles, followed by 2.8 mm and 3.6 mm diameter trephine to achieve osteotomy site of 3.6 mm diameter and 10 mm length [Figure 1a].

Osteotomy with bone expander was started with copious cold normal saline irrigation. Osteotomy sites were marked on the lower border of the hemimandibular bone using a flame-shaped dental implant marking bur followed by first 10-mm deep osteotomy site was created using a Ø2 mm standard implant pilot drill followed by sequential bone expansion using tapered screw type alveolar expanders in sequence of Ø3.2; >Ø3.4; >Ø3.5 till the final expansion of 3.5 mm diameter and length of 10 mm was achieved [Figure 1b]. Between the use of each expander, a pause for 10 s was given to achieve sufficient expansion of bone.

All the ten hemimandibles were subjected to CBCT (KODAK 9000 series, CARESTREAM, exposure – 68 KV, current – 8.00 mA, time – 10.80 s, total dose exposure – 167 mGy/cm<sup>2</sup>) for imaging to evaluate and compare the bone removed/condensed using drill, trephine, and alveolar expanders in the cortical and marrow region of the mandibles [Figure 1c].



**Figure 1:** (a) Preparation of osteotomy site, (b) prepared osteotomy site with various study modalities and linear fracture of cortical bone, (c) cone-beam computed tomography image of prepared osteotomy sites

The following parameters were recorded on the CBCT images:

1. Diameter of the bone removed/condensed at the cortical level
2. Bone marrow removed/condensed at the middle third and the lower third of the L10 osteotomy.

All the measurements were recorded as a linear distance on the midsagittal section of the osteotomy on the CBCT images using CS-3D Imaging Software 3.2.9 (Carestream Health Inc., Atlanta, GA). Data obtained were statistically analyzed using one-way ANOVA with *post hoc* Tukey test to evaluate intergroup variations.

**RESULTS**

The mean and standard deviation of bone removed or condensed at different levels using a standard implant drill, bone trephine, and screw type bone expanders is summarized in Table 1. The osteotomy created using bone expander Ø3.5/L10 showed minimal bone destruction at the cortical level and no marrow loss at the middle and lower third of the osteotomy. On gross inspection of the bone used for creating osteotomy, 90% samples showed a linear hairline cortical fracture in association with the expander screw osteotomy [Figures 1b and 2]. *Post hoc* Tukey’s test for intergroup comparison of bone destruction by different drills at various bone levels was summarized in Table 2. The intergroup comparisons showed statically significant bone loss at cortical level with the standard drill (*P* value  $2.71 \times 10^{-5}$ ) and trephine (*P* value  $2.71 \times 10^{-5}$ ) when compared to alveolar expander. Difference in bone loss with standard drill (mean ± standard deviation [SD]  $3.62 \pm 4.216 \times 10^{-2}$ ) and trephine (mean ± SD  $3.60 \pm 4.681 \times 10^{-16}$ ) at cortical level was found to be almost similar [Graph 1]. All the three modalities showed statistically significant difference in bone marrow loss at the middle-third level of the osteotomy, with alveolar expander causing minimal marrow loss (mean ± SD  $0.03 \pm 9.487 \times 10^{-2}$ ) and standard drill causing maximum marrow destruction (mean ± SD  $3.38 \pm 7.888 \times 10^{-2}$ ) [Graph 2]. Bone marrow loss at the lower third of the L10 osteotomy did not show any significant difference in the osteotomies created using the bone trephine and the alveolar expander screw (*P* = 0.594304). The transverse width as measured in the cortical bone and bone marrow to compare the three study modalities are illustrated in Figure 3a-d. Marrow destruction at lower third in the osteotomies created using the standard drill was maximum (mean ± SD  $2.3 \pm 4.714 \times 10^{-2}$ ) when compared with the bone trephine (mean ± SD  $0.02 \pm 6.325 \times 10^{-2}$ ) and the alveolar expander (mean ± SD  $0.00 \pm 0.00$ ) [Graph 3].

**Table 1: Mean and standard deviation of bone removed or condensed at different levels with various drills**


	Mean±SD		
	Cortical bone	Bone marrow	
		Middle third	Lower third
Standard drill (mm)	$3.62 \pm 4.216 \times 10^{-2}$	$3.38 \pm 7.888 \times 10^{-2}$	$2.3 \pm 4.714 \times 10^{-2}$
Trephine (mm)	$3.60 \pm 4.681 \times 10^{-16}$	$2.15 \pm 8.498 \times 10^{-2}$	$0.02 \pm 6.325 \times 10^{-2}$
Alveolar expanders (mm)	$3.15 \pm 7.071 \times 10^{-2}$	$0.03 \pm 9.487 \times 10^{-2}$	$0.00 \pm 0.00$

SD: Standard deviation

**Table 2: Post hoc Tukey’s test for intergroup comparison of bone destruction by different drills at various bone levels**

Intergroup comparison	<i>P</i>		
	Cortical bone	Marrow middle third	Marrow lower third
Standard drill (alveolar expanders)	$2.71 \times 10^{-5*}$	$2.71 \times 10^{-5*}$	$2.71 \times 10^{-5*}$
Standard drill (trephine)	0.619692	$2.71 \times 10^{-5*}$	$2.71 \times 10^{-5*}$
Trephine (alveolar expanders)	$2.71 \times 10^{-5*}$	$2.71 \times 10^{-5*}$	0.594304

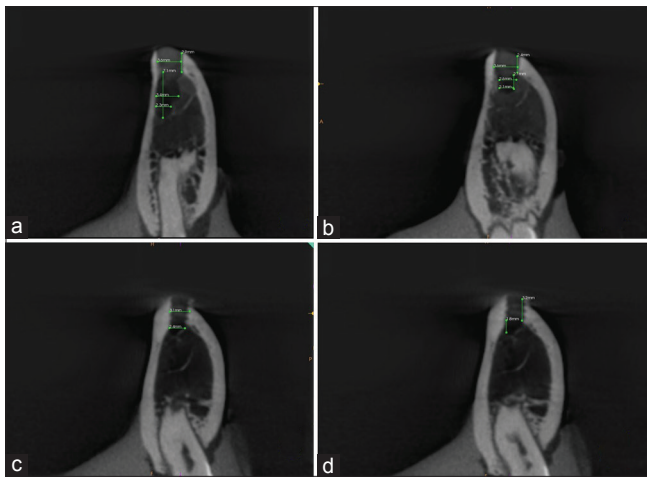
Significant differences were denoted in asterisk



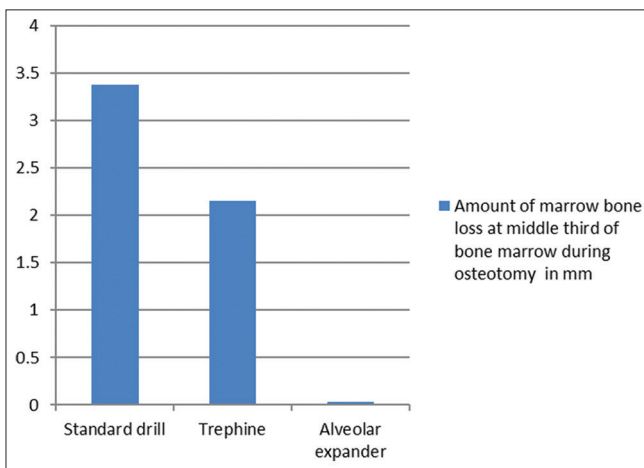
**Figure 2: Axial section of cone-beam computed tomography showing osteotomy sites and linear fracture neighboring the expander osteotomy**

**DISCUSSION**

The degree of osseointegration achieved in healthy bone is very important for the longterm success of dental implants.<sup>[7]</sup> The protocol for the rehabilitation with implant-supported prosthesis requires minimal surgical intervention.<sup>[8]</sup> Intraoperative surgical techniques such as bone condensing and undersizing the osteotomy improve bone density and increase the primary or mechanical stability of the dental implants. Conservative bone removal during the implant osteotomy offers adequate mechanical stability for the dental implants which in turn may offers higher rates of osseointegration.<sup>[6]</sup> The avoidance of excessive temperature generation during surgical drilling, so that there should be minimal damage to



**Figure 3:** (a) Evaluation of bone loss by standard drill, (b) evaluation of bone loss by trephine drill, (c) evaluation of cortical bone loss by alveolar expander, (d) evaluation of bone marrow loss by alveolar expander

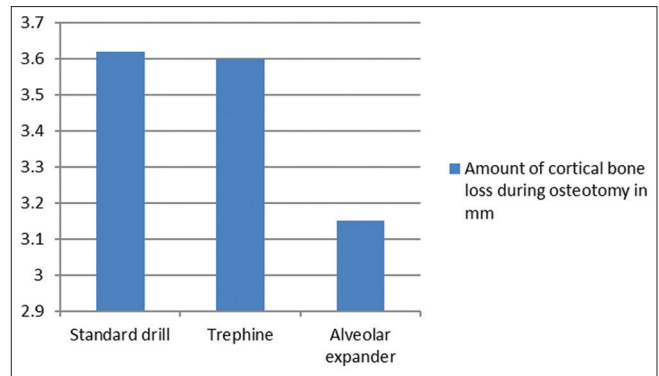


**Graph 2:** Amount of marrow bone loss at middle third of bone marrow during osteotomy

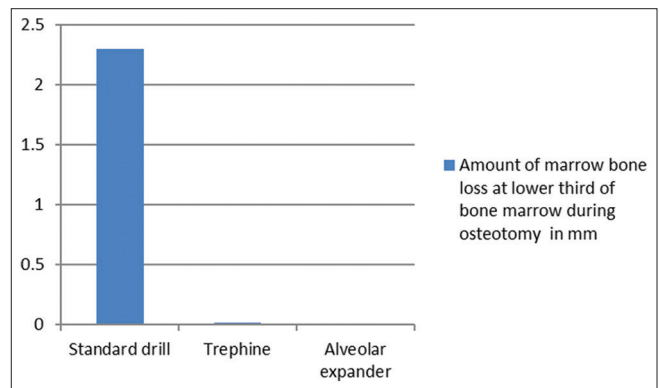
surrounding tissues is an important requisite for successful preparation of an implant osteotomy.<sup>[9]</sup>

This study evaluates the quantitative bone loss during implant osteotomy in the cortical region and bone marrow using a standard drill, bone trephine, and alveolar expanders. Many methods have been proposed to image implant osteotomy such as intraoral periapical films with grid, orthopantomogram, and DentaScan software applied to computed tomographic images and CBCT. CBCT was used for imaging in this study owing to its reliability for being applied at different clinical situations where the linear measurements between anatomical sites are required, such as preoperative assessment for dental implant.<sup>[10,11]</sup>

The standard drill and trephine drill of 3.6 mm diameter was used which demonstrated 3.6-mm bone loss in the cortical region of the specimens, and alveolar expanders of



**Graph 1:** Amount of cortical bone loss during osteotomy



**Graph 3:** Amount of marrow bone loss at lower third of bone marrow during osteotomy

size 3.5 mm (closest available size) was used which showed expansion of 3.1 mm in the cortical region. The expected expansion with the use of the alveolar expander (Ø3.5/L10) was 3.3 mm; the 0.2 mm difference observed was most probably compensated by the shear fracture observed adjacent to alveolar expander osteotomy site in 90% of the specimens. The extent of bone removal in cortical bone and bone marrow was more ruinous with standard drills and least damage was done with alveolar expanders.

Procedural observation with regard to the use of trephine for creating implant osteotomy which needs a highlight is the plugging of the trephine cutting edge and port with the dense cortical bone after the cortical osteotomy is completed. The osteotomy at the marrow after the cortical bone plug in the trephine cylinder and cutting-edge mimics a blunt cylinder performing the bone marrow condensation rather actual marrow removal. This phenomenon is evident from the bone loss pattern as seen on the CBCT images obtained using dental implant trephines used for the osteotomy.

The osteotomy created using screw type bone expander Ø3.5/L10 showed minimal bone destruction at the cortical level and no marrow loss at the middle and lower third of the osteotomy. The mean cortical expansion obtains

with bone expander was  $3.15 \pm 7.071 \times 10^{-2}$  mm, which was 0.35 mm less than the size of the final bone expander used (3.5 mm). This difference in the diameter of the osteotomy was compensated by a linear hairline cortical fracture associated with the expander screw osteotomy in 90% of the study specimens. The bone marrow destruction in the osteotomy procedure was found minimal using bone expanders. There was clear evidence of lateral condensation of the marrow than the actual removal on CBCT images in the middle and lower third of the osteotomy length. The average expansion observed in the middle third of the osteotomy length in the bone marrow was  $0.03 \pm 9.487 \times 10^{-2}$ . The lower third of the osteotomy in the marrow did not show any evidence of bone removal on CBCT images. From the cortical to the depth of the osteotomy in the marrow using screw type bone expanders, the general pattern of transition from conservative bone removal at the cortex to pure condensation at the greatest depth of the osteotomy was seen in all the study specimens.

The advantages of using a bone expander as a modality for dental implant osteotomy, when indicated, is that the alveolar expanders are less invasive and requires shorter time for rehabilitation,<sup>[12-15]</sup> whereas the drill relatively generates more heat which may cause bone necrosis and excessive bone loss during the healing phase of the implant. With the use of bone expanders, there is minimal trauma to the bone, which may have beneficial effects on the initial healing at the bone-implant interface.<sup>[14]</sup> Dental implant trephine has also shown to produce less bone loss when compared to the standard drill.<sup>[16]</sup> The limitations of the present study were that the study was done in *in vitro* animal model which does not simulate the exact oral conditions of the human and also the sample size is less, so same can be verified with more sample size in the human studies.

## CONCLUSION

The use of alveolar bone expanders has minimal bone loss at the osteotomy site. Expanders produce the undersized implant osteotomies as demonstrated in the present study. The bone removed was minimum with the use of alveolar expander which followed the principle of lateral bone condensation rather removal of the marrow. Alveolar bone expander seems to be more conservative for osteotomy and thus provide good primary stability and successful osseointegration of dental implants.

## Financial support and sponsorship

Nil.

## Conflicts of interest

There are no conflicts of interest.

## REFERENCES

- Swami V, Vijayaraghavan V, Swami V. Current trends to measure implant stability. *J Indian Prosthodont Soc* 2016;16:124-30.
- Shadid RM, Sadaqah NR, Othman SA. Does the implant surgical technique affect the primary and/or secondary stability of dental implants? A Systematic review. *Int J Dent* 2014;2014:204838.
- Turkyilmaz I, Tumer C, Ozbek EN, Tözüm TF. Relations between the bone density values from computerized tomography, and implant stability parameters: A clinical study of 230 regular platform implants. *J Clin Periodontol* 2007;34:716-22.
- Elias CN, Rocha FA, Nascimento AL, Coelho PG. Influence of implant shape, surface morphology, surgical technique and bone quality on the primary stability of dental implants. *J Mech Behav Biomed Mater* 2012;16:169-80.
- Davies JE. Mechanisms of endosseous integration. *Int J Prosthodont* 1998;11:391-401.
- Javed F, Ahmed HB, Crespi R, Romanos GE. Role of primary stability for successful osseointegration of dental implants: Factors of influence and evaluation. *Interv Med Appl Sci* 2013;5:162-7.
- Mishra SK, Chowdhary R. Heat generated by dental implant drills during osteotomy-a review: Heat generated by dental implant drills. *J Indian Prosthodont Soc* 2014;14:131-43.
- Tribst JP, de Moraes DC, Alonso AA, Piva AM, Borges AL. Comparative three-dimensional finite element analysis of implant-supported fixed complete arch mandibular prostheses in two materials. *J Indian Prosthodont Soc* 2017;17:255-60.
- Elakkiya S, Ramesh AS, Prabhu K. Systematic analysis on the efficacy of bone enhancement methods used for success in dental implants. *J Indian Prosthodont Soc* 2017;17:219-25.
- Deshpande A, Bhargava D. Intraoral periapical radiographs with grids for implant dentistry. *J Maxillofac Oral Surg* 2014;13:603-5.
- Lascale CA, Panella J, Marques MM. Analysis of the accuracy of linear measurements obtained by cone beam computed tomography (CBCT-newTom). *Dentomaxillofac Radiol* 2004;33:291-4.
- Mohamed JB, Alam MN, Singh G, Chandrasekaran SN. Alveolar bone expansion for implant placement in compromised aesthetic zone – Case series. *J Clin Diagn Res* 2014;8:237-8.
- Gehrke SA, König B, Marin GW. Bone expansion in one surgical step. Available from: [http://www.dentaltribune.com/htdocs/uploads/printarchive/editions/86f3c164689f77dedcf3605faff97fb7\\_26-29.pdf](http://www.dentaltribune.com/htdocs/uploads/printarchive/editions/86f3c164689f77dedcf3605faff97fb7_26-29.pdf). [Last accessed on 2015 Oct 01].
- Cortes AR, Cortes DN. Nontraumatic bone expansion for immediate dental implant placement: An analysis of 21 cases. *Implant Dent* 2010;19:92-7.
- Lee EA, Anitua E. Atraumatic ridge expansion and implant site preparation with motorized bone expanders. *Pract Proced Aesthet Dent* 2006;18:17-22.
- Rai A, Agrawal S, Datarkar A. Utility of trephine drills in implant dentistry. *J Maxillofac Oral Surg* 2015;14:506-8.