

Granulomatosis with polyangiitis and associated pulmonary emphysema: Breathtaking vasculitis

Shruti K. Gadre¹, James K. Stoller^{2,3}, Atul C. Mehta³

¹Departments of Medicine, ²Education Institute, ³Department of Pulmonary Medicine, Respiratory Institute Cleveland Clinic, Cleveland, Ohio, USA

ABSTRACT

Pulmonary emphysema occasionally occurs in the absence of smoking or noxious exposures. Other than through a known association with alpha-1 antitrypsin deficiency, to our knowledge, no reports implicate granulomatosis with polyangiitis (GPA) in causing airflow obstruction with small airway involvement and severe air trapping. To extend available experience, we report a 51-year-old male with biopsy-proven cytoplasmic-antineutrophilic cytoplasmic antibody proteinase 3 (ANCA PR3)-positive GPA who developed centrilobular emphysema and airflow obstruction during a phase of active vasculitis. He was a lifelong non-smoker and had a normal alpha-1 antitrypsin level and a PI*MM phenotype. Treatment with corticosteroids and cyclophosphamide caused clinical remission of his vasculitis which was associated with improvement in his respiratory symptoms. However, to date, structural changes of emphysema have persisted for over 9 years of follow-up. Clinicians should remain vigilant to the possibility of emphysema in patients with pulmonary vasculitis.

KEY WORDS: Chronic obstructive pulmonary disease (COPD), emphysema, granulomatosis with polyangiitis (GPA)

Address for correspondence: Dr. Atul C Mehta, Department of Pulmonary Medicine, Respiratory Institute, Cleveland Clinic, 9500 Euclid Avenue, Cleveland, Ohio - 44195, USA. E-mail: mehtaa1@ccf.org

INTRODUCTION

Granulomatosis with polyangiitis (GPA) is a small vessel vasculitis which causes systemic necrotizing vasculitis, necrotizing glomerulonephritis and granulomatous inflammation of the upper and lower respiratory tracts presenting as rhinosinusitis, bronchial ulcerations and stenosis or diffuse alveolar hemorrhage (DAH).^[1] GPA has also been associated with alpha-1 antitrypsin deficiency (AATD), which has been implicated in causing emphysema.^[2] To our knowledge, to date, only a few cases have been reported with emphysematous changes associated with GPA in the absence of AATD.^[3,4] The current report extends available experience by describing a 51-year-old male, non-smoker with GPA, centrilobular emphysema with severe air trapping,

and airflow obstruction with a normal AAT level and phenotype.

CASE REPORT

A 51-year-old male presented in April 2005 with an 18-month history of dyspnea on exertion, mildly productive cough, and a 6-month history of resting hypoxemia. Arterial blood gas on admission showed a partial pressure of carbon dioxide (PaCO₂) of 40 mmHg and a partial pressure of oxygen (PaO₂) of 55 mmHg with a saturation of 85% on room air.

In February 2005, he had presented with lower extremity myalgias and arthralgias, low grade fevers, chills, night sweats, and a history of chronic sinusitis, nasal discharge and crusting. Nerve conduction studies showed mononeuritis multiplex. He had also developed acute kidney injury with biopsy proven pauci-immune focal necrotizing glomerulonephritis. Laboratory assessment showed a positive antinuclear antibody and positive c-ANCA, PR3 serology. He was diagnosed with GPA and was treated initially with cyclophosphamide 100 mg and prednisone 60 mg daily and prophylactic trimethoprim-sulfamethoxazole.

Access this article online

Quick Response Code:



Website:

www.lungindia.com

DOI:

10.4103/0970-2113.159576

He was a lifelong non-smoker, denied significant second-hand smoke exposure and had no history of either intravenous or inhaled drug abuse. He worked in building maintenance, conducting minor repairs but denied exposure to chemicals or fumes. Spirometry revealed mild airflow obstruction (FEV₁/FVC- 64% predicted, FEV₁-76% predicted) without a bronchodilator response, severe hyperinflation (TLC- 123% predicted, RV- 185% predicted) and reduced diffusing capacity [Table 1]. The chest X-ray demonstrated air trapping suggestive of emphysema [Figure 1a and b]. A computed tomographic (CT) scan of the chest showed extensive homogeneous, centrilobular emphysema with multiple thin-walled cystic spaces scattered throughout the parenchyma with no evidence of interstitial lung disease, pneumonia, or pulmonary embolism [Figure 2a and b]. There was no evidence of prior DAH. A serum AAT level was normal (180 mg/dl, normal 100-200 mg/dl) and the phenotype by immunoelectrophoresis (Quest Diagnostics, San-Juan Capistrano, CA) was PI*MM. Medications were begun, including inhaled tiotropium bromide, fluticasone/salmeterol 250 mcg/50 mcg, and supplemental oxygen of 4 l nasal oxygen at rest, exertion and sleep.

Cyclophosphamide was maintained and oral corticosteroids were tapered over 6 months with an excellent response, characterized by normalization of kidney function and improvement in constitutional symptoms and dyspnea on exertion.

His respiratory symptoms continued to improve. His supplemental oxygen requirements also continued to

improve such that in June 2008 he required 2 l of nasal oxygen only with exertion. An arterial blood gas at that time showed a PaO₂ of 64 mmHg on room air. He no longer required supplemental oxygen and his inhalers were discontinued in July 2008. Since then, his GPA was in remission with azathioprine and his respiratory symptoms stabilized. Repeat CT chest at 5 months, 2, 3, and 6 years showed stable emphysematous changes and PFTs showed stable airflow obstruction with severe air trapping [Table 1].

DISCUSSION

The current patient had radiographic and physiologic evidence of emphysema in the absence of recognized causes but with concomitant GPA. The report extends available knowledge by describing, a rare case of a patient with GPA and otherwise unexplained emphysema. In particular, our patient lacked evidence of either common (smoking, AATD, noxious inhalation exposure) or uncommon predispositions to emphysema (connective tissue disorders [cutis laxa, Marfan syndrome, Ehlers-Danlos syndrome]), intravenous drug abuse, human immunodeficiency virus infection, hypocomplementemic urticarial vasculitis, malnutrition, or metabolic disorders like Menke or Salla syndrome).^[5]

Table 2 summarizes the available cases of GPA with otherwise unexplained emphysema (present case included). Among these cases, our patient was unique in being a non-smoker. Mouly *et al.* reported a patient with Wegener’s granulomatosis who developed bullous emphysema during severe active lung vasculitis. He had normal AAT levels, but was a smoker which could have contributed to his emphysema.^[3] Another patient with

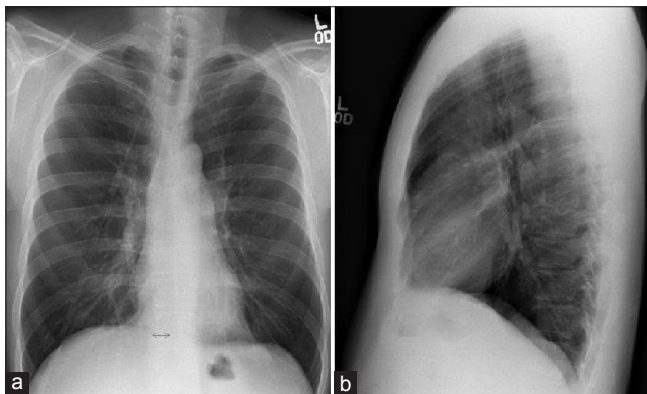


Figure 1: (a and b) Chest X-ray postero-anterior (PA) and lateral views revealing hyperinflation, horizontal ribs widened intercostal spaces and increased PA diameter suggestive of emphysema. Dated: April 2005

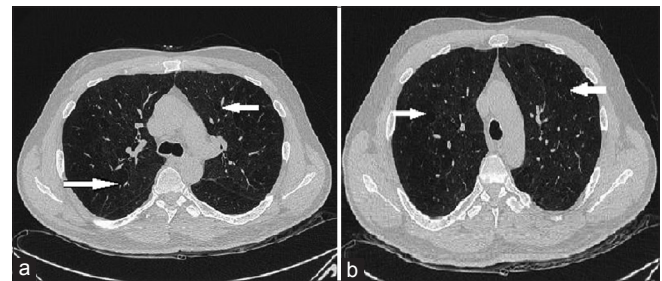


Figure 2: (a and b) Chest CT: Multiple thin-walled cystic spaces scattered (Solid white arrows) throughout the pulmonary parenchyma indicative of homogeneous centrilobular emphysema. Dated: April 2005

Table 1: Serial pulmonary function test results in the current patient: (Original)

	On admission	3 years later	4 years later	8 years later	9 years later
FVC in liters (% predicted)	4.44 (94)	3.93 (81)	3.90 (80)		4.07 (88)
FEV ₁ in liters (% predicted)	2.88 (76)	2.66 (69)	2.43 (63)		2.63 (75)
FEV ₁ /FVC (%)	64.8	67.7	62.3		64.8
TLC in liters (% predicted)	8.21 (123)			8.53 (125)	
RV in liters (% predicted)	3.65 (185)			4.02 (185)	
RV/TLC (%)	44.5			47.1	
DLCO ml/mmHg/min (% Predicted)	18.5 (76)		15.71 (66)	15.45 (55)	

FEV₁/FVC: Forced expiratory volume in one second/ Forced vital capacity, RV/TLC: Residual volume to total lung capacity ratio, DLCO: Diffusing capacity of the lung for carbon monoxide

Table 2: Summary of available reports of emphysema associated with GPA (Original)

Author (year)	Demographic features	Evidence of emphysema	Risk factors	AAT assessment	Comments
Mouly (2000)	Age: 30 year Gender: Male ANCA MPO: Positive	CT: 12.5×14 cm RLL bulla, minimal emphysematous changes in the lower lobes	Smoker. Pack years: NR	Serum level 1.31 g/L (0.9-2) Phenotype: NR	Follow up: 5 years, Developed emphysema during a phase of active vasculitis
Motoya (1995)	Age: 46 year Gender: Male ANCA: Negative	CXR and CT: Giant bulla RUL	NR	NR	Required partial lobectomy, GPA on resected tissue
Present patient	Age: 51 year Gender: Male ANCA PR3: Positive	CT chest: Severe homogeneous centrilobular emphysema	Never smoker	Serum level 180 mg/dl, (100-200) Phenotype PI*MM	Follow up: 9 years. Respiratory symptoms improved with remission of vasculitis

RLL: Right lower lobe, RUL: Right upper lobe, NR: Not reported, CXR: Chest X-ray, CT: Computed tomography, GPA: Granulomatosis with polyangiitis, ANCA PR3: Antineutrophilic cytoplasmic antibody proteinase 3

ANCA-negative GPA and a large pulmonary bulla was reported in the Japanese literature.^[4] A partial lobectomy showed evidence of granulomatous and necrotizing vasculitis in the resected tissue.

The diagnosis of GPA in our patient was secure, as it was established by clinical, pathologic and serologic features consistent with the American College of Rheumatology^[6] and the Chapel Hill Consensus Conference criteria.^[7] Pathologic features were confirmed on a kidney biopsy; however, lung biopsy was not performed.

In the context of GPA, our patient had the uncommon pulmonary finding of emphysema but lacked the well-described sequelae of GPA.^[8]

While the pathogenesis of emphysema in our patient is unclear, several mechanisms in GPA are plausible. First, diffuse alveolar hemorrhage has been shown to release proteolytic enzymes and free oxygen radicals, which could destroy alveolar walls.^[9] Secondly, proteinase 3 is a potent protease released in the extracellular fluid after neutrophil activation. Alpha-1-antitrypsin is a major physiologic inhibitor of PR3 in the extracellular fluid. It is speculated that ANCA antibodies may prevent PR3 from complexing with alpha-1 antitrypsin resulting in secondary protease-antiprotease imbalance which may be pathogenic.^[10] That vasculitis is implicated in causing the emphysema in our patient is suggested by the temporal course; respiratory symptoms began at the time of a vasculitic flare and improved as the vasculitis remitted on immunosuppressive therapy. Furthermore, a 6-year flare-free follow-up showed stable CT findings of emphysema. Repeat PFTs also remained stable [Table 1] over time.

CONCLUSIONS

In conclusion, we report a rare patient with severe centrilobular emphysema and airflow obstruction in

the context of ANCA PR3-positive granulomatosis with polyangiitis. In the absence of a recognized cause of emphysema in this patient, we speculate that his vasculitis caused emphysema and suggest that clinicians should remain vigilant to the possibility of emphysema in patients with pulmonary vasculitides.

REFERENCES

- Falk RJ, Gross WL, Guillevin L, Hoffman GS, Jayne DR, Jennette JC, *et al.*; American College of Rheumatology; American Society of Nephrology; European League Against Rheumatism. Granulomatosis with polyangiitis (Wegener's): An alternative name for Wegener's granulomatosis. *Arthritis Rheum* 2011;63:863-4.
- Stoller JK, Aboussouan LS. A review of α -1-antitrypsin deficiency. *Am J Respir Crit Care Med* 2012;185:246-59.
- Mouly S, Brilllet G, Stern M, Lesavre P, Guillevin L. Pulmonary giant bulla in Wegener's granulomatosis. *Scand J Rheumatol* 2000;29:333-5.
- Motoya S, Tsujisaki M, Ibayashi Y, Bekki E, Kusumoto K, Sawada Y, *et al.* A case of ANCA negative Wegener's granulomatosis with pulmonary giant bulla showing high level of soluble ICAM-1. *Nihon Rinsho Meneki Gakkai Kaishi* 1995;18:296-302.
- Lee P, Gildea TR, Stoller JK. Emphysema in nonsmokers: Alpha 1-antitrypsin deficiency and other causes. *Cleve Clin J Med* 2002;69:928-9, 933, 936 passim.
- Leavitt RY, Fauci AS, Bloch DA, Michel BA, Hunder GG, Arend WP, *et al.* The American College of Rheumatology 1990 criteria for the classification of Wegener's granulomatosis. *Arthritis Rheum* 1990;33:1101-7.
- Jennette JC, Falk RJ, Andrassy K, Bacon PA, Churg J, Gross WL, *et al.* Nomenclature of systemic vasculitides. Proposal of an international consensus conference. *Arthritis Rheum* 1994;37:187-92.
- Pesci A, Pavone L, Buzio C, Manganello P. Respiratory system involvement in ANCA-associated systemic vasculitides. *Sarcoidosis Vasc Diffuse Lung Dis* 2005;22(Suppl 1):S40-8.
- Schwarz MI, Mortenson RL, Colby TV, Waldron JA, Lynch DA, Hutt MP, *et al.* Pulmonary capillaritis: The association with progressive irreversible airflow limitation and hyperinflation. *Am Rev Respir Dis* 1993;148:507-11.
- Alzouki AN. The role of alpha1 -antitrypsin deficiency in the pathogenesis of antineutrophil cytoplasmic antibodies associated systemic necrotizing vasculitides. *Saudi J Kidney Dis Transpl* 1999;10:41-53.

How to cite this article: Gadre SK, Stoller JK, Mehta AC. Granulomatosis with polyangiitis and associated pulmonary emphysema: Breathtaking vasculitis. *Lung India* 2015;32:367-9.

Source of Support: Nil, **Conflict of Interest:** None declared.