

A Comparative Study of Endoscopic versus Microscopic Cartilage Type I Tympanoplasty

Dipesh Shakya¹  Arun KC² Ajit Nepal³

¹Department of Otorhinolaryngology, Civil Service Hospital, Kathmandu, Nepal

²Department of Otorhinolaryngology, National Academy of Medical Sciences, Kathmandu, Nepal

³Department of Otorhinolaryngology, Patan Academy of Health Science, Lalitpur, Nepal

Address for correspondence Dr. Dipesh Shakya, Department of otorhinolaryngology, MD, MS, Civil Service Hospital, Minbhawan Kathmandu, Kathmandu, 44600, Nepal (e-mail: dipeshent@yahoo.com).

Int Arch Otorhinolaryngol 2020;24:e80–e85.

Abstract

Introduction The use of endoscope is rapidly increasing in otological and neuro-otological surgery in the last 2 decades. Middle ear surgeries, including tympanoplasty, have increasingly utilized endoscopes as an adjunct to or as a replacement for the operative microscope. Superior visualization and transcanal access to diseases normally managed with a transmastoid approach are touted as advantages with the endoscope.

Objectives The present study aimed to compare the outcomes of endoscopic and microscopic cartilage tympanoplasty (Type I)

Methods This was a retrospective comparative study of 70 patients (25 males and 45 females) who underwent type I tympanoplasty between March 2015 and April 2016. The subjects were classified into 2 groups: endoscopic tympanoplasty (ET, $n = 35$), and microscopic tympanoplasty (MT, $n = 35$). Tragal cartilage was used as a graft and technique used was cartilage shield tympanoplasty in both groups. Demographic data, perforation size of the tympanic membrane at the preoperative state, operation time, hearing outcome, and graft success rate were evaluated.

Results The epidemiological profiles, the preoperative hearing status, and the perforation size were similar in both groups. The mean operation time of the MT group (52.63 ± 8.68 minutes) was longer than that of the ET group (48.20 ± 10.37 minutes), but the difference was not statistically significant. The graft success rates 12 weeks postoperatively were 91.42% both in the ET and MT groups, that is, 32/35; and these values were not statistically significantly different. There was a statistically significant improvement in hearing within the groups, both pre- and postoperatively, but there was no difference between the groups.

Conclusion Endoscopic tympanoplasty is a minimally invasive surgery with similar graft success rate, comparable hearing outcomes and shorter operative time period as compared to microscopic use.

Keywords

- ▶ tympanoplasty
- ▶ cartilage
- ▶ microscope
- ▶ endoscope

received
April 17, 2019
accepted
May 21, 2019

DOI <https://doi.org/10.1055/s-0039-1693139>.
ISSN 1809-9777.

Copyright © 2020 by Thieme Revinter Publicações Ltda, Rio de Janeiro, Brazil

License terms



Introduction

Chronic otitis media (COM) is one of the most common problems in otology, which leads to permanent changes in the tympanic membrane and/or in the structures of the middle ear.¹ It is further classified as non-cholesteatomatous and cholesteatomatous.²

Type I tympanoplasty is the repair of the perforation of the tympanic membrane, and it was first performed by Berthold (1878), later popularized by Wullstein and Zollner (1950).³

Although the temporalis fascia is still being used as graft material, it has been largely replaced by cartilage due to its stability and long-term uptake result.⁴

A microscope was first used by Swedish otologist Carl Olof Nylen in 1921, but it was monocular. Later Binocular microscope was used by Gunner Holmgren in 1922; however, this type of microscope was not popular due to poor light quality, limited field of vision, instability and very short focal distance until new model appeared in 1951 which was perfected by Littmann and the Zeiss company that replaced all other models.⁵ The microscope gives the advantage of magnified vision, good depth perception, and utilizes two hand techniques. However, it has the disadvantages of giving straight line vision and of not providing a good vision of deep recesses.⁶

The use of the endoscope is rapidly increasing in otological and neuro-otological surgery in the last 2 decades. Middle ear surgeries, including tympanoplasty, have increasingly utilized endoscopes as an adjunct to or as a replacement for the operative microscope. Superior visualization and transcanal access to diseases normally managed with the transmastoid approach are touted as advantages of the endoscope.⁷ The objectives of the present study were to compare the outcome of endoscopic and microscopic cartilage Type I tympanoplasty regarding graft uptake rate, hearing outcome, and operation time.

Methods

We performed a retrospective comparative study of prospectively maintained data of 70 patients (25 males and 45 females) who underwent type I tympanoplasty from March 2015 to April 2016. The subjects were classified into 2 groups: endoscopic tympanoplasty group (ET, $n = 35$), and microscopic tympanoplasty group (MT, $n = 35$). All of the surgeries used tragal cartilage as graft and shield technique used. Demographic data, perforation size of the tympanic membrane at the preoperative state, operation time, and graft success rate were evaluated.

For the ET group, all of the cases were performed transcanally, whereas in the MT group the perimeatal and postaural approaches were used. Three cases of the MT group needed the postaural approach due to the lack of vision of the anterior margin.

All of the procedures were performed by two surgeons (the first two authors of the present article). Patients aged < 13 years old were operated under general anesthesia, and those ≥ 13 years old were operated under local anesthesia. Cases operated under local anesthesia were performed on a day-case

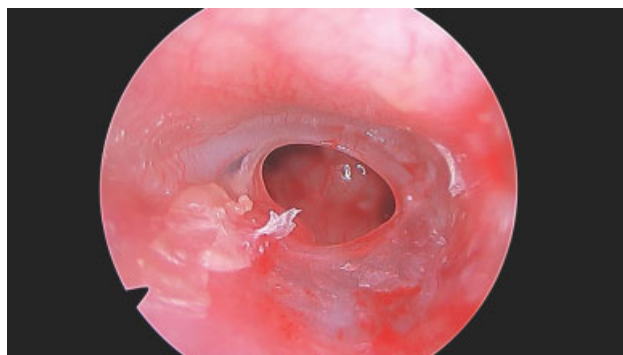


Fig. 1 Preoperative perforation

basis without admission. Ethical clearance was obtained from the Institutional Review Board. A local antibiotic and steroid treatment was performed in case of preoperative inflammation of the tympanic cavity. A tragal cartilage graft was harvested, and the perichondrium was removed on both sides. The margin of the perforation was refreshed, and the drum remnant was removed from the handle of the malleus. The mobility of the ossicular chain was checked. The graft was shaped to the size of the perforation. Gelfoams were kept in the middle ear accordingly. For the posterior perforation, the graft was placed in the underlay technique, medial to the handle of the malleus, to the tympanic membrane, and to the annulus. For central, anterior and subtotal perforations, the graft was notched to fit the handle of the malleus and placed in the over-underlay technique. All of the cases were then reinforced using the perichondrium. The tympanomeatal flap was pulled down and the annulus was meticulously inserted in the sulcus. The external auditory canal (EAC) was packed with gelfoam and then with ear pack, which was removed after 7 days. (**→ Figs. 1 to 6**)

The patients were followed up at 6 weeks, 12 weeks, and 6 months. The average on 4 frequencies (0.5; 1.0; 2.0; and 3.0 kHz) of hearing thresholds in air and bone conduction and the air-bone gap (ABG) were evaluated 7 days before the surgery and 12 weeks afterwards.

Data were analyzed as graft uptake rate and as change between pre- and postoperative hearing. Data were analyzed using the Fisher exact test, the chi-squared test, and the dependent and independent t-test in IBM SPSS Statistics for Windows, Version 23.0 (IBM Corp., Armonk, NY, USA). The level of statistical significance was set at $p < 0.05$.

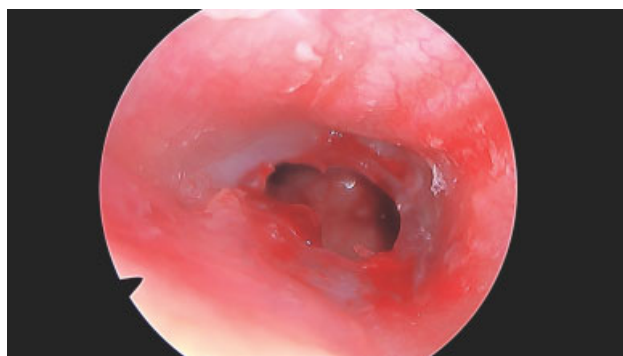


Fig. 2 Margin refreshed

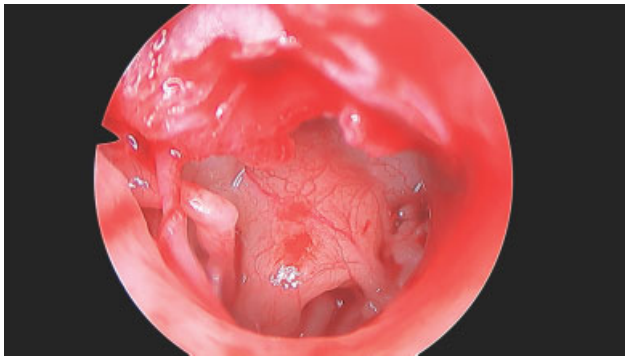


Fig. 3 Middle ear and ossicles exposed

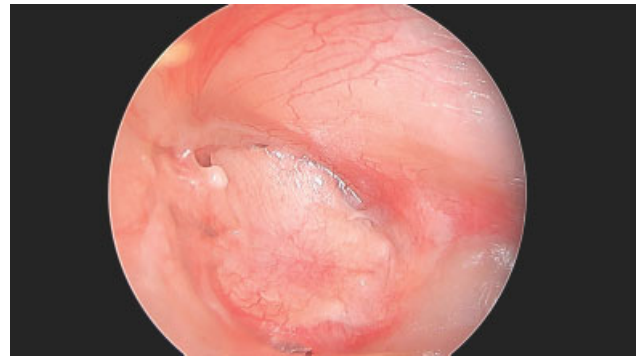


Fig. 6 Graft uptake after 12 weeks

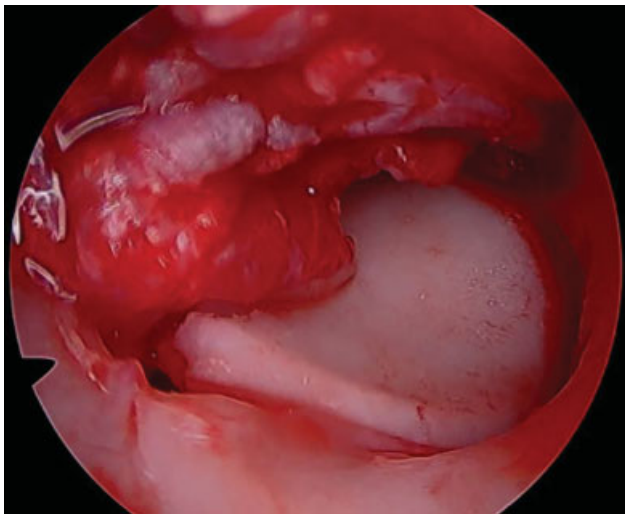


Fig. 4 Cartilage graft placed

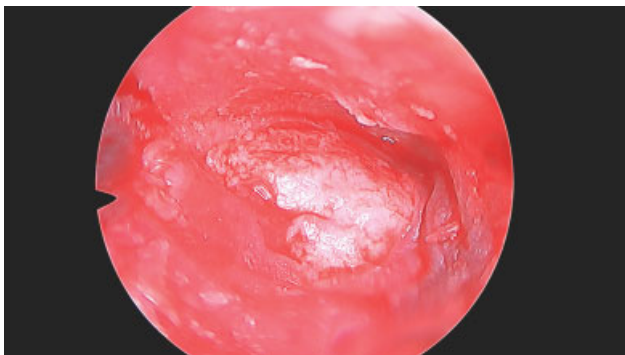


Fig. 5 Perichondrium reinforced

Table 1 Pre- and postoperative hearing outcomes

	Endoscopic tympanoplasty group	Microscopic tympanoplasty group	
Enrolled	35	35	
Age (years old)			
Range	12–65	12–50	
Mean	31.34 ± 14.89	25.86 ± 9.43	<i>p</i> -value 0.070
Gender			
Male	14	11	
Female	21	24	
Ratio	0.66	0.45	<i>p</i> -value 0.618
Site			
Left	20	19	
Right	15	16	
Ratio	1.33	1.18	<i>p</i> -value 1.00
Perforation size (%)	66.86 ± 20.15	67.57 ± 17.87	<i>p</i> -value 0.876
Graft			
Uptake	32 (91.42%)	32 (91.42%)	
Failure	3 (8.57%)	3 (8.57%)	<i>p</i> -value 1.00
Operation time (minutes)	48.20 ± 10.37	52.63 ± 8.68	<i>p</i> -value 0.57
Follow-up (weeks)			
Range	5–29	5–49	
Mean	12.15 ± 6.31	17.11 ± 11.43	<i>p</i> -value 0.028

Results

The epidemiological profiles, the preoperative hearing status, and the perforation size were similar in both groups, as shown in ►Table 1. In the ET group, the mean age of the patients was 31.34 ± 14.89 years old, ranging from 12 to 65 years old, and in the MT group, the mean age of the patients was 25.86 ± 9.43 years old, ranging from 12 to 50 years old. There was no statistically significant difference between the two age groups (*p* = 0.070).

There were 14 males and 21 females in the ET group, and 11 males and 24 females in the MT group, which was not statistically different (*p* = 0.618).

Based on the laterality of the disease, in the ET group, 20 cases were on left side, and 15 were on the right side. In the MT group, 19 cases were on the left side, and 16 on the right side. Both were statistically insignificant (*p* = 1.00). The mean perforation size on percentage was 66.86 ± 20.15 on the ET group, and 67.57 ± 17.87 on the MT group. Both group based on perforation size was not statistically significant (*p* = 0.876).

The graft success rates at 12 weeks postoperatively were 91.42% both in the ET and MT groups, that is, 32/35; and these values were not statistically significantly different ($p = 1.00$).

Hearing outcomes were as shown in ► **Tables 2 to 5**. There was a highly statistically significant hearing outcome before and after the surgery in both the ET and the MT groups. However, there was no change in hearing outcomes between the two groups. Thus, the hearing outcome did not change with use either of the endoscope or of the microscope.

The mean operation time of the MT group (52.63 ± 8.68 minutes) was longer than that of the ET group (48.20 ± 10.37 minutes), but not statistically different ($p = 0.57$).

Discussion

The microscope has been used as the ideal operative tool for tympanoplasty. The endoscope has been now rapidly used

for tympanoplasty since the first article published by el-Guindy in 1992.⁸ Even tympanomastoidectomy, which was traditionally performed using a microscope, is currently being performed using an endoscope.⁹

Our study showed no differences between the graft closure rates between the 2 groups ($p = 1.00$). Similarly, there was no statistically significant difference obtained in the demographic profile, in the hearing outcomes, and in the operation time between the 2 groups ($p > 0.05$). The results obtained were comparable to those of other studies.

The graft uptake rate both in the ET and in the MT groups was 32/35 (91.42%) at the 6-month follow-up. The operation time for the ET group was 48.20 ± 10.37 minutes, and for the MT group, it was 52.63 ± 8.68 minutes; although it was shorter for the ET group, the difference was not statistically significant ($p = 0.57$). However, three cases in the MT group needed the postaural approach due to the lack of vision of the anterior margin of the perforation. The hearing outcome was

Table 2 Endoscopic tympanoplasty group

		Mean	n	Standard deviation	Standard error of mean	p-value
Pair 1	Preoperative ACT	43.7143	35	11.32526	1.91432	0.000
	Postoperative ACT	32.6786	35	14.60932	2.46943	
Pair 2	Preoperative ABG	29.4143	35	9.85426	1.66567	0.000
	Postoperative ABG	20.6000	35	11.33419	1.91583	

Abbreviations: ABG, air-bone Gap; ACT, air conduction threshold.

Table 3 Microscopic tympanoplasty group

		Mean	n	Standard deviation	Standard error of mean	p-value
Pair 1	Preoperative ACT	44.9643	35	12.21922	2.06543	0.000
	Postoperative ACT	33.2857	35	14.08706	2.38115	
Pair 2	Preoperative ABG	29.0500	35	11.60103	1.96093	0.000
	Postoperative ABG	19.6071	35	10.54913	1.78313	

Abbreviations: ABG, air-bone Gap; ACT, air conduction threshold.

Table 4 Pre- and postoperative air conduction threshold (endoscopic versus microscopic groups)

	Groups	n	Mean	Standard deviation	Standard error of mean	p-value
Preoperative ACT	ET	35	43.7143	11.32526	1.91432	.405
	MT	35	44.9643	12.21922	2.06543	
Postoperative ACT	ET	35	32.6786	14.60932	2.46943	.825
	MT	35	33.2857	14.08706	2.38115	

Abbreviations: ACT, air conduction threshold; ET, endoscopic tympanoplasty group; MT, microscopic tympanoplasty group.

Table 5 Pre- and postoperative air-bone gap (endoscopic versus microscopic groups)

	Groups	n	Mean	Standard deviation	Standard error of mean	p-value
Preoperative ABG	ET	35	29.4143	9.85426	1.66567	.456
	MT	35	29.0500	11.60103	1.96093	
Postoperative ABG	ET	35	20.6000	11.33419	1.91583	.572
	MT	35	19.6071	10.54913	1.78313	

Abbreviations: ABG, air-bone gap; ET, endoscopic tympanoplasty group; MT, microscopic tympanoplasty group.

not statistically significant between the groups but had significant results within the groups.

Huang et al performed a similar study in 2016 between 2 groups, microscopic and endoscopic, using the tragal cartilage shield technique, and he had 96% graft uptake results in both groups at 6 months of follow-up. The operation time in the endoscopic group was of 50.4 ± 13.4 minutes, and of 75.5 ± 20 minutes in the microscopic group, with $p = 0.0001$. Endoscope use revealed to have a shorter operative time than the microscopic group, with a statistically significant result.¹⁰

A study performed by Choi et al in 2016 that compared endoscopic and microscopic tympanoplasty had 100% graft uptake in the endoscopic group ($n = 25$) and 95.8% ($n = 48$) in the microscopic group, which was not statistically significant ($p = 0.304$), with a mean follow-up of 6.4 months (range: 3–11 months). The mean operation time in the microscopic group was of 88.9 ± 28.5 minutes, and of 68.2 ± 22.1 minutes in the endoscopic group ($p = 0.002$). It revealed that endoscope use had reduced the operative time significantly, which resulted in less exposure to general anesthesia.¹¹

A similar study was performed in 2015 by Mokbel et al, who compared endoscopic and microscopic tympanoplasty, with 40 cases in each group, with an uptake rate of 100% in the endoscopic group and of 90% in the microscopic group, with a follow-up range between 6 and 24 months. The operation time was of 40 ± 5.50 minutes in the endoscopic group, and of 55 ± 10.50 minutes in the microscopic group ($p < 0.0001$).¹² Another study, performed in 2017 by Jyothi et al, compared microscopic with endoscopic myringoplasty, with 60 cases in each group. They had an uptake rate of 91.67% in the endoscopic group and of 93.3% in the microscopic group at 1 year of follow-up. They had a mean operative time of 60 minutes in the endoscopic group and of 120 minutes in the microscopic group.¹³

A prospective randomized controlled trial performed in 2017 by Kaya et al had 13 patients presenting with bilateral chronic otitis media, and performed microscopic and endoscopic ear surgery in the same patients. They had a graft uptake of 100% in both groups at 12 months of follow-up. The operative time was of 36 ± 4.20 minutes in the endoscopic group and of 69.38 ± 216.11 minutes in the microscopic group, a difference that was statistically significant.¹⁴

In 2015, Awad et al performed endoscopic cartilage type I tympanoplasty in 36 pediatric cases, whose age ranged from 13 to 17 years old, with an uptake rate of 90% at 6 months of follow-up, with a mean operative time of 55.03 ± 2.50 minutes.¹⁵

In 2015, Özgür et al submitted 53 patients to endoscopic cartilage tympanoplasty, with a graft uptake of 92.5% at 6 postoperative months, and a mean operative time of 49.4 ± 8.1 minutes.¹⁶

All of the aforementioned studies had significant hearing improvement pre- and postoperatively within the groups and no change between the groups. Similarly, all of the aforementioned studies performed microscopic tympanoplasty with either the postaural or the endaural approach. However, for the homogeneity of the present study, we included microscopic and endoscopic both groups, with

only the transcanal approach. There were 3 cases in the MT group that were operated with the postaural approach and it was excluded in average operative time period.

The microscope is considered as the gold standard for the otological procedures, as it provides stereoscopic vision, better depth perception, and bimanual handling.¹⁰ The first reported case of endoscopic tympanoplasty was by el-Guindy in 1992.⁸

Several studies have already proven that the endoscope significantly reduces the operative time due to the lack of necessity to see the recesses, to its wide vision, and to the lack of necessity to perform postoperative suturing.

This has helped patients to have a fast recovery, a shorter hospital stay, and a lower financial burden, which is especially helpful for developing countries like ours. Newer high-definition cameras have provided better image quality to access blind sacs, middle ear spaces that would be impossible to be visible by microscope.¹⁷

There are also limitations to endoscopic ear surgery. It is a one-handed surgery and there is lack of depth perception.¹⁸ Both of these limitations can be overcome by experience and practice.

Sometimes, it's difficult to negotiate instruments in narrow canal along with endoscope, and bleeding makes the surgery hard to deal with. There are studies that give us tips about how to handle bleeding during endoscopic surgery.¹⁹

We did not find any difficulty while performing endoscopic tympanoplasty. It offered comparable results between the MT and ET groups with respect to graft uptake and hearing outcomes. The ET group had a slightly shorter operative time than the MT group.

Conclusion

With use of endoscope, minimal invasive tympanoplasty can be possible with similar graft success rate and shorter operative time period as compared to microscope.

Conflicts of Interests

The authors have no conflicts of interests to disclose.

References

- Cabra J, Moñux A. Efficacy of cartilage palisade tympanoplasty: randomized controlled trial. *Otol Neurotol* 2010;31(04):589–595
- Fukuchi I, Cerchiari DP, Garcia E, Rezende CE, Rapoport PB. Tympanoplasty: surgical results and a comparison of the factors that may interfere in their success. *Rev Bras Otorrinolaringol (Engl Ed)* 2006;72(02):267–271
- Dornhoffer JL. Surgical management of the atelectatic ear. *Am J Otol* 2000;21(03):315–321
- Beutner D, Huttenbrink KB, Stumpf R, et al. Cartilage plate tympanoplasty. *Otol Neurotol* 2010;31(01):105–110
- Mudry A. History of myringoplasty and tympanoplasty type I. *Otolaryngology—head and neck surgery: official journal of American Academy of Otolaryngology—Head Neck Surg* 2008;139(05):613–614
- Tarabichi M. Endoscopic transcanal middle ear surgery. *Indian J Otolaryngol Head Neck Surg* 2010;62(01):6–24
- Yadav SP, Aggarwal N, Julaha M, Goel A. Endoscope-assisted myringoplasty. *Singapore Med J* 2009;50(05):510–512
- el-Guindy A. Endoscopic transcanal myringoplasty. *J Laryngol Otol* 1992;106(06):493–495

- 9 Bedajit RK, Mallik P, Kumar P, et al. Endoscopic transcanal mastoidectomy with tympanoplasty. *Natl J Otorhinolaryngol Head Neck Surg* 2015;3(12):10–11
- 10 Huang TY, Ho KY, Wang LF, Chien CY, Wang HM. A Comparative Study of Endoscopic and Microscopic Approach Type 1 Tympanoplasty for Simple Chronic Otitis Media. *J Int Adv Otol* 2016;12(01):28–31
- 11 Choi N, Noh Y, Park W, et al. Comparison of endoscopic tympanoplasty to microscopic tympanoplasty. *Clin Exp Otorhinolaryngol* 2017;10(01):44–49
- 12 Mokbel KM, Moneir W, Elsisi H, et al. Endoscopic Transcanal Cartilage Myringoplasty for Repair of Subtotal Tympanic Membrane Perforation: A Method to Avoid Postauricular Incision. *J Otolaryngol Rhinol* 2015;1:010
- 13 Jyothi AC, Shrikrishna BH, Kulkarni NH, Kumar A. Endoscopic Myringoplasty Versus Microscopic Myringoplasty in Tubotympanic CSOM: A Comparative Study of 120 Cases. *Indian J Otolaryngol Head Neck Surg* 2017;69(03):357–362
- 14 Kaya I, Sezgin B, Sergin D, et al. Endoscopic versus microscopic type 1 tympanoplasty in the same patients: a prospective randomized controlled trial. *Eur Arch Otorhinolaryngol* 2017;274(09):3343–3349
- 15 Awad OG, Hamid KA. Endoscopic type 1 tympanoplasty in pediatric patients using tragal cartilage. *JAMA Otolaryngol Head Neck Surg* 2015;141(06):532–538
- 16 Özgür A, Dursun E, Erdivanli OC, et al. Endoscopic cartilage tympanoplasty in chronic otitis media. *J Laryngol Otol* 2015;129(11):1073–1077
- 17 Kanona H, Virk JS, Owa A. Endoscopic ear surgery: A case series and first United Kingdom experience. *World J Clin Cases* 2015;3(03):310–317
- 18 Kuo CH, Wu HM. Comparison of endoscopic and microscopic tympanoplasty. *Eur Arch Otorhinolaryngol* 2017;274(07):2727–2732
- 19 Anschuetz L, Bonali M, Guarino P, et al. Management of bleeding in exclusive endoscopic ear surgery: pilot clinical experience. *Otolaryngol Head Neck Surg* 2017;157(04):700–706