

Alectinib-associated drug reaction with eosinophilia and systemic symptoms syndrome



Sahira Farooq, BS,^a Saisindhu Narala, MD,^b and Omar Pacha, MD^c
Houston, Texas

Key words: alectinib; anaplastic lymphoma kinase inhibitor; DRESS; drug reaction; drug reaction with eosinophilia and systemic symptoms; drug-induced hypersensitivity syndrome; eosinophilia; severe drug eruption.

INTRODUCTION

Drug reaction with eosinophilia and systemic symptoms (DRESS) syndrome is a potentially fatal drug reaction with multiorgan system and cutaneous involvement. Mortality is approximately 10%, usually from fulminant hepatitis with hepatic necrosis.¹ The syndrome is most frequently associated with anti-convulsants and sulfonamides.¹ We present a case of DRESS syndrome after initiation of anaplastic lymphoma kinase inhibitor, alectinib, a first-line agent for metastatic anaplastic lymphoma kinase–positive non–small cell lung carcinoma. Cutaneous reactions with alectinib are uncommon, and to our knowledge, alectinib-associated DRESS syndrome has not been previously reported.

CASE SYNOPSIS

A 34-year old woman with metastatic lung adenocarcinoma was admitted for development of a diffuse, painless, pruritic rash 2.5 weeks after initiation of oral alectinib, 600 mg twice daily. Per the patient, the rash was preceded by fever and myalgias. Eruption began on her left arm and quickly progressed to the entire body. Two days before admission, alectinib was discontinued by the oncologist, as it was the suspected cause.

The patient was afebrile with erythematous, edematous annular papules coalescing into plaques across the trunk (Fig 1), bilateral upper and lower extremities (Fig 2), palms (Fig 3), and soles. Several

Abbreviation used:

DRESS: drug reaction with eosinophilia and systemic symptoms

targetoid lesions with faint, dusky centers were present. There was no evidence of bullae, erosions, facial swelling, or involvement of oral or genital mucosa. Left cervical and right inguinal lymphadenopathy were noted. Laboratory results were unremarkable. Medication review was notable only for recent initiation of alectinib. Intravenous dexamethasone, 60 mg/d, was started as well as triamcinolone 0.1% cream, hydrocortisone 2.5% cream, and an oral antihistamine. She was discharged 5 days after admission on a 2-week oral dexamethasone taper with near resolution of her rash.

At a 1-week follow-up, she reported rash recurrence on her trunk and new-onset facial edema (Fig 4) while on steroid taper. In the interval, she presented to the emergency department where she was given 60 mg of intravenous methylprednisone. Laboratory values showed elevated liver enzymes and eosinophilia at 22%. A diagnosis of DRESS syndrome was favored. Treatment was escalated to 50 mg/d oral prednisone with 25 mg oral hydroxyzine as needed for itching.

At a 2-week follow-up, the oncologist had since started the patient on brigatinib in place of alectinib.

From the McGovern Medical School, University of Texas Health Science Center at Houston^a; Department of Dermatology, University of Texas Health Science Center at Houston^b; and Department of Dermatology, University of Texas MD Anderson Cancer Center.^c

Funding sources: None.

Conflicts of interest: None disclosed.

IRB approval status: Not applicable.

Correspondence to: Sahira Farooq, BS, 6431 Fannin St, MSB G.400, Houston, TX 77030. E-mail: sahira.farooq.1@uth.tmc.edu.

JAAD Case Reports 2020;6:1339-41.

2352-5126

© 2020 by the American Academy of Dermatology, Inc. Published by Elsevier, Inc. This is an open access article under the CC BY-NC-ND license (<http://creativecommons.org/licenses/by-nc-nd/4.0/>).

<https://doi.org/10.1016/j.jidcr.2020.09.007>

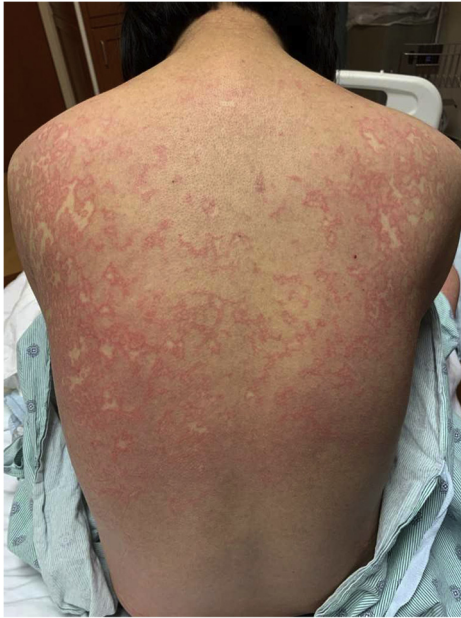

Fig 1. DRESS syndrome. Erythematous, edematous annular papules coalescing into plaques on the back. *DRESS*, Drug reaction with eosinophilia and systemic symptoms.

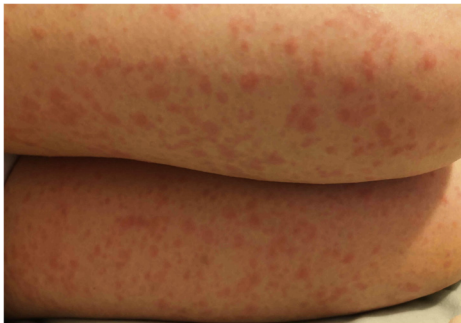

Fig 2. DRESS syndrome. Erythematous, edematous annular papules on bilateral thighs. *DRESS*, Drug reaction with eosinophilia and systemic symptoms.

In the interval, she again presented for rash persistence to the emergency department, where oral prednisone was increased to 60 mg/d. Physical examination found superficial desquamation of the face with significant improvement of edema. Diffuse morbilliform eruption to the trunk and new erythematous papules to forearms and thighs were noted. Steroid tapering over 4 to 6 weeks was initiated in addition to emollients and topical steroids.

She showed clinical improvement with normalization of laboratory values over the following weeks until 11 weeks, when she presented for another flare. After taper completion, blisters developed on her hands and feet, requiring resumption of oral prednisone at 30 mg/d. Dosage decreased to 20 mg/d upon clinical improvement. She continued

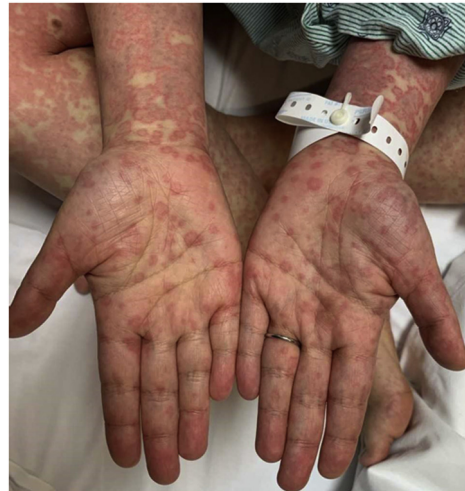

Fig 3. DRESS syndrome. Erythematous, edematous annular papules coalescing into plaques on bilateral palms. *DRESS*, Drug reaction with eosinophilia and systemic symptoms.

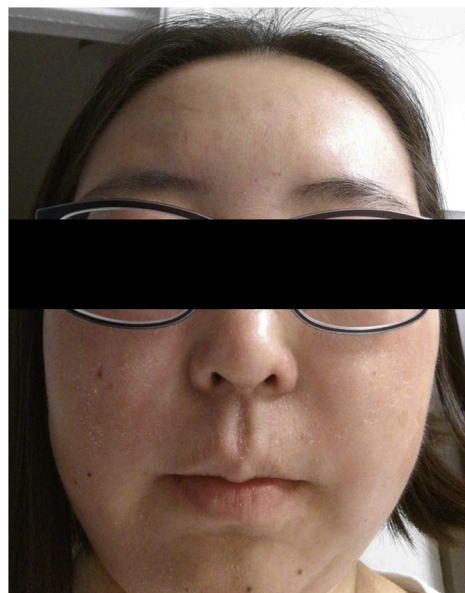


Fig 4. DRESS syndrome. Superficial desquamation and edema of face. *DRESS*, Drug reaction with eosinophilia and systemic symptoms.

improving on this dose, and 2 months later, tapering by 2 mg/wk was initiated.

Approximately 1 year after her diagnosis—at the time of this writing—she continues taking brigatinib, remaining clear of DRESS syndrome with only mild dermatitis to the scalp and hands, managed with topical agents.

DISCUSSION

According to alectinib clinical trial data (600 mg orally twice daily) in 152 patients, the most common

any-grade adverse events were anemia (22.4%), increased serum bilirubin (19.1%), peripheral edema (18.4%), elevated alanine aminotransferase (17.1%), and myalgia (16.4%).² Any-grade cutaneous adverse events included photosensitivity (5.9%) and alopecia (0.7%).² Few cases of severe rashes (eg, erythema multiforme) have been reported with alectinib.^{3,4}

Symptom onset for DRESS syndrome generally occurs 2 to 6 weeks after administering the causative agent, often beginning with fever several days before rash eruption.¹ Our patient exhibited signs and symptoms after 2.5 weeks. The most common cutaneous manifestation is morbilliform rash, often first affecting the face, upper trunk, and upper extremities and later spreading to the lower extremities.¹ As observed in our patient, this rash often progresses to exfoliative dermatitis with facial edema.⁵ Bullae, vesicles, pustules, purpura, cheilitis, erythroderma, or target lesions may be present.^{1,5,6} Other common features include lymphadenopathy, hematologic abnormalities (eg, eosinophilia, leukocytosis), and abnormal liver function test results that can mimic viral hepatitis.⁶

Diagnosis is primarily clinical as histology is often nonspecific. Latency, symptom diversity, and exclusion of other drug-induced complications must be considered.^{1,5} High index of suspicion should be given with fever, rash, liver involvement, eosinophilia, and lymphadenopathy.⁵ Each of these manifested in our patient. Bocquet et al⁷ proposed the original DRESS syndrome diagnostic criteria. Since then, criteria have also been suggested by the European Registry of Severe Cutaneous Adverse Reactions⁸ and the Japanese Research Committee.⁹ Diagnosis in our patient was further supported by a Registry of Severe Cutaneous Adverse Reactions score of 6: afebrile (-1); lymph node enlargement (+1); atypical lymphocytes (+1); eosinophilia (+2); rash affecting greater than 50% body surface area (+1); edema and scaling (+1); biopsy suggestive of DRESS, unknown (0); internal organ involvement (+1); resolution delay of greater than 15 days (0); 3 or more negative biologic investigations, unknown (0). A score of 6 or more is definite DRESS syndrome.

Immediate withdrawal of the suspected medication and initiation of systemic corticosteroids are mainstays of treatment.^{5,10} Symptoms may persist weeks after causative agent discontinuation and treatment initiation.¹⁰ Flares are common despite management, and rapid reduction in corticosteroid dose can lead to relapse.^{5,10} Our patient experienced flares, but these resolved with continued

management and a slow taper. There is no consensus on optimal dose and duration of steroids; however, some recommend that a minimum of 1 mg/kg/d of systemic prednisone or an equivalent should be given for signs of severe organ involvement (eg, transaminases >5 times normal, renal involvement, pneumonia, hemophagocytosis, and cardiac involvement).¹⁰ Gradual tapering over 3 to 6 months may prevent relapse.¹⁰ In absence of severe organ involvement, topical corticosteroids with emollients and antihistamines are an option.¹⁰ For most, complete resolution occurs if the causative agent is discontinued, although some experience chronic exfoliative dermatitis or other long-term sequelae due to systemic damage.¹⁰

This case demonstrates DRESS syndrome is a potential adverse effect of alectinib. Clinicians should be aware of this reaction so close follow-up and thorough evaluation may be pursued in event of rash development after alectinib initiation.

REFERENCES

1. Husain Z, Reddy BY, Schwartz RA, Husain Z. DRESS syndrome: Part I. clinical perspectives. *J Am Acad Dermatol.* 2013;68(5):693.e1-693.e14. quiz 706-708.
2. Camidge DR, Dziadziuszko R, Peters S, et al. Updated efficacy and safety data and impact of the EML4-ALK fusion variant on the efficacy of alectinib in untreated ALK-positive advanced non-small cell lung cancer in the global phase III ALEX study. *J Thorac Oncol.* 2019;14(7):1233-1243.
3. Shirasawa M, Kubota M, Harada S, et al. Successful oral desensitization against skin rash induced by alectinib in a patient with anaplastic lymphoma kinase-positive lung adenocarcinoma: a case report. *Lung Cancer.* 2016;99:66-68.
4. Kimura T, Sowa-Osako J, Nakai T, et al. Alectinib-induced erythema multiforme and successful rechallenge with alectinib in a patient with anaplastic lymphoma kinase-rearranged lung cancer. *Case Rep Oncol.* 2016;9(3):826-832.
5. Cacoub P, Musette P, Descamps V, et al. The DRESS syndrome: a literature review. *Am J Med.* 2011;124(7):588-597.
6. Choudhary S, McLeod M, Torchia D, Romanelli P. Drug reaction with eosinophilia and systemic symptoms (DRESS) syndrome. *J Clin Aesthet Dermatol.* 2013;6(6):31.
7. Bocquet H, Bagot M, Roujeau JC. Drug-induced pseudolymphoma and drug hypersensitivity syndrome (Drug Rash with Eosinophilia and Systemic Symptoms: DRESS). *Semin Cutan Med Surg.* 1996;15(4):250-257.
8. Kardaun SH, Sidoroff A, Valeyrie-Allanore L, et al. Variability in the clinical pattern of cutaneous side-effects of drugs with systemic symptoms: Does a DRESS syndrome really exist? *Br J Dermatol.* 2007;156(3):609-611.
9. Shiohara T, Iijima M, Ikezawa Z, Hashimoto K. The diagnosis of a DRESS syndrome has been sufficiently established on the basis of typical clinical features and viral reactivations. *Br J Dermatol.* 2007;156(5):1083-1084.
10. Husain Z, Reddy BY, Schwartz RA, Husain Z. DRESS syndrome: Part II. management and therapeutics. *J Am Acad Dermatol.* 2013;68(5):709.e1-709.e9. quiz 718-720.