

Received: 2017.07.03
Accepted: 2017.09.07
Published: 2017.11.02

Recurrent Thrombosis: A Case of Hereditary Thromboembolism

Authors' Contribution:
Study Design A
Data Collection B
Statistical Analysis C
Data Interpretation D
Manuscript Preparation E
Literature Search F
Funds Collection G

E 1 **Maria Concetta Giofrè**
B 1 **Francesca Napoli**
C 1 **Daniela La Rosa**
G 1 **Alessia Caruso**
D 1 **Natascia Laganà**
C 2 **Lucia Orlando Settembrini**
F 1 **Antonino Saitta**
A 1 **Antonio Giovanni Versace**

1 Department of Clinical and Experimental Medicine, Azienda Ospedaliera Universitaria – Policlinico “G. Martino”, Messina, Italy
2 Azienda Ospedaliera “Pugliese-Ciaccio”, Catanzaro, Italy

Corresponding Author: Maria Concetta Giofrè, e-mail: giofremariaconcetta@libero.it
Conflict of interest: None declared

Patient: Female, 56
Final Diagnosis: Hereditary thrombophilia
Symptoms: Dyspnea
Medication: —
Clinical Procedure: —
Specialty: Hematology

Objective: Congenital defects/diseases

Background: Thrombophilia is a predisposition to thrombosis. Genetic causes include antithrombin III, protein C, protein S, factor V Leiden, prothrombin 20210A allele, and MTHFR mutations. Other genetic factors causing thrombosis and pulmonary embolism have been identified in recent studies, including 4G/4G polymorphism of the PAI-1 gene.





Case Report: A patient with a personal and family history of recurrent thrombosis and pulmonary embolism was admitted to our Internal Medicine Department. After the most common acquired risk factors for thromboembolism were ruled out, the patient and her family members underwent genetic diagnostic testing. These tests showed homozygous 4G/4G polymorphism of the PAI-1 gene in 14 subjects, homozygous 4G/4G polymorphism of the PAI-1 gene and C677T/A1298C polymorphism of the MTHFR gene in 4 subjects, and heterozygous 4G/4G polymorphism of the PAI-1 gene and C677T/A1298C polymorphism of the MTHFR gene in 3 subjects. Afterwards, we initiated the administration of Rivaroxaban, with beneficial results.

Conclusions: No thrombotic recurrence has been observed in the patient since 2014. This case report shows the efficacy and superiority of Rivaroxaban over traditional anticoagulants in the treatment of hereditary thrombophilia. Further studies are clearly needed before Rivaroxaban can be recommended as a standard treatment in patients with inherited thrombophilia.

MeSH Keywords: Anticoagulants • Factor X • Polymorphism, Restriction Fragment Length

Abbreviations: DVT – deep vein thrombosis; FDA – Food and Drug Administration; MTHFR – methylene tetrahydrofolate reductase; NOA – new oral anticoagulant; PAI-1 – plasminogen activator inhibitor-1; PE – pulmonary embolism; VKA – vitamin K antagonists

Full-text PDF: <https://www.amjcaserep.com/abstract/index/idArt/906035>

 837   1  10



Background

Thrombophilia is defined as a predisposition to thrombosis. It is caused by inherited or acquired causes. Genetic causes include antithrombin III, protein C, protein S, factor V Leiden, prothrombin 20210A allele, and MTHFR mutations [1]. Other genetic factors causing thrombosis or pulmonary embolism have been identified in recent studies, including factor VIII [2] and plasminogen activator inhibitor-1 (PAI-1) [3]. Acquired factors include neoplasms, oral contraceptive use, immobilization, immune diseases as the antiphospholipid syndrome [4], and surgery. The treatment is parenteral anticoagulation in the acute phase, and warfarin and the new oral anticoagulants (NOAs) in the chronic phase. Presently, the effectiveness of NOA therapy is unclear in inherited thrombophilia, as there is little evidence available in the literature. The duration of therapy depends on the type and severity of thrombosis. In hereditary thrombosis, its duration is above 6 months if the risk of recurrence is high and the bleeding risk is low. Extended treatment is justified by a high probability of recurrence after the first thrombosis or pulmonary embolism episode (25% after 5 years [5], and 30% after 10 years [6]) and high mortality rates (mortality rate is 6% for vein thrombosis and 12% for pulmonary embolism within 1 month of diagnosis) [7]. In this paper, we present the effects of Rivaroxaban treatment in a family suffering from hereditary thrombophilia.

Case Report

We present the case of a family suffering from recurrent thrombosis and pulmonary embolism due to hereditary thrombophilia, under treatment with Rivaroxaban.

A 56-year-old female patient was admitted to our Department of Emergency Medicine for deep vein thrombosis (DVT) of the right lower limb. Past medical history revealed that the patient had essential hypertension, and a previous episode of idiopathic venous thromboembolism treated with vitamin K antagonists (VKA) for a 3-month period.

She denied oral contraceptive use, recent surgery, immobilization, and exposure to other thrombosis risk factors, but she reported similar episodes involving her relatives, which is why we recommended the patient and some of her relatives (because 2 of them died of pulmonary embolism and 21 relatives were not available) undergo genetic testing.

Genetic tests revealed that 14 subjects (3 sisters and 11 grandchildren of the patient) were homozygous for PAI-1 4G/4G polymorphism, 4 individuals (2 brothers and 2 grandchildren of the patient) were homozygous for PAI-1 4G/4G polymorphism and MTHFR C677T/A1298C polymorphisms, and 3 individuals (1 sister and 2 grandchildren of patient) were heterozygous for PAI-1 4G/4G polymorphism and MTHFR C677T/A1298C polymorphisms (Figure 1).

The first 2 group of patients suffered from recurrent DVP and pulmonary embolism, although they were treated with VKA. We prescribed Rivaroxaban to the patients in the first 2 groups.

They have been regularly followed as outpatients since November 2014 and, to date, no patients have developed DVT, pulmonary embolism, or bleeding, which demonstrates that Rivaroxaban is effective for the treatment of hereditary thromboembolism.

Discussion

The present case involves Rivaroxaban treatment in a family affected by hereditary thrombophilia. This disorder is caused by altered transcription of antithrombin, protein C, protein S, factor V Leiden, prothrombin 20210 A allele, MTHFR, and PAI-1 genes.

In this family, we documented the presence of homozygous 4G/4G polymorphism of the PAI-1 gene in 14 subjects, homozygous 4G/4G polymorphism of the PAI-1 gene and C677T/A1298C polymorphism of the MTHFR gene in 4 subjects, and heterozygous 4G/4G polymorphism of the PAI-1 gene and C677T/A1298C polymorphism of the MTHFR gene in 3 subjects.

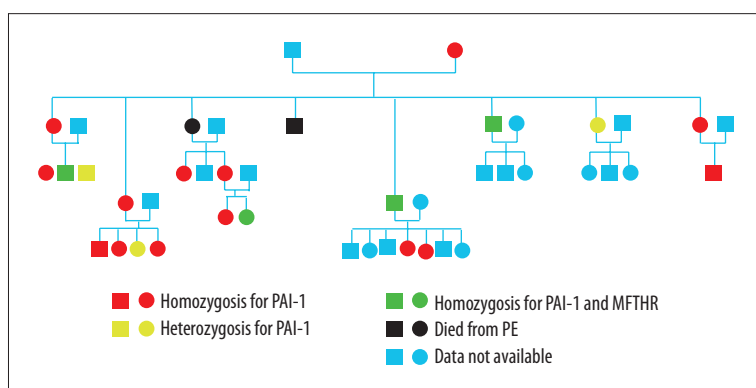


Figure 1. Genetic testing for polymorphisms.

Involvement of the PAI-1 gene has been described in recent literature [8]. Although current guidelines do not provide specific recommendations regarding the use of novel oral anticoagulants in hereditary thrombophilia, clinical trials with NOACs show overall success in the population treated with warfarin. In addition, there are controversial data concerning the efficacy of Rivaroxaban: Wypasek reported no resolution of venous thromboembolism with Rivaroxaban treatment in 2 patients (with overall superiority of enoxaparin), while Mertinelli, Cook, and Plander showed superior effectiveness of Rivaroxaban versus enoxaparin in 3 cases of hereditary thrombosis [9].

The patient in our study suffered from recurrent episodes of thrombosis despite long-term treatment with warfarin, which is why we decided to switch to Rivaroxaban, a direct factor Xa inhibitor, which is approved for acute and long-term treatment of DVT and PE. In the EINSTEIN study, Rivaroxaban was administered to a small population with inherited thrombophilia, but the types of genes involved were not reported [10]. Accordingly, further studies are needed to assess the efficacy of Rivaroxaban in these particular patients with thrombophilia.

References:

1. White RH: The epidemiology of venous thromboembolism. *Circulation*, 2003; 107(23 Suppl. 1): I4–8
2. Jenkins PV, Rawley O, Smith OP, O'Donnell JS: Elevated factor VIII levels and risk of venous thrombosis. *Br J Haematol*, 2012; 157(6): 653–63
3. Eriksson P, Kallin B, van't Hooft FM et al: Allele-specific increase in basal transcription of the plasminogen-activator inhibitor 1 gene is associated with myocardial infarction. *Proc Natl Acad Sci USA*, 1995; 92(6): 1851–55
4. Levine JS, Branch DW: The antiphospholipid syndrome. *N Engl J Med*, 2002; 346: 752–63
5. Prandoni P, Lensing AW, Cogo A et al: The long-term course of acute deep venous thrombosis. *Ann Intern Med*, 1996; 125: 1–7
6. Heit JA, Mohr DN, Silverstein MD et al: Predictors of recurrence after deep vein thrombosis and pulmonary embolism: A population-based cohort study. *Arch Intern Med*, 2000; 160: 761–68
7. Heit JA, Spencer FA, White RH: The epidemiology of venous thromboembolism. *J Thromb Thrombolysis*, 2016; 41(1): 3–14
8. Liguori R, Quaranta S, Di Fiore R et al: A novel polymorphism in the PAI-1 gene promoter enhances gene expression. A novel pro-thrombotic risk factor? *Thromb Res*, 2014; 134(6): 1229–33
9. Skelley JW, White CW, Thomason AR: The use of direct oral anticoagulants in inherited thrombophilia. *J Thromb Thrombolysis*, 2017; 43(1): 24–30
10. Bauersachs R, Berkowitz SD, Brenner B et al: Oral rivaroxaban for symptomatic venous thromboembolism. *N Engl J Med*, 2010; 363: 2499–510

Conclusions

In this article we want to emphasize, first of all, the efficacy of Rivaroxaban and its superiority over warfarin in this type of inherited thrombophilia, even though vitamin K antagonists still remain the criterion standard for management of these patients. Clearly, clinical trials are needed before Rivaroxaban can be recommended as a standard treatment for this disorder. Secondly, we want to highlight the importance of personal and family history in the diagnosis of hereditary thrombophilia. Thirdly, we emphasize the need to take into consideration rare mutations. Finally, accurate diagnosis is essential to initiate proper treatment.

Conflict of interests

None.