

This is an Open Access article licensed under the terms of the Creative Commons Attribution-NonCommercial-NoDerivs 3.0 License ([www.karger.com/OA-license](http://www.karger.com/OA-license)), applicable to the online version of the article only. Distribution for non-commercial purposes only.

# De novo Cryoglobulinaemic Mononeuritis Multiplex during Treatment of Chronic Hepatitis C Infection: A Viral Effect or Induced by Pegylated Interferon Alpha?

J.R. Potts<sup>a</sup> S. Atkinson<sup>b</sup> J.A. Aram<sup>c</sup> J. Tibble<sup>b</sup>  
K.A. Davies<sup>a</sup> S. Verma<sup>a</sup>

<sup>a</sup>Department of Medicine, Brighton and Sussex Medical School, and Departments of <sup>b</sup>Gastroenterology and <sup>c</sup>Neurology, Brighton and Sussex University Hospital NHS Trust, Brighton, UK

## Key Words

Hepatitis C virus · Mononeuritis multiplex · Cryoglobulinaemic vasculitis · Pegylated interferon

## Abstract

Cryoglobulinaemic mononeuritis multiplex (MNM) is an extrahepatic manifestation of chronic hepatitis C virus (HCV) infection for which interferon-based antiviral therapy is currently the treatment of choice. Rarely MNM can be associated with HCV treatment though generally in the setting of pre-existing cryoglobulinaemia and detectable HCV viraemia. We report an unusual case of de novo MNM occurring late during the course of pegylated interferon and ribavirin therapy for chronic HCV infection, following a prolonged period of viral suppression. The patient had no evidence of cryoglobulinaemia prior to HCV treatment and undetectable HCV RNA levels at the time of presentation with MNM. The case raises the possibility that MNM could develop as an adverse immunomodulatory effect of pegylated interferon therapy.

## Background

Chronic hepatitis C virus (HCV) infection is an important cause of chronic liver disease worldwide and a major indication for liver transplantation. Despite the exciting and promising discovery of direct-acting antiviral agents [1], pegylated interferon alpha (PEG-IFN $\alpha$ ) and ribavirin will remain the backbone of HCV therapy for the foreseeable future. Numerous extrahepatic features are associated with chronic HCV infection, of which essential mixed (type II) cryoglobulinaemia is well recognised [2]. Mixed cryoglobulinaemia is a systemic vasculitis affecting small and medium-sized arteries and veins. It is characterized by the deposition of immune complexes containing rheumatoid factor, IgG, HCV RNA and complement on endothelial surfaces, eliciting vascular inflammation through poorly understood mechanisms [3]. Clinical manifestations include skin lesions and a peripheral mixed sensory and motor neuropathy. These signs and symptoms tend to occur in the setting of detectable circulating HCV RNA levels and normally respond to therapy with PEG-IFN $\alpha$  and ribavirin [2].

Exacerbations of vasculitic symptoms have been reported during interferon therapy, but they have almost always occurred in those with pre-existing vasculitis or cryoglobulinaemia [4, 5]. Occurrence of de novo cryoglobulinaemic vasculitis after successful viral suppression late in the course of interferon therapy is unusual, especially with use of the pegylated form. We report a case of severe de novo cryoglobulinaemic mononeuritis multiplex (MNM) that occurred during week 30 of antiviral treatment for chronic HCV infection. Cryoglobulins had been undetectable in the pre-treatment period and at the time of presentation the patient was HCV RNA-negative.

## Case Report

A 47-year-old Caucasian man was referred by his primary care physician to the Hepatitis Clinic at our institution following the finding of abnormal liver function tests and elevated serum ferritin. Risk factors for liver disease included a brief period of injection drug use 20 years previously. His alcohol intake was within the national recommended limits (~20 units/week) and there was no prior history of neurological, psychiatric or rheumatological illness. On examination there were no stigmata of chronic liver disease. Screening blood tests showed positive serology for HCV, genotype 1a, with a viral load of  $1.68 \times 10^5$  IU/ml (PCR, Abbott). An exhaustive screen for other causes of chronic liver disease (including HFE gene mutation analysis) was negative and abdominal ultrasonography was unremarkable. Percutaneous liver biopsy revealed incomplete cirrhosis (Ishak fibrosis stage 5), with a necroinflammatory score of 6/18, there being no histological evidence of iron overload. In view of the advanced hepatic fibrosis, antiviral treatment was recommended, and the risk and benefits of therapy were clearly discussed. This included potential side effects such as 'flu-like' and neuropsychiatric symptoms, haematological side effects and the small risk of hepatic decompensation. Pre-treatment bloods tests were as follows: haemoglobin 15.3 g/dl (13.5–18), white blood cells  $5.5 \times 10^9$ /l (4.0–11.0), platelets  $203 \times 10^9$ /l (150–450), bilirubin 9  $\mu$ mol/l (0–21), alanine aminotransferase (ALT) 226 IU/l (0–41), alkaline phosphatase 68 IU/l (40–129), albumin 44 g/l (34–48), INR 1.0 (0.8–1.2). Rheumatoid factor was elevated at 88 IU/ml (0–14) and C4 complement low at 0.03 g/l (0.14–0.54) with normal C3 levels. Whilst anti-nuclear antibody (ANA) had been positive on initial referral (1:160 titre), this was negative on repeat testing and cryoglobulins were undetectable.

In accordance with current guidelines [6], antiviral treatment with PEG-IFN $\alpha$  2a (Pegasys, Roche) 180  $\mu$ g weekly and weight-based ribavirin (Copegus, Roche) 1,000 mg daily was initiated for a planned 48-week course. Early virological response (EVR; undetectable HCV RNA at week 12 of

treatment) was achieved and in the initial stages antiviral treatment was well tolerated, except for mild lethargy.

The patient presented to hospital during week 30 of antiviral therapy with progressive painful bilateral foot drop of 2 weeks duration, associated with left ankle monoarthritis and weakness and sensory loss in the distribution of the left ulnar nerve. A week later the right ulnar nerve had become involved although less severely. A clinical diagnosis of MNM was made, corroborated by compatible neurophysiology studies suggesting an asymmetrical mixed sensory and motor peripheral neuropathy. Cerebrospinal fluid analysis and magnetic resonance imaging of the spine showed no abnormality. When repeated, cryoglobulin levels were found to be significantly elevated (8%) and analysis demonstrated a mixed (type II) picture. HCV RNA was still undetectable and serum transaminases remained normal. ANA was again positive (1:160 titre) with an elevated rheumatoid factor (201 IU/ml vs. 88 IU/ml at initiation of antiviral therapy) and low C4 (0.03 g/l, unchanged from pre-treatment levels) with normal C3 levels. Antineutrophil cytoplasmic antibody was undetectable.

PEG-IFN $\alpha$  and ribavirin were discontinued immediately and oral prednisolone 40 mg daily was commenced. Despite immunosuppression the patient's clinical state worsened over the following week with the development of cutaneous vasculitic stigmata and progressive bilateral median and common peroneal nerve palsies.

In view of the progressive disease and persistence of cryoglobulinaemia, plasma exchange was performed (5 sessions over 1 week) and cyclophosphamide initiated (150 mg/day). Neurological function stabilised and neuropathic pain rapidly improved following plasma exchange. Cryoglobulin levels were subsequently undetectable and remained so over the following 8 weeks. Cyclophosphamide was well tolerated and continued for 2 months before changing to azathioprine 75 mg twice daily. Prednisolone was increased to 80 mg daily and subsequently weaned progressively, aiming to taper completely over 12 months. A slow but steady partial neurological recovery was observed in the outpatient clinic over the following 4 months, with resolution of median and common peroneal nerve palsies and improvement in the other affected areas. Joint pain resolved completely and the patient became ambulant with two sticks.

Given that the severe MNM occurred during the course of antiviral therapy, we deemed it appropriate to discontinue PEG-IFN $\alpha$  and ribavirin. This was a difficult decision in view of the advanced hepatic fibrosis and encouraging initial response to treatment with achievement of EVR. However, since MNM was the more immediately life-threatening condition with progressive weakness affecting all four limbs, discontinuation of antiviral therapy was justified. Not unsurprisingly, the patient developed virological rebound in HCV RNA ( $5.6 \times 10^5$  IU/ml) approximately 1 month after the withdrawal of antiviral therapy and initiation of immunosuppression. This was not associated with any hepatic decompensation. The time course of ALT, HCV RNA, rheumatoid factor and cryoglobulin levels in relation to antiviral treatment, the development of MNM and immunosuppression are shown in [fig. 1](#).

Unfortunately, 3 months after the onset of neurological disease the patient's mood worsened with the development of biological features of depression. Antidepressants were commenced but his depression worsened, and regrettably the patient died following a drug overdose 10 months after the onset of MNM. Post-mortem examination indicated that the cause of death was unrelated to liver disease or cryoglobulinaemia.

## Discussion

We have described a patient with HCV-related cirrhosis who developed de novo cryoglobulinaemic MNM late in the course of antiviral therapy with PEG-IFN $\alpha$  and ribavirin. At the time of neurological presentation he had received 30 weeks of antiviral treatment with negative HCV RNA since week 12 of therapy. There was no prior history of vasculitis and pre-treatment testing for cryoglobulins had been negative. Our case is unique as occurrence of de novo cryoglobulinaemic vasculitis after successful viral suppression late in the course of interferon therapy is most unusual. Exacerbations of

vasculitic symptoms have in fact been reported during interferon therapy, but almost always occur in those with pre-existing vasculitis or cryoglobulinaemia [4, 5].

MNM is a well-documented complication of chronic HCV infection, normally associated with HCV viraemia, and typically responds to antiviral treatment. In our case the temporal association (both in terms of onset and recovery) between neurological symptoms, cryoglobulinaemia and the use of antiviral treatment raises the intriguing possibility that MNM could have been induced by antiviral therapy. However, it must be emphasised that at present this presumed association between PEG-IFN $\alpha$  2a and MNM remains speculative. The various immunomodulatory effects of interferon that may have contributed to the development of MNM include upregulation of MHC class I and downregulation of MHC class II expression, increased cytolytic activity of natural killer cells, increased dendritic cell activation and antigen uptake and presentation from apoptotic cells and finally increased production of autoantibodies [7, 8].

The association between HCV and vasculitis is well established, related usually to the development of cryoglobulinaemia or, less commonly, a non-cryoglobulinaemic polyarteritis nodosa-type disease [4]. Estimates of mixed cryoglobulinaemia prevalence in patients with HCV infection vary widely from 10 to 70%, perhaps a reflection of population selection and lead time biases [3]. High viral titres and the presence of type II cryoglobulinaemia, as present in this case, increase the likelihood of clinically apparent vasculitic disease [9]. When present pre-treatment these diseases usually abate and improve with the initiation of PEG-IFN $\alpha$  and ribavirin and hence antivirals can be used for treatment of symptomatic cryoglobulinaemia associated with HCV infection [10]. However interferon therapy has also been associated with the development/exacerbation of various underlying autoimmune diseases including HCV-associated vasculitis, systemic lupus erythematosus and rheumatoid arthritis [11, 12]. There are also reports of the development and/or exacerbation of cryoglobulinaemic disease upon commencement of pegylated interferon therapy [4, 5], though these have almost always occurred in those with pre-existing vasculitis. The time span between the initiation of interferon therapy and the development or exacerbation of vasculitis is usually short, typically within the first few doses. These problems seem far less frequent with the pegylated form compared to standard interferon [13]. Finally, interferon may induce its own non-cryoglobulinaemic vasculitis [14].

De novo MNM during pegylated interferon therapy for HCV is more unusual, with only two prior published cases [13, 15]. In the case reported by Jacobi et al. [15] the patient achieved a rapid virological response (undetectable HCV RNA by week 4 of treatment) and first presented with MNM 6 weeks into antiviral therapy. Beuthien et al. [13] describe a case of MNM occurring later in the course of PEG-IFN $\alpha$  treatment, with the onset of neurological symptoms at week 40 in a patient with negative HCV RNA since week 24. Similar to our case report, these two patients were also men and at least one also had advanced hepatic fibrosis. However in both cases it is unclear whether there was pre-existing cryoglobulinaemia before the initiation of antiviral therapy. In contrast, cryoglobulins were undetectable in our patient prior to therapy, though pre-treatment work-up did reveal a positive ANA (titre 1:160), elevated rheumatoid factor and suppressed C4 level. The significance of these findings in the absence of detectable cryoglobulins or clinical evidence of vasculitis is uncertain. Conceivably they could be representative of low-level cryoglobulinaemia below the threshold for

detection, resulting in an increased propensity to develop a nascent autoimmune process.

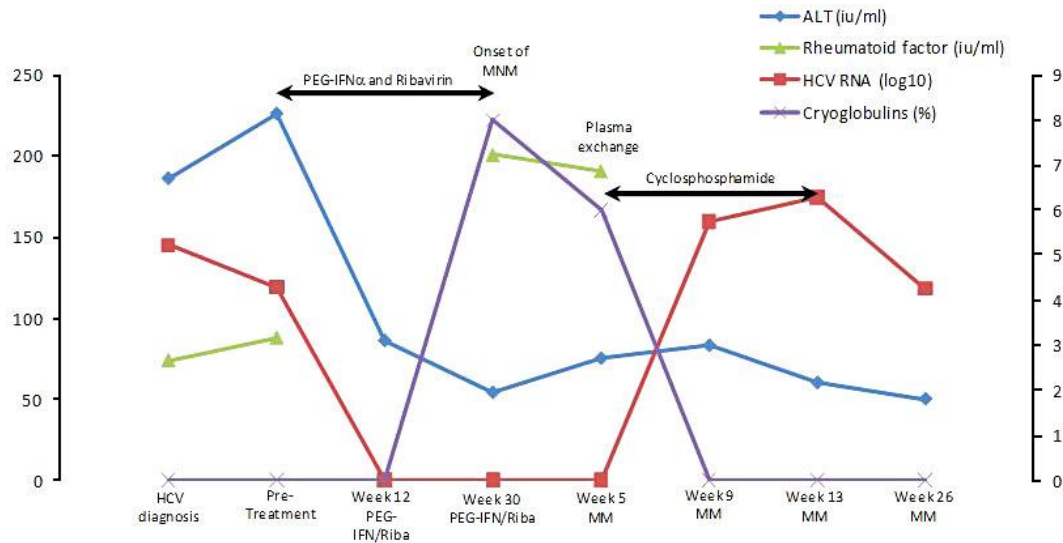
When performed, nerve biopsy in patients with mixed cryoglobulinaemic MNM typically shows a perivascular lymphocytic infiltrate. However, as indicated above, it is possible for the direct neuropathic effects of both HCV and PEG-IFN $\alpha$  to result in an ischaemic rather than vasculitic neuropathy [14]. Our patient did not undergo nerve biopsy and it may be argued that histology is required in order to discriminate between direct IFN $\alpha$ -induced and mixed cryoglobulinaemic neuropathies. In the case we describe there was a significant deterioration in symptoms following withdrawal of PEG-IFN $\alpha$  and disease only stabilised and subsequently ameliorated once specific therapy for cryoglobulinaemic disease had been initiated. Additionally, the clinical picture was that of MNM rather than progressive peripheral neuropathy usually associated with IFN $\alpha$  [13]. We would therefore maintain that the clinical course in this case strongly favours mixed cryoglobulinaemic vasculitis over IFN $\alpha$ -induced neuropathy.

### Conclusions

In summary we report a patient with HCV-related cirrhosis who developed de novo MNM associated with cryoglobulinaemia during week 30 of antiviral therapy, having achieved EVR. While interferon therapy is the treatment of choice for HCV-related MNM, exacerbations have been reported during its use. Usually this has been reported in those with pre-existing cryoglobulinaemia and in the setting of detectable HCV viraemia. The de novo development of MNM during HCV therapy with undetectable HCV RNA is most unusual. This raises the possibility that MNM could have developed as an adverse immunomodulatory effect of interferon therapy. However it must be re-emphasized that at present this association remains speculative. Nonetheless, such patients with advanced hepatic fibrosis present a challenging dilemma as the inevitable virological rebound after discontinuation of antiviral therapy can have grave implications. Clinical trials exploring interferon-free HCV treatment regimens are ongoing and these could ease the management of such patients in the future.

### Disclosure Statement

The authors have no conflicts of interest to disclose.



**Fig. 1.** Graph showing the time course of ALT, HCV RNA, rheumatoid factor and cryoglobulins relative to onset of MNM, antiviral therapy and immunosuppression.

## References

- Sarrazin C, Hézode C, Zeuzem S, Pawlotsky JM: Antiviral strategies in hepatitis C virus infection. *J Hepatol* 2012;56(suppl 1):S88–S100.
- Cacoub P, Maisonneuve T, Thibault V, et al: Systemic vasculitis in patients with hepatitis C. *J Rheumatol* 2001;28:109–118.
- Charles ED, Dustin LB: Hepatitis C virus-induced cryoglobulinemia. *Kidney Int* 2009;76:818–824.
- Gordon AC, Edgar JD, Finch RG: Acute exacerbation of vasculitis during interferon-alpha therapy for hepatitis C-associated cryoglobulinaemia. *J Infect* 1998;36:229–230.
- Friedman G, Mehta S, Sherker AH: Fatal exacerbation of hepatitis C-related cryoglobulinemia with interferon-alpha therapy. *Dig Dis Sci* 1999;44:1364–1365.
- European Association for the Study of the Liver: EASL Clinical Practice Guidelines: management of hepatitis C virus infection. *J Hepatol* 2011;55:245–264.
- Jego G, Palucka AK, Blanck JP, Chalouni C, Pascual V, Banchereau J: Plasmacytoid dendritic cells induce plasma cell differentiation through type I interferon and interleukin 6. *Immunity* 2003;19:225–234.
- Rizza P, Moretti F, Belardelli F: Recent advances on the immunomodulatory effects of IFN-alpha: implications for cancer immunotherapy and autoimmunity. *Autoimmunity* 2010;43:204–209.
- Donada C, Crucitti A, Donadon V, et al: Systemic manifestations and liver disease in patients with chronic hepatitis C and type II or III mixed cryoglobulinaemia. *J Viral Hepat* 1998;5:179–185.
- Misiani R, Bellavita P, Fenili D, et al: Interferon alfa-2a therapy in cryoglobulinemia associated with hepatitis C virus. *N Engl J Med* 1994;330:751–756.
- Fattovich G, Giustina G, Favarato S, Ruol A: A survey of adverse events in 11,241 patients with chronic viral hepatitis treated with alfa interferon. *J Hepatol* 1996;24:38–47.
- Wilson LE, Widman D, Dikman SH, Gorevic PD: Autoimmune disease complicating antiviral therapy for hepatitis C virus infection. *Semin Arthritis Rheum* 2002;32:163–173.

- 13 Beuthien W, Mellinghoff HU, von Kempis J: Vasculitic complications of interferon-alpha treatment for chronic hepatitis C virus infection: case report and review of the literature. *Clin Rheumatol* 2005;24:507–515.
- 14 Lidove O, Cacoub P, Maisonneuve T, et al: Hepatitis C virus infection with peripheral neuropathy is not always associated with cryoglobulinaemia. *Ann Rheum Dis* 2001;60:290–292.
- 15 Jacobi C, Müller HD, Korporeal M, Back T, Wildemann B: Mononeuropathy multiplex as a result of treatment with interferon-alpha and ribavirin in a patient with hepatitis C. *Eur J Neurol* 2008;15:e55–e56.