



Case report

Advanced colorectal cancer resulting in acute bowel obstruction during pregnancy; a case report

Rikkert R. Ossendorp ^{a, b, *}, Rob Silvis ^a, Gerben J. van der Bij ^b^a Department of Surgery, Spaarne Gasthuis, P.O. Box 417, 2000 AK, Haarlem, The Netherlands^b Department of Surgery, VU University Medical Center, P.O. Box 7057, 1007 MB, Amsterdam, The Netherlands

H I G H L I G H T S

- Abdominal pain during gravidity is a commonly seen in the emergency room.
- Even though the incidence is low, it may still be a sign of serious abdominal pathology.
- Additional imaging is required when diagnosing acute abdominal pain during pregnancy.
- Suspicion of serious abdominal pathology should arise when no progress is seen during conservative treatment.
- If the diagnosis is made and the gestational age is sufficient, surgery should not be delayed.

A R T I C L E I N F O

Article history:

Received 9 February 2016

Received in revised form

18 April 2016

Accepted 19 April 2016

Keywords:

Abdominal pain
Colorectal neoplasms
Diagnostic imaging
Pregnancy
Surgery

A B S T R A C T

Introduction: Abdominal pain is frequently found in the pregnant population; however life-threatening pathology such as colorectal cancer does occur rarely. As such, intestinal obstructions are usually attributed to pregnancy-related issues. We present the case of a young woman with an acute bowel obstruction caused by advanced colorectal carcinoma.

Presentation of Case: A 34-year old pregnant woman was referred to our emergency department with complaints of severe upper abdominal pain. Initial investigations did not show abdominal pathology and conservative treatment for obstipation was commenced. However, complaints persisted and a near blowout of the colon was diagnosed, prompting a caesarean section and diagnostic laparotomy. An obstructing tumour was found and a left-sided hemi-colectomy was performed. Unfortunately, skeletal, lymphatic and additional hepatogenic metastasis were discovered during chemotherapy and treatment was discontinued.

Discussion and conclusion: The mainstay of abdominal complaints during pregnancy can be attributed to normal physiological alterations associated with gravidity. Nonetheless serious pathology should be considered, especially when conservative treatment fails. On this note, diagnostic imaging during pregnancy should be used promptly upon suspicion of serious abdominal pathology.

© 2016 Published by Elsevier Ltd on behalf of IJS Publishing Group Ltd. This is an open access article under the CC BY-NC-ND license (<http://creativecommons.org/licenses/by-nc-nd/4.0/>).

1. Introduction

Abdominal pain, altered bowel movements, nausea, vomiting and rectal bleeding are commonly found in the pregnant population. In the vast majority of women, these symptoms reflect altered physiology that is normally accompanied with pregnancy. However, albeit rare, life-threatening abdominal pathology does occur

in this population. The incidence of CRC during pregnancy is estimated at 0.002% or in about 1 case per 13,000 gestations [1–3]. The majority of these tumours are found in the rectum or sigmoid and many are diagnosed at an advanced stage [4]. In the general population, acute bowel obstruction as the first symptom of CRC is commonly seen and therefore well recognized [5]. Due to the low incidence however, intestinal obstructions in pregnant women due to CRC are extremely rare and are usually attributed to pregnancy-related issues. In this article, we will present the case of a young woman with an acute bowel obstruction caused by CRC in an advanced stage.

* Corresponding author. Department of Surgery, Spaarne Gasthuis, P.O. Box 417, 2000 AK, Haarlem, The Netherlands

E-mail address: rr.ossendorp@vumc.nl (R.R. Ossendorp).

2. Presentation of case

A 34-year old pregnant woman was referred to our emergency department with complaints of severe upper abdominal pain. She suffered from nausea, vomiting and did not have defecation for 5 days. No signs of infection were present. The foetus was 32 weeks of estimated gestational age and the mother had not suffered from any complaints throughout her pregnancy. A previous pregnancy resulted in a successful caesarean section due to abruption placentae and a re-laparotomy was needed at the time to stop postoperative bleeding. There was no family history of colorectal, endometrial, breast or ovarian cancer.

Physical examination showed a distended abdomen with absent bowel sounds. No abnormalities were found by gynaecological ultrasound. Due to the severity of the complaints, following local standards, a computed tomography-scan (CT) with intravenous contrast was made to rule out underlying pathology and the patient was admitted to our obstetrics ward and treated for obstipation with laxatives and enema's. The scan showed faecal impaction in the colon but no clear bowel obstruction or tumour (Fig. 1). As such, conservative treatment for obstipation was continued, but proved unsuccessful. Three days later plain radiographic imaging revealed a near blowout of the colon, prompting a caesarean section and diagnostic laparotomy (Fig. 2). An obstructing tumour was found in the splenic flexure and a left-sided hemi-colectomy was performed with formation of a stoma. Postoperative recovery of both the patient and the premature baby, born at 33 weeks of gestational age, was uncomplicated.

Pathologic examination revealed a malignant adenoma of 2 cm diameter with lymphatic, intramural and extramural invasion. Fourteen out of fifteen lymph nodes contained metastasis. Liver dissemination was found using Positron Emission Tomography (PET), resulting in a stage IV/Dukes D colon tumour (T3 N2 M1 (WHO 5th edition)).

In agreement with the clinical oncologist the patient commenced an intensive chemotherapy course. Regrettably there were signs of hepatic tumour growth and new skeletal metastasis were found and chemotherapy was altered. Due to lymphatic dissemination, a pulmonary lymphangitic carcinomatosis developed and in concordance with the relatives all treatment was

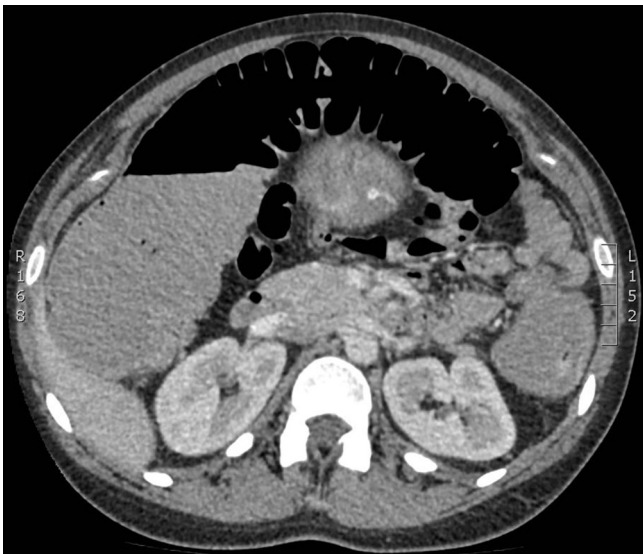


Fig. 1. Transverse plane of abdominal CT-scan showing the lineal flexure and faecal impaction.

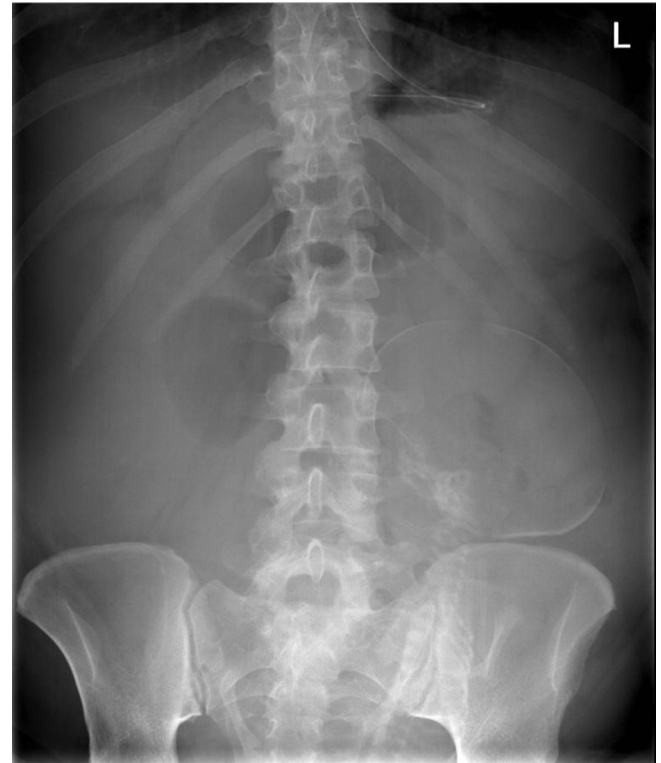

Fig. 2. Plain abdominal radiographic image showing a distended transverse colon.

discontinued. Our patient passed away at 36 years of age.

Genetic analysis using a panel of 135 known genes showed no genetic causes for the bowel carcinoma. Molecular analysis was negative for Lynch syndrome or Microsatellite Instability, solely a TP53 mutation was found. Chemotherapy choices were based on a BRAF and KRAS wild type, plus an TP53 mutation. Unfortunately, CEA expression was a mere 10%, excluding trial chemotherapy.

3. Discussion

This report describes the unfortunate case of a young pregnant female with metastatic CRC discovered at an advanced stage. Although no clear signs of intra-abdominal pathology were present before or during the course of pregnancy, the malignancy resulted in an acute bowel obstruction that called for immediate caesarean section and resection of the left colon.

The mainstay of abdominal complaints during pregnancy can be attributed to normal physiological alterations associated with gravidity. Nonetheless, just as in the general population, non-obstetric pathology should be considered when complaints are specific, severe or perseverate. Unfortunately, symptoms of abdominal pathology can be either absent or altered during pregnancy, impeding proper diagnosis. Approximately 1 in 500 pregnancies develop an acute abdomen and up to 1% of women require surgery for a non-obstetric problem [6]. Whereas appendicitis, cholecystitis, urinary tract infection, urolithiasis and gastroenteritis are not uncommon; vascular causes, acute pancreatitis and bowel obstruction are infrequently seen in pregnant women [7]. Bowel obstruction occurs in about 1 in 2500–3500 pregnancies. Adhesions and volvulus are the most common reason of bowel obstruction, next to intussusception, hernias and malignancies [8,9]. The majority of abdominal pathology during gestation is infectious or mechanical, but malignancies cannot be ruled out without adequate imaging.

There has been much debate on the use of diagnostic imaging during pregnancy. Standard imaging techniques frequently need to be adapted to minimize teratogenic and carcinogenic effects to the foetus. Ultrasound remains the primary choice in the diagnosis of abdominal disease and is often appropriate for appendicitis and cholecystitis. However, sensitivity for other abdominal pathology including CRC, is low and further diagnostics are frequently necessary when ultrasounds is negative [10]. Magnetic Resonance Imaging (MRI) without the use of gadolinium has been proven useful in the diagnosis of abdominal problems during pregnancy and should be the next diagnostic tool when available [7,11,12]. When MRI is unavailable or inconclusive, CT can be of great value. However, especially during the first two trimesters of pregnancy, CT should be used with caution due to the hazardous effects on the foetus [7,13]. In the presented case, diagnostic imaging did not show a mechanical bowel obstruction, and the patient displayed no clinical improvement. When persistent bowel obstruction is diagnosed or highly anticipated, exploratory laparotomy must be commenced since prompt operative intervention maximizes outcome for both foetus and mother.

4. Conclusion

Pregnant women presenting with an acute abdomen can be very challenging for physicians. Notably bowel obstruction is difficult to diagnose as the signs and symptoms such as pain, distention, vomiting and constipation can be easily attributed to normal pregnancy. As well, gravidity requires alternative use of diagnostics tools, further hampering quick and adequate diagnosis. Nonetheless, we like to emphasize that diagnostic imaging should be used promptly upon suspicion of serious abdominal pathology. Moreover, when severe pathology such as bowel obstruction is diagnosed or anticipated, surgery should not be delayed.

Consent

Written informed consent was obtained from the patient for publication of this case report and accompanying images. A copy of the written consent is available for review by the Editor-in-Chief of this journal on request.

Ethical approval

None.

Funding

None.

Conflict of interest

None of the participating authors have received either a financial or personal benefit with regard to this article and thus do not have a conflict of interests.

Guarantor

R.R. Ossendorp, MD.

Acknowledgements

All authors have made a substantial and equal contribution to submitting the attached article. No third party was involved during the process.

References

- [1] C. Walsh, V.W. Fazio, Cancer of the colon, rectum, and anus during pregnancy. The surgeon's perspective, *Gastroenterol. Clin. North Am.* 27 (1998) 257–267, [http://dx.doi.org/10.1016/S0889-8553\(05\)70356-3](http://dx.doi.org/10.1016/S0889-8553(05)70356-3).
- [2] N.A. Pavlidis, Coexistence of pregnancy and malignancy, *Oncologist* 7 (2002) 279–287, <http://dx.doi.org/10.1634/theoncologist.2012-0432>.
- [3] S. De Carolis, F. Grimalizzi, S. Garofalo, G. Fatigante, S. Ferrazzani, B. Carducci, et al., Cancer in pregnancy: results of a series of 32 patients, *Anticancer Res.* 26 (2006) 2413–2418.
- [4] M. Bernstein, R. Madoff, P. Cashaj, *Colon and rectal cancer in pregnancy*, *Dis. Colon Rectum* 36 (1993) 172–178.
- [5] R. Cirocchi, E. Farinella, S. Trastulli, J. Desiderio, C. Listorti, C. Boselli, et al., Safety and efficacy of endoscopic colonic stenting as a bridge to surgery in the management of intestinal obstruction due to left colon and rectal cancer: a systematic review and meta-analysis, *Surg. Oncol.* 22 (2013) 14–21, <http://dx.doi.org/10.1016/j.suronc.2012.10.003>.
- [6] L. Diegelmann, Nonobstetric abdominal pain and surgical emergencies in pregnancy, *Emerg. Med. Clin. North Am.* 30 (2012) 885–901, <http://dx.doi.org/10.1016/j.emc.2012.08.012>.
- [7] G. Masselli, L. Derchi, J. McHugo, A. Rockall, P. Vock, M. Weston, et al., Acute abdominal and pelvic pain in pregnancy: ESUR recommendations, *Eur. Radiol.* 23 (2013) 3485–3500, <http://dx.doi.org/10.1007/s00330-013-2987-7>.
- [8] E. Kalu, E. Sherriff, M.A. Alsibai, M. Haidar, Gestational intestinal obstruction: a case report and review of literature, *Arch. Gynecol. Obstet.* 274 (2006) 60–62, <http://dx.doi.org/10.1007/s00404-005-0097-8>.
- [9] P.W. Perdue, H.W. Johnson, P.W. Stafford, *Intestinal obstruction complicating pregnancy*, *Am. J. Surg.* 164 (1992) 384–388.
- [10] K.T. Baron, E.K. Arleo, C. Robinson, P.C. Sanelli, Comparing the diagnostic performance of MRI versus CT in the evaluation of acute nontraumatic abdominal pain during pregnancy, *Emerg. Radiol.* 19 (2012) 519–525, <http://dx.doi.org/10.1007/s10140-012-1066-8>.
- [11] E. Kanal, A.J. Barkovich, C. Bell, J.P. Borgstede, W.G. Bradley, J.W. Froelich, et al., ACR guidance document on MR safe practices: 2013, *J. Magn. Reson. Imaging* 37 (2013) 501–530, <http://dx.doi.org/10.1002/jmri.24011>.
- [12] Y. Patenaude, D. Pugash, K. Lim, L. Morin, S. Bly, K. Butt, et al., The use of magnetic resonance imaging in the obstetric patient, *J. Obstet. Gynaecol. Can.* 36 (2014) 349–355, <http://www.ncbi.nlm.nih.gov/pubmed/24798674>.
- [13] M.M. Chen, F.V. Coakley, A. Kaimal, R.K. Laros, Guidelines for computed tomography and magnetic resonance imaging use during pregnancy and lactation, *Obstet. Gynecol.* 112 (2008) 333–340, <http://dx.doi.org/10.1097/AOG.0b013e318180a505>.