

THEMATIC REVIEW

EDUCATIONAL SERIES ON THE SPECIALIST VALVE CLINIC

The central role of the cardiac imager in heart valve disease

Erwan Donal MD PhD¹, Elena Galli MD PhD¹, Amedeo Anselmi MD PhD², Auriane Bidaut MD¹ and Guillaume Leurent MD¹

¹University of Rennes, CHU Rennes, Inserm, LTSI – UMR 1099, Rennes, France

²The Cardio Vascular Surgical Department, University of Rennes, CHU Rennes, Rennes, France

Correspondence should be addressed to E Donal: erwan.donal@chu-rennes.fr

This paper is part of a series on specialist valve clinics. The Guest Editors for this series were Richard P Steeds and John B Chambers

Abstract

In this review, we discuss the central role of the imager in the heart team in the successful application of current guidelines for heart valve diseases to daily practice, and for improving patient care through new approaches, new techniques and new strategies for dealing with increasingly complex cases. This is an opportunity to emphasize the importance of having good imagers and the value of continuous learning in a modern heart team. It is essential to employ technological improvements and to appropriately adapt guidelines to the patients we see day to day.

Key Words

- ▶ imagers
- ▶ heart valve team
- ▶ guidelines

Introduction

The timing for heart valve surgery is based on the combination of the clinical evaluation of the patient and imaging assessments. It depends also on local expertise in surgical techniques and in interventional cardiology approaches. In this review, we will focus on the imaging and clinical aspects, which have extremely strong interdependencies, together with interactions with surgical and interventional expertise (1, 2, 3).

The role of the imager in the heart team and during percutaneous procedures

The importance of cardio-vascular imagers is increasing as techniques are improved, or new technologies are developed, for solving many of the issues related to valvular heart disease (VHD).

In 2016, the ESC guidelines on VHD were published based on a few randomized studies, together with a great deal of observational data and expert consensus (1). Since the 2016 ESC guidelines were published, more data has been published, especially in the field of percutaneous approaches to the treatment of aortic valve stenosis and mitral regurgitation. The concept of the heart team and the concept of heart valve clinics have been emphasized by these recent guidelines. Therefore, our daily practice is based on these guidelines: imagers, interventionists and surgeons combine their strengths in order to improve patient management. However, imagers and others still have a lot to learn from each other: new concepts, clinical experience, the latest devices and the development of new strategies to integrate into daily practice.

For the past 40 years, VHD has usually been treated by open-heart surgery. This approach has been extremely

useful and has saved so many lives all over the world that it remains the gold standard treatment, and the benchmark against which all reassessment of the management of VHD is measured.

Nevertheless, the increasing age of patients with VHD, the presence of comorbidities, concomitant end-organ disease and frailty can lead to a significant increase in surgical risk, and may contraindicate open-heart surgery (4).

Therefore, it is now possible to treat aortic, pulmonary, tricuspid valve disease and peri-prosthetic leaks by percutaneous approaches. These approaches are based on the development of new, specific devices and represent an exciting new challenge for cardiac imagers: appropriate candidates must be identified pre-operatively, the implantation of the device must be monitored, and follow-up must be conducted with patients after interventions. This strategy will ensure positive outcomes and guide the optimization of pharmacological treatment.

The pre-procedural phase is often based on a multimodal approach, which requires the combination of trans-thoracic and trans-oesophageal echocardiography, cardiac CT and MRI data. The assessment of heart valve disease should not be dissociated from the assessment of overall left and right heart morphology and function. After this preliminary phase, the imager has a pivotal role in the choice of device and in procedural guidance. In recent years, the development of real-time 3D trans-oesophageal echocardiography, intracardiac echocardiography, and fusion imaging, has paved the way for a more comprehensive evaluation and management of VHD, which simplifies the overall percutaneous procedure. This phase requires a strict collaboration between cardiac

imagers and invasive cardiologists, and the development of a mutual relationship of confidence and respect (Fig. 1).

The aortic valve stenosis

The assessment of patients with aortic stenosis has changed considerably in recent years, especially with regard to TAVI. As imagers are no longer involved in the implantation of the prosthesis in aortic stenosis in most centers, the role of the imager is perhaps less obvious than in other heart valve diseases. Nevertheless, imagers play an important role and should not be excluded from any heart team which specializes in the management of aortic stenosis. Imagers are valuable in identifying anatomical considerations that may make TAVI unappealing, such as a small aortic annulus, heavily calcified LVOT, concomitant significant primary mitral valve disease (e.g. MV prolapse), or marked basal septal thickening which encroaches into the LVOT. These are just some example findings from echocardiography; imagers are also the people who deal (before any heart team meeting) with a diagnosis of amyloidosis (5) or with the different kinds of aortic valve stenosis (6, 7). Low-flow low-gradient AS is one example of a condition which demands expertise in dobutamine stress echocardiography and in cross-sectional imaging (cardiac CT and cardiac MRI); expertise which imagers possess. Cardiac CT is now essential in the decision-making process for many patients with aortic stenosis. Cardiac CT images calcification (8), the anatomy of the aortic root, and the anatomy of the arterial tree (any tortuosity of the iliofemoral vessels is very important in determining whether a patient could

Grasping of the mitral valve leaflets by a mitralclip positioned perpendicular to A2 – P2 using the intercommissural view and long axis and the 3D rendering ‘en-face’ view

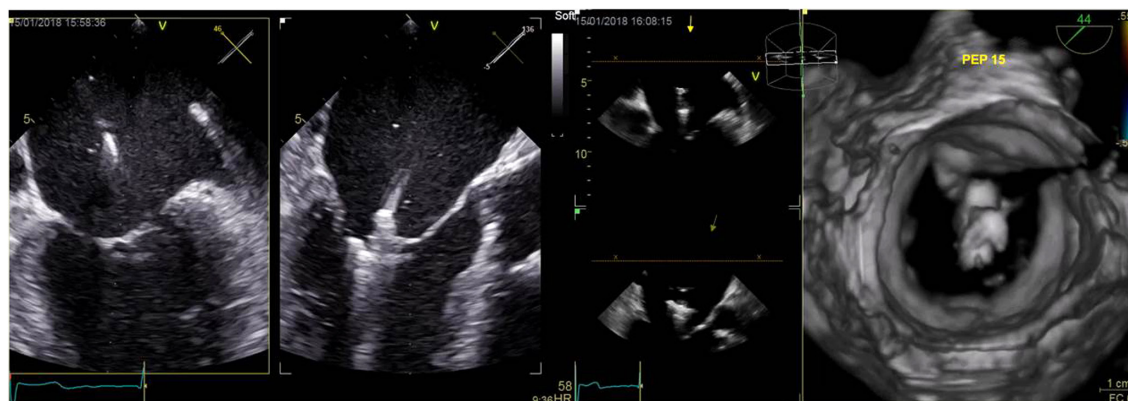

Figure 1

An example of a mitral valve grasping with a clip using 2D and 3D transoesophageal capabilities.

have transfemoral TAVI). Any patient that has small and heavily calcified femoral (or subclavian) vessels, and any patient who has heavy calcification extending from the valve into the LV outflow tract are too high a surgical risk: if these are the findings of imaging, the cardiac surgeon may wish to consider open heart surgery. In such a case, the imager clearly has a central role in liaising between interventionists, surgeons and directing appropriate patient management.

Secondary mitral regurgitation (SMR) management: interaction of imagers, surgeons and interventional cardiologists

It is impossible to go into the details of all the guidelines dedicated to VHD, and explain how they are applied in a heart team of 2019. Therefore, we take the example of the management of secondary mitral regurgitation (SMR). This item has been updated in the 2016 ESC guidelines (Table 1) (1, 9). In the management of SMR, we have to deal with opportunities related to:

- new surgical approaches (namely ‘minimally-invasive’ approaches)
- percutaneous mitral valve prosthesis (e.g., promising results with the TENDYNE valve)
- clips (Mitraclip® and Pascal®)
- percutaneous annuloplasty (Fig. 2)

Symptomatic patients with SMR are often very sick. They have a dilated left ventricle with reduced left ventricular ejection fraction. The presence of comorbidities can increase the severity of the symptomatic status and contribute to a poor prognosis.

The best management for SMR is an object of debate. Neither surgical annuloplasty nor mitral valve replacement demonstrated the beneficial effect that could have been expected (10). Surgical mitral valve replacement/repair

is an option when a coronary artery bypass is required. Nevertheless, it is rare to discuss an isolated conventional mitral valve replacement when a patient is symptomatic due to SMR, despite treatment optimized to include cardiac resynchronization therapy (1).

Therefore, percutaneous repair of SMR with the edge-to-edge technique seems to be a valuable strategy for the management of these patients. The EVEREST trial was convincing and provided clear rules for patient selection, which may also be adapted according to the expertise of a given laboratory (Table 2).

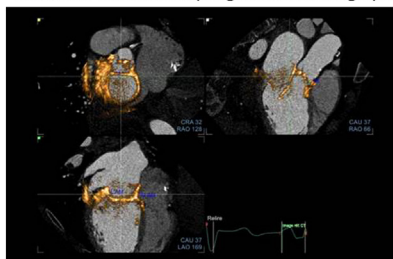
A meta-analysis of six retrospective studies with a propensity-matched analysis showed that patients treated by MitraClip® for SMR had a better prognosis in term of mortality and re-hospitalization (median follow-up of 400 days), compared to patients treated by optimal medical treatment alone (11, 12, 13, 14). The COAPT trial showed for the first time, the clear benefit of MitraClip® therapy in SMR, when used in addition to optimal medical therapy (OMT): the primary endpoint (all hospitalizations for heart failure within 24 months) was significantly reduced in the MitraClip group (HR 0.53; 95 CI 0.40–0.70; $P > 0.001$), with an impressive number needed to treat (NNT) of 3.1. The MitraClip group also showed a significant reduction in all-cause mortality (HR 0.62; 95 CI 0.46–0.82; $P < 0.001$), with a NNT of 5.9, as well as improvements in quality of life, NYHA functional class, and functional parameters. In contrast, the MITRA-FR trial failed to show any 12-month clinical benefit of an additional MitraClip® therapy on the top of OMT, in 304 patients with severe symptomatic SMR (15).

The different results between the COAPT and the MITRA-Fr trial can be explained by the considerable differences between the populations included in each study. The COAPT population clearly had more patients with severe MR (mean effective regurgitant orifice area (EROA) 41 ± 15 mm²), with mild left ventricular end-diastolic volume (LVEDV; 101 ± 34 mL/m²). In the

Table 1 Indications for mitral valve intervention in chronic secondary mitral regurgitation (1).

Recommendation	Recommendation category
Surgery is indicated in patients with severe secondary mitral regurgitation, undergoing a surgical revascularization and having a left ventricular ejection fraction $\geq 30\%$	High
When revascularization is not indicated, surgery may be considered in symptomatic patients with severe secondary mitral regurgitation, left ventricular ejection fraction $\geq 30\%$ and when symptoms persist despite optimal medical management. Surgical risk must be low	Low level of recommendation (outcomes identical to ‘clip’ approaches evaluated in randomized studies published in 2018)
When revascularization is not indicated, clip may be considered in symptomatic patients with severe secondary mitral regurgitation, left ventricular ejection fraction $\geq 30\%$ and when symptoms persist despite optimal medical management. Surgical risk must be low	Low level of recommendation

Pre-implantation images done by fusion between cardiac CT and transesophageal echocardiography



Opening of the Tendyne prosthesis monitored by transesophageal echocardiography

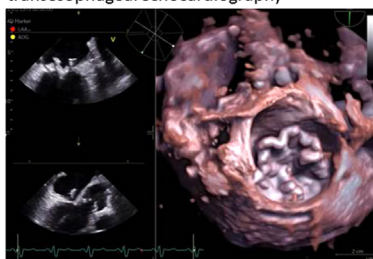
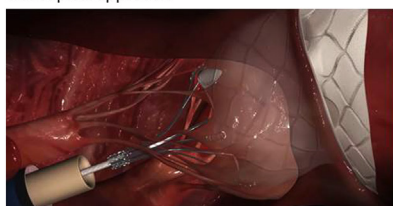


Illustration of the positioning the prosthesis using a transapical approach



Post-implantation, immediate images using the fusion between the actual transesophageal echocardiography and the pre-operative cardiac CT

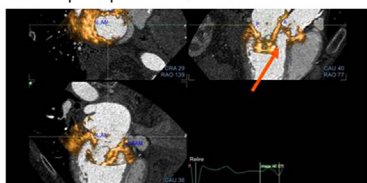


Figure 2
An example of the TENDYNE trans-apical prosthesis.

MITRA-FR trial, the degree of MR was weaker (EROA $31 \pm 10 \text{ mm}^2$), but with a more pronounced LV dilatation (LVEDV $135 \pm 35 \text{ mL/m}^2$) and dysfunction (16). These findings indicate that in patients with SMR, the presence of advanced heart disease supersedes the presence of SMR in dictating prognosis (Figs 3 and 4). This concept essentially reiterates the lessons learnt from surgical SMR series. Accordingly, patients with an excessively enlarged and sick LV should be promptly evaluated for advanced heart failure therapies such as implantation of an LVAD (left ventricular assist device) and/or heart transplantation before their clinical profile deteriorates too much. Therefore, treating SMR with the MitraClip® approach improves the prognosis and functional status of heart failure patients who remain symptomatic despite an OMT. An impact on prognosis is very likely when the MR remains with a regurgitant volume $\geq 60 \text{ mL}$ and a not excessively enlarged LV.

Because of the complexity of the matter, the weekly heart team meeting is the perfect occasion to provide a comprehensive presentation of clinical cases of patients

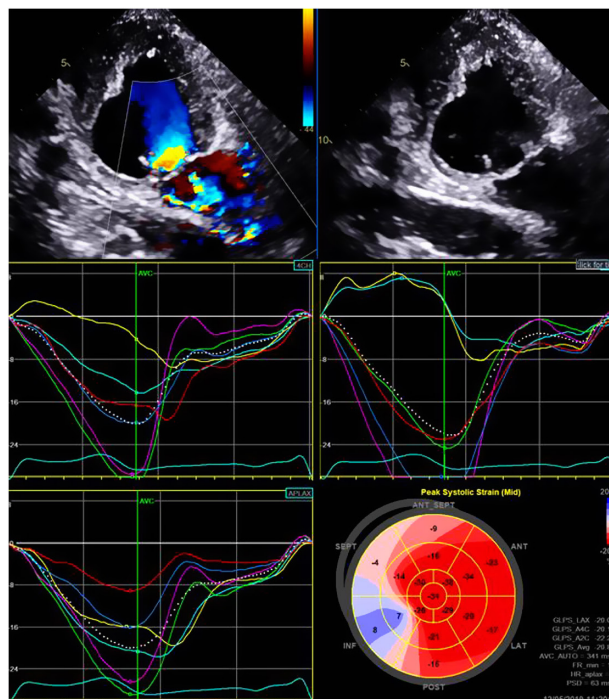
with SMR (17). During this meeting, patients' symptoms and comorbidities should be highlighted. The 'image-gallery' should present a mix of transoesophageal and transoesophageal echocardiography, cardiac CT, coronary angiography, occasionally cardiac-MR and exercise stress testing, and the best therapeutic options in each case should be discussed. In addition to clinical status and an accurate left heart assessment, we always establish that patients do not have severe pulmonary hypertension and/or significant right heart dysfunction prior to the meeting.

Tricuspid regurgitation

The importance of tricuspid regurgitation (TR) has frequently been overlooked in the past, particularly when associated with left-sided VHD. Nevertheless, current recommendations suggest the correction of TR when the tricuspid annulus diastolic diameter is $\geq 21 \text{ mm/m}^2$ and the patient is undergoing surgery for other heart valve disease. Recently, long-term outcomes after mitral valve

Table 2 From EVEREST to now: selection criteria.

Optimal	Possible	Inappropriate or marginal
Pathology in segment 2 No calcification	Pathology in segment 1 or 3 Ring calcification or calcifications separate from the grasping zone	Leaflet perforation or cleft Mitral stenosis (mean pressure gradient $>5 \text{ mmHg}$) and diastolic surface area $<4 \text{ cm}^2$
Length of the posterior leaflet $>10 \text{ mm}$	Length of the posterior leaflet $7-10 \text{ mm}$	Length of the posterior leaflet $<7 \text{ mm}$
Normal thickness and mobility of the leaflets	Carpentier IIIB with an over enlarged and sick left ventricle (LVEF $<20\%$)	Rheumatic thickening and systole-diastolic restriction (Carpentier IIIA)
Prolapse with a flail size $<15 \text{ mm}$	Flail size $>15 \text{ mm}$ if the diastolic surface of the orifice $>5 \text{ cm}^2$	Caution advised, extreme caution in Barlow disease

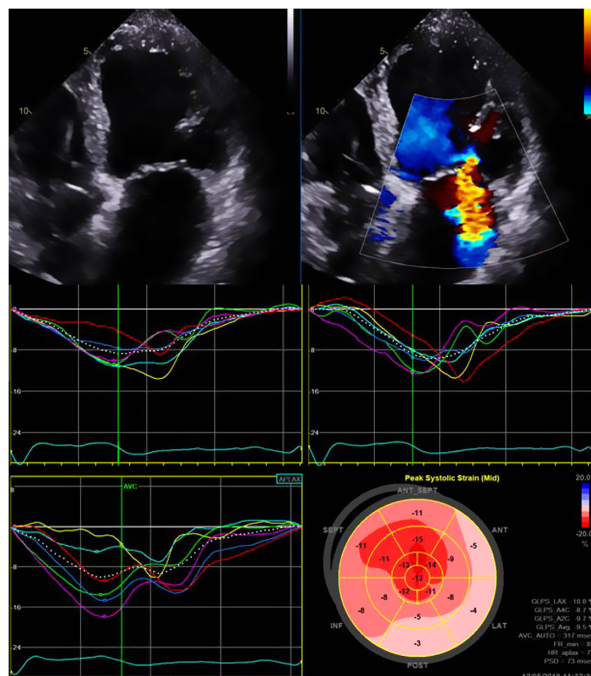


**Disproportionate mitral regurgitation is a
ischemic cardiomyopathy (inferior
myocardial infarction)**

- Left ventricular end-diastolic diameter = 52mm
 - Left ventricular end-diastolic volume = 228 ml
- Central mitral regurgitation analyzed in an euvolemic patient with a blood pressure = 120/80 mmHg:*
- Left ventricular ejection fraction = 43%
 - Regurgitant orifice area 45mm²
 - Regurgitant volume 67ml
 - Regurgitant fraction 72%

Figure 3

An example of a patient with a proportional secondary mitral regurgitation, where the LV is enlarged and regurgitation is proportional to that dilatation.



**Proportionate secondary mitral
regurgitation**

Non-ischemic cardiomyopathy:

- Left ventricular end-diastolic diameter= 65mm
 - Left ventricular end-diastolic volume=336ml
- Central secondary mitral regurgitation analyzed in a euvolemic status and a blood pressure = 120/80 mmHg:*
- Left ventricular ejection fraction=30 %
 - Effective regurgitant orifice area 34 mm²
 - Regurgitant Volume 60 ml
 - Regurgitant fraction 55 %

Figure 4

An example of a patient without any severe LV enlargement, but with a severe secondary mitral regurgitation.

repair have been reported (18). Surprisingly, the incidence of late moderate-severe TR was >20%, a finding which the surgeons were unable to explain but which suggests that even well-repaired mitral valves can be associated with long-term right heart dysfunction. Thus, the importance of assessing right heart size and TR severity in patients undergoing mitral valve surgery is emphasized. Percutaneous approaches for treating TR are also becoming available, providing new challenges and opportunities for cardiac imagers in selecting patients most suitable for taking advantage of these treatments (19).

In the context of the rediscovered importance of TR, a recent publication from Hahn *et al.* emphasized the importance of a multimodal imaging approach in the assessment of TR severity, and proposed a new classification of TR. This classification (which has not yet been validated) extends the severity scale of TR from 'severe' to 'massive' and 'torrential' (20). This scale might be useful in assessing the efficacy of new transcatheter devices for the percutaneous treatment of TR, and to illustrate the importance of the collaboration between imagers and interventional cardiologists in the field of VHD management.

Endocarditis

This importance of echocardiography and of other imaging modalities has been confirmed in recent European guidelines, where the concept of a multi-disciplinary endocarditis team has been highlighted (21). Echocardiography remains essential in the decision-making process and in diagnosis, but nuclear imaging and cardiac CT are both increasingly important imaging techniques (22, 23), which require appropriate interpretation in cases of diagnosed or suspected endocarditis.

Promoting the imager for conducting new randomized studies that will influence future guidelines

In the previous section, we discussed the role of cardiac imaging in the assessment and management of patients with SMR, but this example can be extended to all other VHDs.

Moreover, cardiac imagers have a pivotal role in all the studies involving patients with VHD and which require heart team participation. Many of these trials involve the assessment of new devices and new therapeutic strategies (15, 16), which requires a comprehensive knowledge of

the valvular apparatus, heart function and, frequently, the interpretation of several different imaging modalities. Therefore, the imager should probably be the one to have seen the patient, to have made the clinical evaluation and the images that will form the basis of the proposal made to the heart team and to the patient about any potential inclusion in a study. In addition, for many studies about devices, the images have to be assessed by a centralized corelab; this stage is essential before including any patient in a study. The acceptance rate in percutaneous prosthesis studies is lower than 80%.

Conclusion

The 2016 ESC guidelines on VHD have clearly emphasized the importance of the heart team in the management of patients with VHD, particularly in complex cases.

The increasing number of percutaneous procedures and the ongoing randomized trials on VHD has strengthened the role of imagers in the assessment and management of patients with VHD (1, 17).

Continuous interaction between different disciplines, including the surgeon, the interventional cardiologist, anesthesiologists and heart failure experts, is essential in order to provide the best standard of care for patients with VHD.

Declaration of interest

The authors declare that there is no conflict of interest that could be perceived as prejudicing the impartiality of this review.

Funding

This review did not receive any specific grant from any funding agency in the public, commercial or not-for-profit sector.

References

- 1 Baumgartner H, Falk V, Bax JJ, De Bonis M, Hamm C, Holm PJ, Iung B, Lancellotti P, Lansac E, Rodriguez Muñoz D, *et al.* 2017 ESC/EACTS Guidelines for the management of valvular heart disease. *European Heart Journal* 2017 **38** 2739–2791. (<https://doi.org/10.1093/eurheartj/ehx391>)
- 2 Chambers JB, Prendergast B, Iung B, Rosenhek R, Zamorano JL, Pierard LA, Modine T, Falk V, Kappetein AP, Pibarot P, *et al.* Standards defining a 'Heart Valve Centre': ESC Working Group on valvular heart disease and European Association for cardiothoracic surgery viewpoint. *European Journal of Cardio-Thoracic Surgery* 2017 **52** 418–424. (<https://doi.org/10.1093/ejcts/ezx283>)
- 3 Bhattacharyya S, Pavitt C, Lloyd G, Chambers JB & British Heart Valve Society. Prevalence and composition of heart valve

- multi-disciplinary teams within a national health system. *International Journal of Cardiology* 2014 **177** 1120–1121. (<https://doi.org/10.1016/j.ijcard.2014.08.070>)
- 4 Steiner JM, Cooper S & Kirkpatrick JN. Palliative care in end-stage valvular heart disease. *Heart* 2017 **103** 1233–1237. (<https://doi.org/10.1136/heartjnl-2016-310538>)
 - 5 Castano A, Narotsky DL, Hamid N, Khalique OK, Morgenstern R, DeLuca A, Rubin J, Chiuzan C, Nazif T, Vahl T, *et al.* Unveiling transthyretin cardiac amyloidosis and its predictors among elderly patients with severe aortic stenosis undergoing transcatheter aortic valve replacement. *European Heart Journal* 2017 **38** 2879–2887. (<https://doi.org/10.1093/eurheartj/ehx350>)
 - 6 Vollema EM, Amanullah MR, Ng ACT, van der Bijl P, Prevedello F, Sin YK, Prihadi EA, Marsan NA, Ding ZP, Génèreux P, *et al.* Staging cardiac damage in patients with symptomatic aortic valve stenosis. *Journal of the American College of Cardiology* 2019 **74** 538–549. (<https://doi.org/10.1016/j.jacc.2019.05.048>)
 - 7 Pibarot P, Sengupta P & Chandrashekhar Y. Imaging is the cornerstone of the management of aortic valve stenosis. *JACC: Cardiovascular Imaging* 2019 **12** 220–223. (<https://doi.org/10.1016/j.jcmg.2018.12.001>)
 - 8 Pawade T, Sheth T, Guzzetti E, Dweck MR & Clavel MA. Why and how to measure aortic valve calcification in patients with aortic stenosis. *JACC: Cardiovascular Imaging* 2019 **12** 1835–1848. (<https://doi.org/10.1016/j.jcmg.2019.01.045>)
 - 9 Jain P & Fabbro 2nd M. ACC Expert Consensus Decision pathway on the management of mitral regurgitation: a review of the 2017 document for the cardiac anesthesiologist. *Journal of Cardiothoracic and Vascular Anesthesia* 2019 **33** 274–289. (<https://doi.org/10.1053/j.jvca.2018.07.029>)
 - 10 Pibarot P, Delgado V & Bax JJ. MITRA FR vs. COAPT: lessons from two trials with diametrically opposed results. *European Heart Journal: Cardiovascular Imaging* 2019 **20** 620–624. (<https://doi.org/10.1093/ehjci/jez073>)
 - 11 Bertaina M, Galluzzo A, D'Ascenzo F, Conrotto F, Grosso Marra W, Frea S, Alunni G, Crimi G, Moretti C, Montefusco A, *et al.* Prognostic impact of MitraClip in patients with left ventricular dysfunction and functional mitral valve regurgitation: a comprehensive meta-analysis of RCTs and adjusted observational studies. *International Journal of Cardiology* 2019 **290** 70–76. (<https://doi.org/10.1016/j.ijcard.2019.05.015>)
 - 12 De Rosa R, Silverio A, Baldi C, Di Maio M, Prota C, Radano I, Rey J, Herrmann E, Citro R, Piscione F, *et al.* Transcatheter repair of functional mitral regurgitation in heart failure patients – a meta-analysis of 23 studies on MitraClip implantation. *Circulation Journal* 2018 **82** 2800–2810. (<https://doi.org/10.1253/circj.CJ-18-0571>)
 - 13 Giannini C, D'Ascenzo F, Fiorelli F, Spontoni P, Swaans MJ, Velazquez EJ, Armeni P, Adamo M, De Carlo M & Petronio AS. A meta-analysis of MitraClip combined with medical therapy vs. medical therapy alone for treatment of mitral regurgitation in heart failure patients. *ESC Heart Failure* 2018 **5** 1150–1158. (<https://doi.org/10.1002/ehf2.12339>)
 - 14 D'Ascenzo F, Moretti C, Marra WG, Montefusco A, Omede P, Taha S, Castagno D, Gaemperli O, Taramasso M, Frea S, *et al.* Meta-analysis of the usefulness of MitraClip in patients with functional mitral regurgitation. *American Journal of Cardiology* 2015 **116** 325–331. (<https://doi.org/10.1016/j.amjcard.2015.04.025>)
 - 15 Obadia JF, Messika-Zeitoun D, Leurent G, Iung B, Bonnet G, Piriou N, Lefèvre T, Piot C, Rouleau F, Carrié D, *et al.* Percutaneous repair or medical treatment for secondary mitral regurgitation. *New England Journal of Medicine* 2018 **379** 2297–2306. (<https://doi.org/10.1056/NEJMoa1805374>)
 - 16 Stone GW, Lindenfeld J, Abraham WT, Kar S, Lim DS, Mishell JM, Whisenant B, Grayburn PA, Rinaldi M, Kapadia SR, *et al.* Transcatheter mitral-valve repair in patients with heart failure. *New England Journal of Medicine* 2018 **379** 2307–2318. (<https://doi.org/10.1056/NEJMoa1806640>)
 - 17 Chambers JB, Prendergast B, Iung B, Rosenhek R, Zamorano JL, Pierard LA, Modine T, Falk V, Kappetein AP, Pibarot P, *et al.* Standards defining a 'Heart Valve Centre': ESC Working Group on valvular heart disease and European Association for cardiothoracic surgery viewpoint. *European Heart Journal* 2017 **38** 2177–2183. (<https://doi.org/10.1093/eurheartj/ehx370>)
 - 18 David TE, David CM, Tsang W, Lafreniere-Roula M & Manlhiot C. Long-term results of mitral valve repair for regurgitation due to leaflet prolapse. *Journal of the American College of Cardiology* 2019 **74** 1044–1053. (<https://doi.org/10.1016/j.jacc.2019.06.052>)
 - 19 Gafoor S & Wang DD. Does the idea of percutaneous tricuspid valve replacement need repair? *JACC: Cardiovascular Imaging* 2019 **12** 430–432. (<https://doi.org/10.1016/j.jcmg.2018.09.013>)
 - 20 Hahn RT & Zamorano JL. The need for a new tricuspid regurgitation grading scheme. *European Heart Journal Cardiovascular Imaging* 2017 **18** 1342–1343. (<https://doi.org/10.1093/ehjci/jex139>)
 - 21 Habib G, Lancellotti P, Antunes MJ, Bongiorni MG, Casalta JP, Del Zotti F, Dulgheru R, El Khoury G, Erba PA, Iung B, *et al.* 2015 ESC Guidelines for the management of infective endocarditis: the task force for the management of infective endocarditis of the European Society of Cardiology (ESC). Endorsed by: European Association for Cardio-Thoracic Surgery (EACTS), the European Association of Nuclear Medicine (EANM). *European Heart Journal* 2015 **36** 3075–3128. (<https://doi.org/10.1093/eurheartj/ehv319>)
 - 22 San S, Ravis E, Tessonier L, Philip M, Cammilleri S, Lavagna F, Norscini G, Arregle F, Martel H, Oliver L, *et al.* Prognostic value of (18)F-fluorodeoxyglucose positron emission tomography/computed tomography in infective endocarditis. *Journal of the American College of Cardiology* 2019 **74** 1031–1040. (<https://doi.org/10.1016/j.jacc.2019.06.050>)
 - 23 Cahill TJ, Baddour LM, Habib G, Hoen B, Salaun E, Pettersson GB, Schäfers HJ & Prendergast BD. Challenges in infective endocarditis. *Journal of the American College of Cardiology* 2017 **69** 325–344. (<https://doi.org/10.1016/j.jacc.2016.10.066>)

Received in final form 29 September 2019

Accepted 22 October 2019

Accepted Manuscript published online 23 October 2019