

Study of the Correlation Between Severity of Endophthalmitis and Posterior Vitreous Detachment Using a Rabbit Endophthalmitis Model

Ryo Baba,¹ Kazuhiko Umazume,¹ Naohito Koike,² and Hiroshi Goto¹

¹Department of Ophthalmology, Tokyo Medical University, Tokyo, Japan

²Department of Microbiology, Tokyo Medical University, Tokyo, Japan

Correspondence: Kazuhiko Umazume, Department of Ophthalmology, Tokyo Medical University Hospital, 6-7-1 Nishi-Shinjuku, Shinjuku-ku, Tokyo 160-0023, Japan; kazuhiko-uma@kvf.biglobe.ne.jp.

Received: August 20, 2021

Accepted: January 10, 2022

Published: February 2, 2022

Citation: Baba R, Umazume K, Koike N, Goto H. Study of the correlation between severity of endophthalmitis and posterior vitreous detachment using a rabbit endophthalmitis model. *Invest Ophthalmol Vis Sci.* 2022;63(2):6. <https://doi.org/10.1167/iovs.63.2.6>

PURPOSE. We have reported that the absence of posterior vitreous detachment (PVD) is related to the onset and severity of infectious endophthalmitis, based on clinical experience. To demonstrate clinical findings in animal models, we created endophthalmitis models for the presence or absence of PVD and examined differences in severity.

METHOD. We estimated a rabbit infectious eye model with and without PVD using *Pseudomonas aeruginosa* (PVD(+)) and PVD(-) groups. After injection of bacteria inoculation for 3, 6, 12, and 24 hours, we evaluated the clinical score of the anterior chamber ($n = 14$). Removing the vitreous and retina from the enucleated eyeballs, the number of bacteria was counted using each specimen ($n = 12$). In addition, the number of inflammatory cells approximately 3 mm² around the optic disc and histopathologic grading of intraocular inflammation was compared from histopathologic images ($n = 7$). Electroretinogram (ERG) was performed in experimentally infected rabbit eyes in both groups at three times after injection of the bacterial suspension.

RESULTS. There was no difference between the two groups in the clinical score of the anterior chamber of each time phase, but the bacterial cultures showed significantly fewer bacteria in the PVD(-) group 24 hours after bacterial inoculation ($P < 0.05$). Furthermore, the number of inflammatory cells was significantly less in the PVD group ($P < 0.05$). As a result of ERG, the decreases of a- and b-waves in amplitude were significantly greater in the PVD(-) group than in the PVD(+) group.

CONCLUSIONS. The present study confirms using animal models that the absence of PVD contributed to the severity of bacterial endophthalmitis.

Keywords: bacterial endophthalmitis, posterior vitreous detachment

In intraocular surgeries, postoperative bacterial endophthalmitis occurs at a certain rate. However, even with the recent advances in vitreous surgery, postoperative bacterial endophthalmitis remains a disease with poor visual prognosis. Except for toxicity of the causative bacteria, the factors that aggravate postoperative bacterial endophthalmitis are still unknown. Moreover, the risk factors for aggravation in the early stage of endophthalmitis remain unclear. The most common causative microorganism of endophthalmitis after cataract surgery is coagulase-negative *Streptococcus*,^{1,2} followed by Gram-positive cocci. The main causative bacteria of bleb-related endophthalmitis (BRE) after glaucoma surgery are *Streptococcus* species (37%) and *Haemophilus influenzae* (8.9%). According to the classification of BRE by severity, stage I is defined as infection confining to the filtration bleb, stage II as infection mainly confined to inside the anterior chamber and not extending to the vitreous body, stage IIIa as infection involving the vitreous body but mild, and stage IIIb as infection involving the vitreous body and serious. In Japan, the incidence of BRE in one survey was reported to be 1.5% at 2.5-year follow-up after

mitomycin C-augmented trabeculectomy, and a subsequent survey reported an incidence of 2.6% at 5-year follow-up.³⁻⁵ In endogenous endophthalmitis caused by metastatic spread of bacteria or fungi from other organs, apart from *Staphylococcus aureus* and *Streptococcus* species, Gram-negative bacteria such as *Klebsiella* species and fungi were also reported as causative microorganisms.⁶⁻⁸

We reported the absence of posterior vitreous detachment (PVD) despite old age in 70% of patients with endogenous endophthalmitis (7 of 10 patients) and 80% of those with BRE (8 of 10 patients).^{9,10} In addition, retinal necrosis occurred in many patients with endogenous endophthalmitis and those with BRE who did not have PVD. In one patient with BRE who required enucleation, histopathologic examination confirmed the absence of PVD. According to a previous report, PVD generally occurs between the ages of 54 and 57 years,¹¹ and the possibility that PVD may be associated with the onset and severity of endophthalmitis has been suggested. A study in rabbits has shown more vigorous bacterial growth in the vitreous than in the anterior chamber.¹²

On the basis of the clinical observations and the findings to date, we hypothesized that continuity of the infection focus, the vitreous body, and the retina facilitates infection in the eye and accelerates aggravation of the disease. Therefore, this research aimed to elucidate the relationship between the presence or absence of PVD and aggravation of endophthalmitis by verifying in vivo that the presence of gel vitreous is a factor associated with the development of endophthalmitis and aggravation of the pathologic state. As the first step, an animal model of endophthalmitis using rabbits was established, and the effect of the presence or absence of PVD on the severity of endophthalmitis was investigated.

METHODS

Animals and Anesthesia

This study was conducted in compliance with the ARVO Statement for the Use of Animals in Ophthalmic and Vision Research and was approved by the Institutional Animal Care and Use Committee of Tokyo Medical University.

The right eyes of female New Zealand White rabbits aged 12 weeks and weighing 2.0 to 2.5 kg were used in the study. The anesthetics used were medetomidine hydrochloride (hereinafter medetomidine; Dolbene; Kyoritsu Seiyaku Corp., Tokyo, Japan), which is an adrenaline α 2 receptor agonist; midazolam (hereinafter midazolam; Dormicum injection 10 mg; Astellas Pharma, Tokyo, Japan), which is a benzodiazepine sedative; and butorphanol tartrate (hereinafter butorphanol; Bettlefar; Meiji Seika Pharma Co. Ltd., Tokyo, Japan), which is an opioid κ receptor agonist. For general anesthesia, a mixture of medetomidine 0.15 mg/kg, midazolam 1.0 mg/kg, and butorphanol 1.5 mg/kg was injected intravenously.¹³ For local anesthesia, oxybuprocaine ophthalmic solution 0.4% (hereinafter oxybuprocaine; Benoxil; Santen Pharmaceutical Co. Ltd., Osaka, Japan) was used. In addition, tropicamide phenylephrine hydrochloride ophthalmic solution (Mydrin P; Santen Pharmaceutical Co. Ltd.) was used as a mydriatic agent. Euthanasia of rabbits was performed by intravenous administration of large doses of pentobarbital.

Bacterial Species and Culture Method

The bacterial strain used was *Pseudomonas aeruginosa* strain PAO-1.^{14,15} Culture was performed in NAC medium (Eiken Chemical Co. Ltd., Tokyo, Japan), which is a selective medium for *P. aeruginosa*, at 37°C for 24 hours, and adjusted to 1.0×10^8 CFU/mL.

Creation of the PVD Model

The PVD model was created according to a previous report of a rabbit proliferative vitreoretinopathy (PVR) model.¹⁶ After performing an anterior chamber paracentesis with a 27-gauge needle to lower the intraocular pressure sufficiently, 0.4 mL sulfur hexafluoride (SF₆ gas) was injected with a 30-gauge needle via a site 6 mm from the corneal limbus. Seven days after injection, the rabbit was euthanized and the presence or absence of PVD was confirmed by histopathologic examination. A preliminary experiment was performed on five rabbits, which confirmed that PVD was induced in all five rabbits.

Creation of the Endophthalmitis Model

The endophthalmitis model without induced PVD was created according to a previous report.¹⁷ After performing an anterior chamber paracentesis with a 27-gauge needle to reduce the intraocular pressure sufficiently, 100 μ L *P. aeruginosa* suspension was injected with a 30-gauge needle via a site 6 mm from the corneal limbus. For inoculation, a bacterial suspension adjusted to a density of 1.0×10^8 CFU/mL was diluted to 1.0×10^5 CFU/mL. Fourteen rabbits were used in this group (PVD(-) group).

The endophthalmitis model with induced PVD was created by injecting the bacterial suspension into the eyes using the same methods as described above. Fourteen rabbits were used in this group (PVD(+) group).

After intraocular inoculation of the bacterial suspension, the eyes were observed at 3, 6, 12, 24, and 48 hours after inoculation, and then the rabbits were euthanized. The eyeballs were enucleated for pathologic examination to evaluate the state of infection.

Anterior Segment Grading

At 3, 6, 12, and 24 hours after injection of the bacterial suspension, the anterior segment of all rabbits in both groups was evaluated. According to previous reports,^{18,19} the three items evaluated were conjunctival hyperemia, conjunctival edema, and anterior chamber hypopyon, with scores of 1 point, 1 point, and 3 points, respectively. Fourteen rabbits were used in both groups.

Bacterial Colony Count in Retinal Tissue

The numbers of bacterial colonies on the cultures of retinal tissue from all the rabbits in both groups were enumerated at 3, 6, 12, and 24 hours after injection of the bacterial suspension. Twelve rabbits were used in both groups.

At each time point, the eyeball was enucleated and disinfected with iodine in polyvinyl alcohol and saline. Next, the retina was removed from the ora serrata of the enucleated eyeball and mixed with saline to a total volume of 1 mL. After serial dilution by physiologic saline, the sample was spread on NAC medium and cultured at 37°C for 24 hours. Thereafter, colonies that formed on the medium were counted.

Number of Inflammatory Cells Around the Optic Disc and Histopathologic Grading of Intraocular Inflammation

Experimentally infected rabbits in both PVD(+) and PVD(-) groups were euthanized at 3, 6, 12, and 24 hours after injection of the bacterial suspension. After the eyeballs were enucleated, histopathologic sections were prepared for hematoxylin and eosin (HE) staining. The number of inflammatory cells within an area of 3 mm² (3 mm in width \times 1 mm in length) around the optic disc was counted (Fig. 1; \times 40). The experimenter (KU) did the mixing and then counted the number of bacteria. In addition, grading was performed as shown in the Table. Seven rabbits were used in both groups.

Electroretinographic Evaluation

Electroretinogram (ERG) was performed in experimentally infected rabbit eyes in both PVD(+) and PVD(-) groups

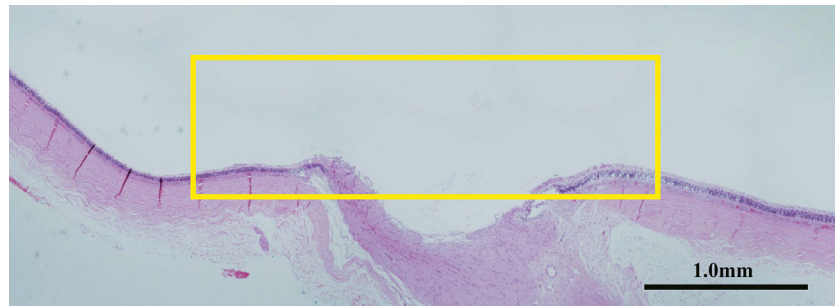


FIGURE 1. The area inside the *yellow frame* is shown the area we counted inflammatory cells within an area of 3 mm² (3 mm in width × 1 mm in length) around the optic disc.

TABLE. Histopathologic Grading of Retina and Vitreous Body

Grade	Description
Grade 0	Normal retina, vitreous
Grade 1	With cell infiltration into the vitreous
Grade 2	Cell infiltration into the retina without tissue destruction
Grade 3	Retinal tissue destruction extending to the inner nuclear layer
Grade 4	Tissue destruction across all layers of the retina

at 3, 6, 12, and 24 hours after injection of the bacterial suspension. After inducing general anesthesia, the eye was instilled with oxybuprocaine and Mydrin P ophthalmic solutions, reference needle electrodes were placed at the forehead and base of the ear, and LED electrodes (H2000; Kyoto Contact Lens, Ltd., Kyoto, Japan) were placed on the cornea after a corneal protective agent was applied (Scopisol; Senju Pharmaceutical Co. Ltd., Osaka, Japan). A flash ERG test and a cone flicker test were performed using a portable ERG (LE-1000; Tomey Corporation, Aichi, Japan). The measurement conditions were set according to the protocol determined

by the International Society for Clinical Electrophysiology of Vision (ISCEV).²⁰ Seven rabbits were used in both groups.

Statistical Analysis

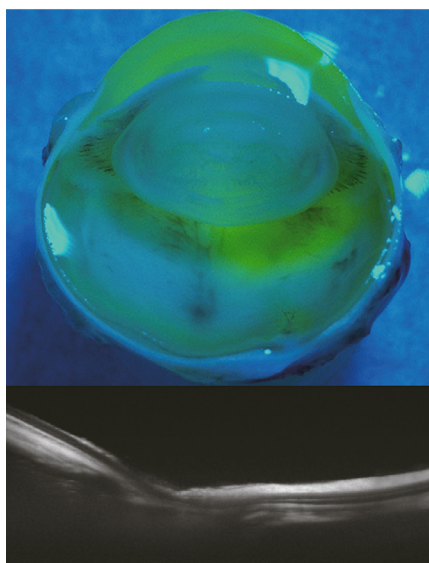
The differences between PVD(+) and PVD(-) were compared by Mann-Whitney U test. Statistical analyses were performed using MedCalc version 12.1.1 (MedCalc Software, Mariakerke, Belgium). A P value of <0.05 was considered statistically significant.

RESULTS

Creation of the PVD Model

Histopathologic examination of the enucleated eyeballs confirmed that PVD was induced. In addition, the examination also confirmed that the vitreous body was compressed and displaced forward as a result of SF₆ gas injection. The demonstration of PVD was shown by stereomicrographs using the Kishi method²¹ and imaging findings using swept-source optical coherence tomography (SS-OCT) (Fig. 2).

PVD induction (+)



PVD induction (-)

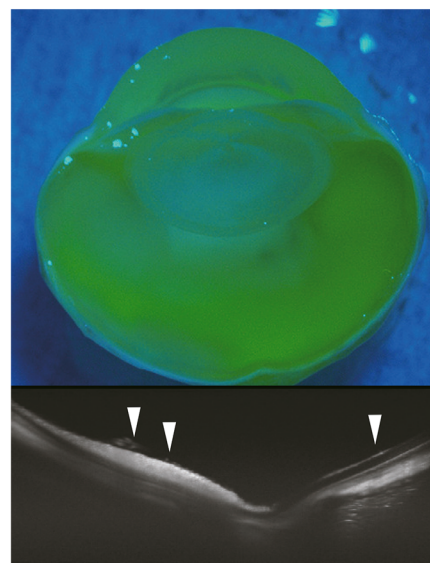


FIGURE 2. In the PVD(+) group, the vitreous stained with fluorescein was found only in the posterior part of the lens, whereas in the PVD(-) group, the vitreous was stained throughout. Furthermore, OCT shows that there is the vitreous on the retina in the area indicated by the *arrowhead* in the PVD(-) group.

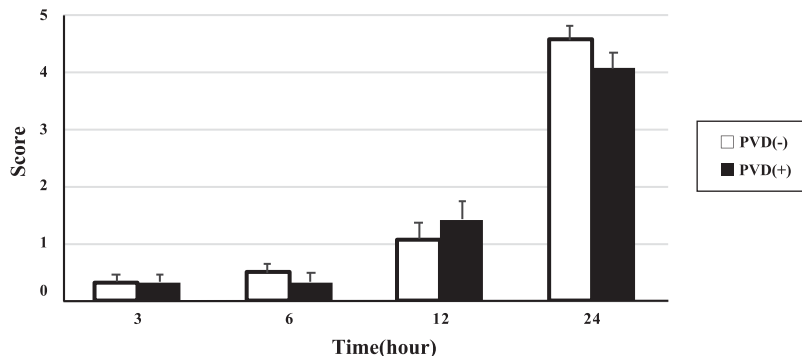


FIGURE 3. Grading of ocular anterior segment. At 3, 6, 12, and 24 hours after injection of the bacterial suspension, the anterior segment of all rabbits in both groups was evaluated. There were no differences in anterior segment score between the two groups at all time points.

Creation of the Endophthalmitis Model

No obvious signs of infection were observed at 3 hours and 6 hours after bacteria inoculation in both the PVD(-) and PVD(+) groups. After 12 hours, conjunctival hyperemia and discharge appeared gradually. At 24 hours, the eyes in both groups showed findings suggestive of endophthalmitis, including conjunctival edema and hypopyon in the anterior chamber. In many eyes, the fundus could not be visualized due to opacity of the anterior chamber. At 48 hours, the inflammatory findings became more severe, and the enucleated eyeballs showed necrosis of the retina, suggesting that intraocular infection was established.

Evaluation of the Anterior Segment

At 3 hours and 6 hours after bacteria inoculation, only conjunctival hyperemia was observed in both groups. From 12 hours, conjunctival edema and hypopyon in the anterior chamber were observed. At 24 hours, all the eyes showed conjunctival edema in addition to conjunctival edema or anterior chamber hypopyon. All these findings were present in 9 of 14 eyes in the PVD(-) group and 7 of 14 eyes in the PVD(+) group. There were no differences in anterior

segment score between the two groups at all the time points (Fig. 3).

Enumeration of CFU in Retina Tissue

Both the PVD(+) group and PVD(-) group were inoculated with 1.0×10^4 CFU of bacteria per eye at day 0. No increase in CPU was detected at 3 and 6 hours after inoculation. Thereafter, the number increased gradually over time, and the counts at 12 hours were $2.49 \times 10^6 \pm 4.03 \times 10^6$ CFU/mL in the PVD(-) group and $1.00 \times 10^6 \pm 9.62 \times 10^5$ CFU/mL in the PVD(+) group. At 24 hours, the counts increased to $1.55 \times 10^7 \pm 1.70 \times 10^7$ CFU/mL in the PVD(-) group and $3.80 \times 10^6 \pm 3.32 \times 10^6$ CFU/mL in the PVD(+) group. Although there was no significant difference between the two groups at 12 hours, the bacterial count was significantly higher in the PVD(-) group than in the PVD(+) group ($P = 0.03$) at 24 hours (Fig. 4).

Evaluation of Inflammation Around the Optic Disc

The involvement of inflammation was also evaluated using HE-stained histopathologic specimens prepared from the enucleated eyeballs. Almost no inflammatory cells were

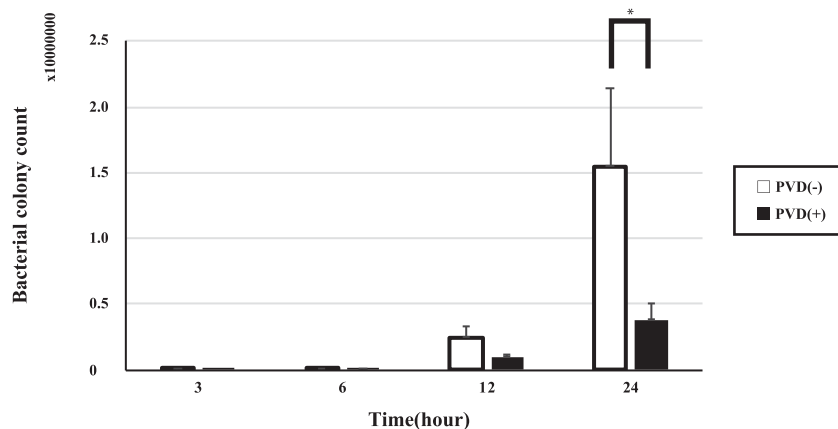


FIGURE 4. Enumeration of CFU in retinal tissue. The numbers of bacterial colonies on the cultures of retinal tissue from all the rabbits in both groups were enumerated at 3, 6, 12, and 24 hours after injection of the bacterial suspension. Although there was no significant difference between the two groups at 12 hours, the bacterial count was significantly higher in the PVD(-) group ($n = 12$) than in the PVD(+) group ($n = 12$) ($P = 0.03$) at 24 hours. *Statistically significant difference between PVD(-) group and PVD(+) group.

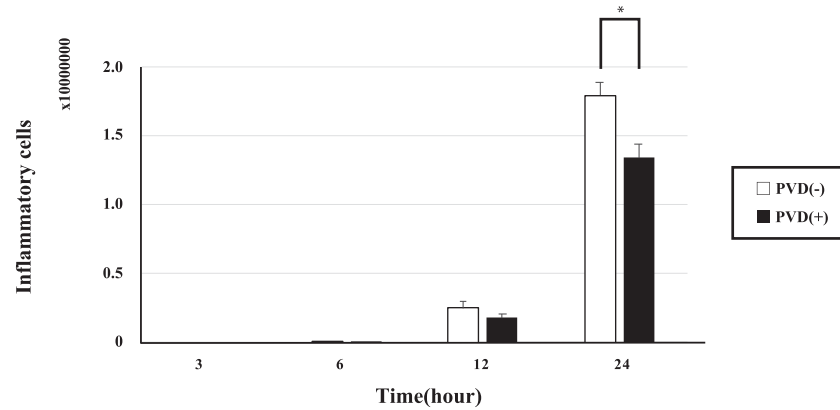


FIGURE 5. Number of inflammatory cells around the optic disc. Experimentally infected rabbits in both groups were euthanized at 3, 6, 12, and 24 hours after injection of the bacterial suspension. We counted inflammatory cells within an area of 3 mm² (3 mm in width × 1 mm in length) around the optic disc. While there was no significant difference between the two groups at 12 hours, the number of inflammatory cells was significantly higher in the PVD(–) group than in the PVD(+) group ($P < 0.01$) at 24 hours. *Statistically significant difference between PVD(–) group and PVD(+) group.

observed at 3 and 6 hours after bacteria inoculation. Thereafter, the numbers of cells increased to $2.48 \times 10^2 \pm 1.28 \times 10^2$ in the PVD(–) group and $1.77 \times 10^2 \pm 7.36 \times 10^1$ CFU/mL in the PVD(+) group at 12 hours, and further to $1.79 \times 10^3 \pm 2.58 \times 10^2$ CFU/mL in the PVD(–) group and $1.34 \times 10^3 \pm 2.56 \times 10^2$ CFU/mL in the PVD(+) group at 24 hours. While there was no significant difference between the two groups at 12 hours, the number of inflammatory cells was significantly higher in the PVD(–) group compared to the PVD(+) group ($P < 0.01$) at 24 hours (Fig. 5).

Histopathologic Grading of Retina and Vitreous Body

No abnormal findings were observed in the vitreous body and retina at 3 hours after bacteria inoculation. Inflammatory cell infiltration in the vitreous was detected in two eyes each in both groups at 6 hours. Thereafter, inflammatory cell filtration progressed gradually and was observed in the retina at 12 hours. At 24 hours, inflammation reached the deep layers of the retina. However, there were no differences

in histopathologic grade between the two groups at all the time points (Fig. 6).

Evaluation by Electroretinogram

Both groups were examined according to the ISCEV protocol. From 3 to 12 hours after bacteria inoculation, no decreases in both a-wave and b-wave amplitudes were observed. At 12 hours, the a-wave amplitudes were $90.4 \pm 18.7 \mu\text{V}$ in the PVD(–) group and $108.3 \pm 26.4 \mu\text{V}$ in the PVD(+) group, while the b-wave amplitudes were $133.3 \pm 31.9 \mu\text{V}$ in the PVD(–) group and $181.6 \pm 52.3 \mu\text{V}$ in the PVD(+) group. At 24 hours, however, the amplitudes of both a- and b-waves were markedly lower compared to those at 12 hours: a-wave amplitudes were $18.1 \pm 20.7 \mu\text{V}$ in the PVD(–) group and $54.4 \pm 35.8 \mu\text{V}$ in the PVD(+) group, and b-wave amplitudes were $17.2 \pm 10.8 \mu\text{V}$ in the PVD(–) group and $63.9 \pm 55.7 \mu\text{V}$ in the PVD(+) group. The decreases of a- and b-waves in amplitude were significantly greater in the PVD(–) group than in the PVD(+) group (a-wave, $P < 0.05$; b-wave, $P < 0.05$) (Figs. 7a, 7b).

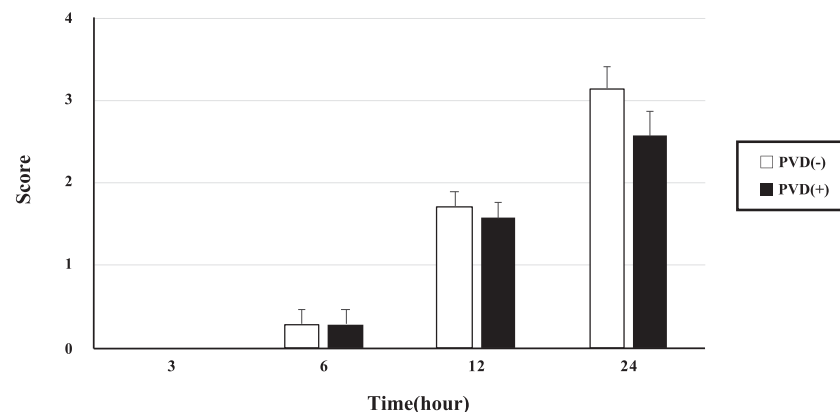


FIGURE 6. Histopathologic grading of retina and vitreous body. Experimentally infected rabbits in both groups were euthanized at 3, 6, 12, and 24 hours after injection of the bacterial suspension. We performed histopathologic grading. There were no differences in histopathologic grade between the two groups at all time points.

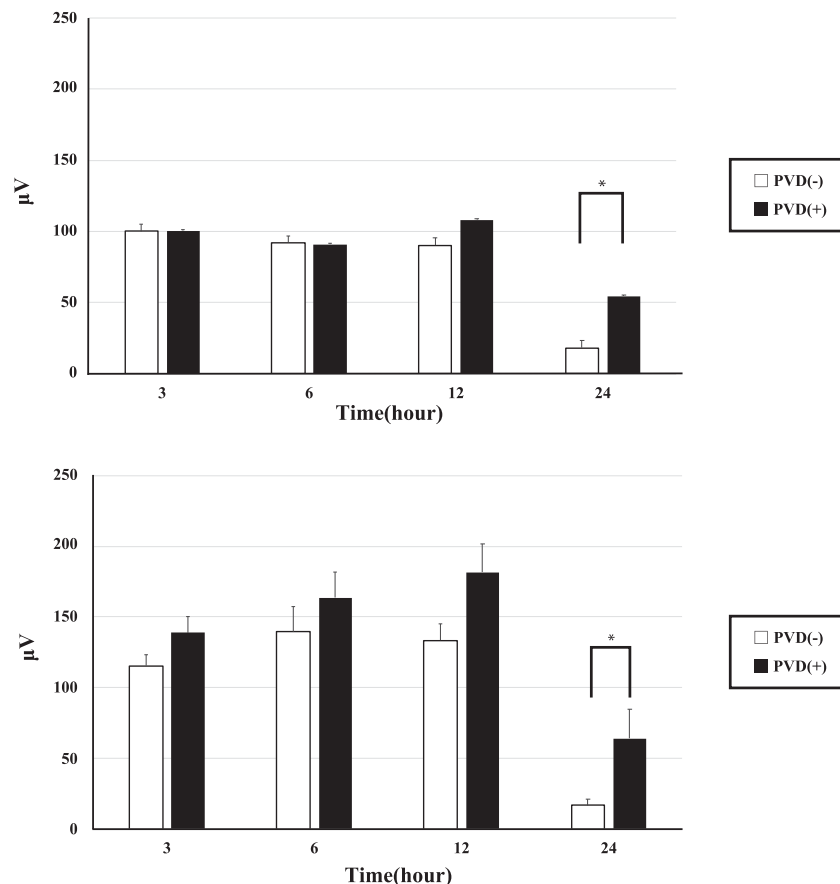


FIGURE 7. Electroretinogram. *Top:* a-wave. *Bottom:* b-wave. ERG examination was performed in experimentally infected rabbit eyes in both groups at 3, 6, 12, and 24 hours after injection of the bacterial suspension. For both a- and b-waves, the decreases in amplitude were significantly greater in the PVD(-) group than in the PVD(+) group (a-wave, $P < 0.05$; b-wave, $P < 0.05$). *Statistically significant difference between PVD(-) group and PVD(+) group.

DISCUSSION

In this study, animal models were created, which validated the findings related to endophthalmitis observed in clinical practice. In all the experiments, various outcome measures were evaluated at 3, 6, 12, and 24 hours after inoculation of the bacteria. No significant differences in the anterior segment grading and in the histopathologic grading of retinal and vitreous tissues were observed between the PVD(-) and PVD(+) groups at all the observation time points. In contrast, significant differences in the number of bacteria in the retina, the number of inflammatory cells in the retina and vitreous body, and electroretinographic results were observed between the two groups at 24 hours after bacteria inoculation, and all these outcome measures were more severe in the PVD(-) group. The result of the anterior segment grading in the animal model in this study may not contradict with the experience in clinical practice, because the clinical assessment of severity in the anterior segment often does not match the fundus findings in patients.

In the eyes without induced PVD, the retina is adhered to the vitreous body, and hence there is continuity between the infected site and the retina. In other words, the infection focus, the vitreous body, and the retina are connected. Under this condition, it is possible that infection of the retina

may be established earlier and aggravation of the pathologic condition may be accelerated. On the other hand, induction of PVD breaks the continuity between the retina and the vitreous body, resulting in the loss of continuity between the infection site and the retina, and as a result, it may take a longer time to complete the infection process in the retina. This probably gave rise to the significant differences in the number of bacteria in the retina, the number of inflammatory cells in the retina and vitreous body, and the electroretinographic result between PVD(-) and PVD(+) eyes.

While indirect experiments examining the involvement of bacteria produced significant results, our experiment demonstrated that despite the significantly larger number of inflammatory cells in the retina and vitreous in the PVD(-) group, there was no significant difference in the histopathologic grading of the retina and vitreous between the two groups. One possible explanation is that in both the PVD(-) and PVD(+) groups, few eyes showed a state of full-thickness retinal destruction, and in most cases, destruction did not extend beyond the inner nuclear layer. It is possible that a significant difference in histopathologic grading could be detected by using a more detailed scoring scale.

In the present study, in all evaluations that showed a significant difference between the PVD(-) and PVD(+) groups, there were no significant differences between the

two groups before 24 hours following bacteria inoculation. Destruction of retina was mild, and the bacterial load and number of inflammatory cells in the retina were low up to 12 hours after inoculation. On the other hand, the number of bacteria in the retina and the number of infiltrated inflammatory cells increased dramatically over the period from 12 to 24 hours, accompanied by progression of retinal tissue damage. These findings may suggest that intraocular infection is established after 12 hours following inoculation of the bacteria.

The above results suggest that endophthalmitis progresses more rapidly in the eyes without PVD. Postoperative endophthalmitis may cause serious visual impairment, and a multifaceted approach is required, which includes appropriate prevention, rapid diagnosis, and proper treatment.²² Currently, the mainstay of endophthalmitis management is identification of the causative organism, proper use of antibacterial agents, and vitrectomy.^{23,24} Based on the results of the current study, it may be possible to propose a guideline that if the presence or absence of PVD can be diagnosed before surgery by direct slit-lamp examination and/or ultrasonography, early vitrectomy is recommended for eyes without PVD.

In addition, the *P. aeruginosa* strain used in this experiment has one flagella at one end of the cell and moves actively. Even though infection was caused by a motile *P. aeruginosa* strain, intraocular inflammation and the degree of tissue destruction were mild in the PVD(+) endophthalmitis model animals. This finding may support the relationship between the presence or absence of PVD and the severity of postoperative endophthalmitis.

One of the limitations of the present study was that only *P. aeruginosa* was used that aimed to examine the aggravating factors of postoperative endophthalmitis and BRE. Other causative microorganisms of bacterial endophthalmitis, including staphylococci and streptococci, have not been studied. Further research using these bacterial species is required in the future. This experiment is a proof of concept that focuses on ensuring the establishment of infection and demonstrating the relationship between posterior vitreous detachment and bacterial infection. Our previous clinical report has shown many cases of endophthalmitis caused by bacteria with low virulence, such as coagulase-negative staphylococci. Conducting experiments using these bacteria would simulate conditions closer to the actual clinical practice. In addition, since the number of model rabbits used in each experiment was small, the present results should be verified by conducting experiments using a larger number of animals.

To the best of our knowledge, there is no other report demonstrating the relationship between PVD and endophthalmitis using animal models as in this study. Using animal models, the present study was able to validate that the presence or absence of PVD is involved in the aggravation of endophthalmitis, as is known from clinical experience; in other words, the absence of PVD is one of the factors that aggravate endophthalmitis. Although *P. aeruginosa* is a rare cause of endophthalmitis, it does cause severe sight-threatening endophthalmitis. Here we use it in our experimental model because it consistently caused endophthalmitis in our model. Future work will involve repeating these studies with Gram-positive bacteria that induce endophthalmitis.

Acknowledgments

Supported by JSPS KAKENHI (Grant 19K18858).

Disclosure: **R. Baba**, None; **K. Umazume**, None; **N. Koike**, None; **H. Goto**, None

References

- Gentile RC, Shukla S, Shah M, et al. Microbiological spectrum and antibiotic sensitivity in endophthalmitis: a 25-year review. *Ophthalmology*. 2014;121:1634–1642.
- Yassin SA. Bleb-related infection revisited: a literature review. *Acta Ophthalmol*. 2016;94:122–134.
- Yamamoto T, Kuwayama Y; Collaborative Bleb-related Infection Incidence and Treatment Study Group. Interim clinical outcomes in the collaborative bleb-related infection incidence and treatment study. *Ophthalmology*. 2011;118:453–458.
- Yamamoto T, Kuwayama Y, Kano K, Sawada A, Shoji N; Study Group for the Japan Glaucoma Society Survey of Bleb-related Infection. Clinical features of bleb-related infection: a 5-year survey in Japan. *Acta Ophthalmol*. 2013;91:619–624.
- Yamamoto T, Sawada A, Mayama C, et al. The 5-year incidence of bleb-related infection and its risk factors after filtering surgeries with adjunctive mitomycin C: collaborative bleb-related infection incidence and treatment study 2. *Ophthalmology*. 2014;121:1001–1006.
- Durand ML. Endophthalmitis. *Clin Microbiol Infect*. 2013;19:227–234.
- Hatano H, Inoue K, Matoba H, et al. Endophthalmitis in Japan—a nationwide study with reference to type and etiology. *Nippon Ganka Gakkai Zasshi*. 1991;95:369–376.
- Jackson TL, Eykyn SJ, Graham EM, Stanford MR. Endogenous bacterial endophthalmitis: a 17-year prospective series and review of 267 reported cases. *Surv Ophthalmol*. 2003;48:403–423.
- Umazume K, Suzuki J, Usui Y, Maruyama K, Wakabayashi Y, Goto H. Absence of posterior vitreous detachment is a risk factor of severe bleb-related endophthalmitis. *J Ophthalmol*. 2019;2019:1585830.
- Umazume K, Suzuki J, Usui Y, Wakabayashi Y, Goto H. Possible relation between lack of posterior vitreous detachment and severe endogenous endophthalmitis. *J Ophthalmol*. 2016;2016:8561379.
- Yonemoto J, Noda Y, Masuhara N, Ohno S. Age of onset of posterior vitreous detachment. *Curr Opin Ophthalmol*. 1996;7:73–76.
- Hatano H, Sasaki T, Tanaka N. Pseudomonas endophthalmitis in rabbits—intravitreal inoculation of two pseudomonas strains [in Japanese]. *Nippon Ganka Gakkai Zasshi*. 1988;92:1758–1764.
- Kirihara Y, Takechi M, Kurosaki K, Matsuo H, Kajitani N, Saito Y. Effects of an anesthetic mixture of medetomidine, midazolam, and butorphanol and antagonism by atipamezole in rabbits. *Exp Anim*. 2019;68:443–452.
- Dhawale MR, Creaser EH. Analysis of an L-histidinol-utilizing mutant of *Pseudomonas aeruginosa*. *J Gen Microbiol*. 1975;91:241–248.
- Hazlett LD, Moon MM, Singh A, Berk RS, Rudner XL. Analysis of adhesion, piliation, protease production and ocular infectivity of several *P. aeruginosa* strains. *Curr Eye Res*. 1991;10:351–362.
- Chandler DB, Quansah FA, Hida T, Machemer R. A refined experimental model for proliferative vitreoretinopathy. *Graefes Arch Clin Exp Ophthalmol*. 1986;224:86–91.

17. Kowalski RP, Romanowski EG, Mah FS, Yates KA, Gordon YJ. Topical prophylaxis with moxifloxacin prevents endophthalmitis in a rabbit model. *Am J Ophthalmol*. 2004;138:33–37.
18. Benton AH, Fulton LK, Marquart ME. Exogenous *Streptococcus pneumoniae* endophthalmitis in diabetic rabbits. *Sci Rep*. 2017;7:46196.
19. Ermis SS, Cetinkaya Z, Kiyici H, Ozturk F. Treatment of Staphylococcus epidermidis endophthalmitis with intravitreal moxifloxacin in a rabbit model. *Toboku J Exp Med*. 2005;205:223–229.
20. McCulloch DL, Kondo M, Hamilton R, et al. ISCEV extended protocol for the stimulus-response series for light-adapted full-field ERG. *Doc Ophthalmol*. 2019;138:205–215.
21. Kishi S, Shimizu K. Posterior precortical vitreous pocket. *Arch Ophthalmol*. 1990;108:979–982.
22. Maguire JI. Postoperative endophthalmitis: optimal management and the role and timing of vitrectomy surgery. *Eye (Lond)*. 2008;22:1290–1300.
23. Clarke B, Williamson TH, Gini G, Gupta B. Management of bacterial postoperative endophthalmitis and the role of vitrectomy. *Surv Ophthalmol*. 2018;63:677–693.
24. Floney GD, Pecan PE, Cathcart JN, Palestine AG. Trends in treatment strategies for suspected bacterial endophthalmitis. *Graefes Arch Clin Exp Ophthalmol*. 2018;256:833–838.