

Transforaminal Thoracic Interbody Fusion for Thoracic Disc Prolapse: Surgicoradiological Analysis of 18 Cases

Global Spine Journal
2020, Vol. 10(6) 706-714
© The Author(s) 2019
Article reuse guidelines:
sagepub.com/journals-permissions
DOI: 10.1177/2192568219870459
journals.sagepub.com/home/gsj



Ajay Krishnan, MS^{1,2} , Devanand Degulmadi, MS¹,
Shivanand Mayi, MS¹, Mahesh Kulkarni, MS¹ , Chaitanya Reddy, MS¹,
Mreetunjay Singh, MS¹, Ravi Ranjan Rai, MS¹ , and Bharat R. Dave, MS¹

Abstract

Study Design: Retrospective observational study.

Objectives: Thoracic disc prolapse (TDP) surgeries have reported complications ranging from paraplegia to approach related complications. This study is to present a series of TDP patients surgically treated with transforaminal thoracic interbody fusion (TTIF). Emphasis on surgical technique and strategies to avoid complications are analyzed.

Methods: Eighteen patients with TDP were included. Imagings were analyzed for end-plate changes and calcification. Type of disc prolapse (central/para-central) and percentage of canal occupancy were noted. Objective outcome was quantified with Visual Analogue Scale (VAS), modified Nurick's grade, and ASIA (American Spinal Injury Association) score. All complications were noted.

Results: Eighteen patients (average age 43.65 years) having total 22 levels operated, that included double level (n = 2) and missed level (n = 2) are reported. All patients had myelopathy. Calcification of disc (n = 13), central disc prolapses (n = 9), para-central (n = 11) and more than 50% canal occupancy (n = 8) were noted. VAS back pain, modified Nurick's grade and ASIA grade improved significantly in all patients. One patient had postoperative transient deficit. The functional score achieved its maximum at 1 year follow-up and remained static at final follow-up of 65.05 months. Union was achieved in all patients.

Conclusions: The most important factor for outcome in TDP is the technical aspect of avoiding cord handling and avoiding wrong level surgeries. TTIF is not devoid of complications but can give good results to posterior approach trained surgeons.

Keywords

thoracic disc prolapse, transforaminal, interbody, posterior, fusion, calcified disc, complication, myelopathy

Introduction

Thoracic disc prolapse (TDP) is infrequent and occurs with clinical features ranging from radiculopathy to significant myelopathy.¹⁻⁴ There has been no consensus in the treatment of TDP as each technique has unique advantages and disadvantages. The reported outcomes with various approaches do not give the superiority of one over another. Varied approach surgeries have reported complications ranging from paraplegia, paraparesis, recurrent disability/deficits, and other approach-related complications.^{2,3,5} Laminectomy was the only historical treatment ending with reports of high paresis or paralysis up to even 27%.^{6,7} Thus, trans-thoracic approach became a gold standard approach in the management of severe canal

compromised TDP.^{8,9} In a systematic review of 164 patients analyzed, 3%, 13%, and 25% had permanent neurologic deterioration in surgery via the transthoracic approach, the posterolateral approach, and the thoracoscopy approach, respectively.⁹ However, posterior approach decompression with or without fusion has been advocated as an alternative

¹ Stavva Spine Hospital & Research Institute, Ahmedabad, Gujarat, India

² BIMS Hospital, Bhavnagar, Gujarat, India

Corresponding Author:

Ajay Krishnan, C302, Orange Avenue, Maple County I, Thaltej, Ahmedabad, Gujarat 380059, India.

Email: drajaykrishnan@gmail.com



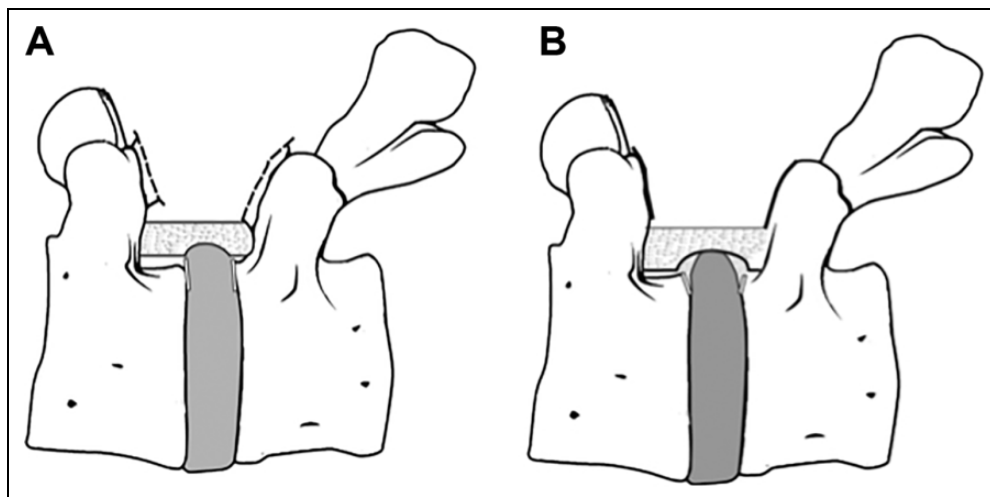


Figure 1. (A) Illustration showing the wide exposure with laminotomy. Sharp annular margin cut is needed for soft big disc to deliver it ventrally into the space created in the intervertebral disc area. (B) Complete laminectomy is needed when end-plate spurs of upper end-plate are present. Oblique markings showing the osteotomy cut that needs to be placed when end-plate spur is present.

and successful treatment modality in other reports.¹⁰⁻¹⁷ One of the main problems is that an accomplished spine surgeon will see very low numbers of TDP in his life time. This makes long series reporting less likely. We present our case series of TDP surgically treated with transforaminal thoracic interbody fusion (TTIF). We also analyzed the radiological features, surgical technique, complications and strategies to avoid complications.

Materials and Methods

This was a retrospective observational study. So, no institutional/independent ethics committee approval was needed. Informed consent was taken from all patients. Eighteen patients operated upon for TDP by TTIF with bone graft alone or bone graft and cage between July 2010 and January 2015 at our institute with a minimum follow-up of 3 years were included in this retrospective study. All the demographic, clinical, radiological, and operative details were reviewed from the hospital records and on follow-up visits. Age, sex, presence of radiculopathy, myelopathy, and involvement of bladder and bowel were noted. Visual Analogue Scale (VAS) for pain, modified Nurick's grade scoring for myelopathy was used for objective assessment of disability and affection along with ASIA (American Spinal Injury Association) score.

Radiological Assessment

End-plate damage changes (superior/inferior or both) and calcification at the level of disc prolapse were noted on radiographs. Level of disc prolapse, type (central/para-central), migration of disc (proximal/distal), end-plate spur, end-plate defects, status of posterior longitudinal ligament (intact/breached), and ligamentum flavum hypertrophy-ossification were noted on magnetic resonance imaging (MRI) and computed tomography (CT) scans. CT scan was obtained only in a few patients.

Calcified spurs are end-plate ossifications/projections that are accompanied by soft/hard disc fragment. End-plate defects are the discontinuity or breaks noted in the superior or inferior end plates at the disc prolapse level. Schmorl's nodes are defined as vertical protrusions of the contents of the nucleus into the adjacent vertebral body. Canal compromise was measured as <50% or >50% on T2 axial section at most stenotic level.

Surgical Technique and Strategies

All the patients were operated under general anesthesia in prone position by a 3-surgeon team. No neuromonitoring was done. Care was taken to identify the level by cross checking radiographs with MRI/CT scans and intraoperative C-arm imaging. Freedom of speech and reconfirmation by at least 3 surgeons was followed to avoid any missed level surgery. Operative time, blood loss, dural tear, and strategies employed were noted. Routine posterior midline approach was used to expose the posterior elements. Pedicle screws were inserted by free hand and confirmed by image guidance. Connecting rod was placed on one side. Laminectomy or laminotomy (Figure 1) was done manually using rongeur and osteotomes. After December 2012, UBS (ultrasonic bone scalpel; Misonix Farmingdale, NY, USA) was used for laminectomy and bone sculpting. Loupe magnification was used when required. Hemostasis was achieved using bipolar cautery. Symptomatic side/radiological prominent compressive side was selected to remove the contained interbody disc for interbody fusion. No cord retraction was done to expose disc. Careful dissection in separating the plane between dura and the disc was done with due care to adhesions. On selected side, though screw track is made in the lower body, but it was kept empty. This was to keep better visibility and avoid visual hinderance by screw head. Total/partial facetectomy-pediclectomy was completed. Block chisel entry was made into the intervertebral disc and sequential

reaming followed by complete debulking done. End-plate preparations were completed and interbody fusion completed. It was filled with autogenous bone graft alone (local posterior element harvest) or bone graft combined with cage. The use of cage or bone graft was decided on the basis of the available disc space size, age, and associated comorbidities. If there was small disc space, older age, and any comorbidities that preclude long-duration surgery, then the cage was avoided. After this procedure, the actual compressive intracanalicular disc was addressed to remove it. Strategies employed were multiple but not limited to one and varied from case to case depending on the location of the disc, size/migration, hardness of the disc and associated end-plate calcific spur. These were to avoid pathological cord manipulation and to get the best visualized angle to achieve complete ventral compression. The strategies were the following:

- A. Superior half of pedicle or the complete pedicle removed when inferior vertebral superior end plate spur was present or high downward migration was present.
- B. Tying of the root and sacrificing it when superior vertebral inferior end-plate spur was present or big calcified or high upward migration was present.
- C. Skin transverse incision and transverse multifidus muscle cutting (T incision, ie, horizontal T) with single rib and transverse process excision to have lateral extra cavity approach (LECA) was taken in central big disc with or without calcifications.
- D. Only skin transverse incision and transverse multifidus muscle cutting (T incision) without any LECA to improve the exposure and improve angle of approach was taken when calcification was only para-central and desired angle was not obtained from direct midline approach.
- E. Opposite side facet was sacrificed to reach the disc and release the ventral part attachment which has a continuous opposite side with or without compression. This was not needed in unilateral migrations or extrusions which were soft.
- F. When migrated extruded piece in visibility present, it was delivered out directly from the spinal canal first laterally then out. For soft disc protrusion without spurs perpendicular cut was made at annulus endplate junction (Figure 1a). But, if the central disc was present or calcified spurs are associated, osteotome was used to cut through the spur margins obliquely with the body (Figure 1b). Then the compressive soft-hard disc was pushed into the already created ventral empty disc cavity before it was pulled out. The vertebral body osteotomy is limited to the posterior 1/4th and posterior elements only. Extensive reconstruction and deformity correction are not needed as against in a posterior vertebral column reconstruction.

Postoperative Protocol and Follow-up

No anticoagulants were given as it is institutional protocol to give only mechanical prophylaxis. All patients were subjected to postoperative T2 sagittal screening MRI as a routine protocol. This was to check for level and adequacy of decompression. Postoperative mobilization was started after 24 hours as tolerated and based on patients' neurological status. Patients were discharged on fourth to sixth postoperative day. Postoperative neurological improvement was evaluated by modified Nurick's grade and with ASIA score. VAS was noted for back pain. Postoperative neurological worsening was noted along with any complications in recovery period. Complications were noted as major (that interfered with treatment significantly or outcome course) and minor (which did not interfere significantly). Follow-up radiographs were taken and assessed for presence of bony union and status of instrumentation. Fusion was considered if there was no loss of fixation and no peri screw loosening at 3-year follow-up with or without apparent continuous bone formation between the vertebral body.

Statistics

Patients' demographics and characteristic categorical variables were analyzed. Mean (standard deviation) for applicable variables were calculated. Each category was compared by using appropriate statistical tools like Wilcoxon test, Pearson correlations, unpaired Student *t* test, and paired *t* test. The significance of the relation was considered in patients only if $P < .05$. When the data was not normally distributed, nonparametric Mann-Whitney test was used to find significance of difference. The software used was SPSS version 20.0.

Results

No institutional review board approval was needed as it was a retrospective observational study. Eighteen patients were enrolled in the study. All patients were operated upon with high risk consent. There were 17 males and 1 female with mean age of 43.65 (12.53) years. Twelve patients had myelopathy and 6 patients had myeloradiculopathy. Total number of levels operated were 22, which included double level in 2 cases. Also, in it are included 2 missed level surgeries. T8-9 ($n = 1$), T10-11 ($n = 6$), T11-12 ($n = 8$), T12-L1 ($n = 7$) were the levels addressed. On radiographs, end-plates were normal ($n = 7$), calcification of disc ($n = 13$), and end-plate spur ($n = 16$) in the involved levels. On MRI, central disc prolapses ($n = 11$), right para-central ($n = 10$), and left para-central ($n = 1$) were noted. Eight cases had more than 50% canal occupancy. Eleven cases had end-plate defects on MRI: superior ($n = 0$)/inferior ($n = 8$)/both ($n = 3$). Seven cases had superior migration of disc, 3 had inferior migration, and 12 were central. Posterior longitudinal ligament was intact in 15 patients and breached in = 3 patients. CT were done in 6 cases only. Associated ligamentum flavum hypertrophy was seen at the level of disc prolapse in 2 cases. One case had laminectomy done previously at

Table 1. Surgical Decision Affecting Radiological Features of Thoracic Disc Prolapse and the Main Strategic Decisions for Approach and 360-Degree Decompression of the Cord.

No.	Sex	Level	Prolapsed Nucleus Calcification (+/–)	End-plate Spur, Bilateral Both Right and Left (B), Unilateral (U)	Migration Nil/Up/Down	Posterior Longitudinal Ligament Breached (B) or Intact (I)	Central (C)/Para-Central (PC)	Canal Occupancy (%)	Midline/T-Incision/LECA	Bilateral Right and Left Access and Release (+/–)
1	Male	T10-T11	+	B	Nil	B	PC	>50	LECA	+
2	Male	T11-T12	–	B	Up	I	C	<50	Midline	+
3	Male	T12-L1	+	B	Down	I	C	<50	Midline	+
4	Male	T11 ^a -T12-L1	+	U	Up	I	PC	<50	Midline	+
5	Male	T11-T12	+	B	Down	B	PC	>50	T incision	+
6	Male	T10-T11	+	U	Nil	I	PC	<50	Midline	+
7	Male	T11 ^a -T12-L1	–	U	Nil	I	PC	<50	Midline	–
8	Male	T12-L1	+	U	Up	I	PC	<50	T incision	–
9	Male	T12-L1	–	U	Up	I	PC	<50	Midline	–
10	Male	T10-T11	+	U	Nil	I	PC	<50	Midline	–
11	Female	T12-L1	+	B	Up	I	PC	>50	LECA	+
12	Male	T11-T12	+	B	Nil	I	C	<50	Midline	+
13	Male	T12-L1	+	U	Down	B	PC	<50	Midline	–
14	Male	T11-T12	+	B	Up	I	C	>50	T incision	+
15	Male	T10-T11	–	B	Nil	I	C	>50	T incision	+
16	Male	T8-T9	+	U	Nil	I	C	>50	LECA	+
17	Male	T11-T12	+	B	Up	I	PC	>50	T incision	+
18	Male	T11-T12	+	U	Nil	I	C	>50	Midline	+

Abbreviation: LECA, lateral extra cavity approach.

^aTwo levels affected.

the same level of disc prolapse with no relief of symptoms. Associated L4-5 stenosis was operated with transforaminal lumbar interbody fusion in the same sitting in 1 patient and 1 patient had L5-S1 lytic listhesis that was asymptomatic and not addressed. Exposure was only midline posterior approach (n = 10), T incision (n = 5), and additional more access with LECA needed in 3 cases (Table 1). Interbody cage with bone graft was used in 15 cases and only bone graft in 3 cases. To avoid manipulations various strategies were used as needed to deliver the soft-hard ventral compression. The roots were sacrificed in 3 case bilaterally and 5 cases needed only unilateral sacrifice. Mean (SD) operative time was 130 (26) minutes. Estimated blood loss was 221.67 (71.97) mL. One patient had calcification of the dura itself with a migrating fragment, which was removed with focal planned durectomy without any untoward complications.

The VAS for back improved from 6.94 (1.11) preoperative to 1.0 (0.9) postoperatively at follow-up and was significant ($P < .0001$). The modified Nurick's grade improved from 3.44 (1.09) preoperatively to 1.66 (0.38) postoperatively at follow-up and was significant ($P < 0.001$). ASIA grade numerically improved from 2.33 (0.76) preoperatively to 2.94 (0.23) postoperatively at follow-up and was significant ($P = .0137$). The improvement of the functional score achieved its maximum at 1-year follow-up in all patients (Figure 2). These outcomes remained static at final follow-up of 65.05 (12.24) months. Union was achieved in all patients and no construct failure noted or disc space collapse or implant failure.

Two patients had missed levels surgery and one of them developed deficit (2 major complications). One was detected intraoperatively when the intended compression was not appreciable, and exploration was done at the lower level to correct further in the same sitting. The other one could not be identified intraoperatively, showed neurological deterioration, and was found to have been operated at the wrong level on postoperative MRI. He was operated on next day followed by quick neurological improvement at 6 weeks without any residual symptoms or disability at final follow-up. Three minor complications occurred. Nonrepairable dural axillary tear occurred in 1 patient that did not give any postoperative symptoms needing management. One patient had delayed wound healing at the T crossing point in LECA that took 5 weeks to secondarily heal. One patient had urinary tract infection managed conservatively.

Discussion

Historically as reported, only 0.15% to 4% of all symptomatic disc herniations are in thoracic spine.^{18,19} More commonly, the lower thoracic discs are involved and 75% of all the TDP are reported to occur below T8.¹⁸ TDP typically present with a variety of nonspecific symptoms, frequently leading to a wrong or delayed diagnosis.^{11,20,21} Men are more affected than women in TDP, with a peak age affection between 40 to 50 years.⁵ In our series also it was most common at T11-12

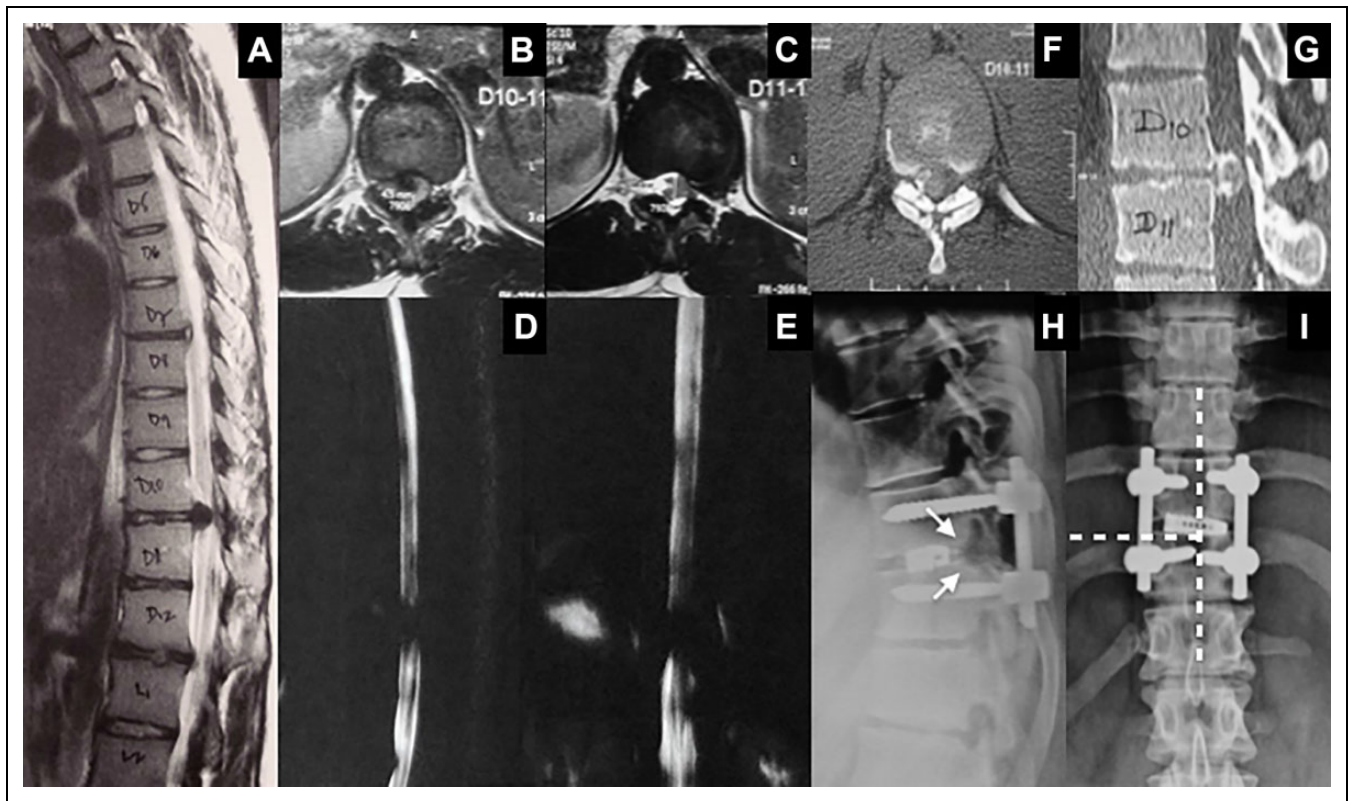


Figure 2. Magnetic resonance imaging (MRI): T2 sagittal (A), T1 axial (B), T2 axial (C), and sagittal and coronal MR myelogram (D, E) showing central extruded disc with paracentral encroachment and a canal occupancy >50% with complete myeloblock. Axial computed tomography (CT) scan (F) and sagittal CT scan (G) showing calcified disc. Postoperative lateral (H) and anteroposterior (I) radiographs showing single segment pedicle screw construct with interbody cage. Bilateral facetectomy and complete laminectomy was needed after a T incision exposure. The dotted line shows the overlay of the exposure. The arrows show the blunting of the end-plate margins, which is the oblique osteotomy cutting of the margin of the end-plate.

level ($n = 8$) and occurrence was predominantly in males (17, 94.44%) in their 40s.

Only laminectomy did not reduce ventral forces on the spinal cord and spinal cord manipulation was not tolerated well during discectomy with this approach.²² In fact, only laminectomy is contraindicated and an incomplete decompression by laminectomy can cause hourglass narrowing of the adjacent missed level by vascular congestion, which may precipitate a neurological deficit as occurred with one of our patients of missed level. But, it has been still recently considered for elderly patients with calcified TDP and some benefits.²³ Alternative surgical procedures that have been developed include oblique paraspinous,²⁴ posterolateral (transfacet pedicle sparing,^{11-14,19} transcostovertebral,²⁵ costotransversectomy²), LECA,^{3,26} anterolateral (transthoracic,²⁷ thoracoscopic²¹) and mini-thoracotomy approaches.²⁸ Fessler et al²⁸ have concluded that the decision for a particular technique should include the consideration of the anatomical location of the herniated material, general health of the patient and surgeons experience. They have even concluded that the mortality and morbidity are virtually identical between different techniques.²⁸ Anterior approaches have been favored because of their ability to safely achieve

ventral cord decompression. They have advantages of good visualization but carry potential morbidity associated with thoracotomy.²⁹ However, anterior approaches have been found difficult in cases with chest disease, decreased respiratory function, extreme obesity and to address the ligamentum flavum hypertrophy.^{5,9,29,30} Postoperative pneumonia, cerebrospinal fluid leakage, pulmonary embolism, deep vein thrombosis, intensive care unit stays, readmissions, longer hospital stay, and intercostal neuralgia have been serious sequelae with anterior approach.^{5,9,30}

In contrast to cervical and lumbar canal, thoracic canal is smaller and difficult to enter and explore ventrally without a facetectomy. Different variations and extensions of the approach were followed by us to increase the working angle of the surgeon directly to the ventrally located disc (Figure 3). Midline or T incision alone or with LECA helped us to get the best visualization and working angle, which was the first essential thing before decompressing ventral to cord. Customized long, down-going, and various angled curettes to achieve a unilateral decompression by a medial sparing transfacet approach is also reported along with a novel osteotomy in similar segmental fusion-decompression method.¹⁵⁻¹⁷ If they provide equal ventral exposure like anterior approach,

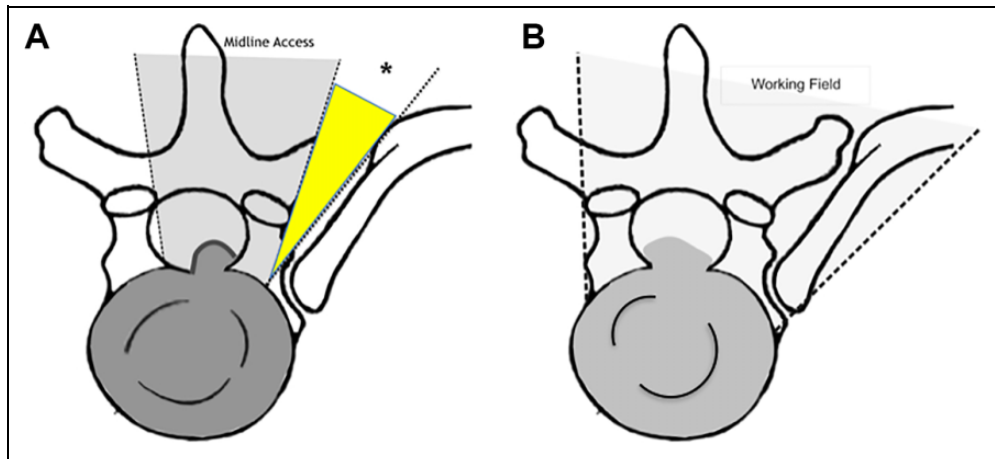


Figure 3. (A) Illustration showing widening of window of posterior midline approach with facetectomy to have better working angle ventral to the dura. T incision gives additional angle (*) for ventral work. (B) Lateral extra cavity approach (LECA) with rib excision for significant big and calcified disc or with end plate spurs. This increases visualization and approach angle significantly.

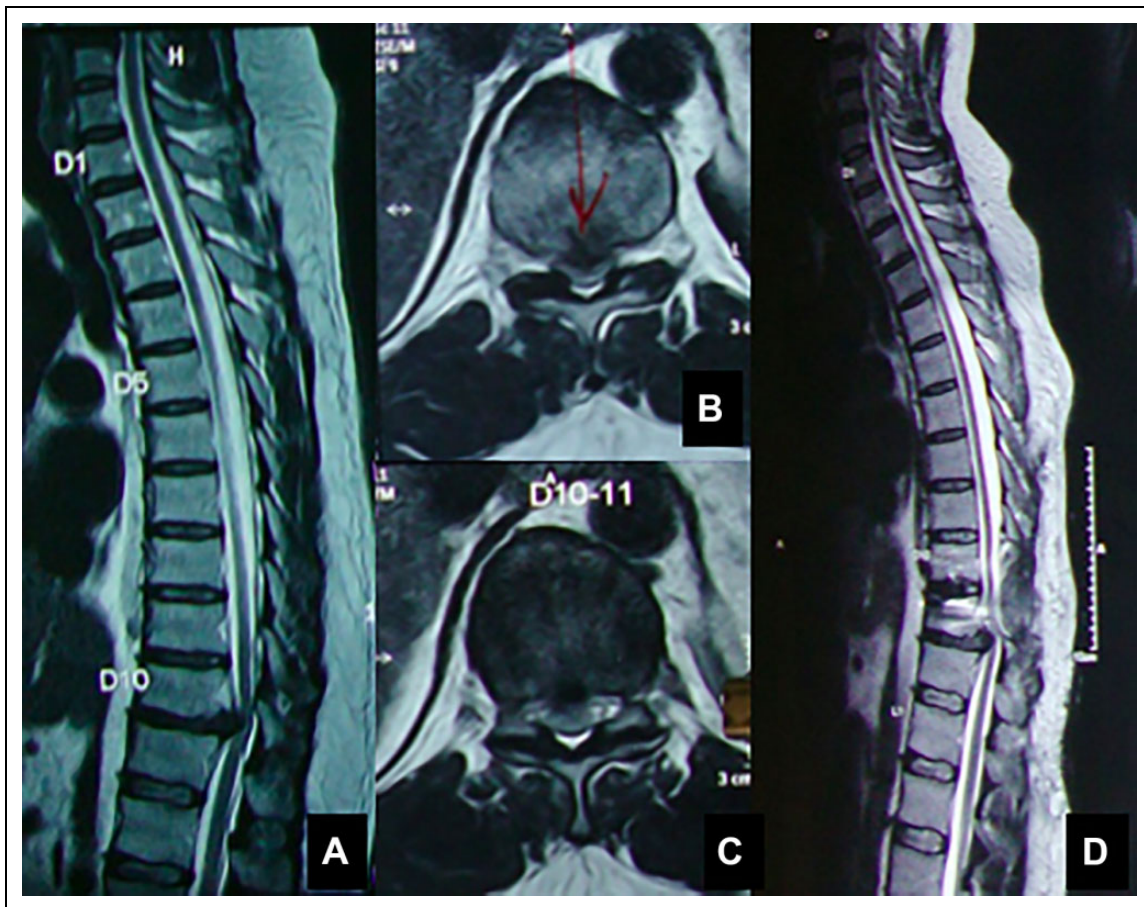


Figure 4. (A, B, C) Magnetic resonance imaging (MRI): sagittal partial film, axial T2 and T1 sequence that had marked the target level as T10-T11. Surgery was done on correct counting on radiographs and C arm. Postoperative patient had deficit with missed level which was revealed as T11-T12 in the postoperative full-length screening MRI (D).

nonanterior approaches for TDP can be favoured.³⁰ This is quite evident by all strategies we adopted, adequate ventral exposure can be achieved. Complete 360-degree decompression

with restoration of cerebrospinal flow and sphericity of cord was the ultimate goal and achieved in all 18 myelopathic patients.

Calcification of the disc is known to occur more frequently in thoracic spine with varying rates between 26% and 90%.^{31,32} The disc extrusion in calcified discs may result in damage to the ventral dura mater that may manifest as erosion, thinning, and tearing of the ventral dura.³¹ Disc calcification was seen in 14 patients in our series. End-plate spur was present in 16 cases needing en bloc removal of spur (Figure 2H). Five patients needed T incision (Figure 2I) exposure only for access angle. Eight cases had more than 50% spinal canal occupancy, and 3 of these required LECA. T incision was needed without LECA in 4 patients. One case with midline approach and facetectomy itself gave enough exposure. Bilateral access was needed in overall 13 cases (all were hard-calcified disc or with end-plate spurs) and unilateral access in rest of the cases was enough. So, >50% canal occupancy and calcified disc mandated more strategies of exposure. Both-side access is classically reported by Bransford et al.⁸ Bilateral approach from both sides of the disc has been acknowledged by some and refuted by others.¹⁵⁻¹⁷ The T incision and /or LECA increase the ventral non manipulative reach of the surgical instruments. Another notable thing is that the interbody fusion part is completed before the intracanalicular decompression is started. This is to decrease handling around cord for limited time. Two cases had associated ligamentum flavum hypertrophy without cord changes at the adjacent proximal level that was addressed with laminectomy alone at the same sitting. Careful reading of imaging, characterization of the quality and location of the TDP and preoperative planning of strategies are needed.

Intraoperative localization of the level in TDP has been a technical difficulty and wrong level spine surgery with prevalence of 1 per 3110 procedures has been reported.^{33,34} Counting of levels can be done from cervicothoracic junction or lumbosacral junction. This is done if full length radiographs are taken preoperatively. Horizontal skin markers can be fixed and preoperative radiographs can be taken.³⁵ Percutaneous insertion of k-wire into a pedicle as a marker has been one of the preferred method to avoid wrong level by Thambiraj et al.³⁶ Preoperative cement vertebroplasty performed in the outpatient setting has also been reported for morbidly obese patients to easily localize levels intraoperatively.³⁷ Vertebral spinous process preoperative marking with a live dye has also been practiced in thoracic surgery.³⁸ Counting of levels, checking, and reaffirmation by all operating team surgeons is a rule at our place. Presence or absence of 12th rib, lumbarization or sacralization, calcification at disc level, wedging of vertebra, reduction in disc space, and anterior osteophytes were additional things taken into consideration during identification of levels. Full spine screening film preoperatively and postoperative needs to be made mandatory in all the cases. In spite of all the measures taken to check the levels during surgery by us, we had 2 cases that were operated at the wrong level. Both showed surgery was done at the proximal to the affected disc level. In one case, it was improper marking of the level on preoperative MRI without full spine screening (Figure 4). The other case was intraoperative wrong level marking by the surgeon team. Both the patients were corrected and neurology improved in both the

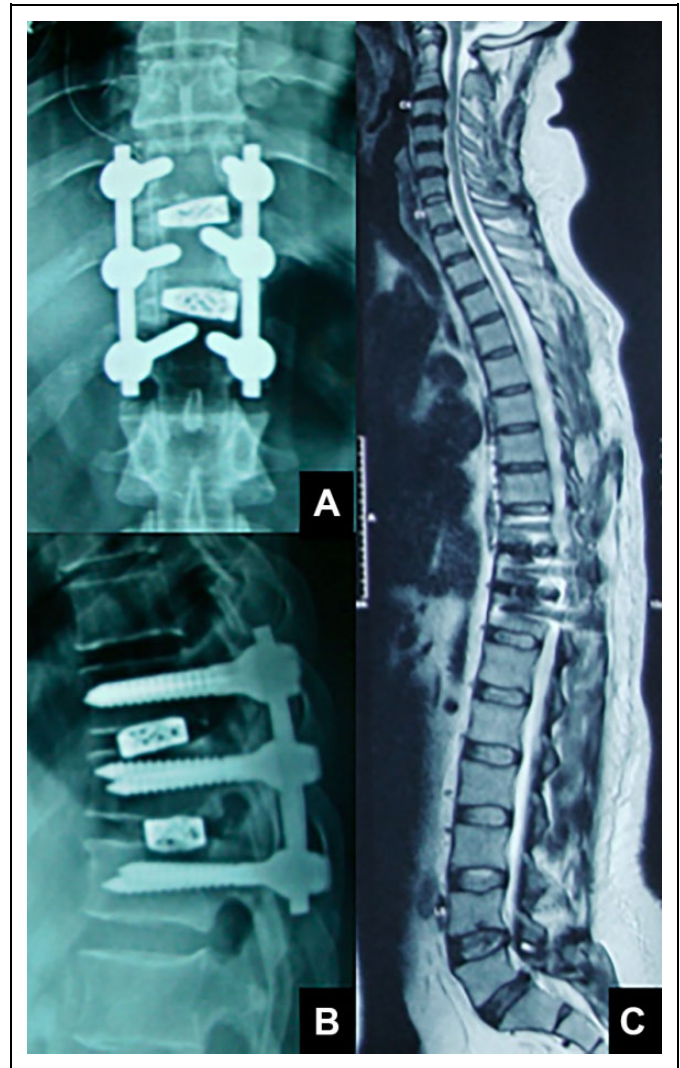

Figure 5. Postoperative radiograph after second surgery (A, B). Magnetic resonance imaging (MRI) (C) showing adequacy of surgery and the patient recovered to Nurick's grade I, in 8 weeks.

cases (Figure 5). Navigation and O-arm would be the future for avoiding missed levels completely.³⁹

Uribe et al⁴⁰ reviewed the literature on open versus minimally invasive approaches for TDP finding a complication rate of 36.7% and 28.4%, respectively. This again shows the steep learning curve associated with minimal invasive surgery and its demoting role in improving outcome in a critical disabling disease. Though, ventral endoscopic approach could be the future gold standard likely to replace all other surgeries if it gets adopted by all.⁴¹ Open TTIF for TDP has given us good clinical outcome with major correctible complication in 11.11% (n = 2). The VAS improvement and the ASIA scale improvement (Figure 6) were statistically significant. At the follow-up, all the patients had fusion at the operated level.

TTIF yielded good outcome in other series as well (n = 18, n = 11, n = 27, n = 25, n = 51) with minor or major complication rate of 33%, 18%, 3.70%, 12%, and 1.96% respectively.^{8,10,15-17} No deterioration due to cord handling noted in these series. No

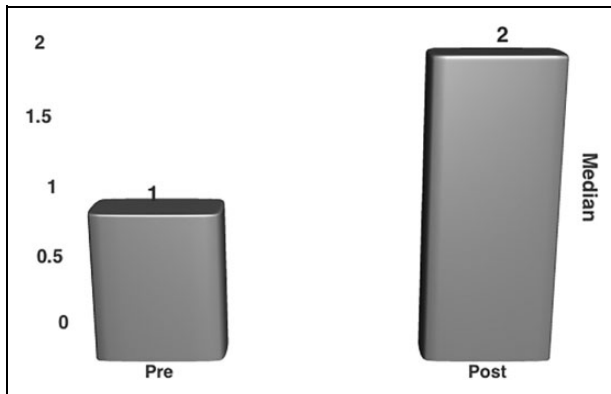


Figure 6. Bar diagram showing improvement of American Spinal Injury Association (ASIA) score improvement, which is significant (median used as it is ordinal data; $P = .0137$).




Figure 7. Bar diagram showing improvement of modified Nurick's grading, which is significant ($P < .001$).

anticoagulants were given by us. As the incidences of deep vein thrombosis in our temperate climates is less. Moreover, literature reports of postoperative hematoma and worsening are present.^{16,17} In our series the final outcome in terms of modified Nurick's grading was significant (Figure 7) and better in comparison to all other series.

The limitations of the present study should be noted. Our study and technique have many and methodological restrictions of retrospective studies with limited number of patients which is the most critical. But with the low incidence of TDP that a spine surgeon sees in his or her lifetime, this short series is also a good addition to existing literature. Anterior limited approach surgeries, especially endoscopic, may become the best technique in the future. But like any advances, it may remain limited with very few centers or surgeons and may not come to the rescue of limited resourced patients like in our part of the world. TTIF can be more easily learned by a surgeon. The significant improvements in objective scores and resumption of activities in all patients who presented with myelopathy and high disability does indicate the usefulness of TTIF in TDP.

The most important factor that the authors propose is the technical strategies for avoiding cord handling. Multiple MRI

findings have been highlighted that may help in surgical decision making and also technical aspects in addressing them. Whole spine screening with radiographic correlation is a must in order to avoid wrong level surgeries. Postoperative MRI confirmation should become standard protocol for dorsal pathologies and surgeries.

Conclusion

TTIF is a rewarding surgery in TDP provided that the strategies for avoiding cord manipulations and missed levels are followed. It is a workhorse approach that a posterior approach-trained surgeon can master.




Declaration of Conflicting Interests

The author(s) declared no potential conflicts of interest with respect to the research, authorship, and/or publication of this article.

Funding

The author(s) received no financial support for the research, authorship, and/or publication of this article.

ORCID iD

Ajay Krishnan, MS  <https://orcid.org/0000-0001-9808-2371>
 Mahesh Kulkarni, MS  <https://orcid.org/0000-0003-3147-050X>
 Ravi Ranjan Rai, MS  <https://orcid.org/0000-0002-0873-6907>

References

1. Brown CW, Deffer JP Jr, Akmakjian J, Donaldson DH, Brugman JL. The natural history of thoracic disc herniation. *Spine (Phila Pa 1976)*. 1992;17(6 suppl):S97-S102.
2. Maiman DJ, Larson SJ, Luck E, El-Ghatit A. Lateral extracavitary approach to the spine for thoracic disc herniation: report of 23 cases. *Neurosurgery*. 1984;14:178-182.
3. Otani KI, Yoshida MU, Fujii EI, Nakai SA, Shibasaki KE. Thoracic disc herniation. Surgical treatment in 23 patients. *Spine (Phila Pa 1976)*. 1988;13:1262-1267.
4. Stillerman CB, Chen TC, Couldwell WT, Zhang W, Weiss MH. Experience in the surgical management of 82 symptomatic herniated thoracic discs and review of the literature. *J Neurosurg*. 1998;88:623-633.
5. Mulier S, Debois V. Thoracic disc herniation: transthoracic, lateral or posterolateral approach? A review. *Surg Neurol*. 1998;49:599-608.
6. Lowe TG. Scheuermann disease. *J Bone Joint Surg Am*. 1990;72:940-945.
7. Logue V. Thoracic intervertebral disc prolapse with spinal cord compression. *J Neurol Neurosurg Psychiatry*. 1952;15:227-241.
8. Bransford R, Zhang F, Bellabarba C, Konodi M, Chapman JR. Early experience treating thoracic disc herniations using a modified transfacet pedicle-sparing decompression and fusion. *J Neurosurg Spine*. 2010;12:221-231.
9. Kerezoudis P, Rajjoub KR, Goncalves S, et al. Anterior versus posterior approaches for thoracic disc herniation: association with postoperative complications. *Clin Neurol Neurosurg*. 2018;167:17-23.

10. Yamasaki R, Okuda S, Maeno T, Haku T, Iwasaki M, Oda T. Surgical outcomes of posterior thoracic interbody fusion for thoracic disc herniations. *Eur Spine J*. 2013;22:2496-2503.
11. Stillerman CB, Chen TC, Day JD, Couldwell WT, Weiss MH. The transfacet pedicle sparing approach for thoracic disc removal: cadaveric morphometric analysis and preliminary clinical experience. *J Neurosurg*. 1995;83:971-976.
12. Arnold PM, Johnson PL, Anderson KK. Surgical management of multiple thoracic disc herniations via a transfacet approach: a report of 15 cases. *J Neurosurg Spine*. 2011;15:76-81.
13. Bilsky MH. Transpedicular approach for thoracic disc herniations. *Neurosurg Focus*. 2000;9:e3.
14. Le Roux PD, Haglund MM, Harris AB. Thoracic disc disease: experience with the transpedicular approach in twenty consecutive patients. *Neurosurgery*. 1993;33:58-66.
15. Zhuang QS, Lun DX, Xu ZW, Dai WH, Liu DY. Surgical treatment for central calcified thoracic disk herniation: a novel L-shaped osteotome. *Orthopedics*. 2015;38:e794-e798.
16. Yang SD, Chen Q, Ning SH, Ding WY, Yang DL. Modified eggshell procedure via posterior approach for sclerosing thoracic disc herniation: a preliminary study. *J Orthop Surg Res*. 2016;11:102.
17. Carr DA, Volkov AA, Rhoiney DL, et al. Management of thoracic disc herniations via posterior unilateral modified transfacet pedicle-sparing decompression with segmental instrumentation and interbody fusion. *Global Spine J*. 2017;7:506-513.
18. Arce CA, Dohrmann GJ. Herniated thoracic disks. *Neurol Clin*. 1985;3:383-392.
19. Ridenour TR, Haddad SF, Hitchon PW, Piper J, Traynelis VC, VanGilder JC. Herniated thoracic disks: treatment and outcome. *J Spinal Disord*. 1993;6:218-224.
20. Chen TC. Surgical outcome for thoracic disc surgery in the post laminectomy era. *Neurosurg Focus*. 2000;9:e12.
21. Russo A, Balamurali G, Nowicki R, Boszczyk BM. Anterior thoracic foraminotomy through mini thoracotomy for the treatment of giant thoracic disc herniations. *Eur Spine J*. 2012;21(suppl 2):S212-S220.
22. Cho JY, Lee SH, Jang SH, Lee HY. Oblique paraspinous approach for thoracic disc herniations using tubular retractor with robotic holder: a technical note. *Eur Spine J*. 2012;21:2620-2625.
23. Oitment C, Kwok D, Steyn C. Calcified thoracic disc herniations in the elderly: revisiting the laminectomy for single level disease. *Global Spine J*. 2018;9:527-531.
24. Dinh DH, Tompkins J, Clarks SB. Transcostovertebral approach for thoracic disc herniations. *J Neurosurg*. 2001;94(1 suppl):38-44.
25. Simpson JM, Silveri CP, Simeone FA, Balderston RA, An HS. Thoracic disc herniation. Re-evaluation of the posterior approach using a modified costotransversectomy. *Spine (Phila Pa 1976)*. 1993;18:1872-1877.
26. Foreman PM, Naftel RP, Moore TA, Hadley MN. The lateral extracavitary approach to the thoracolumbar spine: a case series and systematic review. *J Neurosurg Spine*. 2016;24:570-579.
27. Gille O, Soderlund C, Razafimahandri HJ, Mangione P, Vital JM. Analysis of hard thoracic herniated discs. review of 18 cases operated by thoracoscopy. *Eur Spine J*. 2006;15:537-542.
28. Fessler RG, Sturgill M. Complications of spine surgery for thoracic disc disease. *Surg Neurol*. 1998;49:609-618.
29. McCormick WE, Will SF, Benzel EC. Surgery for thoracic disc disease. Complication avoidance: overview and management. *Neurosurg Focus*. 2000;9:e13.
30. Bouthors C, Benzakour A, Court C. Surgical treatment of thoracic disc herniation: an overview. *Int Orthop*. 2019;43:807-816.
31. Barbanera A, Serchi E, Fiorenza V, Nina P, Andreoli A. Giant calcified thoracic herniated disc: consideration aiming a proper surgical strategy. *J Neurosurg Sci*. 2009;53:19-26.
32. Hott JS, Feiz-Erfan I, Kenny K, Dickman CA. Surgical management of giant herniated thoracic disc, analysis of 20 cases. *J Neurosurg Spine*. 2005;3:191-197.
33. Mody MG, Nourbakhsh A, Stahl DL, Gibbs M, Alfawareh M, Garges KJ. The prevalence of wrong level surgery among spine surgeons. *Spine (Phila Pa 1976)*. 2008;33:194-198.
34. Binning MJ, Schmidt MH. Percutaneous placement of radiopaque markers at the pedicle of interest for preoperative localization of thoracic spine level. *Spine (Phila Pa 1976)*. 2010;35:1821-1825.
35. Hsiang J. Wrong-level surgery: a unique problem in spine surgery. *Surg Neurol Int*. 2011;2:47.
36. Thambiraj S, Quraishi NA. Intra-operative localisation of thoracic spine level: a simple “K-wire in pedicle” technique. *Eur Spine J*. 2012;21(suppl 2):S221-S224.
37. Hsu W, Sciubba DM, Sasson AD, et al. Intraoperative localization of thoracic spine level with preoperative percutaneous placement of intravertebral polymethylmethacrylate. *J Spinal Disord Tech*. 2008;21:72-75.
38. Paolini S, Ciappetta P, Missori P, Raco A, Delfini R. Spinous process marking: a reliable method for preoperative surface localization of intradural lesions of the high thoracic spine. *Br J Neurosurg*. 2005;19:74-76.
39. Van de Kelft E, Costa F, Van der Planken D, Schils F. A prospective multicenter registry on the accuracy of pedicle screw placement in the thoracic, lumbar, and sacral levels with the use of the O-arm imaging system and StealthStation navigation. *Spine (Phila Pa 1976)*. 2012;37:E1580-E1587.
40. Uribe JS, Smith WS, Pimenta L, et al. Minimally invasive lateral approach for symptomatic thoracic disc herniation: initial multicentre clinical experience. *J Neurosurg Spine*. 2012;16:264-279.
41. Ruetten S, Hahn P, Oezdemir S, Baraliakos X, Godolias G, Komp M. Decompression of the anterior thoracic spinal canal using a novel full-endoscopic uniportal transthoracic retropleural technique—an anatomical feasibility study in human cadavers. *Clin Anat*. 2018;31:716-723.