

# Treatment of Idiopathic Intracranial Hypotension With Tea: A Case Report

Peyman Petramfar,<sup>1</sup> S. Saeed Mohammadi,<sup>2,\*</sup> and Farideh Hosseinzadeh<sup>2,\*</sup>

<sup>1</sup>Department of Neurology, School of Medicine, Shiraz University of Medical Sciences, Shiraz, IR Iran

<sup>2</sup>Student Research Committee, Shiraz University of Medical Sciences, Shiraz, IR Iran

\*Corresponding authors: S. Saeed Mohammadi, Student Research Committee, Shiraz University of Medical Sciences, Shiraz, IR Iran. E-mail: s.saeed.mohammadi@gmail.com; Farideh Hosseinzadeh, Shiraz University of Medical Sciences, Shiraz, IR Iran. E-mail: hosseinzadf@ymail.com

Received 2014 October 18; Revised 2015 March 30; Accepted 2015 April 18.

## Abstract

**Introduction:** The syndrome of spontaneous intracranial hypotension has been increasingly diagnosed since its discovery through magnetic resonance imaging (MRI). It is a rare syndrome that is due to the leakage of cerebrospinal fluid (CSF) from a tear in the dura and can occur at any age, even among adolescents, but is most frequently seen among females in late middle age.

**Case Presentation:** Here, we describe a 32-year-old woman with a two-month history of headaches and occasional nausea and vomiting (N/V). MRI without gadolinium was normal, but meningeal enhancement was seen in MRI with gadolinium. The lumbar puncture revealed a low opening pressure. Computed tomography myelography (CT myelography) showed no leakage; therefore, idiopathic intracranial hypotension was diagnosed. Treatment was started using tea, and the patient's headache got significantly better in about a day.

**Conclusions:** Conservative therapy, such as bed rest and caffeine treatment with eight cups of tea daily, yielded a significant improvement in our patient. Effectively, the patient constitutes a case of idiopathic intracranial hypotension due to undetectable CSF leakage or hyper-absorption, with good response to conservative management through tea-drinking. Further investigations with an appropriate sample size are needed in order to confirm this intervention in the treatment of idiopathic intracranial hypotension.

**Keywords:** Headache, Intracranial Hypotension, Tea, Caffeine, Idiopathic Orthostatic Hypotension

## 1. Introduction

Spontaneous intracranial hypotension is a rare syndrome of low cerebrospinal fluid pressure, resulting from cerebrospinal fluid volume depletion due to leakage or hyper-absorption. Annual incidence is 5 per 100,000. Women are twice as likely to have this condition compared with men, and it is more common between the ages of 40 - 50 (1). The most common and primary symptom of spontaneous intracranial hypotension is headache. These types of headache are typically orthostatic, but can also present persistently as daily headaches. They are often misdiagnosed as migraines, tension headaches, or viral meningitis. This syndrome is characterized by postural or orthostatic headache, secondary to low cerebrospinal fluid pressure, in patients without any history of trauma or dural punctures. These headaches may be accompanied by neck stiffness, nausea, vomiting, vertigo, tinnitus, deafness, or cognitive abnormalities (2, 3). The syndrome may also sometimes mimic fronto-temporal dementia, even causing changes of behavior in some patients, such as hypoactive-hypoaletness condition with somnolence, impaired attention, and stereotyped motor activity (2). The

clinical picture may well suggest the diagnosis, but MRI will help to confirm it and to localize the site of the CSF leakage. MRI myelograms are of particular value, but if MRI does not show an obvious diagnosis, a computed tomography myelogram should be performed (4). Myelography is the study of choice to identify the CSF leakage, but it is not always necessary in order to make the diagnosis. The leakage of CSF could be due to a tear in the dura, most frequently in the area where the spinal roots leave the subarachnoid space.

## 2. Case Presentation

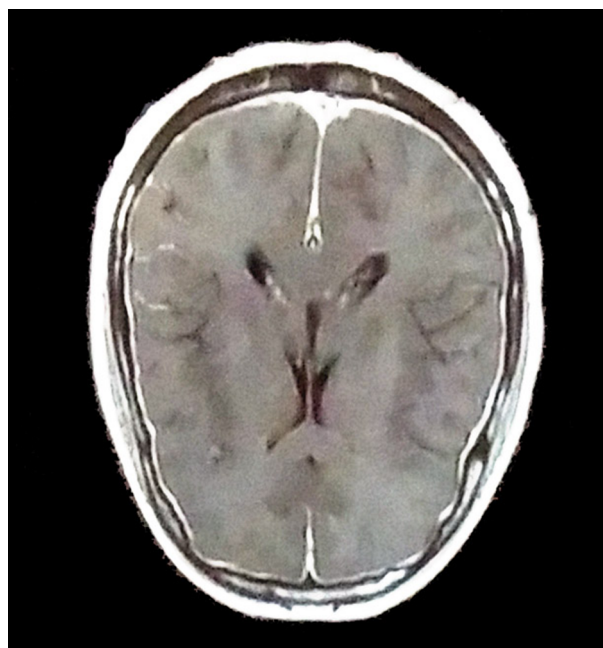
A 32-year-old woman was admitted to the ward with a two-month history of headaches, occasionally accompanied by nausea, vomiting, and vertigo. She had a chronic daily headache, starting in the morning and becoming worse in the upright position. The headaches manifested as a dull ache with moderate to severe intensity, which was constant during the day in the frontal and occipital regions bilaterally. Her headache got better when lying down. She also had a negative history of lumbar puncture, trauma, or manipulation. There was no fever, chills, dizziness,

unsteady gait, blurred vision, diplopia, or photophobia. In her past medical history, previous headaches, Ehlers-Danlos, Marfan syndrome, polycystic kidney disease, and spontaneous retinal detachment were not detected; all these conditions are related to intra-cranial hypotension. In drug history, the use of oral contraceptive pills was positive, but she did not use any other drugs. On physical examination, her vital signs were normal, with blood pressure: 120/80, pulse rate: 88/minutes, respiratory rate: 16/minutes, temperature: 37.2°C orally. General physical examination indicated that the head, neck, abdomen, extremities, and skin were normal. In addition, in neurological examination, the patient was awake, obeyed requests, and was oriented to time, place, and person. Her speech was fluent, and all cranial nerves were intact. An ophthalmologic exam showed normal eye movement and reactive pupils, and normal fundoscopic exam was detected. In the motor system, there was no atrophy, and the muscle power was 5/5. The plantar reflex was bilaterally downward and deep tendon reflexes were all 2/2. Sensory and cerebellar tests were normal, and meningeal signs were absent. She had no family history of these diseases, nor any past history of any other diseases. She was a teacher and did not have any psychiatric disorders. The patient had normal complete blood count (CBC). Brain computed tomography (CT) and magnetic resonance venography (MRV) were normal. Brain MRI, with and without gadolinium, was performed; the MRI without gadolinium was completely normal, but in the MRI with gadolinium, meningeal enhancement was clearly seen (Figures 1 and 2).

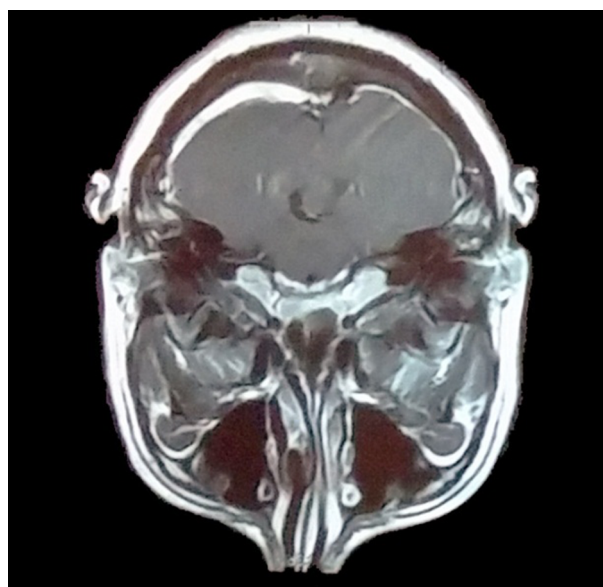
A lumbar puncture was conducted, revealing an opening pressure of 2 - 3 cm H<sub>2</sub>O with no leukocytes or erythrocytes, and with normal protein and glucose levels and regular lactate dehydrogenase (LDH) (Table 1). The lumbar puncture clearly worsened her positional headache. Her CT myelography from the cerebrum end to the spine revealed a normal condition, without any leakage of CSF or abnormality. Therefore, we tried to increase the intracranial pressure (ICP) of the patient with hydration, using dextrose water serum and a high caffeine diet, including drinking tea, and reducing daily activity. After two days, a significant improvement was seen in her headache.

### 3. Discussion

Spontaneous intracranial hypotension is an underdiagnosed condition. It is extremely important that we always keep this condition in our differential diagnosis during examination of patients with a chief complaint of headache. The patient in this case had a positive history of headaches; during the history taking, a key component was the positional nature of the headache. In our patient,



**Figure 1.** Brain MRI With Gadolinium -Meningeal Enhancement is Clearly Seen, Due to Intra-Cranial Hypotension



**Figure 2.** Brain MRI With Gadolinium -Meningeal Enhancement is Clearly Seen, Due to Intra-Cranial Hypotension

brain CT scan and brain MRI without gadolinium were normal. A lumbar puncture was performed, which showed very low cerebral pressure of about 2 - 3 cm H<sub>2</sub>O. The lumbar puncture worsened the patient's positional headache.

**Table 1.** CSF Analysis of the Patient With Idiopathic Intracranial Hypotension

CSF Analysis	
FL. LDH	85
FL. Protein, mg	51
FL. sugar	42
Fluid total count	No cell count

Since our patient had a positional headache, the other necessary investigations which were important for finding other causes were MRV and MRA; these were done, and were completely normal. Patchy meningeal enhancement, and downward displacement of the brain, are the characteristic imaging for a diagnosis of spontaneous intracranial hypotension (SIH) (5), which was approved by the MRI with gadolinium. SIH is an important risk factor for cerebral venous thrombosis (CVT), which is found in about 2.1% of the population with SIH (6, 7).

Epidural blood patching is the therapy of choice for spontaneous low cerebrospinal fluid (CSF) pressure headaches. Although there is insufficient data, some patients with spontaneous low CSF pressure headache might improve without any intervention. However, in many cases, treatment is necessary, not only to hasten improvement, but also to achieve full recovery.

Unfortunately, there is no definitive treatment protocol, and the efficacy of various treatments has not been studied. The first line therapy for most patients with spontaneous low CSF pressure headache consists of conservative treatment and/or epidural blood patching. For patients who do not respond to these treatments, supplementary choices include continuous epidural saline infusion, epidural fibrin glue, or surgical repair of the defect (8).

Conservative treatment for low pressure headache consists of avoidance of the upright position, consumption of analgesics, and strict bed rest. Oral or intravenous hydration of the patient, combined with high oral caffeine intake, helps to restore CSF volume (9).

If a leakage does not heal with bed rest, an epidural blood patch, percutaneous injection of fibrin glue, or surgical CSF repair may be needed. However, if no leakage can be found in the scalp or spinal canal, supportive care with an analgesic, hydration, and bed rest may be highly beneficial (10, 11).

We strongly assert that appropriate history taking played the most important part in the diagnosis of SIH in the patient; all of her findings were normal, except that she had low cerebral pressure with meningeal enhancement. For treatment of this patient, we decided to start conserva-

tive therapy such as placing in the bed rest position with daily consumption of tea as a hydration and caffeine diet. The patient was drinking about 200 cc of tea every two hours in the daytime, and the result was very interesting; her headache improved significantly in about 48 hours.

Because hydration and the use of caffeine is the first line in therapy for intracranial hypotension, and since tea is a traditional and low cost drink in Iran, it seems that drinking tea is a promising method of treatment for intracranial hypotension. Despite all these advantages, however, drinking this amount of tea could be unpleasant for the patient.

SIH is an underdiagnosed condition, and some patients may be misdiagnosed without a good history taking; therefore, history assessment and a physical exam should play a key role in the diagnosis of SIH, which can be confirmed with opening pressure CSF measurement. Conservative management could be helpful in idiopathic cases, but further evaluations are required to approve this issue; in addition, original studies with a suitable sample size are needed in order to confirm the therapeutic effects of tea.

### Acknowledgments

I would like to express my deepest appreciation to Professor N. Shokrpour for improving the English of this manuscript.

### Footnote

**Authors' Contribution:** Study concept and design: Peyman Petramfar, Farideh Hosseinzadeh and S. Saeed Mohammadi; acquisition of data: Hosseinzadeh and S. Saeed Mohammadi; analysis and interpretation of data: Peyman Petramfar and Farideh Hosseinzadeh; drafting of the manuscript: Farideh Hosseinzadeh and S. Saeed Mohammadi; critical revision of the manuscript for important intellectual content: Peyman Petramfar; Study supervision: Peyman Petramfar.

## References

1. Mea E, Chiapparini L, Savoiaro M, Franzini A, Bussone G, Leone M. Headache attributed to spontaneous intracranial hypotension. *Neurol Sci.* 2008;**29** Suppl 1:S164-5. doi: [10.1007/s10072-008-0914-5](https://doi.org/10.1007/s10072-008-0914-5). [PubMed: [18545924](https://pubmed.ncbi.nlm.nih.gov/18545924/)].
2. Schievink WI. Spontaneous spinal cerebrospinal fluid leaks. *Cephalalgia.* 2008;**28**(12):1345-56. doi: [10.1111/j.1468-2982.2008.01776.x](https://doi.org/10.1111/j.1468-2982.2008.01776.x). [PubMed: [19037970](https://pubmed.ncbi.nlm.nih.gov/19037970/)].
3. Mokri B. Spontaneous cerebrospinal fluid leaks: from intracranial hypotension to cerebrospinal fluid hypovolemia—evolution of a concept. *Mayo Clin Proc.* 1999;**74**(11):1113-23. doi: [10.4065/74.11.1113](https://doi.org/10.4065/74.11.1113). [PubMed: [10560599](https://pubmed.ncbi.nlm.nih.gov/10560599/)].
4. Ohwaki K, Yano E, Ishii T, Takanashi S, Nakagomi T. Symptom predictors of cerebrospinal fluid leaks. *Can J Neurol Sci.* 2008;**35**(4):452-7. [PubMed: [18973062](https://pubmed.ncbi.nlm.nih.gov/18973062/)].
5. Tosaka M, Sato N, Fujimaki H, Tanaka Y, Kagoshima K, Takahashi A, et al. Diffuse pachymeningeal hyperintensity and subdural effusion/hematoma detected by fluid-attenuated inversion recovery MR imaging in patients with spontaneous intracranial hypotension. *AJNR Am J Neuroradiol.* 2008;**29**(6):1164-70. doi: [10.3174/ajnr.A1041](https://doi.org/10.3174/ajnr.A1041). [PubMed: [18417608](https://pubmed.ncbi.nlm.nih.gov/18417608/)].
6. Yoon KW, Cho MK, Kim YJ, Cho CS, Lee SK. Sinus Thrombosis in a Patient with Intracranial Hypotension: A Suggested Hypothesis of Venous Stasis A Case Report. *Interventl Neuroradiol.* 2011;**17**(2):248-51.
7. Ade S, Moonis M. Intracranial hypotension with multiple complications: an unusual case report. *Case Rep Neurol Med.* 2013;**2013**:913465. doi: [10.1155/2013/913465](https://doi.org/10.1155/2013/913465). [PubMed: [24324901](https://pubmed.ncbi.nlm.nih.gov/24324901/)].
8. Schievink WI, Meyer FB, Atkinson JL, Mokri B. Spontaneous spinal cerebrospinal fluid leaks and intracranial hypotension. *J Neurosurg.* 1996;**84**(4):598-605. doi: [10.3171/jns.1996.84.4.0598](https://doi.org/10.3171/jns.1996.84.4.0598). [PubMed: [8613851](https://pubmed.ncbi.nlm.nih.gov/8613851/)].
9. Marcellis J, Silberstein SD. Spontaneous low cerebrospinal fluid pressure headache. *Headache.* 1990;**30**(4):192-6. [PubMed: [2335473](https://pubmed.ncbi.nlm.nih.gov/2335473/)].
10. Arai M, Takada T. [A case of spontaneous intracranial hypotension with multiple CSF leaks in the thoracic region]. *Rinsho Shinkeigaku.* 2005;**45**(9):679-81. [PubMed: [16248402](https://pubmed.ncbi.nlm.nih.gov/16248402/)].
11. Cho KI, Moon HS, Jeon HJ, Park K, Kong DS. Spontaneous intracranial hypotension: efficacy of radiologic targeting vs blind blood patch. *Neurology.* 2011;**76**(13):1139-44. doi: [10.1212/WNL.0b013e318212ab43](https://doi.org/10.1212/WNL.0b013e318212ab43). [PubMed: [21444899](https://pubmed.ncbi.nlm.nih.gov/21444899/)].