

Aspergillus colonization in patients with chronic obstructive pulmonary disease

Shahi M¹, Ayatollahi Mousavi SA¹, Nabili M², Aliyali M³, Khodavaisy S^{4,5}, Badali H^{6*}¹ Department of Medical Mycology and Parasitology, Faculty of Medicine, Tropical and Infectious Diseases Center, Kerman University of Medical Sciences, Kerman, Iran² Students Research Committee, Mazandaran University of Medical Sciences, Sari, Iran³ Pulmonary and Critical Care Division, Mazandaran University of Medical Sciences, Sari, Iran⁴ Department of Medical Parasitology and Mycology, Kurdistan University of Medical Sciences, Sanandaj, Iran⁵ Department of Medical Parasitology and Mycology, Tehran University of Medical Sciences, Tehran, Iran⁶ Invasive Fungi Research Center (IFRC), Department of Medical Mycology and Parasitology, School of Medicine, Mazandaran University of Medical Sciences, Sari, Iran***Corresponding author: Hamid Badali**, Invasive Fungi Research Center (IFRC), Department of Medical Mycology and Parasitology, School of Medicine, Mazandaran University of Medical Sciences, Sari, Iran. Email: badalii@yahoo.com

(12 October 2015; Revised: 18 November 2015; Accepted: 21 November 2015)

Abstract

Background and Purpose: Chronic obstructive pulmonary disease (COPD) has been recognized as a risk factor for invasive aspergillosis. Airway colonization by *Aspergillus* species is a common feature of chronic pulmonary diseases. Nowadays, the incidence of COPD has increased in critically ill patients. The aim of the present study was to isolate and identify *Aspergillus* colonies in the respiratory tract of COPD patients.**Materials and Methods:** This study was performed on 50 COPD patients, who were aged above 18 years, and were in intensive care units of three hospitals in Sari, Iran, for at least six days. All the samples obtained from sputum, bronchoalveolar lavage, and tracheal aspirates were cultured for fungi each week. According to the conventional techniques, *Aspergillus* isolates were initially based on growth and standard morphological characteristics. To confirm the identification of grown *Aspergillus*, the partial beta-tubulin gene was sequenced using specific primers.**Results:** A total of 50 patients, who met our inclusion criteria, were enrolled in the study during 2012-14. The results showed that 27 (54%) and 23 (46%) of the participants were male and female, respectively. The majority of the patients developed dyspnea followed by hemoptysis, chest pain, and high fever. Corticosteroids and broad-spectrum antibacterial agents were administered to 75% and 80% of the patients, respectively. Based on the conventional and molecular approaches, *A. fumigatus* (seven cases; 43.7%), *A. flavus* (five cases; 31.2%), *A. niger* (one case; 6.2%), *A. terreus* (one case; 6.2%), *A. oryzae* (one case; 6.2%), and *A. tubingensis* (one case; 6.2%) were recovered.**Conclusion:** Recovery of *Aspergillus* species from the respiratory tract of COPD patients with pneumonia indicates two possibilities: either colonization or invasive aspergillosis.**Keywords:** *Aspergillus*, Chronic obstructive pulmonary disease, Sequence Analysis

➤ How to cite this paper:

Shahi M, Ayatollahi Mousavi SA, Nabili M, Aliyali M, Khodavaisy S, Badali H. *Aspergillus* colonization in patients with chronic obstructive pulmonary disease. Curr Med Mycol. 2015; 1(3):45-51. DOI: [10.18869/acadpub.cmm.1.3.45](https://doi.org/10.18869/acadpub.cmm.1.3.45)

Introduction

In the recent years, chronic obstructive pulmonary disease (COPD) has been recognized as a risk factor for invasive aspergillosis, which occurs as a result of smoking tobacco or long-term exposure to pollution caused by burning of wood and other biomass fuels [1, 2]. Currently, COPD is the fourth cause of morbidity and mortality, and it has been estimated to rank third by 2020 [3].

The airflow limitation characteristic of COPD is caused by chronic inflammatory response in both airways (obstructive bronchiolitis) and lung parenchyma (emphysema) [4]. Four stages of COPD are defined as mild, moderate, severe, and very

severe (stages I to IV, respectively) [3]. Airway colonization by *Aspergillus* species is a common feature of chronic pulmonary diseases [5]. According to the National Nosocomial Infection Surveillance System, *Aspergillus* species were responsible for 1.3% of the nosocomial fungal infections [6]. Nowadays, incidence of COPD has increased, so that in India the occurrence of this disease has increased by was 4.1% [7]. In a retrospective study conducted by Khasawneh et al., it was found that COPD was the most common underlying disease (22%) in critically ill patients [8].

Various studies demonstrated the incidence

of invasive pulmonary aspergillosis (IPA) in COPD patients [9-11]. The increased prevalence of *Aspergillus* species colonization was observed in COPD patients [12], although other fungal infections such as colonization of *Pneumocystis jirovecii* is also possible [13]. *Aspergillus* species are responsible for a variety of infections ranging from saprophytic colonization of the respiratory tract to rapidly invasive and disseminated diseases [14].

Aspergillus can usually colonize in the upper respiratory tract, where the progress of the infection requires penetration of the spores in the lower airways, which is associated with germination and tissue invasion [15]. Given the small size (2–3 mm) of *Aspergillus* spores, *A. fumigatus* can reach lung parenchyma through the airways [16]. In COPD patients, ciliary activity of the bronchial epithelium, defense mechanisms of the airways, phagocytic host defense, and natural killer lymphocytes are often impaired, which facilitates the binding of conidia to the epithelial layer [17].

Consumption of corticosteroids and broad-spectrum antibiotics before ICU admission seems to be associated with high risk for IPA in COPD patients [11, 18]. Recurrent interpretation of *Aspergillus* hyphae in COPD patients might indicate an ongoing semi-invasive or invasive process, and must be avoided in the clinical context. The aim of the present study, therefore, was to isolate and identify colonization of *Aspergillus* species in the respiratory tract of COPD patients as an important risk factor for development of invasive aspergillosis.

Material and Methods

Study population

This study was performed on 50 patients (27 males and 23 females; age range: 18-80 years; mean age: 57.5 years) diagnosed with COPD, based on the Global Initiative for Chronic Obstructive Lung Disease guidelines [3]. The patients were admitted to the intensive care units (ICU) of hospitals affiliated (Imam Khomeini, Boo Ali and Shafa) to Mazandaran University of Medical Sciences, Sari, Iran, during 2012-14.

The study was approved by the Ethics

Committee (ethical no. 94.6.4-188) of Mazandaran University of Medical Sciences, Sari, Iran, and written informed consent was obtained from the patient's next of kin for publication of this report. A total of 65 respiratory samples, including sputum, bronchoalveolar lavage (BAL), and tracheal aspirates (intubated patients), were initially obtained six days after admission and once a week thereafter. BAL samples were obtained by fiberoptic bronchoscopy (Olympus BF20D, Philippines) twice a week if feasible. Direct examination with potassium hydroxide with calcofluor white (KOH + CFW) was done to identify fungal elements in all the samples.

In order for homogenization, respiratory tract specimens were diluted with an equal volume of 0.5% pancreatin, and were incubated for 1-2 hours at 30°C with shaking. Afterward, they were centrifuged for five minutes at 5000 rpm, and the supernatant was discarded. The remaining sediment was used for direct smear using calcofluor white (solution 0.1%, Sigma-Aldrich Darmstadt, Germany) and 15% KOH staining.

For isolation of *Aspergillus* species, the samples were cultured on Sabouraud Dextrose Agar (SDA, Difco) containing chloramphenicol, and were incubated at 30°C in dark for five days. According to the conventional techniques, *Aspergillus* isolates were identified based on growth and standard morphologically characteristic. All the yeasts were cultured on SDA plates and CHROM agar (Himedia, India) *Candida* and incubated at 35°C for 48 hours.

Molecular analysis

Genomic DNA was extracted using UltraClean Microbial DNA Isolation Kit (Mo Bio, Carlsbad, CA 92010, USA) according to the manufacturer's instructions, and was stored at -20°C until used. The partial β -tubulin genes were amplified and sequenced using TUB2A (5'-TGACCCAGCAGATGTT-3') and TUB2B (5'-GTTGTTGGGAATCCACTC-3') primers. Polymerase chain reaction (PCR) was performed on 50 μ L volumes of 25 ng template DNA, 5 μ L reaction buffer (0.1 M Tris HCl, 0.5 M KCl, 15 mM MgCl₂, 0.1% gelatin, 1% Triton X-100, pH 8.0), 0.2 mM of

each dNTP, and 2.0 U Taq DNA Polymerase (ITK Diagnostics, Leiden, Netherlands) using a Gene Amp PCR System 9700 (Applied Biosystems, Foster City, USA).

For primary denaturation, amplification was performed at 94°C in cycles of two minutes, followed by 35 cycles at 94°C (45 seconds), 58°C (30 seconds), and 72°C (120 seconds), with a final seven-minute extension step at 72°C. Amplicons were purified using QIAquick PCR Purification Kit (Qiagen, Cat. No. 28104, UK).

Sequencing was performed at 95°C for one minute, followed by 30 cycles at 95°C for 10 seconds, at 50°C for five seconds, and at 60°C for two minutes. Reactions were purified using Sephadex G-50 Fine (GE Healthcare Bio-Sciences, Uppsala, Sweden), and sequencing was done on an ABI 3730XL automated sequencer (Applied Biosystems, Foster City, CA 94404, USA). The sequence data were adjusted using SeqMan from Lasergene software (DNASTAR Inc., Madison, Wisconsin, USA), and were compared with GenBank database (<http://blast.ncbi.nlm.nih.gov/Blast.cgi>) and through basic local alignment search tool, and with a molecular database maintained for research purposes at the CBS-KNAW Fungal Biodiversity Centre, Utrecht, Netherlands.

Results

The results showed that 27 (54%) of the participants were male and 23 (46%) were female (f/m ratio 1:1.1), and the mean age was 57.5 years. The patients suffering from severe COPD were aged over 70 years. The mean duration of ICU stay was 11.5 days and the range of duration was 1–45 days. Table 1 summarizes the characteristics of the participants.

Pulmonary function tests were performed, and most of the patients (95%) demonstrated obstructive disease followed by dyspnea, hemoptysis, chest pain, and high fever. Corticosteroids and broad-spectrum antibacterial agents were administered to 75% and 80% of the patients, respectively. Subsequently, high-resolution computed tomography (CT) scan was performed in 45 patients (90%) within an average of one week after the onset of symptoms. The principal findings were lobular infiltration and multi-focal infiltration. More specific signs, such as halo or air-crescent signs were not observed.

Generally, 65 respiratory samples comprising BAL (41%), endotracheal (39%), and sputum (20%) were collected from the patients. Direct examination and/or culture of respiratory specimens yielded positive results for 42 of the samples (sensitivity: 65%). Colonization with *Candida* species, *Aspergillus* species, and other filamentous fungi and bacteria (*Pseudomonas aeruginosa*) were diagnosed in 20 (47.6%), 16 (38%), 2 (4.7%), and 4 (9.5%) specimens, respectively.

C. albicans (60.5%) was the most frequently recovered species by culture, followed by *C. tropicalis* (16%), *C. krusei* (15.5%), and *C. glabrata* (8%). The most common species of filamentous fungi was *Aspergillus* species. Based on the conventional and molecular approaches, *A. fumigatus* (seven cases; 43.7%), *A. flavus* (five cases; 31.2%), *A. niger* (one case; 6.2%), *A. terreus* (one case; 6.2%), *A. orezea* (one case; 6.2%), and *A. tubingensis* (one case; 6.2%) were recovered (Figure 1). All the samples showed a single band at 500 bp (amplicon) by gel electrophoresis; the band represented a fungal amplicon.

Table 1. Demographic and clinical information of chronic obstructive pulmonary disease patients

Mean age (year)	Gender	Intensive care unit stay (day)	Clinical sign	Radiographic sign	Source of sample	Isolated <i>Aspergillus</i> spp.
18-29: 8%	Male: 54% Female: 46%	1-7: 22%	Dyspnea: 42%	Lobular infiltration: 30%	BAL: 41% Endotracheal: 39% Sputum: 20%	<i>A. fumigatus</i> : 43.7%
30-49: 22%		7-16: 52%	Hemoptysis: 40.5%	Multi focal infiltration: 22%		<i>A. flavus</i> : 37.5%
50-69: 34%		>21: 26%	Chest pain: 37%	Consolidation: 14%		<i>A. niger</i> : 12.5%
>70: 36%			High fever: 35%	Nodule: 14%		<i>A. terreus</i> : 6.2%
			Plural rub: 10%	Plural effusion: 12%		<i>A. orezea</i> : 6.2%
	Cough: 5%	Cavitations: 8%	<i>A. tubingensis</i> : 6.2%			
		Neurological symptoms: 4%				

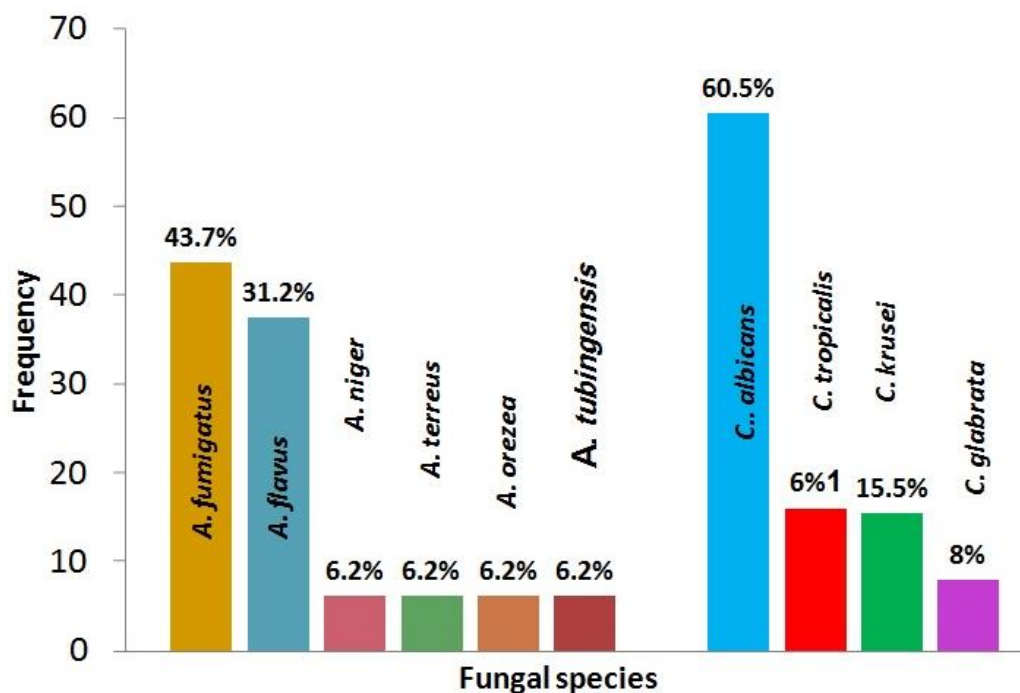


Figure 1. Frequency of filamentous and yeast fungi in chronic obstructive pulmonary disease patients

Discussion

COPD is a chronic inflammatory disease of pulmonary airways, and the most commonly encountered risk factor for this disorder is tobacco smoking. It has been estimated that this disease will become the third leading cause of mortality by 2020 [3]. *Aspergillus* species are ubiquitous airborne filamentous fungi, and are commonly isolated from lung transplant recipients. Although invasive Aspergillosis is relatively uncommon, non-invasive colonization of Aspergillosis occurs in approximately one-third of lung transplant recipients, which might lead to disease and sometimes mortality.

Predisposing factors such as mildly impaired host immunity and underlying pulmonary diseases can lead to aspergillosis [19, 20]. However, it is a big challenge between fungal colonization of the lung and active fungal infection. A recent study reflected COPD as one of the most significant predisposing factors for *Aspergillus* spp. colonization/infection in ICU patients [21, 21]. Guinea et al. reported that 1.63% of COPD patients had *Aspergillus* species in their lower respiratory tract samples, and 22.1% of these patients had probable IPA [11].

Colonization of the airways is defined as obtaining one or more positive cultures of

Aspergillus species from respiratory discharge (BAL, endotracheal, and sputum) in three consecutive months. We found our patients to be colonized, since none of our patients met the criteria for “proven”, “probable” or “possible” invasive fungal disease based on the definitions of invasive fungal disease propounded by the European Organization for Research and Treatment of Cancer and Mycoses Study Group (EORTC/MSG) Consensus Group [22].

None of the patients showed any radiological abnormalities which could not be explained by their underlying pulmonary pathology. Further follow-up visits are required to determine whether such colonization is a prelude to the development of co-morbidity due to invasive or disseminated fungal disease and if so, to work out the time kinetics and nature of such progression. However, none of our patients developed invasive fungal infection until the completion of the study.

In the current study, 16 positive cultures of *Aspergillus* species were obtained from 65 specimens and the prevalence of colonization was 24.6%. *A. fumigatus* was the most frequently recovered species (43.7%), followed by *A. flavus* (31.2%), *A. niger* (6.2%), *A. terreus* (6.2%), *A. orezea* (6.2%), and *A. tubingensis* (6.2%). Cornillet et al. reported that

in mycological examination of 79 BAL fluid specimens, *A. fumigatus* was the most frequently recovered species (44 cases; 90%), either alone or with another *Aspergillus* species, followed by *A. terreus* (four cases; 8%), *A. nidulans* (one case; 2%), *A. niger* (one case; 2%) and *A. flavus* (one case; 2%) [23].

A study by Huerta et al. reported that isolation rate of *Aspergillus* species from sputum specimens was 16.6%, whereas this rate was 14.4% after one year of follow-up [24]. In addition, Kurhade et al. [25] and Shahid et al. [26] isolated *Aspergillus* species from sputum and BAL samples of 16.3% and 14.7% of the cases with chronic respiratory diseases, respectively.

In contrast, in our cases isolation of *Aspergillus* species from respiratory samples, in the absence of signs of pneumonia, was considered to represent colonization. However, the patients presenting with risk factors were treated by antifungal drugs. Isolation of *Aspergillus* species from respiratory samples in critically ill patients was significantly related to both an underlying diagnosis of COPD and treatment with corticosteroids [14]. Therefore, COPD patients are at risk for *Aspergillus* spp. colonization [2, 27].

In addition, corticosteroid therapy may suppress neutrophils, which are the first immunological responses against *Aspergillus* infection [28]. In this study, corticosteroids were administered to 75% of the patients. These results have been confirmed by other studies, and have supported the relationship between pulmonary infection with *Aspergillus* spp. and use of intravenous corticosteroids in patients admitted to ICUs for severe exacerbation of COPD [29].

A study carried out by Afessa et al., indicated no isolation of *Aspergillus* species in the respiratory secretions of 250 COPD patients admitted to ICU due to acute respiratory failure, although no report on corticosteroid therapy was found [30]. In our study, broad-spectrum antibacterial agents were administered to 80% of the patients. Antibiotic therapy in patients with previous severe exacerbations is one of the key factors in promoting further *Aspergillus* species isolation. In a recent study conducted in Spain,

approximately 73% of COPD patients received antibiotics [31].

Our findings demonstrated considerable colonization of respiratory tract with *Pseudomonas aeruginosa* (9.5%). Isolation of bacterial infection, especially *Pseudomonas aeruginosa* in COPD exacerbation was also associated with high risk for *Aspergillus* species isolation [32-34]. In the present study, halo or air crescent signs were observed; however, classic CT scan characteristics such as, air-crescent and halo signs, as well as consolidation are very infrequent in COPD patients with invasive pulmonary aspergillosis [9, 11].

Ultimately, one of the major risk factors for *Aspergillus* species colonization/infection in COPD patients is treatment with corticosteroids. Therefore, in ICU patients with these underlying factors, treatment with antifungal agents should only be applied in the presence of symptoms of infection and positive cultures for *Aspergillus* species from respiratory samples.

Whereas, with colonization of *Aspergillus* species (confirmed by obtaining samples from respiratory secretions of critically ill patients), and absence of risk factors and signs and symptoms of infection, antifungal therapy should not be initiated.

Acknowledgments

We would like to thank School of Medicine, Mazandaran University of Medical Sciences, Sari, Iran and Kerman University of Medical Sciences, Kerman, Iran for their financial support. The authors are grateful to staff of the hospitals for cooperating with sampling. We also wish to thank Iman Haghani for his excellent technical assistance.

Authors' Contributions

H.B. and S.A. AM: Conceived, designed and revised paper; M.A: Samples offered and revised the manuscript; M.Sh, M.N and S.Kh: Performed the experiments and analyzed the data.

Conflicts of Interest

The authors declare that there is no conflict of interests regarding the publication of this paper.

Financial Disclosure

No financial interests regarding the content of this manuscript are declared.

References

- Vestbo J, Hurd SS, Agustí AG, Jones PW, Vogelmeier C, Anzueto A, et al. Global strategy for the diagnosis, management, and prevention of chronic obstructive pulmonary disease: GOLD executive summary. *Am J Respir Crit Care Med.* 2013; 187(4):347-65.
- Ader F, Bienvenu AL, Rammaert B, Nseir S. Management of invasive aspergillosis in patients with COPD: rational use of voriconazole. *Int J Chron Obstruct Pulmon Dis.* 2009; 4:279-87.
- Rabe KF, Hurd S, Anzueto A, Barnes PJ, Buist SA, Calverley P, et al. Global strategy for the diagnosis, management, and prevention of chronic obstructive pulmonary disease: GOLD executive summary. *Am J Respir Crit Care Med.* 2007; 176(6):532-55.
- Chung KF, Adcock IM. Multifaceted mechanisms in COPD: inflammation, immunity, and tissue repair and destruction. *Eur Respir J.* 2008; 31(6):1334-56.
- Yu VL, Muder RR, Poorsattar A. Significance of isolation of *Aspergillus* from the respiratory tract in diagnosis of invasive pulmonary aspergillosis. Results from a three-year prospective study. *Am J Med.* 1986; 81(2):249-54.
- Beck-Sagué C, Jarvis WR. Secular trends in the epidemiology of nosocomial fungal infections in the United States, 1980-1990. National Nosocomial Infection Surveillance System. *J Infect Dis.* 1993; 167(5):1247-51.
- Jindal SK, Aggarwal AN, Chaudhry K, Chhabra SK, D'Souza GA, Gupta D, et al. A multicentric study on epidemiology of chronic obstructive pulmonary disease and its relationship with tobacco smoking and environmental tobacco smoke exposure. *Indian J Chest Dis Allied Sci.* 2006; 48(1):23-9.
- Khasawneh F, Mohamad T, Moughrabieh MK, Lai Z, Ager J, Soubani AO. Isolation of *Aspergillus* in critically ill patients: a potential marker of poor outcome. *J Crit Care.* 2006; 21(4):322-7.
- Bulpa P, Dive A, Sibille Y. Invasive pulmonary aspergillosis in patients with chronic obstructive pulmonary disease. *Eur Respir J.* 2007; 30(4):782-7.
- Samarakoon P, Soubani A. Invasive pulmonary aspergillosis in patients with COPD: a report of five cases and systematic review of the literature. *Chron Respir Dis.* 2008; 5(1):19-27.
- Guinea J, Torres-Narbona M, Gijón P, Muñoz P, Pozo F, Peláez T, et al. Pulmonary aspergillosis in patients with chronic obstructive pulmonary disease: incidence, risk factors, and outcome. *Clin Microbiol Infect.* 2010; 16(7):870-7.
- Ader F. Invasive pulmonary aspergillosis in patients with chronic obstructive pulmonary disease: an emerging fungal disease. *Cur Infect Dis Rep.* 2010; 12(6):409-16.
- Khodavaissy S, Mortaz E, Mohammadi F, Aliyali M, Fakhim H, Badali H. *Pneumocystis jirovecii* colonization in Chronic Obstructive Pulmonary Disease (COPD). *Curr Med Mycol.* 2015; 1(1):42-8.
- Garnacho-Montero J, Amaya-Villar R, Ortiz-Leyba C, León C, Álvarez-Lerma F, Nolla-Salas J, et al. Isolation of *Aspergillus* spp. from the respiratory tract in critically ill patients: risk factors, clinical presentation and outcome. *Crit Care.* 2005; 9(3):R191-9.
- Pihet M, Carrere J, Cimon B, Chabasse D, Delhaes L, Symoens F, et al. Occurrence and relevance of filamentous fungi in respiratory secretions of patients with cystic fibrosis—a review. *Med Mycol.* 2009; 47(4):387-97.
- Latgé JP. The pathobiology of *Aspergillus fumigatus*. *Trends Microbiol.* 2001; 9(8):382-9.
- Latgé JP. *Aspergillus fumigatus* and aspergillosis. *Clin Microbiol Rev.* 1999; 12(2):310-50.
- Gao X, Chen L, Hu G, Mei H. Invasive pulmonary aspergillosis in acute exacerbation of chronic obstructive pulmonary disease and the diagnostic value of combined serological tests. *Ann Saudi Med.* 2010; 30(3):193-7.
- Maschmeyer G, Haas A, Cornely OA. Invasive aspergillosis: epidemiology, diagnosis and management in immunocompromised patients. *Drugs.* 2007; 67(11):1567-601.
- Hope WW, Walsh TJ, Denning DW. Laboratory diagnosis of invasive aspergillosis. *Lancet Infect Dis.* 2005; 5(10):609-22.
- Meersseman W, Lagrou K, Maertens J, Van Wijngaerden E. Invasive aspergillosis in the intensive care unit. *Clin Infect Dis.* 2007; 45(2):205-16.
- De Pauw B, Walsh TJ, Donnelly JP, Stevens DA, Edwards JE, Calandra T, et al. Revised definitions of invasive fungal disease from the European Organization for Research and Treatment of Cancer/Invasive Fungal Infections Cooperative Group and the National Institute of Allergy and Infectious Diseases Mycoses Study Group (EORTC/MSG) Consensus Group. *Clin Infect Dis.* 2008; 46(12):1813-21.
- Cornillet A, Camus C, Nimubona S, Gandemer V, Tattevin P, Belleguic C, et al. Comparison of epidemiological, clinical, and biological features of invasive aspergillosis in neutropenic and nonneutropenic patients: a 6-year survey. *Clin Infect Dis.* 2006; 43(5):577-84.
- Huerta A, Soler N, Esperatti M, Guerrero M, Menendez R, Gimeno A, et al. Importance of *Aspergillus* spp. isolation in Acute exacerbations of severe COPD: prevalence, factors and follow-up: the FUNGI-COPD study. *Respiratory research.* 2014; 15(1):17.
- Kurhade AM, Deshmukh JM, Fule RP, Chande C, Akulwar S. Mycological and serological study of pulmonary aspergillosis in Central India. *Indian J Med Microbiol.* 2002; 20(3):141-4.

26. Shahid M, Malik A, Bhargava R. Prevalence of Aspergillosis in chronic lung diseases. *Ind J Med Microbiol.* 2001; 19(4):201-5.
27. Barberan J, Alcazar B, Malmierca E, Garcia de la Llana F, Dorca J, Del Castillo D, et al. Repeated Aspergillus isolation in respiratory samples from non-immunocompromised patients not selected based on clinical diagnoses: colonisation or infection? *BMC Infect Dis.* 2012; 12(1):295-305.
28. Denning DW. Invasive aspergillosis. *Clin Infect Dis.* 1998; 26(4):781-803.
29. Bulpa PA, Dive AM, Garrino MG, Delos MA, Gonzalez MR, Evrard PA, et al. Chronic obstructive pulmonary disease patients with invasive pulmonary aspergillosis: benefits of intensive care? *Intensive Care Med.* 2001; 27(1):59-67.
30. Afessa B, Morales IJ, Scanlon PD, Peters SG. Prognostic factors, clinical course, and hospital outcome of patients with chronic obstructive pulmonary disease admitted to an intensive care unit for acute respiratory failure. *Crit Care Med.* 2002; 30(7):1610-5.
31. Miravittles M, García-Polo C, Domenech A, Villegas G, Conget F, de la Roza C. Clinical outcomes and cost analysis of exacerbations in chronic obstructive pulmonary disease. *Lung.* 2013; 191(5):523-30.
32. Miravittles M, Espinosa C, Fernández-Laso E, Martos JA, Maldonado JA, Gallego M. Relationship between bacterial flora in sputum and functional impairment in patients with acute exacerbations of COPD. *Chest.* 1999; 116(1):40-6.
33. Murphy TF, Brauer AL, Eschberger K, Lobbins P, Grove L, Cai X, et al. Pseudomonas aeruginosa in chronic obstructive pulmonary disease. *Am J Respir Crit Care Med.* 2008; 177(8):853-60.
34. Garcia-Vidal C, Almagro P, Romani V, Rodriguez-Carballeira M, Cuchi E, Canales L, et al. Pseudomonas aeruginosa in patients hospitalised for COPD exacerbation: a prospective study. *Euro Respir J.* 2009; 34(5):1072-8.