

Is Humerus a Good Choice for Intraosseous Access During Fluid Resuscitation in a Child with Severe Septic Shock?

Gökcan Öztürk¹, Burak Balaban², Tanıl Kendirli²

¹Department of Pediatrics, Ankara University, Faculty of Medicine, Ankara, Turkey

²Division of Pediatric Critical Care Medicine, Ankara University, Faculty of Medicine, Ankara, Turkey

Shock is a life-threatening clinical condition in the pediatric age group. The most common types of shock in children include hypovolemic, septic, cardiac, obstructive, distributive, and anaphylactic. Among these, a septic shock is a complex form that requires knowledge and experience in order to properly define and manage it. It is vital to support airway/breathing/circulation soon after its identification. It is very important to identify sepsis within the first 5 minutes. Moreover, establishing a vascular access is crucial to initiate fluid resuscitation and antibiotherapy as soon as possible.¹⁻³

It is not always possible to find a vascular access in young children. If the vascular access cannot be found, intraosseous pathways should be considered. Multiple venous thrombosis might occur due to recurrent central venous catheter attempts in pediatric intensive care or in patients with a history of recurrent hospitalization. In these cases, it may become impossible to establish a vascular access and to wear a central venous catheter. Hence, intraosseous access becomes the only way for patients to survive both for emergency as well maintenance treatments. Here, we present a pediatric case in which we have demonstrated the relevance of the intraosseous access both for emergency and subsequent treatments as an alternative route in a patient who has had thrombosis due to repeated central venous catheter insertion.⁴⁻⁶ The humerus is one of the alternatives used for intraosseous pathway.^{7,8}

A 6-year-old girl followed up with a home ventilator for hydrocephalus, operated meningo-myelocoele, ventriculoperitoneal shunt, epilepsy, and operated ventricular septal defect, and fed via percutaneous gastrostomy tube. She was under treatment for *Pseudomonas aureginosa* pneumonia in the in-patient clinic and was admitted to the pediatric intensive care unit upon the development of severe septic shock. Vascular access could not be established due to circulatory impairment. Owing to the repeated use of central venous catheters on her former admissions, her central veins were occluded partially or near-completely by thrombi. Attempts were made to establish intraosseous infusion via the right and then left tibia but were ultimately unsuccessful. Access was established via medial epicondyle, but leakage occurred after 2 hours. As the next option, we tried intraosseous access from both anterior and superior iliac spines. Intraosseous access via anterior and superior iliac spines was successful. On the first day of the procedure, a leakage was detected in the intraosseous access, and new access was established via the left humerus of the patient (the center of the diaphysis) (Figure 1A) and we checked it via bone x-ray (Figure 1B). The patient effectively received 0.1 mcg/kg/minute epinephrine infusion, meropenem and amikacin as antibiotics, and fluid therapy at the rate of 66 cc/hour through the intraosseous access line for 22 hours. After this, a central venous catheter was achieved through the left jugular vein of the patient as circulation improved, and the humeral intraosseous access line was terminated. The diaphyseal center of the humerus was chosen because it is the best palpable part of the bone. No complications occurred during the use or after the removal of humeral intraosseous access.

In conclusion, a humeral intraosseous line is an alternative and optional way to administer treatment for patients with septic shock while unprovided other preferable intraosseous line points.

Correspondent author:

Gökcan Öztürk

✉gokcan_ozturk@hotmail.com

Received: October 13, 2021

Accepted: November 17, 2021

Content of this journal is licensed under a Creative Commons Attribution-NonCommercial 4.0 International License.



Cite this article as: Öztürk G, Balaban B, Kendirli T. Is humerus a good choice for intraosseous access during fluid resuscitation in a child with severe septic shock? *Turk Arch Pediatri.* 2022;57(2):237-238.

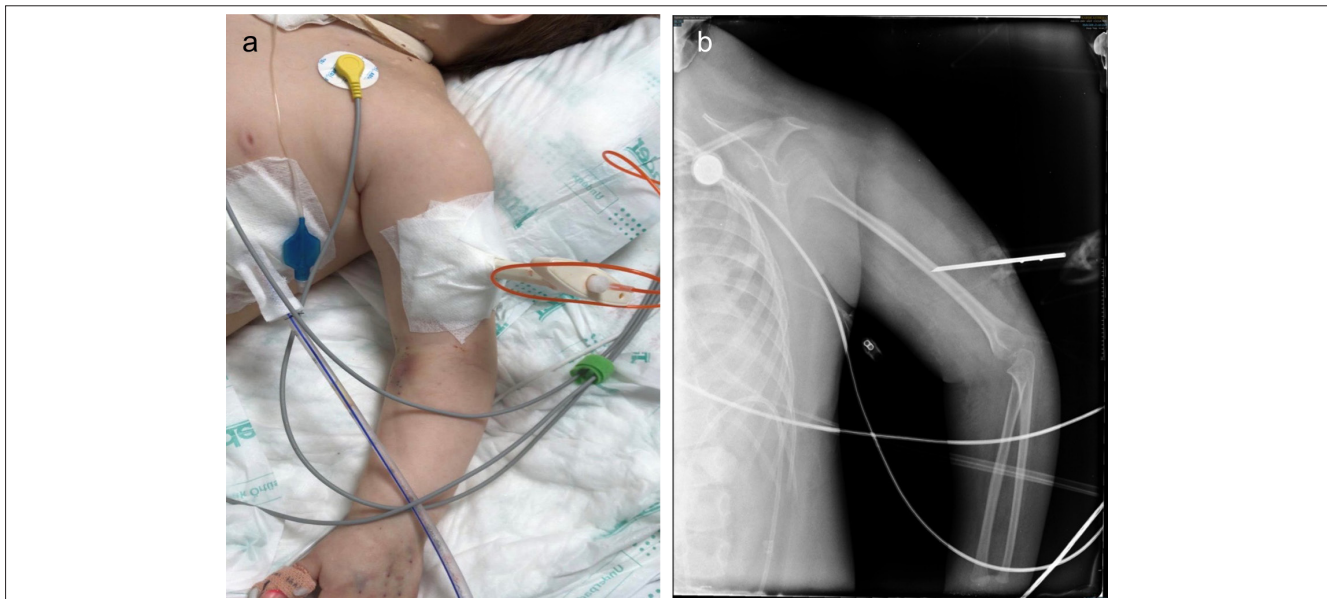


Figure 1. (A) Intraosseous access on the left humerus and (B) The sight of intraosseous pine entering to humerus on bone x-ray.

Informed Consent: Written informed consent was obtained from the patient's parents.

Peer-review: Externally peer-reviewed.

Author Contributions: Concept – G.Ö., B.B., T.K., Design – G.Ö., B.B., T.K., Supervision – T.K. Resources – G.Ö., B.B., T.K.,; Materials – G.Ö., B.B., T.K.,; Data Collection and/or Processing – G.Ö., B.B., T.K.,; Analysis and/or Interpretation – G.Ö., B.B., T.K.,; Literature Search – G.Ö.,; Writing Manuscript Writing – G.Ö.,; Critical Review – G.Ö., B.B., T.K.

Conflict of Interest: The authors have no conflicts of interest to declare.

Financial Disclosure: The authors declared that this study has received no financial support.

REFERENCES

- Duman M, Şevketoglu E, Arslanköylü AE. Sepsis and Septic Shock Protocol in Children. *Pediatric Emergency and Intensive Care Society*; 2018;1:1-22.
- Goldstein B, Giroir B, Randolph A, International Consensus Conference on Pediatric Sepsis. International pediatric sepsis consensus conference: definitions for sepsis and organ dysfunction in pediatrics. *Pediatr Crit Care Med*. 2005;6(1):2-8. [\[CrossRef\]](#)
- Menon K, Schlapbach LJ, Akech S, et al. Pediatric sepsis definition- A systematic review protocol by the pediatric sepsis definition taskforce. *Crit Care Explor*. 2020;2(6):e0123. [\[CrossRef\]](#)
- Luck RP, Haines C, Mull CC. Intraosseous access. *J Emerg Med*. 2010;39(4):468-475. [\[CrossRef\]](#)
- El-Nawawy AA, Omar OM, Khalil M. Intraosseous versus intravenous access in pediatric septic shock patients admitted in the Alexandria University pediatric Intensive Care Unit. *J Trop Pediatr*. 2018;64(2):132-140. [\[CrossRef\]](#)
- Rosenberg H, Cheung WJ. Intraosseous access. *CMAJ*. 2013;185(5):E238. [\[CrossRef\]](#)
- Eifinger F, Scaal M, Wehrle L, Maushake S, Fuchs Z, Koerber F. Finding alternative sites for intraosseous infusions in newborns. *Resuscitation*. 2021;163:57-63. [\[CrossRef\]](#)
- Hess T, Böhmer R, Arndt F, et al. Kasuistik - Bilateraler intraossärer Zugang am humerus bei Reanimation eines 3-jährigen [Case Report - bilateral humeral intraosseous access for CPR in a 3-years-old child]. *Anesthesiol Intensivmed Notfallmed Schmerzther*. 2016;51(7-8):468-474. [\[CrossRef\]](#)