

## Case report

## Pneumatosis intestinalis in a patient with COVID-19

Paige Aiello <sup>1</sup>, Samuel Johnson,<sup>2</sup> Abdiel Ramos Mercado,<sup>3</sup> Shakir Hussein<sup>1</sup><sup>1</sup>Department of Surgery, Wayne State University School of Medicine, Detroit, Michigan, USA<sup>2</sup>Department of Radiology, Wayne State University School of Medicine, Detroit, Michigan, USA<sup>3</sup>Department of Infectious Disease, Wayne State University School of Medicine, Detroit, Michigan, USA**Correspondence to**Dr Paige Aiello;  
paiello@med.wayne.edu

Accepted 17 August 2020

**SUMMARY**

A 73-year-old man with significant medical history including renal transplantation and chronic immunosuppression presented to the hospital with acute respiratory failure. His initial treatment included steroids for concern for *Pneumocystis jiroveci* pneumonia, although this was later excluded as the diagnosis. The patient's illness was consistent with COVID-19; however, he was not diagnosed with the virus until late in his course. The patient was found to have pneumatosis intestinalis that was successfully managed conservatively. Despite his multiple medical comorbidities, the patient had a positive outcome following COVID-19 infection. We discuss the association of pneumatosis intestinalis and COVID-19, and we investigate the various factors, including immunosuppression, that could play a role in this patient's successful recovery from the virus.

**BACKGROUND**

The COVID-19 was first reported to the WHO China Country Office as cases of pneumonia of unknown aetiology on 31 December 2019.<sup>1</sup> The first confirmed case in the USA was reported on 20 January 2020, in Washington State.<sup>2</sup> COVID-19 reportedly reached the state of Michigan on 10 March 2020 and the state became an early epicentre of the disease.<sup>3</sup>

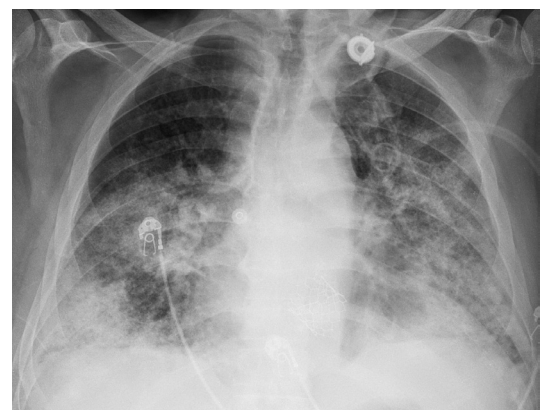
According to the Centers for Disease Control and Prevention, common symptoms of COVID-19 include fever, cough, shortness of breath, muscle aches and even loss of taste or smell. Gastrointestinal (GI) manifestations include nausea, vomiting, diarrhoea and abnormal liver function.<sup>4</sup> Other less common manifestations have included headaches, dizziness, conjunctivitis, ocular irritation and erythematous rash.<sup>5-7</sup> In this report, we present the case of a transplant patient on immunosuppressive medication infected with COVID-19 that developed pneumatosis intestinalis (PI). Although there have been reports of PI in association with COVID-19 in recent literature, it has not been a common GI manifestation of the virus.

**CASE PRESENTATION**

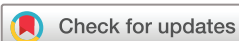A 73-year-old African-American man with a medical history of essential hypertension, diabetes mellitus, atrial fibrillation, heart failure with preserved ejection fraction, coronary artery disease, aortic stenosis status post-transcatheter aortic valve replacement (December 2019) and history of deceased donor renal transplant (2013) for end-stage renal disease originally presented to the hospital in Detroit, Michigan, on 20 January 2020, for anaemia and

heart failure exacerbation. After 2 weeks of inpatient management, the patient was discharged to an inpatient rehabilitation facility (IRF) for therapy due to decreased functional status. Although the patient's previous maintenance immunosuppression included tacrolimus, prednisone and mycophenolate mofetil, he was discharged on only tacrolimus and prednisone. Mycophenolate mofetil was stopped due to chronic anaemia, and prednisone dose was increased. On 14 February 2020, the patient was discharged home from IRF on room air with a normal physical examination.

On 15 February 2020, less than 24 hours after discharge, the patient presented to an outside hospital (OSH) for shortness of breath. At presentation, the patient was afebrile, hypertensive, tachypnoeic, clinically fluid overloaded and in atrial fibrillation with rapid ventricular response. He also had an acute kidney injury. A chest X-ray on admission demonstrated bilateral interstitial opacities, concerning for multifocal pneumonia (figure 1). His white cell count (WCC) was 16.7 k/mm<sup>3</sup>, lactic acid dehydrogenase (LDH) was 525 U/L and alanine aminotransferase (ALT) was 34 U/L. He was admitted to the intensive care unit (ICU) and intubated on hospital day 2 for acute respiratory failure. According to OSH records, the patient was treated with the provisional clinical diagnosis of *Pneumocystis jiroveci* pneumonia (PJP) because he had undergone a broncheolar lavage during his original hospital stay on 25 January 2020, which yielded negative bacterial, fungal, viral and acid-fast bacillus results, as well as negative PJP PCR, but the patient was on chronic immunosuppression, with a recent increase in steroid dosage and had findings of bilateral interstitial opacities concerning for



**Figure 1** Anteroposterior (AP) portable chest X-ray demonstrates extensive bilateral mixed alveolar and interstitial opacities in the mid to lower lungs.



© BMJ Publishing Group Limited 2020. No commercial re-use. See rights and permissions. Published by BMJ.

**To cite:** Aiello P, Johnson S, Ramos Mercado A, et al. *BMJ Case Rep* 2020;**13**:e237564. doi:10.1136/bcr-2020-237564

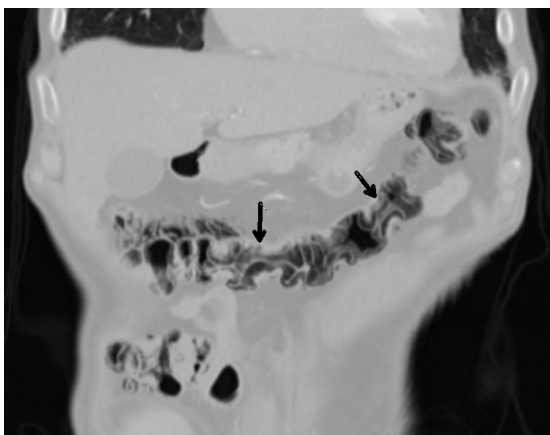
multifocal pneumonia. He was initially started on trimethoprim/sulfamethoxazole but was quickly transitioned to primaquine and clindamycin due to hyperkalaemia. He was also started on high dose prednisone with taper as part of PJP treatment protocol.

PJP PCR returned negative. The patient did not respond to volume removal. The presumptive diagnosis was changed to bacterial pneumonia, and he was started on broad spectrum antibiotics: vancomycin, azithromycin and piperacillin/tazobactam.

A transoesophageal echocardiogram performed on 18 February 2020 was negative for endocarditis and valvular dysfunction. The patient's ventilator requirements increased to fractional inspired oxygen of 100% and a positive end-expiratory pressure of 12 cm H<sub>2</sub>O. Serial chest X-rays continued to show worsening diffuse airspace opacities and bilateral infiltrates concerning for multifocal pneumonia and consistent with acute respiratory distress syndrome (ARDS). A CT scan of the chest, abdomen and pelvis was performed on 26 February 2020, which confirmed diffuse lung opacities and small pleural effusions with no intra-abdominal findings. The presumptive diagnosis remained bacterial pneumonia, although there were no positive microbiological studies, and the patient completed an extended course of antibiotics. The patient was finally extubated on 2 March 2020. The remainder of the course was uncomplicated, and he was discharged back to the IRF. On 4 March 2020, the ferritin was 966 ng/mL. To the best of our knowledge, no other inflammatory markers were obtained throughout the duration of the patient's stay at the OSH.

On arrival at the IRF, the patient was afebrile, hypertensive, had a regular heart rate and respiratory rate and was maintaining appropriate oxygen saturation on room air. The patient's presenting WCC was 12.6 k/mm<sup>3</sup>, ALT was normal at 11 U/L and ferritin was elevated at 1496 ng/mL. On day 9, LDH was 288 U/L and C reactive protein was 5.9 mg/L, both slightly elevated, and ferritin again elevated at 1558 ng/mL. The patient's functional status improved, and the patient was prepared for discharge to a subacute rehabilitation (SAR) facility. SAR facilities in the area were requiring COVID-19 testing prior to accepting patients. The patient tested positive for COVID-19 on 4 April 2020. He was treated with hydroxychloroquine 400 mg twice a day for 1 day followed by 400 mg once a day for 4 days. The patient continued to test positive through 5 May 2020 but remained free of symptoms.

On 6 May 2020, an abdominal X-ray showed a long segment of pneumatosis along the distal transverse colon and ascending



**Figure 2** Coronal CT of the upper abdomen imaged at lung window settings documents linear intramural gas within the transverse colon (arrows).

colon. A CT scan performed on 7 May 2020 confirmed the diagnosis of PI (figure 2). The patient denied abdominal pain and was tolerating diet. He was afebrile with normal vital signs, and lactic acid was within normal limits. The abdominal physical examination revealed no positive finding. The patient was managed conservatively with a course of oral metronidazole. Subsequently, the patient tested negative for COVID-19 on 11 and 12 May 2020. He was discharged home without respiratory or GI symptoms on 15 May 2020.

## INVESTIGATIONS

### Methods

COVID-19 testing at our institution was performed by nasopharyngeal swab that was collected by healthcare professionals and placed in Xpert viral transport medium and secured in double zip locked bags. Samples were hand delivered to the microbiology lab. A Cepheid SARS-CoV-2 real-time RT-PCR assay was used. This is a fully automated system where sample processing/RNA extraction and RT-PCR and detection happen in a closed system.

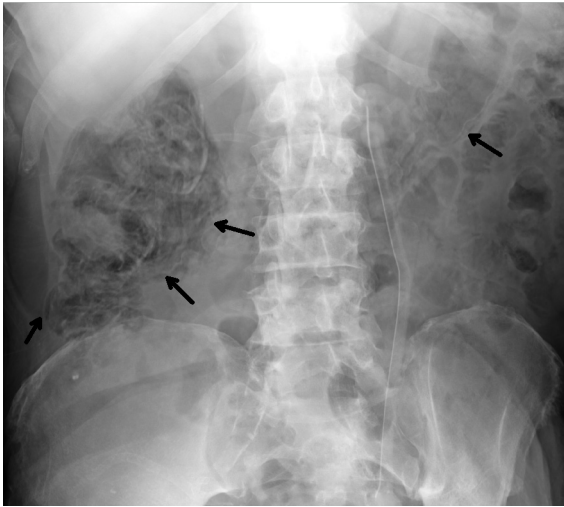
## OUTCOME AND FOLLOW-UP

The patient followed up in the transplant nephrology clinic on 8 June 2020. His review of systems was negative, and he had no new complaints. He currently remains on haemodialysis with a stable creatinine. His immunosuppression regimen includes tacrolimus (1 mg every 12 hours) and prednisone (5 mg daily), while mycophenolate mofetil is held for anaemia. He is tolerating diet and gaining weight.

## DISCUSSION

PI is the finding of gas in the bowel wall. The diagnosis is usually made using abdominal radiography or CT scan.<sup>8</sup> The exact pathophysiology of PI is not completely understood, but mucosal integrity, bacterial flora, intraluminal pressure and intraluminal gas have been reported to play a role in forming pneumocysts.<sup>9</sup> The severity of PI ranges from benign to life threatening, and treatment depends on severity. If the patient is critically ill or unstable, surgery is warranted, but if the patient is stable and asymptomatic, efforts should be made to address the underlying issue causing the finding of PI.<sup>9 10</sup> Conservative management can include antibiotics and elemental diet.<sup>11 12</sup> Indications for operation include signs of perforation, peritonitis and abdominal sepsis, as well as patients who do not respond to non-operative management.<sup>9</sup> Other indications for operation include a combination of age over 60 years, elevated WCC, elevated lactic acid and radiological finding of portal venous gas.<sup>11 13</sup>

PI is a rare but known entity in solid organ transplant patients.<sup>14 15</sup> The majority of patients experience no symptoms or vague, mild symptoms, and most cases resolve with conservative management.<sup>14</sup> There is literature that suggests a relationship between PI and use of systemic corticosteroids.<sup>15-17</sup> Although GI symptoms have been reported since the beginning of the COVID-19 outbreak, to date, there is limited literature regarding the association of PI with the COVID-19 virus.<sup>18 19</sup> Diarrhoea, nausea and vomiting are commonly reported GI symptoms associated with COVID-19.<sup>20-22</sup> The virus has been detected in the faeces of patients with and without GI symptoms and has actually been shown to shed for a longer period of time in the faeces than in the respiratory tract.<sup>21-23</sup> The virus host receptor, ACE2, is expressed in absorptive enterocytes of the GI tract, and viral RNA has been detected in tissue from throughout the GI tract.<sup>22 24 25</sup>



**Figure 3** Cropped X-ray of the upper abdomen with multilamellated collections of intramural gas within the transverse and ascending colon (arrows), representing pneumatosis intestinalis.

The CT scan for this patient obtained on 26 February 2020 was reviewed with the radiology department, and it had no evidence of PI. Two abdominal X-rays done for nausea and diarrhoea at IRF prior to 6 May 2020 were reviewed with the radiology department and, in fact, they had evidence of PI that was not reported on the original read (figure 3). Therefore, it is likely that the PI developed some time during the end of the stay at the OSH or while at rehabilitation, coinciding with the patient's COVID-19 clinical course. This patient had multiple risk factors for PI. As a patient with a solid organ transplant and a patient on systemic steroids, he was at increased risk for PI.<sup>14–17</sup> The patient was on many antibiotics during ICU admission, which could have disrupted the microbiota of the gut, and disrupted bacterial flora is reported to play a role in the development of PI.<sup>9</sup> As stated above, the COVID-19 virus can invade the cells of the GI tract, potentially causing damage to the bowel wall integrity. Additionally, the COVID-19 viral DNA has been detected for a longer duration of time in the faeces of patients taking glucocorticoids compared with patients not taking glucocorticoids, so the steroids likely increased the duration of time the virus was present in the patient's GI tract and faeces, potentially further increasing his risk for PI.<sup>26</sup> To date, there is no literature reporting a causative relationship between COVID-19 and PI, but this case adds to the literature reporting an association between COVID-19 and PI.<sup>18 19</sup> The finding of PI in this patient was successfully managed conservatively with antibiotics.

We believe that there is substantial evidence to suggest that the patient's presentation to the OSH was due to COVID-19. The chest X-ray on admission to the OSH as well as serial chest X-rays and a CT scan from the OSH demonstrated bilateral airspace opacities consistent with multifocal pneumonia and were compatible with COVID-19 presentation.<sup>27</sup> The patient required high ventilator settings consistent with severe ARDS, which is a known complication of COVID-19. In addition, extensive culture, antigen and PCR testing was negative, which suggests an unusual causative agent for the patient's severe pulmonary condition. Furthermore, there is a recent report of a patient on maintenance immunosuppression that had viral shedding of COVID-19 for 65 days, which supports our assumption that the patient had contracted COVID-19 prior to admission to the OSH.<sup>28</sup> If our hypothesis is true, this case occurred before

### Learning points

- ▶ Pneumatosis intestinalis is a finding that can represent a large spectrum of disease.
- ▶ Pneumatosis intestinalis has been associated with the COVID-19 virus.
- ▶ Treatment of pneumatosis intestinalis depends on the severity of disease.
- ▶ Immunosuppressive and immunomodulatory medications could provide benefit in the treatment of COVID-19.

the first recorded case in Michigan. This implication is feasible as there was very limited knowledge and testing available at the beginning of the pandemic.

The patient had a hospital stay in late January and early February prior to presenting to the OSH where he could have been exposed to COVID-19. During that stay, he had exposure to many healthcare workers and other hospitalised patients, including time spent in shared physical therapy areas. The patient received several visits from immediate family members who were regularly visiting another family member at a nursing home during the same time period. There were no reports of healthcare workers or patients testing positive for COVID-19 during the patient's first stay at IRF. This leads us to believe that the patient most likely acquired the disease from an asymptomatic carrier who was either a healthcare employee, a patient or a hospital visitor. This is consistent with the early phase of the pandemic in which the disease was rapidly spread by asymptomatic carriers.<sup>29</sup>

Early studies demonstrate the mortality rate from COVID-19 to be around 30% of hospitalised patients. Strikingly, the mortality rate can reach 97% in patients that require mechanical ventilation, especially in those over 65 years old.<sup>30 31</sup> Advanced age, hypertension and male gender have been associated with higher mortality.<sup>31 32</sup> Kidney transplant impact on survivability of COVID-19 has mixed reviews in literature, with some publications reporting higher mortality.<sup>33–35</sup> Based on these factors, the patient in this report was extremely unlikely to survive. We briefly discuss a few theories that could serve as an explanation for his survival.

First, although there is insufficient literature investigating immunosuppressive treatment in COVID-19, immunosuppression and immunomodulatory drugs have been considered to reduce the cytokine storm and hyperinflammation associated with COVID-19 and could decrease risk of mortality.<sup>36 37</sup> Another theory that could explain the successful recovery of this patient involves the care that the patient received in the ICU. The patient was receiving care before COVID-19 was considered to have reached the state where he resided. The healthcare workers caring for him did not have first-hand experience with the pandemic at the time. Healthcare workers caring for patients with highly contagious and potentially fatal diseases are known to experience fear and anxiety.<sup>38 39</sup> This psychological burden can decrease confidence of healthcare workers and the healthcare delivery system and act as a barrier to appropriate care.<sup>38 39</sup> This patient was not exposed to healthcare workers in the ICU overburdened by the COVID-19 pandemic as the virus had not yet been reported in his state, and he therefore received routine, unbiased, healthcare.

**Contributors** PA and SH were involved in the conception and design of this case report. All authors contributed to acquisition of data, writing of the article and

editing the paper. SH and ARM were involved in the care of the patient. All authors agree on the final version.

**Funding** The authors have not declared a specific grant for this research from any funding agency in the public, commercial or not-for-profit sectors.

**Competing interests** None declared.

**Patient consent for publication** Obtained.

**Provenance and peer review** Not commissioned; externally peer reviewed.

This article is made freely available for use in accordance with BMJ's website terms and conditions for the duration of the covid-19 pandemic or until otherwise determined by BMJ. You may use, download and print the article for any lawful, non-commercial purpose (including text and data mining) provided that all copyright notices and trade marks are retained.

### ORCID iD

Paige Aiello <http://orcid.org/0000-0001-5998-2668>

### REFERENCES

- World Health Organization. Pneumonia of unknown cause – China, 2020. Available: <https://www.who.int/csr/don/05-january-2020-pneumonia-of-unknown-cause-china/en/>
- Holshue ML, DeBolt C, Lindquist S, et al. First case of 2019 novel coronavirus in the United States. *N Engl J Med* 2020;382:929–36.
- Michigan coronavirus timeline: key dates, COVID-19 case tracking, state orders, 2020. Available: <https://www.clickondetroit.com/health/2020/03/24/michigan-coronavirus-timeline-key-dates-covid-19-case-tracking-state-orders/>
- Patel KP, Patel PA, Vunnam RR, et al. Gastrointestinal, hepatobiliary, and pancreatic manifestations of COVID-19. *J Clin Virol* 2020;128:128.
- Asadi-Pooya AA, Simani L. Central nervous system manifestations of COVID-19: a systematic review. *J Neurol Sci* 2020;413:413.
- Hu K, Patel J, Patel BC. Ophthalmic manifestations of coronavirus (COVID-19). *StatPearls* 2020.
- Recalcati S. Cutaneous manifestations in COVID-19: a first perspective. *J Eur Acad Dermatol Venereol* 2020;34:e212–3.
- Ho LM, Paulson EK, Thompson WM. Pneumatosis intestinalis in the adult: benign to life-threatening causes. *AJR Am J Roentgenol* 2007;188:1604–13.
- St Peter SD, Abbas MA, Kelly KA. The spectrum of pneumatosis intestinalis. *Arch Surg* 2003;138:68–75.
- Blair HA, Baker R, Albazaz R. Pneumatosis intestinalis an increasingly common radiological finding, benign or life-threatening? A case series. *BMJ Case Rep* 2015;2015:bcr2014207234.
- Tahiri M, Levy J, Alzaid S, et al. An approach to Pneumatosis intestinalis: factors affecting your management. *Int J Surg Case Rep* 2015;6:133–7.
- Johnston BT, McFarland RJ. Elemental diet in the treatment of pneumatosis coli. *Scand J Gastroenterol* 1995;30:1224–7.
- Greenstein AJ, Nguyen SQ, Berlin A, et al. Pneumatosis intestinalis in adults: management, surgical indications, and risk factors for mortality. *J Gastrointest Surg* 2007;11:1268–74.
- Gemma V, Mistrot D, Row D, et al. Pneumatosis intestinalis in solid organ transplant recipients. *J Thorac Dis* 2018;10:1984–97.
- Pear BL. Pneumatosis intestinalis: a review. *Radiology* 1998;207:13–19.
- Ezuka A, Kawana K, Nagase H, et al. Improvement of pneumatosis cystoides intestinalis after steroid tapering in a patient with bronchial asthma: a case report. *J Med Case Rep* 2013;7:1–4.
- Choi JY, Cho SB, Kim HH, et al. Pneumatosis intestinalis complicated by pneumoperitoneum in a patient with asthma. *Tuberc Respir Dis* 2014;77:219–20.
- Bhayana R, Som A, Li MD, et al. Abdominal imaging findings in COVID-19: preliminary observations. *Radiology* 2020:201908.
- Meini S, Zini C, Passaleva MT, et al. Pneumatosis intestinalis in COVID-19. *BMJ Open Gastroenterol* 2020;7:e000434.
- Jin X, Lian J-S, Hu J-H, et al. Epidemiological, clinical and virological characteristics of 74 cases of coronavirus-infected disease 2019 (COVID-19) with gastrointestinal symptoms. *Gut* 2020;69:1002–9.
- Wu Y, Guo C, Tang L, et al. Prolonged presence of SARS-CoV-2 viral RNA in faecal samples. *Lancet Gastroenterol Hepatol* 2020;5:434–5.
- Lin L, Jiang X, Zhang Z, et al. Gastrointestinal symptoms of 95 cases with SARS-CoV-2 infection. *Gut* 2020;69:997–1001.
- Cheung KS, Hung IFN, Chan PPY, et al. Gastrointestinal manifestations of SARS-CoV-2 infection and virus load in fecal samples from a Hong Kong cohort: systematic review and meta-analysis. *Gastroenterology* 2020;159:81–95.
- Wan Y, Shang J, Graham R, et al. Receptor recognition by the novel coronavirus from Wuhan: an analysis based on decade-long structural studies of SARS coronavirus. *J Virol* 2020;94:e00127–20.
- Zhang H, Kang Z, Gong H, et al. Digestive system is a potential route of COVID-19: an analysis of single-cell coexpression pattern of key proteins in viral entry process. *Gut* 2020;69:1010–8.
- Ling Y, Xu S-B, Lin Y-X, et al. Persistence and clearance of viral RNA in 2019 novel coronavirus disease rehabilitation patients. *Chin Med J* 2020;133:1039–43.
- Shi H, Han X, Jiang N, et al. Radiological findings from 81 patients with COVID-19 pneumonia in Wuhan, China: a descriptive study. *Lancet Infect Dis* 2020;20:425–34.
- Zhang M, Zhang J, Shi H, et al. Viral shedding prolongation in a kidney transplant patient with COVID-19 pneumonia. *Am J Transplant* 2020.
- He X, Lau EHY, Wu P, et al. Temporal dynamics in viral shedding and transmissibility of COVID-19. *Nat Med* 2020;26:672–5.
- Zhou F, Yu T, Du R, et al. Clinical course and risk factors for mortality of adult inpatients with COVID-19 in Wuhan, China: a retrospective cohort study. *Lancet* 2020;395:1054–62.
- Richardson S, Hirsch JS, Narasimhan M, et al. Presenting characteristics, comorbidities, and outcomes among 5700 patients hospitalized with COVID-19 in the new York City area. *JAMA* 2020;323:2052–9.
- Grasselli G, Zangrillo A, Zanella A, et al. Baseline characteristics and outcomes of 1591 patients infected with SARS-CoV-2 admitted to ICUs of the Lombardy region, Italy. *JAMA* 2020;323:1574–81.
- Akalin E, Azzi Y, Bartash R, et al. Covid-19 and kidney transplantation. *N Engl J Med* 2020:NEJMc2011117.
- Gandolfini I, Delsante M, Fiaccordi E, et al. COVID-19 in kidney transplant recipients. *Am J Transplant* 2020.
- Periera M, Mohan S, Cohen DJ, et al. COVID-19 in solid organ transplant recipients: initial report from the US EpiCenter. *Am J Transplant* 2020.
- Mehta P, McAuley DF, Brown M, et al. COVID-19: consider cytokine storm syndromes and immunosuppression. *Lancet* 2020;395:1033–4.
- Wu C, Chen X, Cai Y, et al. Risk factors associated with acute respiratory distress syndrome and death in patients with coronavirus disease 2019 pneumonia in Wuhan, China. *JAMA Intern Med* 2020. doi:10.1001/jamainternmed.2020.0994. [Epub ahead of print: 13 Mar 2020].
- Xiang Y-T, Yang Y, Li W, et al. Timely mental health care for the 2019 novel coronavirus outbreak is urgently needed. *Lancet Psychiatry* 2020;7:228–9.
- Shanafelt T, Ripp J, Trockel M. Understanding and addressing sources of anxiety among health care professionals during the COVID-19 pandemic. *JAMA* 2020. doi:10.1001/jama.2020.5893. [Epub ahead of print: 07 Apr 2020].

Copyright 2020 BMJ Publishing Group. All rights reserved. For permission to reuse any of this content visit <https://www.bmj.com/company/products-services/rights-and-licensing/permissions/>  
BMJ Case Report Fellows may re-use this article for personal use and teaching without any further permission.

Become a Fellow of BMJ Case Reports today and you can:

- ▶ Submit as many cases as you like
- ▶ Enjoy fast sympathetic peer review and rapid publication of accepted articles
- ▶ Access all the published articles
- ▶ Re-use any of the published material for personal use and teaching without further permission

### Customer Service

If you have any further queries about your subscription, please contact our customer services team on +44 (0) 207111 1105 or via email at [support@bmj.com](mailto:support@bmj.com).

Visit [casereports.bmj.com](http://casereports.bmj.com) for more articles like this and to become a Fellow