

CASE REPORT

## Noninvasive intracranial pressure real-time waveform analysis monitor during prostatectomy robotic surgery and Trendelenburg position: case report



Gabriela Tognini Saba <sup>id a,\*</sup>, Vinicius Caldeira Quintão <sup>id a</sup>,  
Suely Pereira Zeferino <sup>id b</sup>, Claudia Marquez Simões <sup>id c</sup>,  
Rafael Ferreira Coelho <sup>id c</sup>, Arnaldo Fazoli <sup>id c</sup>, William Nahas <sup>id d</sup>,  
Gustavo Henrique Frigieri Vilela <sup>id e</sup>, Maria José Carvalho Carmona <sup>id a,f</sup>

<sup>a</sup> Universidade de São Paulo, Faculdade de Medicina, Hospital das Clínicas, Instituto Central, São Paulo, SP, Brazil

<sup>b</sup> Universidade de São Paulo, Faculdade de Medicina, Hospital das Clínicas, Instituto do Coração, São Paulo, SP, Brazil

<sup>c</sup> Universidade de São Paulo, Faculdade de Medicina, Hospital das Clínicas, Instituto do Câncer do Estado de São Paulo, São Paulo, SP, Brazil

<sup>d</sup> Universidade de São Paulo, Faculdade de Medicina, Disciplina de Urologia, São Paulo, SP, Brazil

<sup>e</sup> Brain4care Scientific Department, São Paulo, SP, Brazil

<sup>f</sup> Universidade de São Paulo, Faculdade de Medicina, Disciplina de Anestesiologia, São Paulo, SP, Brazil

Received 16 July 2021; accepted 5 September 2021

Available online 1 October 2021

### KEYWORDS

Head-down tilt;  
Intracranial pressure;  
Robotic surgical  
procedures

**Abstract** Both robotic surgery and head-down tilt increase intracranial pressure by impairing venous blood outflow. Prostatectomy is commonly performed in elderly patients, who are more likely to develop postoperative cognitive disorders. Therefore, increased intracranial pressure could play an essential role in cognitive decline after surgery. We describe a case of a 69-year-old male who underwent a robotic prostatectomy. Noninvasive Brain4care™ intraoperative monitoring showed normal intracranial compliance during anesthesia induction, but it rapidly decreased after head-down tilt despite normal vital signs, low lung pressure, and adequate anesthesia depth. We conclude that there is a need for intraoperative intracranial compliance monitoring since there are major changes in cerebral compliance during surgery, which could potentially allow early identification and treatment of impaired cerebral complacency.

© 2021 Sociedade Brasileira de Anestesiologia. Published by Elsevier Editora Ltda. This is an open access article under the CC BY-NC-ND license (<http://creativecommons.org/licenses/by-nc-nd/4.0/>).

\* Corresponding author.

E-mail: [gabriela.saba@hc.fm.usp.br](mailto:gabriela.saba@hc.fm.usp.br) (G.T. Saba).

## Introduction

Intracranial pressure (ICP) can be accurately measured by insertion of intraventricular, intraparenchymal, or subarachnoid catheter by neurosurgeons, typically used after intracranial tumor surgery or severe traumatic brain injuries. Other noninvasive measurement devices allow inferences to be made but are not very accurate, such as optic nerve sheath diameter measurement, tomography, doppler ultrasound, magnetic resonance imaging, and may instead be unavailable in the operation room or lead to imprecise treatment.<sup>1</sup>

Increased venous pressure in the cavernous sinus is transmitted to the episcleral veins by the superior ophthalmic vein. It results in an increase in intraocular pressure (IOP), which can be measured by handheld tonometer as a non-invasive intracranial pressure monitor, but yet operator dependent and not quite readily available in the operation room context.<sup>2</sup> A prospective study measuring IOP with a tonometer showed no significant relationship with ICP measurement, concluding that noninvasive IOP does not predicts ICP.<sup>3</sup>

In this sense, Brain4care™ monitor (Fig. 1A) is innovative, once it delivers accurate monitoring of intracranial compliance through mathematical analysis of intracranial pressure pulse morphology, without the need for an invasive catheter. This monitor relies on minor volume variations of the skull, measured by a strain gauge positioned over the skin of temporal bone, to analyze intracranial pressure waves and determine whether brain complacency is preserved or not.<sup>4,5</sup>

It is known that Trendelenburg positioning and pneumoperitoneum cause reduction in the blood outflow from

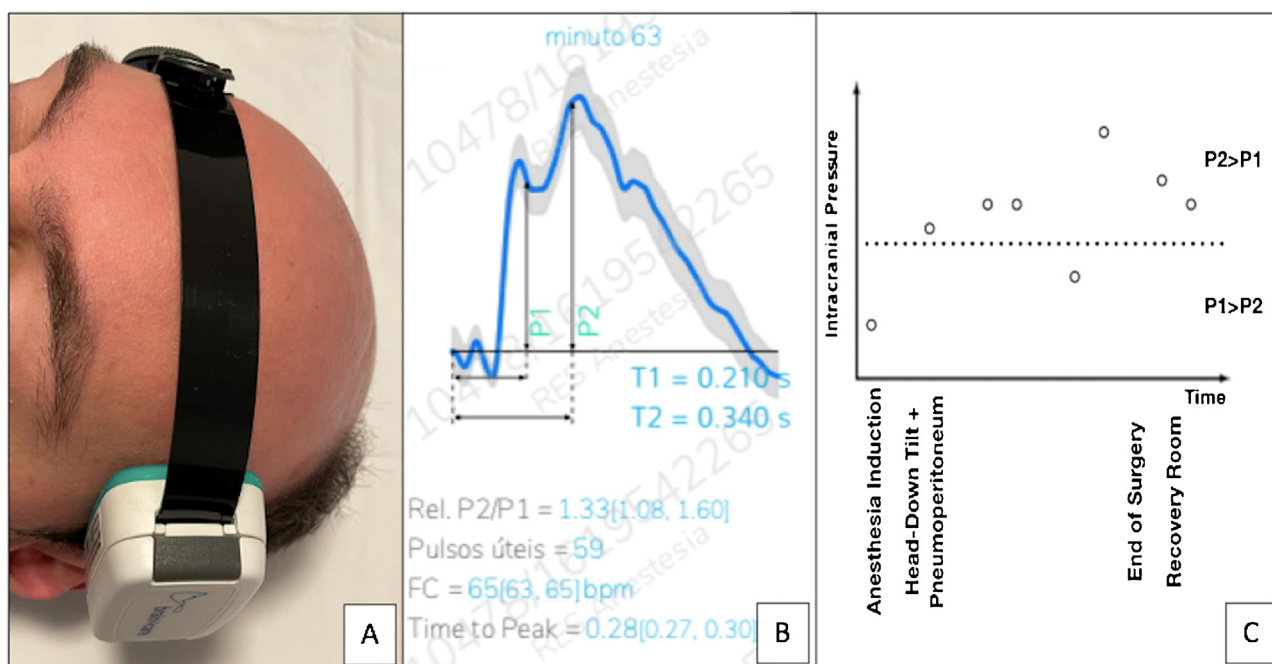
the skull, therefore leading to cerebral congestion. It may cause elevations on ICP.<sup>6</sup> On the other hand, multiple factors influence intracranial pressure during anesthesia, such as alveolar pressure (which impairs venous return), excessive use of anesthetics (which diminish cerebral metabolic rate for oxygen and blood flow), hypotension (which may mask increased ICP), elevated end-tidal carbon dioxide (which causes cerebral arterial vasodilatation), hypothermia (which reduces cerebral metabolism and blood flow), and hypervolemia (which may lead to increases in cerebral blood flow). Thus, we described the use of Brain4care™ during robotic prostatectomy surgery and recorded possibly confounding factors to isolate possible causes for ICP elevation.

## Case report

Written informed consent was obtained from the patient. A 69-year-old male presented at our university hospital for robotic radical prostatectomy due to a locally invasive tumor. He was a smoker for 25 years and had mild pulmonary emphysema previously diagnosed, treated with inhaled formoterol.

The preoperative cognitive assessment revealed a Mini-Mental State Examination of 26 points (a thirty-point questionnaire to measure cognitive impairment in which scores of 24 or more indicates normal cognition) and a Montreal Cognitive Assessment (a thirty-point test for the same purpose in which scores of 26 or over are considered normal) of 25 points. He had no other comorbidities or had any surgical treatment, and was classified as the American Society of Anesthesiologists (ASA) physical status II.

The patient was admitted to the operating room, identified, and monitored by the anesthesiologist with non-



**Figure 1** Brain4care™ monitor in place (A); Brain4care™ data showing ICP waveform inversion on P2/P1 ratio as soon as the final position was guaranteed (B); Intraoperative intracranial pressure measurement results by Brain4care™ software analysis, showing either preserved brain compliance P1 > P2 or non-preserved brain compliance P2 > P1 (C).

**Table 1** Intraoperative monitoring results.

	BIS	Suppression rate	NI-ICP	ONSD	MAP	PEEP	Peak pressure	EtCO <sub>2</sub>	Intra-abdominal pressure	Head-down tilt degree
Admitted to OR	98	0	p1 > p2	3,2	98	0	0	0	0	0
Subarachnoid anesthesia	42	55	p1 > p2	3,93	60	6	22	37	10	0
General anesthesia induction	39	20	p2 > p1	4,64	80	6	27	38	8	0
Head-down tilt	41	0	p2 > p1	4,9	75	6	24	36	15	30
Pneumoperitoneum	45	0	p2 > p1	4,0	80	6	24	37	14	30
1h intraoperative	43	0	p2 > p1	4,4	85	6	23	38	12	30
2h intraoperative	48	0	p1 > p2	4,16	82	6	24	40	12	30
3h intraoperative	44	0	p2 > p1	4,2	78	6	24	45	11	30
Return to supine	49	0	p2 > p1	5,87	80	6	21	48	0	0
Extubation	96	0	p2 > p1	2,89	82	6	18	42	0	0

OR, operating room; BIS, bispectral index; NI-ICP, noninvasive intracranial pressure; ONSD, optic nerve sheath diameter (millimeters), MAP, mean arterial pressure (mmHg) PEEP, positive end-expiratory pressure (mmHg); EtCO<sub>2</sub> End-tidal CO<sub>2</sub> (mmHg)

invasive arterial pressure, heart rate, pulse oximeter, skin temperature, Brain4care™ monitor, and Bispectral Index (Medtronic software version 3.50). Subarachnoid anesthesia single puncture was performed under aseptic technique with low-dose bupivacaine and opioids. The patient was induced to general anesthesia and maintained with a target-controlled infusion of propofol and small boluses of sufentanil. After that, the patient was positioned on a 30-degree Trendelenburg lithotomy, and pneumoperitoneum was readily performed. Overall, 500 mL of ringer lactate were infused, and the temperature was kept between 36 and 36,5 °C with the use of a forced-air heating device. Positive end-expiratory pressure varied from 5 to 6 mmHg, and pulmonary inspiratory peak pressure did not exceed 28 mmHg. The surgeon set intra-abdominal pressure at 12 mmHg (9–15 mmHg), and Bispectral Index values were registered between 39 and 49 (Table 1). Optic Nerve Sheath Diameter (ONSD), measured by ocular ultrasound, increased from 2,9 to 4,9 mm from the beginning to the end of surgery. ICP waveform had inversion on P2/P1 ratio as soon as the final position was guaranteed (Fig. 1B and 1C).

At the end of the procedure, which took 3 hours, the patient was awakened and extubated, arriving fully awake at the PACU. As it was an observational case report, no interventions to routine management of these patients were made. No adverse events were reported as well. The patient did not report any discomfort with the monitoring devices. The patient was followed up during hospitalization, which lasted 2 days, and postoperative cognitive tests were performed on the first day after surgery with Mini-Mental State Examination of 24 points and Montreal Cognitive Assessment of 24 points. No adverse effects were observed postoperatively, nor the patient had any surgical complications.

## Discussion

Brain4care™ noninvasive intracranial pressure monitor consists of a strain gauge mechanical extensometer fixed on an automatic device that touches the scalp and detects small skull deformations resulting from changes in ICP. Although this method is currently limited once it does not yet yield pressure values in mercury millimeters, it can deliver con-

tinuous information about the ICP waveform immediately processed in the software and delivered back to the user.

Therefore, this technique can provide a relatively accurate analysis of intracranial complacency by analyzing the ICP curves. The ICP waveform typically comprises three peaks: P1, related to systolic blood pressure transferred by the choroid plexus to the cerebrospinal fluid; P2, which reflects the systolic wave parenchymal tissue; and P3, which is related to the closure of the aortic valve. The analysis of the relative amplitude of peaks of P1 and P2 directly relates to intracranial compliance, once P2 peaks greater than P1 suggests impaired intracranial compliance.

In this case, by analyzing the ICP curve, it was clear that as soon as the patient was positioned and pneumoperitoneum was made, it impaired intracranial complacency, and it was not seen on ONSD ultrasound measurements. Although ONSD measures are highly operator-dependent, it is quite simple to be made and requires little training. ONSD showed a minor increase at the end of the surgery but was still under normal range values. In addition, this patient had mild pulmonary emphysema previously diagnosed, which did not translate into higher pulmonary pressure, but could hinder generalization.

Studies with more participants need to be carried out to ascertain the real importance of this transient increase in ICP in clinical outcomes. However, the use of these devices is probably of extreme benefit to the anesthesiologist. It does not provide any damage to the patient, is easy to use and handle, has real-time analysis software, and is much more accurate than the other alternatives at the bedside. Further research should include the use of cerebral oximetry to evaluate the effect of these interventions on the balance between the supply of oxygen to the brain and its consumption by analyzing cerebral tissue perfusion.

## Conclusion

We conclude that there is a need for intraoperative intracranial pressure monitoring since there are major changes in cerebral compliance during surgery. And it also explores the

potential of this new technology for noninvasive intraoperative intracranial compliance monitoring.

## Funding

This work was funded by the Centro de Estudos de Anestesiologia e Reanimação (CEDAR), Disciplina de Anestesiologia, Faculdade de Medicina, Universidade de São Paulo.

## Conflicts of interest

The authors declare no conflicts of interest.

## References

1. Vilela GH, Cabella B, Mascarenhas S, et al. Validation of a New Minimally Invasive Intracranial Pressure Monitoring Method by Direct Comparison with an Invasive Technique. *Acta Neurochir Suppl.* 2016;122:97–100.
2. Lashutka MK, Chandra A, Murray HN, et al. The relationship of intraocular pressure to intracranial pressure. *Ann Emerg Med.* 2004;43:585–91. Erratum in: *Ann Emerg Med.* 2004;44:561.
3. Kirk T, Jones K, Miller S, et al. Measurement of intraocular and intracranial pressure: is there a relationship? *Ann Neurol.* 2011;70:323–6.
4. Mascarenhas S, Vilela GH, Carlotti C, et al. The new ICP minimally invasive method shows that the Monro-Kellie doctrine is not valid. *Acta Neurochir Suppl.* 2012;114:117–20.
5. Frigieri G, Andrade RAP, Dias C, et al. Analysis of a Non-invasive Intracranial Pressure Monitoring Method in Patients with Traumatic Brain Injury. *Acta Neurochir Suppl.* 2018;126:107–10.
6. Rosenthal RJ, Hiatt JR, Phillips EH, et al. Intracranial pressure. Effects of pneumoperitoneum in a large-animal model. *Surg Endosc.* 1997;11:376–80.