

CASE REPORT

Prosthodontic management of a patient with mandibular asymmetry: a case report

Nicola Holland*  & Gerald McKenna 

School of Dentistry, Royal Victoria Hospital, 274 Grosvenor Road, Belfast BT12 6BA, UK

Correspondence

Gerald McKenna, Centre for Public Health, Institute of Clinical Sciences, Block B, Royal Victoria Hospital, Queens University Belfast, Belfast BT12 6BA, UK. Tel: 028 9097 6311; Fax: 02890235900; E-mail: g.mckenna@qub.ac.uk

Present address

*Aberdeen Dental Hospital and Institute, Cornhill Road, Aberdeen, UK

Funding Information

No sources of funding were declared for this study.

Received: 30 November 2017; Revised: 5 March 2018; Accepted: 9 March 2018

Clinical Case Reports 2018; 6(7): 1258–1263

doi: 10.1002/ccr3.1558

A small degree of facial and dental asymmetry is a common finding and is normal in the facial dynamics of the population. However, in some cases, facial asymmetries can be more obvious and can lead to functional and esthetic concerns. Management of these patients can be very challenging.

Case History/Examination

A 62-year-old gentleman presented to the Prosthodontic department, in the Centre for Dentistry, Queens University Belfast, following referral by his General Dental Practitioner. His presenting complaint was that he was unable to wear his existing complete removable dentures and found it almost impossible to eat with them in situ.

The patient had previously worn an upper complete denture and lower removable partial denture. The lower denture had been retained with numerous postretained telescopic crowns; however, these abutment teeth were extracted a number of years previously due to periodontal involvement. The patient had then been provided

Key Clinical Message

This case report outlines a conservative treatment approach utilized in the management of a patient with a transverse left-sided mandibular asymmetry, in an attempt to obtain a functional and esthetic occlusion using removable intraoral prostheses. A positive final result was achieved by maintaining close communication with the on-site dental technician.

Keywords

Asymmetry, dental, mandibular, prosthodontic.

with complete upper and lower removable prostheses but these had been replaced previously on two occasions due to difficulties with retention and occlusion. He reported no history of maxillofacial trauma or radiation therapy.

Medically, the patient suffered from high cholesterol, Crohn's disease, arthritis, and benign prostate hypertrophy. His regular medications included simvastatin, mesalazine, omeprazole, pregabalin, tramadol, adalimumab, alverine citrate, alfuzosin hydrochloride, and fentanyl. He also reported a history of depressive illness, controlled with sertraline. He was allergic to penicillin.

On extraoral examination, the patient had a class III skeletal relationship and left-sided transverse asymmetry of the mandible. Asymmetry can affect any of the three planes of space; however, it is most easily assessed in the frontal view [1]. This patient's asymmetry was classified as T1 M3 L3 on the TML classification. There was menton deviation without maxillary or lip cant and deviation of the menton was in the same transverse direction as the soft tissue asymmetry (Table 1) [2].

There were no adverse findings associated with the patient's lymph nodes or muscles of mastication on palpation.

Intraorally, the soft tissues appeared healthy with no evidence of pathology. The class III upper alveolar ridge was well rounded, firm and showed minimal signs of alveolar bone resorption with adequate height and width.

Table 1. A simple classification of facial asymmetry by TML system. [2]

Classification	Description
Transverse asymmetry (T)	T1: Equal direction of menton deviation and transverse soft tissue asymmetry
	T2: Opposite direction of menton deviation and transverse soft tissue asymmetry
	T3: The absence of transverse asymmetry despite the presence of menton deviation
	T4: The presence of transverse asymmetry without menton deviation
Maxillary cant (M)	M0: Neither maxillary cant nor menton deviation
	M1: The presence of menton deviation and maxillary cant with mental deviation and downward maxillary cant in opposite directions
	M2: The presence of menton deviation and maxillary cant with equal direction of mental deviation and downward maxillary cant
	M3: The presence of menton deviation without maxillary cant
Lip cant (L)	M4: The presence of maxillary cant without menton deviation
	L0: Neither lip canting nor soft tissue menton deviation
	L1: The presence of soft tissue menton deviation and lip cant with mental deviation and downward maxillary cant in opposite directions
	L2: The presence of soft tissue menton deviation and lip cant with equal direction of mental deviation and downward of maxillary cant
	L3: The presence of soft tissue menton deviation without lip canting
	L4: The presence of lip canting without soft tissue menton deviation

The class II lower alveolar ridge was moderately resorbed with recent healing extraction sockets present [3].

Investigations

The orthopantomogram (Fig. 1) illustrated that the left mandibular condyle and ramus were shortened and slightly widened. The increased diameter of the neural canal reflected generalized remodeling. There was no radiographic evidence of previous trauma and no obvious mandibular fractures present.

In this case, the investigation into the cause for mandibular asymmetry was inconclusive and no underlying cause was determined. It is likely that the deviation was the result of developmental abnormalities (Table 2) [8, 9].

Differential Diagnosis

- Edentate upper class III alveolar ridge, lower class II alveolar ridge.
- Class III skeletal discrepancy and unilateral left-sided transverse mandibular asymmetry.

Treatment

Treatment options were discussed with the patient which included conventional prosthodontic rehabilitation and possible orthognathic surgery. Orthognathic surgery is often used to create a symmetrical facial midline, ideal facial profile, and optimal dental occlusion. Both options were described to the patient and the benefits and risks discussed. The patient decided the conservative prosthodontic option would be most appropriate for him in this case based on the information provided on the clinic.

Treatment plan:

- Upper and lower complete denture construction.
- Review and maintenance.

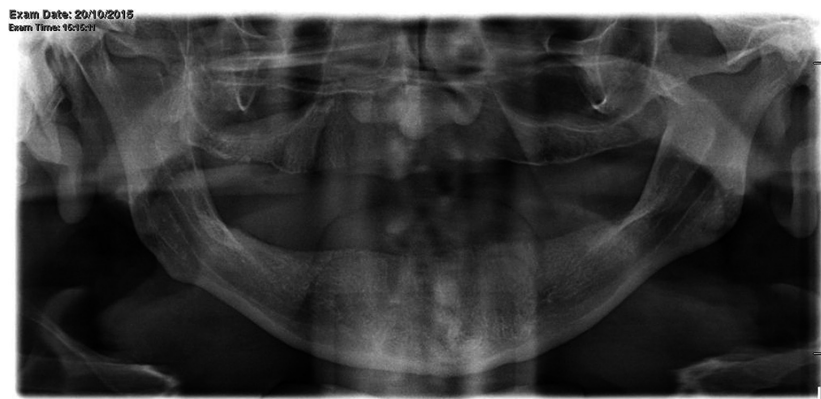


Figure 1. Full orthopantomogram.

Table 2. Potential causes of mandibular asymmetries. [8, 9]

Classification	Example	Description
Developmental	Hemimandibular elongation	<ul style="list-style-type: none"> • Unknown etiology • Affects the mandible unilaterally • Presents as transverse displacement of the chin point to contralateral side which presents in early adulthood • No vertical asymmetry • The contralateral mandibular molars deviate lingually in attempt to remain in occlusion • Cross-bite may develop on the unaffected side • Radiographic elongation of the condyle or body of mandible on the affected side
	Hemimandibular hyperplasia	<ul style="list-style-type: none"> • Horizontal and vertical enlargement on one side of the mandible which involves the condyle, ramus, and body of the mandible • The condition usually begins in puberty • The maxillary dentition on the affected side will overerupt to compensate for the excessive vertical mandibular growth, which results in a characteristic transverse cant of the maxillary occlusal plane • If the vertical growth is rapid, then dental eruption may not keep pace and a lateral open bite will occur on the affected side • Radiographic elongation of ramus and condylar enlargement can be seen. The lower border of mandible on the affected side is lower than the unaffected side. There is usually increased distance between molar roots and inferior alveolar canal on the affected side. The unaffected side will have normal height
	Hemifacial microsomia	<ul style="list-style-type: none"> • Deficiency of hard and soft tissues on one side of the face during embryonic development (congenital disorder) • Chin point displacement is to the affected side • Hypodontia is commonly noted in these patients
	Hemifacial hypertrophy	<ul style="list-style-type: none"> • Asymmetry affects the craniofacial soft and hard tissues • Intrauterine pressure can lead to shortening of the sternocleidomastoid muscle leading to mandibular asymmetries • Likely genetic contribution
	Hemifacial atrophy (Parry-Romberg syndrome)	<ul style="list-style-type: none"> • Uncertain etiology • Atrophy of hard and soft tissues on one side of the face leading to mandibular asymmetry • May be accompanied by hyperpigmentation of the skin, seizures, and facial pain
Pathological	Tumors	<ul style="list-style-type: none"> • For example, benign ameloblastoma • Condylar head tumors cause deviation of the mandible to the unaffected side with unilateral condylar enlargement radiographically
	Cysts	<ul style="list-style-type: none"> • Dentigerous cysts • Keratocysts
	Infection	<ul style="list-style-type: none"> • Dentoalveolar abscess • Sialadenitis
	Condylar resorption	<ul style="list-style-type: none"> • May be secondary to juvenile rheumatoid arthritis, steroid therapy, or orthognathic surgery • Unilateral resorption can lead to mandibular asymmetry
Traumatic	Condylar Fractures	<ul style="list-style-type: none"> • Trauma to condylar region during childhood can lead to arrest in growth • Chin point asymmetry toward affected side
Functional	Mandibular Displacements	<ul style="list-style-type: none"> • Maxillary narrowing can lead to occlusal interferences leading to lateral displacement of the mandible

The patient was seen again in the clinic to start treatment and upper and lower impressions were taken in nonelastic compound material in edentulous perforated stock trays for provision of special trays.

Special trays were constructed using polymethyl methacrylate. The trays were spaced and perforated to allow for impressions in addition reaction silicone (polyvinyl siloxane impression material type 2, medium

viscosity). These special trays were then border molded with green stick used to take master impressions. Care was taken to ensure that the full width and depth of the buccal and lingual sulcus was recorded in the master impressions, along with extension to the hamular notch in the upper arch and retromolar pad in the lower arch. These were poured in the laboratory to be used as master models for construction of registration rims. The master models are shown in Figures 2 and 3.

Jaw registration proved to be very challenging in this case and close liaison and communication took place with the on-site dental laboratory. The upper rim was altered to achieve optimal anterior occlusal plane parallel to the interpupillary line. The posterior occlusal plane was measured according to the ala-tragal line [4]. The lower rim was trimmed to ensure correct interocclusal freeway space of 2–4 mm based on the occlusal vertical and relaxed vertical dimensions. The midline was marked to be coincident with the natural facial midline, using the philtrum of the lip, nose, and labial frenum as a guide. The rims were

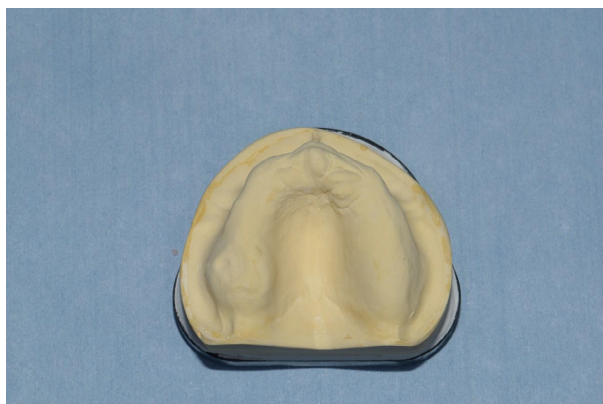

Figure 2. Upper master model.

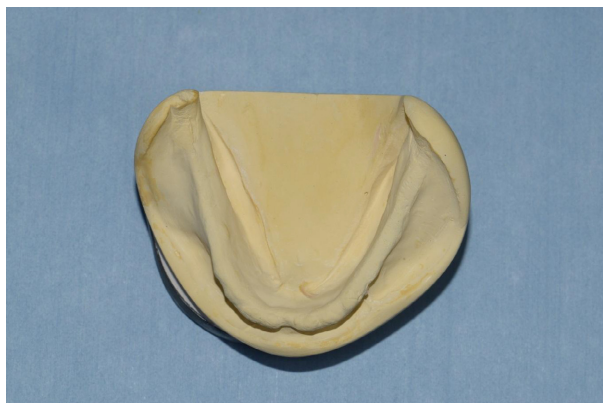

Figure 3. Lower master model.

registered with polyvinyl siloxane registration paste in retruded contact position. These were disinfected and instructions were sent to the laboratory for them to be articulated on an average value articulator (Average Value Articulator, 30° condylar angle and flat incisal table) (Figs. 4 and 5).

The upper teeth were set up as per the registration rim and based around the midline. This was important esthetically to the patient as the asymmetry was confined to a left-sided mandibular chin point shift only. Conventional posterior occlusion was set up on the right side. In order to maintain occlusal contact, the posterior teeth on the lower left side were placed lingual to the alveolar ridge in a balanced occlusal scheme (cross-bite). This was checked with the patient at trial to ensure the teeth were not encroaching in the tongue space. Anatomical teeth were used rather than a flat occlusal table [5]. The upper and lower wax try in complete dentures were well fitting and the dentition arrangement was verified. At this stage, the occlusion was reregistered, again in polyvinyl siloxane registration paste.

The denture was gum fitted in the lower anterior 3-3 region labially (open-faced denture). Due to the gum fit anteriorly and the risk of midline fracture of the denture, processing involved the use of high impact acrylic. This was spot ground on the articulator prior to fit.

The patient returned for fit of the removable complete dentures (Figs. 6 and 7). The occlusion and esthetics were good and at this stage, some adjustment was required on the lower denture fit surface for the patient's comfort. The patient was very pleased with the result. At this stage, oral and written denture instructions were given and the patient was encouraged to make efforts to adapt to the new dentures [6].

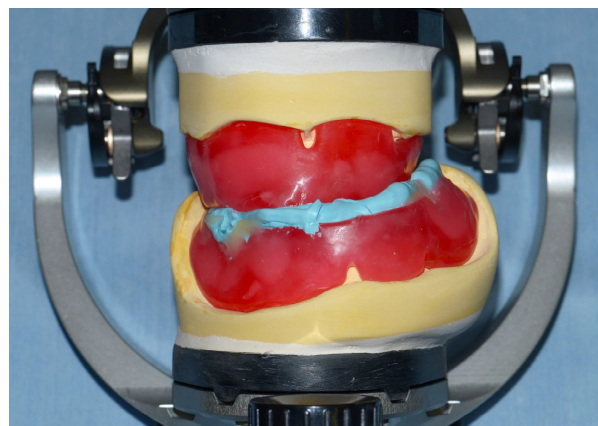


Figure 4. Registration with models mounted on articulator— anterior view.

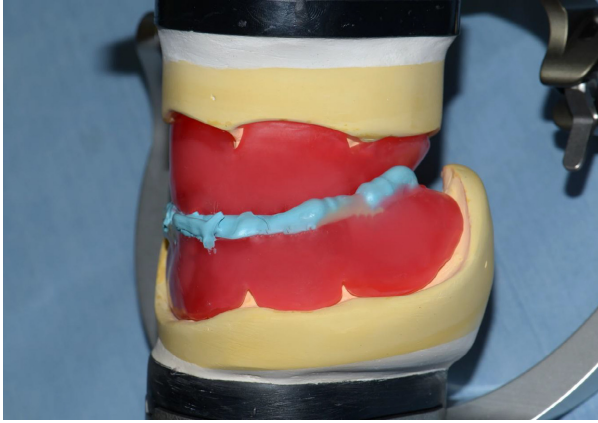


Figure 5. Registration rims on master models mounted on articulator—lateral view.

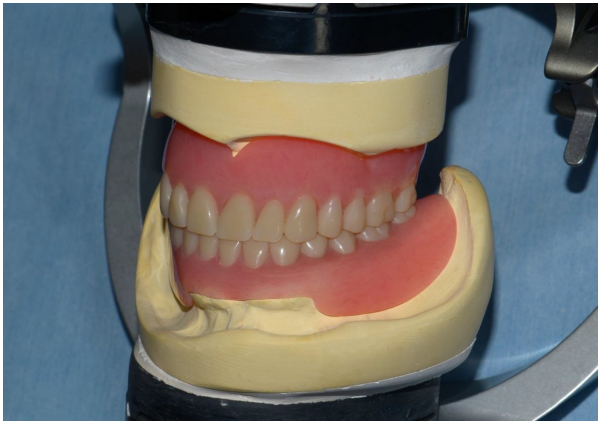

Figure 6. Final C/C dentures mounted on master models on articulator.

Outcome

At review, the patient reported that he was very pleased with the outcome both esthetically and functionally and that he felt his concerns had been appropriately addressed. He was particularly pleased that such success had been achieved by adapting the most conservative treatment option. The final prosthodontic outcome is shown in Figures 7 and 8.

Discussion

Mandibular transverse asymmetries have many causes and can often be challenging to treat [7]. However, as seen in this case, with a detailed clinical history, examination and further investigations into the cause of the problem successful prosthodontic management can be achieved with close input from skilled dental

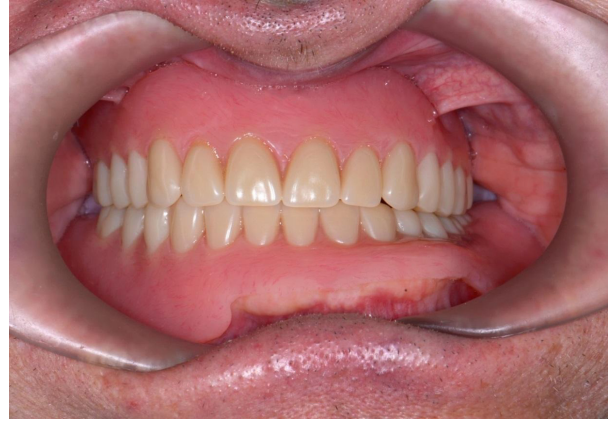

Figure 7. Intraoral view of final complete dentures.

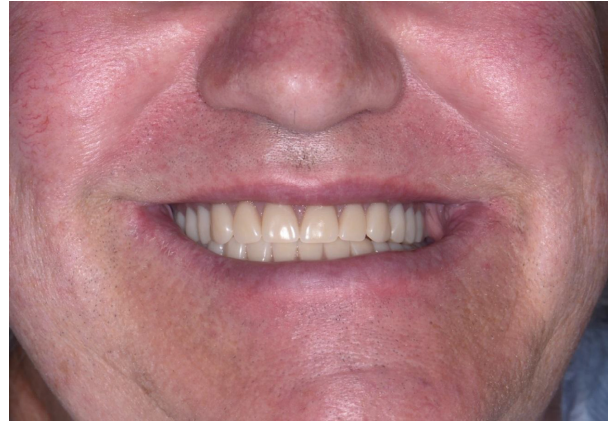

Figure 8. Extraoral view with upper and lower complete dentures in situ. Transverse chin point deviation to the left side is visible.

technicians. It is also important to have discussion with the patient in order to appropriately address their concerns.

Treatment options can range from simple nonsurgical measures to complex multidisciplinary approaches with the requirement for restorative specialists, orthodontic opinions, and surgical input. Surgical options may have included distraction osteogenesis which has been used to treat mandibular asymmetries where the mandibular ramus and body are to be lengthened. Lower border osteotomy of the mandible can reposition the chin point transversely or vertically in order to address the asymmetry. It is one of the most stable movements compared to managing mandibular asymmetries by other orthognathic movements [8].

Understanding the etiology of mandibular asymmetry is important in the management of patients [1]. Common Causes of Mandibular Jaw Deviation are summarized in Table 1 [8, 9].

Conclusion

This case demonstrated the successful prosthodontic rehabilitation of a patient with a significant mandibular asymmetry. In some cases, treatment can be provided within primary care; however, in this case, specialist input was required [1]. There is minimal guidance surrounding the referral criteria for facial asymmetries; however, due to the potential for joint maxillofacial, orthodontic and restorative treatment planning and close liaison with dental laboratories, it may be necessary in most cases to refer to specialist services.

Furthermore, if the cause of the facial asymmetry is unknown further investigations may also be required to rule out pathology, which may not be possible in a primary care setting. The extent to which the functional and esthetic concern affects the patient is also likely to influence the referral decision and treatment choice.

It is hoped that this report will provide further information to practitioners in varying care settings and aid in management of these challenging patients.

Acknowledgments

Robert Thompson—Clinical Case Photography. Gary McNeilly and the Prosthetics Dental Laboratory Staff RVH. Treatment costs covered under National Health Service.

Ethics

Informed and valid consent was obtained from the patient for use of the dental notes, radiographs, and photographs in the case report.

Authorship

NH: was the first Author and Dental Core Trainee. GMK: was the Corresponding Author and Clinical Consultant.

Conflict of Interest

None declared.

References

1. Reyneke, J. P., P. Tsakiris, and F. Kienle. 1997. A simple classification for surgical treatment planning of maxillomandibular asymmetry. *Br. J. Oral Maxillofac. Surg.* 35:349–351.
2. Kim, J. Y., H. D. Jung, Y. S. Jung, C. J. Hwang, and H. S. Park. 2014. A simple classification of facial asymmetry by TML system. *J. Craniomaxillofac. Surg.* 42:313–320.
3. Cawood, J. L., and R. A. Howell. 1988. A classification of the edentulous jaws. *Int. J. Oral Maxillofac. Surg.* 17:232–236.
4. Woelfel, J. B., T. Igarashi, and J. K. Dong. 2014. Faculty-supervised measurements of the face and of mandibular movements on young adults. *J. Adv. Prosthodont.* 6:483–490.
5. Abduo, J. 2013. Occlusal schemes for complete dentures: a systematic review. *Int. J. Prosthodont.* 26:26–33. *Quintessence Journals*
6. Mahajan, T., R. Trivedi, S. Singh, and R. Sangur. 2015. Prosthetic management of edentulous mandibulectomy patient with modified occlusion - A case report. *Rama Univ. J. Dent. Sci.* 2:42–45.
7. Cheong, Y. W., and L. J. Lo. 2011. Facial asymmetry: etiology, evaluation, and management, review article. *Chang. Gung. Med. J.* 34:341–351.
8. Chia, M. S. Y., F. B. Naini, and D. S. Gill. 2008. The aetiology, diagnosis and management of mandibular asymmetry. *Ortho. Update* 1:44–52.
9. Xavier, S. P., T. Santos, E. R. Silv, A. C. Faria, and F. V. de Mello Filh. 2014. Two-stage treatment of facial asymmetry caused by unilateral condylar hyperplasia. *Braz. Dent. J.* 25:257–260. *Ribeirão Preto*