

## Case report

## Please do not put a chest drain in my chest! Vanishing lung syndrome

Avinash Aujayeb\*



Acute Medicine Department, The Northumbria Specialist Emergency Care Hospital, Northumbria Way, Cramlington NE23 6NZ

## A B S T R A C T

**Introduction:** Vanishing lung syndrome, also known as giant bullous emphysema is a condition usually reported in young male thin smokers. There are numerous case reports that have added to the body of evidence. There are also case reports of the giant bulla being misinterpreted for a pneumothorax.

**Case report:** A 61 year old male with severe chronic obstructive lung disease presented to Accident and Emergency with progressive breathlessness. A chest radiograph showed a giant right sided bulla that was initially misinterpreted as a tension pneumothorax. Further review of his imaging and lung function pointed to him having vanishing lung syndrome. He was referred for a cardiothoracic opinion but was eventually managed conservatively.

**Discussion:** Vanishing lung syndrome is characterised by a slowly enlarging upper lobe bulla that compresses normal lung parenchyma and causes mediastinal shift, with the patients experiencing increasing dyspnoea and reduced exercise tolerance. Smoking cessation is the mainstay of treatment. If they are relatively asymptomatic, patients are managed conservatively. Otherwise a variety of lung volume reduction techniques can be considered. A large bulla can look the same as a pneumothorax but the former does not have a lung edge and has a more rounded appearance. A CT scan is very useful in differentiating between the two pathologies. Bullae are predominantly caused by smoking. Bullae will cause high total lung volumes and residual volumes, but low alveolar volumes. Bullae can be observed or treated by surgical techniques

## Introduction

Vanishing lung syndrome, also known as giant bullous emphysema is a condition usually reported in older smokers with advanced chronic obstructive lung disease. It has also been reported in young male thin smokers and there are numerous case reports that have added to the body of evidence [1–8]. There are also case reports of the giant bulla being misinterpreted for a pneumothorax [1–3,6,10].

Vanishing lung syndrome is characterised by a slowly enlarging upper lobe bulla that compresses normal lung parenchyma and causes mediastinal shift, with the patients experiencing increasing dyspnoea and reduced exercise tolerance.

Patients with giant bullae are divided into four groups: Group I—single giant bulla and normal lung parenchyma, Group II—multiple giant bullae and normal lung, Group III—multiple bullae with underlying lung broadly affected by emphysema and Group IV—multiple bullae with underlying lung affected by other diseases. Smoking cessation is the mainstay of treatment. If patients are relatively asymptomatic, they can be managed conservatively. Otherwise a variety of lung volume reduction techniques and lung transplantation can be considered, alongside palliation of symptoms [9]. Patients with more widespread disease have limited treatment options [4].

Computer tomography is the gold standard for distinguishing between a pneumothorax and a giant bulla [2,3,5] as insertion of a chest drain into a bulla leads to significant morbidity and mortality from

prolonged air leaks [9–10].

## Case report

A 61 year old male presented to Accident and Emergency with a gradual onset of a four day history of increasing breathlessness. There was no cough, chest pain or sputum produced.

He was an ex-smoker of fifty pack years. He had never smoked marijuana. Normal exercise tolerance was about forty metres on the flat. He could climb a flight of stairs with 2 stops but had not been able to do either over the last four days.

His past medical history included controlled hypertension and moderate chronic obstructive pulmonary disease for which budesonide 320 micrograms/formetrol dehydrate 9 micrograms inhalation powder 1 puff twice daily and tiotropium Handihaler 2.5 micrograms once daily were prescribed.

Oxygen saturations were 93% on air. He was afebrile and looked comfortable at rest. The pulse rate, number of breaths per minute and blood pressure were normal. Auscultation of the chest revealed decreased air entry in the whole of the right hemithorax. There was left sided tracheal deviation and the rest of the examination was normal, with no wheeze or peripheral oedema detected.

An urgent chest x-ray was performed (Fig. 1). This was interpreted as showing a large right, secondary pneumothorax with some mediastinal shift to the left. However, the patient showed no respiratory

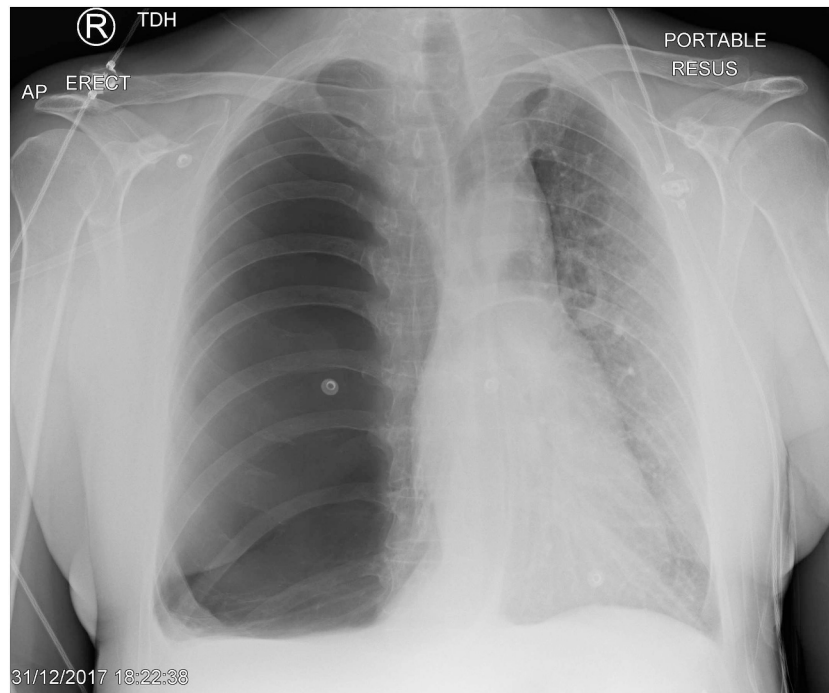
\* Corresponding author.

E-mail address: [avinash.aujayeb@nhct.nhs.uk](mailto:avinash.aujayeb@nhct.nhs.uk).<https://doi.org/10.1016/j.afjem.2020.03.001>

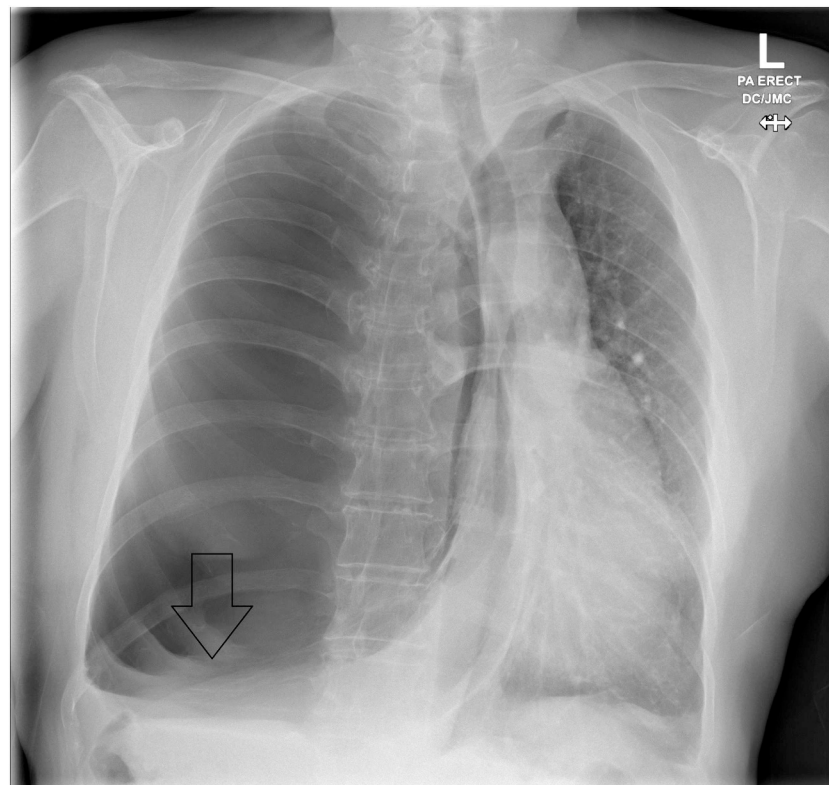
Received 24 July 2019; Received in revised form 23 February 2020; Accepted 8 March 2020

Available online 05 May 2020

2211-419X/ © 2020 African Federation for Emergency Medicine. Publishing services provided by Elsevier. This is an open access article under the CC BY-NC-ND license (<http://creativecommons.org/licenses/by-nc-nd/4.0/>).



**Fig. 1.** Chest radiograph showing a large right sided bulla with lung markings basally. This was misinterpreted as a tension pneumothorax.



**Fig. 2.** Chest radiograph at presentation showing lung markings.

compromise and as such no immediate action such as a needle decompression was taken. A referral was made to respiratory medicine for an urgent review and a possible intervention such as a chest drain insertion. This was serendipitous as the Accident and Emergency (A&E) team knew that a member of the pleural team was on call for respiratory medicine and readily available. Our hospital is a flagship emergency care centre where consultant cover and for respiratory

medicine, pleural cover, is available 24 hours a day, 7 days a week.

Upon further review of the chest radiograph by the respiratory consultant, lung markings could be identified basally (Fig. 2). It was felt that this was not a clear case of a pneumothorax and a chest drain was not immediately inserted.

Previous imaging and electronic notes were urgently reviewed.

The patient had lung function and lung volumes via pletysmograph

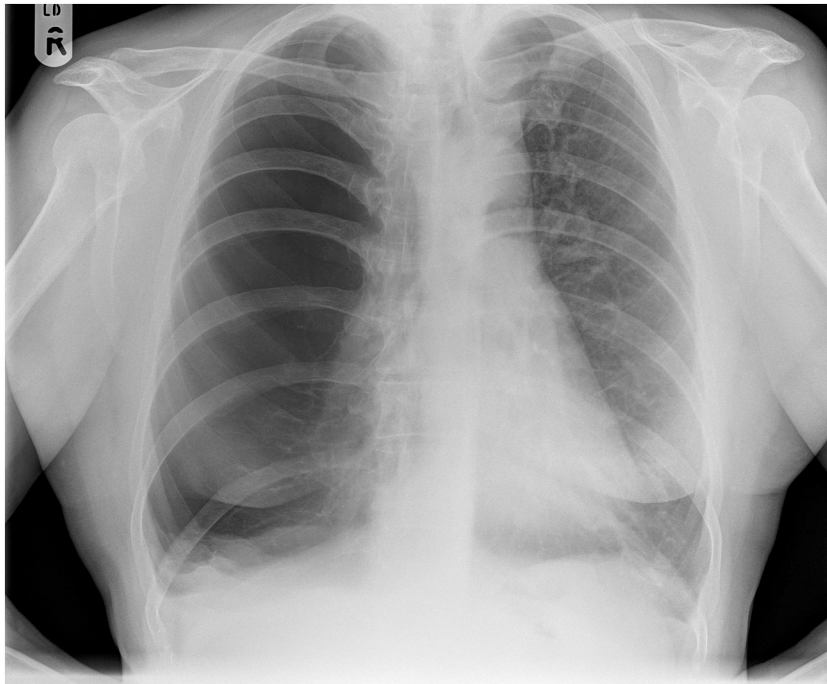


Fig. 3. Chest radiograph in 2013 showing small basal right bulla.

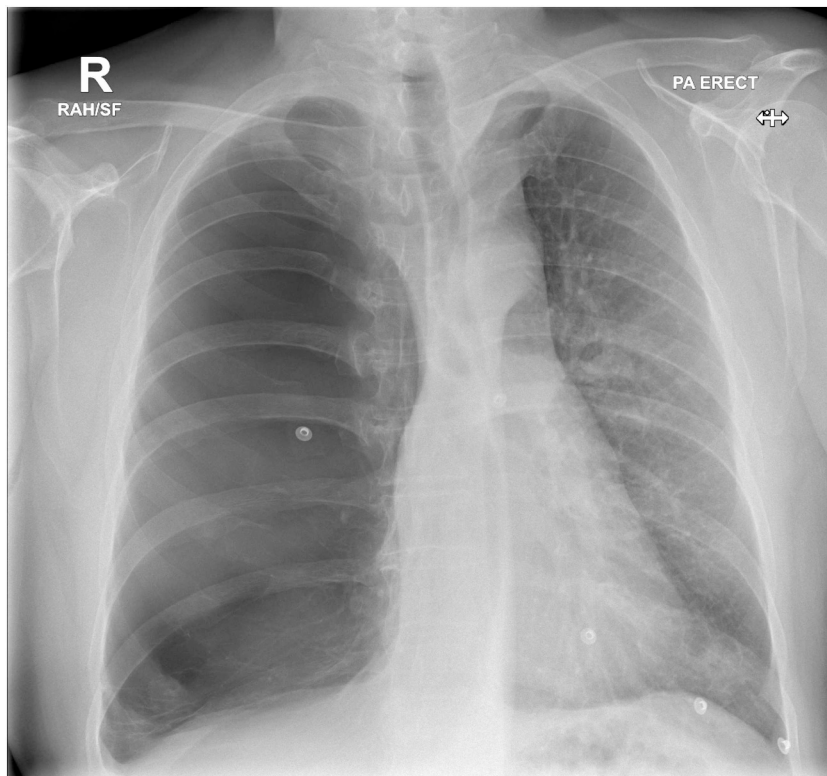


Fig. 4. Chest radiograph in 2015 showing enlarging bulla.

in 2015. The forced expiratory volume in 1 second (FEV1) was 1.2 Litres (L) (41% predicted), forced vital capacity (FVC) 2.43L (67% predicted), total lung capacity (TLC) 7.33L (125% predicted), residual volume (RV) 230% predicted and alveolar volumes 4L (68% predicted). Transfer factor for carbon monoxide (TLCO) was 44% of predicted and the transfer coefficient of carbon monoxide (KCO) was 65% of predicted.

The above confirmed severe chronic obstructive pulmonary disease and emphysema. The very high TLC and RV volumes suggested significant air trapping and the disparity between the alveolar volume and TLC suggested inhomogeneous gas mixing, a component of obstructive lung disease and bullous disease, which resulted in increased anatomical dead space.

Oxygen saturations from clinic were noted to vary between 89% on

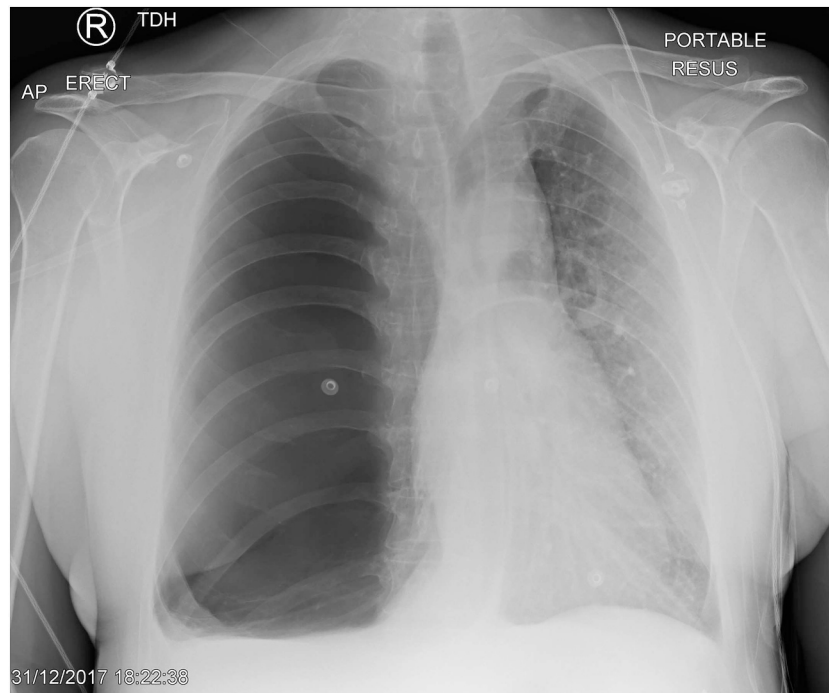


Fig. 5. Chest radiograph in 2017 showing large bulla starting to cause mediastinal shift.

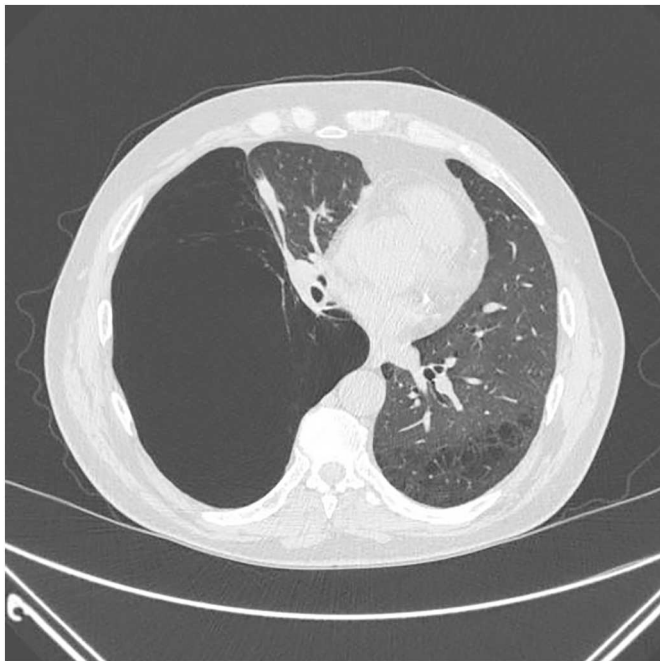


Fig. 6. Computer tomogram in 2015 showing a large bulla occupying approximately 75% of right hemithorax, arising from the right lower lobe and extending to the lung apex, with mediastinal displacement.

air to 94% on air. Left sided tracheal deviation was also noted to have been present from 2016 onwards.

Figs. 3–5 from 2011 to late 2018 revealed a slowly enlarging bulla with increasing effacement of the normal lung parenchyma in the right lung. He had thus been diagnosed with giant bullous emphysema leading to vanishing lung syndrome. Figs. 6 and 7 showed slices of a CT in 2013 showing a large bulla occupying approximately 75% of right hemithorax, arising from the right lower lobe and extending to the lung apex. There was minimal mediastinal displacement to the left in 2013,

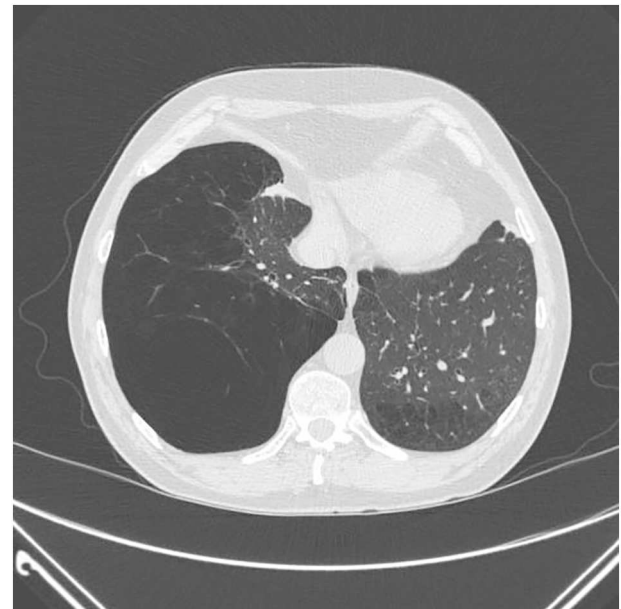

Fig. 7. Computer tomogram in 2015 showing a large bulla occupying approximately 75% of right hemithorax, arising from the right lower lobe and extending to the lung apex, with mediastinal displacement and basal markings.

but the shift has become more pronounced on sequential imaging.

A ventilation-perfusion scan in 2016 showed that the left lung had 89% perfusion and the right 11%, with ventilation at 92% in left lung and 8% in the right. He had been referred for a pneumonectomy at the time but declined any intervention after meeting the cardiothoracic surgeons.

The patient had been initially managed conservatively and then turned up for numerous appointments. He had been thus discharged from secondary care.

The chest radiograph depicted in Fig. 1 was reviewed by the on call radiology service: the absence of a lung edge, the presence of lung

markings as well as the lack of abrupt onset of symptoms such as pain and dyspnoea made a pneumothorax unlikely. The chest radiograph in Fig. 1 looked similar to the last one done in 2018 and as such, a CT scan was not felt to be immediately indicated.

The patient was admitted and treated with 30 milligrams of prednisolone once a day for a possible non infective exacerbation of his obstructive lung disease. There was a clear documented plan that should he not improve, he would require an urgent CT scan to elucidate his anatomy further. After 48 hours, he felt markedly improved (oxygen saturations on air varied between 89% to 94% and his exercise tolerance improved to pre-admission levels) and had not required nebulised or oxygen therapy. He was thus discharged and outpatient follow up arranged.

He was given an alert card that said: 'My right lung has a large bulla. This can look like a pneumothorax. Please do not put a chest drain in me if unsure of what is going on. Consider a CT scan. Ask for senior advice'

The patient then failed to attend for further clinic appointments. A telephone consultation took place: he mentioned his respiratory symptoms being stable and that he did not wish to have any secondary care follow up.

## Discussion

Chronic obstructive pulmonary disease is characterised by airflow limitation and air trapping. Emphysema is an umbrella term for the destruction and permanent enlargement of the alveoli, without overt evidence of fibrosis [9,10].

A bulla is an air space which is more than one centimetre in diameter in the distended state. It consists of a thin wall of visceral pleura with remnants of alveolar and interlobular septa inside. Bullous emphysema is emphysematous lung within a bulla. A bulla will slowly increase over time and compress adjacent lung, with associated loss of function.

A giant bulla occupies more than 30 per cent of the hemi-thorax. The main aetiological factor is cigarette smoking. Cases have also been described with alpha-1 antitrypsin deficiency, untreated human immunodeficiency virus, intravenous drug use and connective tissue diseases such as Marfan's or Ehlers Danlos syndromes [9]. Concurrent cigarette and marijuana smoking might also contribute to upper lobe bullous disease [10].

The lack of a lung edge, the round nature of a bulla, and the presence of bullae elsewhere as well as lung markings all point to the imaging not showing a pneumothorax [1,3,5,6].

Bullae can rupture and cause a secondary spontaneous pneumothorax [9,11]. The management of such a complication would then follow established guidelines. Locally, the British Society guidelines are

followed and they would advocate admission, controlled oxygen therapy and observation or intervention depending on the size of the pneumothorax and symptoms of the patient [12].

Options for management of bullae are smoking cessation, observation only if asymptomatic, endobronchial valves or bullectomy, or in this case potentially a pneumonectomy and in appropriate cases lung transplantation [1–9].

The main learning point from this case is that bullae and pneumothorax can have very similar appearances on chest radiographs. It was only by chance that this patient did not have a chest drain inserted. The presence of lung markings and the lack of a lung edge make bullae more likely. Further imaging with a CT scan will help differentiate between the two pathologies and this was not required here as the clinical presentation did not fit and past radiological images were available and reviewed by a radiology consultant. The patient had also presented during normal working hours and was admitted to a respiratory ward to be monitored in case of any deterioration.

## Declaration of competing interest

The author declared no conflicts of interest.

## References

- [1] Khasawneh FA, Nakhla EN, Karim A, et al. Vanishing lung syndrome mistaken for bilateral spontaneous pneumothorax. *Case Reports* 2013;2013:bcr2013201016.
- [2] Sarangi PK, Nahak SK, Parida S, et al. A rare case of vanishing lung syndrome with pneumothorax: importance of computed tomography. *Int J Sci Rep* 2016;2. <https://doi.org/10.18203/issn.2454-2156.IntJSciRep20163970>. (292–52).
- [3] Vega ME, Civic B. Images in clinical medicine: a tension Bulla mimicking tension pneumothorax. *N Engl J Med* 2011;365:1915. <https://doi.org/10.1056/NEJMicm1101918>.
- [4] Im Y, Farooqi S, Mora A. Vanishing lung syndrome. *Proc (Bayl Univ Med Cent)* 2016;29:399–401.
- [5] Waitches GM, Stern EJ, Dubinsky TJ. Usefulness of the double-wall sign in detecting pneumothorax in patients with giant bullous emphysema. *AJR Am J Roentgenol* 2000;174:1765–8. <https://doi.org/10.2214/ajr.174.6.1741765>.
- [6] Lai CC, Huang SH, Wu TT, et al. Vanishing lung syndrome mimicking pneumothorax. *Postgrad Med J* 2013;2013:427–8.
- [7] Jaiswal P, Sreenivasan J, Jaiswal R, et al. The vanishing lung. *Postgraduate Medical Journal* 2017;93:780–1.
- [8] Sood N. A Rare Case of Vanishing Lung Syndrome. *Case Reports in Pulmonology* 2011;957463. (2 pages).
- [9] <https://www.uptodate.com/contents/evaluation-and-medical-management-of-giant-bullae> (accessed 24.4.2019).
- [10] Ribeiro L. Ind PS127 Effect of cannabis smoking on the development of bullous lung disease: a structured literature review. *Thorax* 2016;71:A74–6.
- [11] Paramasivam E, Bodenham A. Air leaks, pneumothorax, and chest drains. *Continuing Education in Anaesthesia Critical Care & Pain*. 2008;8(6):204–9.
- [12] MacDuff A, Arnold A, Harvey J. Management of spontaneous pneumothorax: British Thoracic Society pleural disease guideline 2010. *Thorax* 2010;65:ii18–31.