

Teaching Point
(Section Editor: A. Meyrier)

2,8-Dihydroxyadeninuria-induced progressive renal failure

Fabrice Mac-Way¹, Simon Desmeules¹, Eva Latulippe², Paul René de Cotret¹ and Mohsen Agharazii¹

¹Divisions of Nephrology and ²Pathology, Centre Hospitalier Universitaire de Québec, L'Hôtel-Dieu de Québec Hospital and Faculty of Medicine, Laval University, Quebec, Canada

Keywords: acute renal failure; adenine phosphoribosyl-transferase deficiency; chronic kidney disease; 2,8-dihydroxyadeninuria; urolithiasis

Introduction

Adenine phosphoribosyl-transferase (APRT) is the key enzyme that transforms adenine into adenylyl monophosphate (AMP). In case of APRT deficiency, xanthine oxidase rapidly oxidizes adenine into 2,8-dihydroxyadenine (2,8-DHA), which is then eliminated by the kidneys through tubular secretion. 2,8-DHA is insoluble at a physiologic range of pH; therefore, it can easily precipitate in the urine. Although subjects with APRT deficiency may have repeated kidney stones, some of these patients may remain asymptomatic throughout life [1,2]. Nevertheless, a handful of reports propose that APRT deficiency can also lead to 2,8-DHA crystal-induced acute or chronic renal failure [3,4].

In this paper, we report a case of a middle-aged man with APRT deficiency that led to 2,8-DHA crystal-induced chronic active tubulointerstitial nephritis.

Case

A 59-year-old man was referred for the evaluation of progressive chronic kidney disease with a serum creatinine level of 5.5 mg/dL (487 µmol/L). He was on aspirin, furosemide and diltiazem for mild coronary artery disease and hypertension. He had a history of only one kidney stone 10 years before, at which time the creatinine level was normal. He denied any family history of kidney stones and any physical complaints. His blood pressure was 140/75 mmHg and his physical examination was otherwise unremarkable. His records showed that the creatinine levels

had increased steadily over the past 3 years from 1.6 mg/dL (141 µmol/L) to 3.3 mg/dL (290 µmol/L). At the time of referral 3 months later, the creatinine level had further increased to 5.5 mg/dL (487 µmol/L). Complete blood count was normal except a haemoglobin level of 9.4 g/dL (94 g/L). Serum electrolyte levels were within the normal range. A renal ultrasound and CT-scan revealed kidneys of normal size without any kidney stones. Urinalysis revealed a specific gravity of 1015 and a protein concentration of 0.3 g/L. Microscopic examination revealed multiple spherical brownish crystals that had a pseudo-Maltese cross appearance under polarized light. These crystals raised suspicion for the diagnosis of 2,8-DHA crystalluria (Figure 1). Renal biopsy revealed that 76% of the glomeruli were obsolescent while the remaining glomeruli were unremarkable. An H&E stain on a frozen section of the kidney sample revealed a moderate interstitial fibrosis and tubular atrophy with severe inflammation composed principally of lymphocytes, eosinophils and macrophages that surrounded multiple intra-tubular birefringent crystals (Figure 2). Using HPLC, the urine concentration of 2,8-DHA was shown to be very high (111 µmol/mmol of creatinine) whereas it is not detectable in healthy controls, providing further support for the diagnosis of 2,8-DHA crystal-induced interstitial nephritis.

Meanwhile, the creatinine concentration peaked to as high as 7.5 mg/dL (665 µmol/L). The patient was treated with allopurinol 300 mg/day and put on a low-purine diet and a high-fluid regimen. The serum creatinine level decreased gradually over the next 2 months to reach a nadir of 2.5 mg/dL (225 µmol/L). However, due to side effects, the allopurinol dose had to be reduced to 100 mg/day. During the following 2 years, the serum creatinine levels remained stable at 2.2 mg/dL (200 µmol/L) and a urine examination remained free of 2,8-DHA crystals.

Discussion

In the present case report of 2,8-DHA crystal-induced renal failure, the patient had but one episode of kidney stone, at which point his creatinine level was normal. In this particular case, the lack of familiarity with APRT deficiency and

Correspondence and offprint requests to: Mohsen Agharazii, Centre de Recherche de l'Hôtel Dieu de Québec, CHUQ-Hôtel-Dieu de Québec, 11, Cote du Palais, Quebec City, G1R 2J6, Canada. Tel: +1-418-691-5464; Fax: +1-418-691-5562; E-mail: mohsen.agharazii@crhdq.ulaval.ca

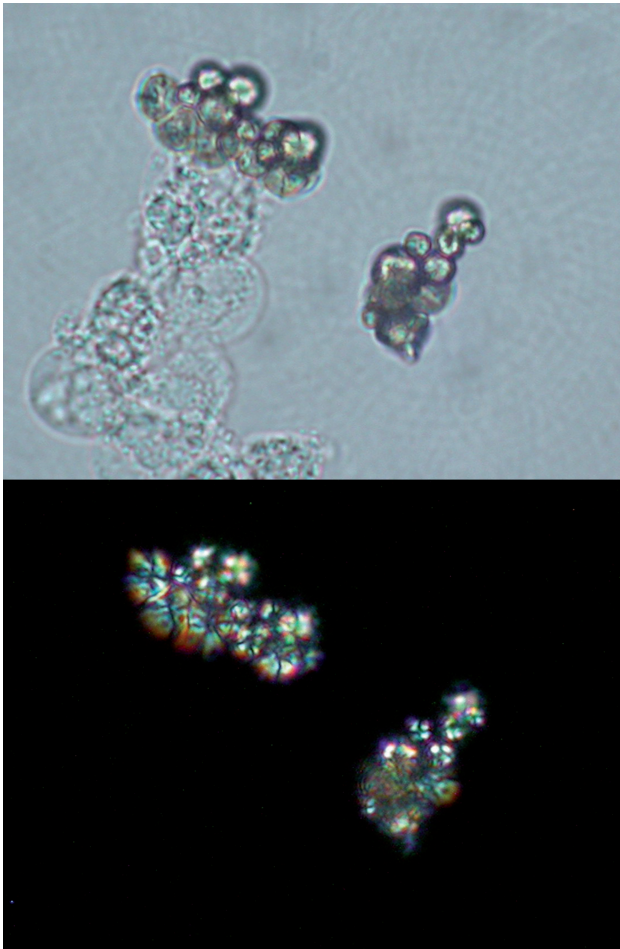


Fig. 1. Urine microscopy. Urinary sediment showing spherical brownish crystals (top panel) that have a birefringent and pseudo-Maltese cross appearance under polarized light (lower panel). Original magnification $\times 400$.

the tardy recognition of these unusual but pathognomonic crystals were, at least partly, responsible for the progression of renal failure and delayed diagnosis. Even in Iceland, where the prevalence is the highest and there is a greater awareness of the disease by the medical community, it is still not uncommon to encounter delayed diagnosis of this condition [1]. Fortunately, timely administration of high fluid intake, a low-purine diet and use of allopurinol led to a significant improvement of renal function of our patient over the following months.

APRT deficiency is classified as a rare inherited stone-forming disease that is transmitted in an autosomal recessive fashion. Type I APRT deficiency is seen in Caucasians and is characterized by a complete deficiency of APRT activity, whereas Type II APRT deficiency is primarily seen in the Japanese population and is characterized by a reduction of APRT activity in lysed erythrocytes, ranging from 10 to 25% of normal [1,5]. While the heterozygotic forms of the APRT deficiency do not generally lead to symptoms, the homozygote patients invariably present 2,8-dihydroxyadeninuria and often experience mul-

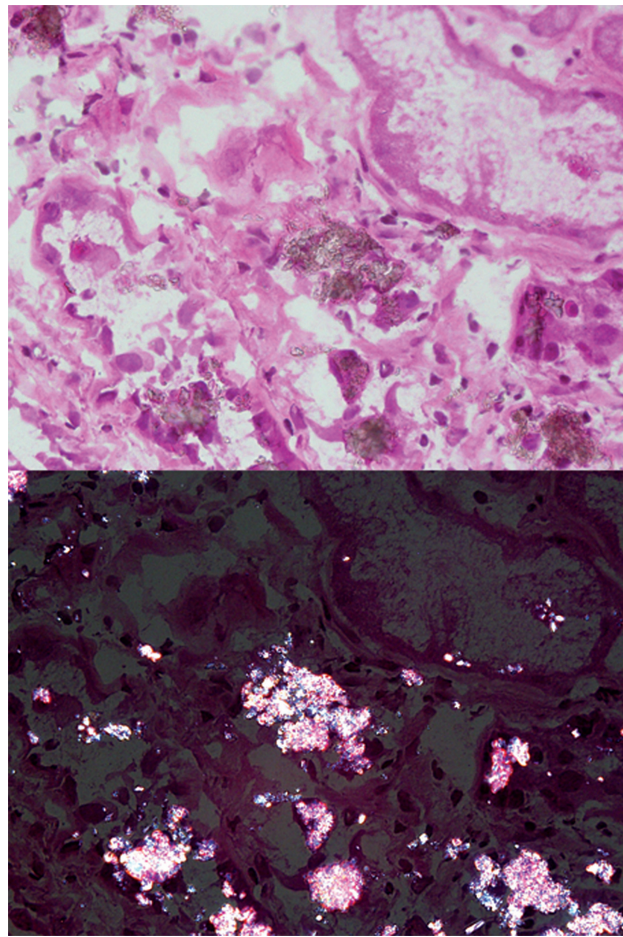


Fig. 2. Renal biopsy. Haematoxylin and eosin staining of a frozen section reveals interstitial inflammation surrounding multiple intra-tubular round brownish crystals that are birefringent under polarized light. Original magnification $\times 600$.

tle episodes of kidney stones. Nevertheless, up to 15% of the patients may remain asymptomatic throughout life. Even though the enzyme deficiency is present at birth, the symptoms related to APRT deficiency may occur from early childhood to the seventh decade of life.

Stone analysis using biochemical methods, including colorimetric reaction and thermogravimetric analysis, can misidentify the 2,8-DHA stones as uric acid nephrolithiasis. Although differentiation of the two disorders can easily be made with infrared and UV spectrophotometry or x-ray crystallography of crystals or stones, recognition of the characteristic 2,8-DHA crystals on urinalysis is invaluable for the proper diagnosis.

More recently, there have been reports of acute renal failure associated with APRT deficiency and 2,8-DHA crystalluria [3,6]. In addition, there have also been reports of progressive renal failure in patients with previous history of repeated kidney stones [1]. However, the absence of previous multiple kidney stones does not preclude the diagnosis of 2,8-DHA-induced renal failure. Indeed, in our patient there was but one episode of previous kidney stone. This is in keeping with a reported case of 2,8-DHA-induced graft

failure in a renal transplant recipient without any prior repeated history of kidney stones [4,7]. In these patients, it has been proposed that significant intra-tubular precipitation of 2,8-DHA crystals may lead to chronic tubulointerstitial injury and hence, progressive renal failure [8].

APRT deficiency is a rare disorder and only few cases of renal failure have been reported in the literature. Because of the lack of familiarity with this condition, it is possible that 2,8-DHA crystal-induced renal failure may be an underdiagnosed aetiology of chronic kidney disease [9]. In this regard, we believe that the nephrology community should become familiar with this condition and consider such diagnosis in unusual cases of renal failure, as it is easily treatable if diagnosed in a timely manner. Since the urinary 2,8-DHA crystals are usually abundant in untreated patients with 2,8-dihydroxyadeninuria, a urine microscopy as performed by a skilful observer is the single most important diagnostic procedure [5]. The presence of 2,8-DHA in urinary sediment can be confirmed by infrared and UV spectrophotometry. The diagnosis may also be confirmed by determination of purine derivative profile showing increased amounts of adenine in both serum and plasma (HPLC) or by measurement of the level of enzymatic activity.

Teaching points

1. 2,8-Dihydroxyadeninuria is a rare inherited stone-forming disease caused by APRT deficiency.
2. APRT deficiency could lead to acute renal failure or progressive kidney disease in adulthood without previous significant history of kidney stones.
3. Recognition of 2,8-DHA crystals in the urine is of utmost importance in diagnosis and treatment of 2,8-DHA crystal-induced renal injury.

4. A simple treatment based on allopurinol administration, high fluid intake and a low-purine diet can reverse or halt renal damage and avoid premature dialysis.

Acknowledgement. Dr M. Agharazii holds a clinician scientist scholarship from *Le Fonds de la Recherche en Santé du Québec* (FRSQ).

Conflict of interest statement. None declared.

References

1. Edvardsson V, Palsson R, Olafsson I *et al.* Clinical features and genotype of adenine phosphoribosyltransferase deficiency in Iceland. *Am J Kidney Dis* 2001; 38: 473–480
2. Simmonds HA, Van Acker KJ, Cameron JS *et al.* The identification of 2,8-dihydroxyadenine, a new component of urinary stones. *Biochem J* 1976; 157: 485–487
3. Arnadóttir M, Laxdal T, Hardarson S *et al.* Acute renal failure in a middle-aged woman with 2,8-dihydroxyadeninuria. *Nephrol Dial Transplant* 1997; 12: 1985–1987
4. Brown HA. Recurrence of 2,8-dihydroxyadenine tubulointerstitial lesions in a kidney transplant recipient with a primary presentation of chronic renal failure. *Nephrol Dial Transplant* 1998; 13: 998–1000
5. Terai C, Hakoda M, Yamanaka H *et al.* Adenine phosphoribosyltransferase deficiency identified by urinary sediment analysis: cellular and molecular confirmation. *Clin Genet* 1995; 48: 246–250
6. Greenwood MC, Dillon MJ, Simmonds HA *et al.* Renal failure due to 2,8-dihydroxyadenine urolithiasis. *Eur J Pediatr* 1982; 138: 346–349
7. Cassidy MJ, McCulloch T, Fairbanks LD *et al.* Diagnosis of adenine phosphoribosyltransferase deficiency as the underlying cause of renal failure in a renal transplant recipient. *Nephrol Dial Transplant* 2004; 19: 736–738
8. Stockelman MG, Lorenz JN, Smith FN *et al.* Chronic renal failure in a mouse model of human adenine phosphoribosyltransferase deficiency. *Am J Physiol* 1998; 275: F154–F163
9. Ceballos-Picot I, Perignon JL, Hamet M *et al.* 2,8-Dihydroxyadenine urolithiasis, an underdiagnosed disease. *Lancet* 1992; 339: 1050–1051

Received for publication: 23.6.08

Accepted in revised form: 15.7.08