

STANDARD ARTICLE

Minimally invasive treatment of sino-nasal aspergillosis in dogs

Clara Ballber¹ | Tracy L. Hill²  | Nick X. Bommer³¹Wood Street Veterinary Hospital, London, United Kingdom²College of Veterinary Medicine, University of Georgia, Athens, Georgia, 30602³Hospital for Small Animals, University of Edinburgh, Edinburgh, EH25 9RG, United Kingdom

Correspondence

Tracy Hill, College of Veterinary Medicine, University of Georgia, 2200 College Station Rd., Athens, GA 30601.

tracy.hill@uga.edu

Background: Sino-nasal aspergillosis is a common nasal disease in dogs. Recommended treatment protocols typically involve trephination of the frontal sinuses or the use of an antifungal solution instilled into the frontal sinus under anesthesia, both of which have associated morbidity and complications.

Objectives: To assess a minimally-invasive topical treatment protocol for sino-nasal aspergillosis in dogs.

Animals: Twelve client-owned dogs diagnosed with sino-nasal aspergillosis that completed recommended treatment.

Methods: Medical records were retrospectively reviewed to identify dogs with sino-nasal aspergillosis that received treatment. Fungal plaques were manually debrided and irrigated via frontal sinuscopy in 12 dogs that then were treated topically with 1% topical clotrimazole cream. Irrigation and topical medication application was achieved using a catheter placed retrograde directly into the frontal sinuses using the Seldinger technique over a guidewire, thereby avoiding the need for frontal sinus trephination. Invasion into the calvarium was recorded before treatment but was not considered a criterion for exclusion. Debridement and cream deposition was repeated every 2 weeks as needed until negative culture and histopathologic findings were obtained.

Results: All dogs were cured (negative results for *Aspergillus* on endoscopy, fungal culture, and histopathology) with a median of 2 treatments. Treatments were well tolerated, with minimal adverse effects reported. Three dogs had evidence of erosion into the calvarium on computed tomography imaging.

Conclusions and Clinical Importance: This protocol appears to be an effective and well-tolerated minimally invasive treatment for sino-nasal aspergillosis, including in dogs with erosion into the calvarium. Only mild adverse effects were noted.

KEYWORDScanine, guidewire, clotrimazole, endoscopic, *Aspergillus*

1 | INTRODUCTION

Sino-nasal aspergillosis accounts for 12%-34% of nasal disease in dogs.¹ Clinical signs include chronic facial pain, mucopurulent to severe hemorrhagic nasal discharge, nasal planum depigmentation, lethargy, and poor appetite.² Because of high failure rates and adverse effects of hepatotoxicity with PO therapy, topical treatment is the standard of care for treatment. Clinical remission rates of 85%-94% are reported using a variety of techniques including trephination of

the frontal sinus, direct sinuscopy, use of antifungal solutions with prolonged (≥ 1 hour) contact time, and depot treatment using a cream formulation.³⁻⁷ When rhinoscopy, fungal culture, or both rather than clinical signs were used to define treatment success, remission and cure rates were lower than previously described.⁸

Although sinus trephination can be well tolerated, up to 20% of dogs experience adverse effects including discomfort, incision site infections, SC emphysema and leakage of antifungal medication under the skin, abscess formation, and penetration of skull resulting in

antifungal drug leakage around the brain and in the retro-bulbar space.^{2,3,5,9,10} Direct frontal sinuscopy allows for direct visualization and manual debridement of fungal plaques, which results in higher cure rates after a single treatment.¹¹ Direct debridement using frontal sinuscopy combined with depot treatment previously has been described in 8 of 43 dogs.⁵ In the remaining 35 dogs with computed tomography (CT) evidence of frontal sinus involvement, trephination was performed. Although the overall success rate in the study was 94%, the outcome of the 8 dogs with frontal sinus involvement that did not receive trephination was not specifically reported.

The combination of frontal sinuscopy with depot treatment combines the least invasive approach with the efficacy and decreased anesthesia time associated with depot treatment. Our objective was to evaluate the success rate, as determined by negative culture and histopathology, of topical treatment including direct visualization and debridement of the frontal sinus using sinuscopy and subsequent deposition of clotrimazole cream into the frontal sinus.

2 | MATERIALS AND METHODS

Sixteen dogs with sino-nasal aspergillosis that presented from December 2013 to June 2016 were retrospectively identified. Diagnostic criteria included evidence of a destructive rhinitis on CT imaging combined with at least 1 of the following: positive fungal culture, characteristic fungi identified on histopathology, and fungal plaques identified rhinoscopically. A fungal culture was considered positive based on colony and cellular morphology. Dogs were excluded if medical records were incomplete, if they were not given topical treatment using guidewire-assisted endoscopically-placed catheters, if they did not complete the full treatment, or if they had had a concurrent sinus or nasal neoplasm or foreign body. Four dogs were excluded, 1 for which treatment was declined, 1 that had clotrimazole placed directly into the nasal cavity rather than the frontal sinus, and 2 that received a single treatment. Of the latter 2 dogs, 1 was lost to follow-up after the first treatment and 1 was euthanized after the first treatment because the owners did not want to continue with topical treatment.

All 12 remaining dogs had routine hematology, serum biochemistry, a coagulation profile (prothrombin time, activated partial thromboplastin time, and fibrinogen assay), and buccal mucosal bleeding time performed before the first treatment. The dogs were anesthetized routinely and a CT scan (Siemens SOMATOM Definition AS, Siemens AG, Munich, Germany) was performed. A 6.5 mm (with 5 mm tip) flexible endoscope (Lucera GIF-XP260, Olympus, Center Valley, Pennsylvania) was used for both retrograde nasopharyngoscopy and anterograde rhinoscopy and sinuscopy. Biopsy specimens of an apparent fungal plaque or nearby region were collected for fungal culture and histopathology. If fungal plaques were identified (Figure 1), treatment for aspergillosis was performed.

The head was placed with the nose tilted down and the pharynx was packed with 2-4 absorbent sponges (Metro-pak dental sponges, Roots Vet Dental supplies, Hinckley, United Kingdom). Fungal plaques in the frontal sinus and nasal cavity were fragmented and loosened using biopsy forceps through the endoscope (Figure 1A). A 0.035 in

Basset (Straight Bentson guidewire, Infiniti Medical, Redwood City, California; straight Bentson) wire was introduced into the sinus via the endoscope biopsy channel (Figure 1B), and the scope was removed over the guidewire, leaving the guidewire in place. An 8F or 10F rigid canine urinary catheter (Portex Dog Catheter with female luer mount, Smiths Medical International, Hythe, Kent, United Kingdom) was trimmed so that the length approximated the distance from the nares to the frontal sinus plus an additional 2-3 cm. The catheter was passed over the wire into the frontal sinus; correct placement was confirmed endoscopically (Figure 1C). The frontal sinus then was irrigated vigorously through the catheter with 0.9% saline using a 60 mL syringe. Sinuscopy examination was performed alongside the catheter after irrigating with approximately 200-300 mL of saline. This process was repeated until no or minimal fungal plaques were detected endoscopically (Figure 2A). One-percent clotrimazole cream (Canesten 1% cream, Bayer, Hanover, New Jersey) warmed to body temperature (to ease passage through the catheter) was instilled via the catheter into the frontal sinus and nasal cavity (typically 50-70 g) until cream was seen to exit the external nares (Figure 2B). This procedure was repeated on both nasal cavities if the contralateral sinus was affected. If the contralateral frontal sinus was normal on CT scan and could not be accessed with the endoscope, the catheter was placed in the caudal nasal cavity under endoscope visualization and the cream instilled into the nasal cavity. The external nares were packed with large cotton swabs and the dog was placed in dorsal recumbency for 10 minutes to allow distribution of the cream to the dorsal wall of the frontal sinus. The patient was recovered with the nose tilted down and monitored closely to minimize the risk of aspiration. Analgesia (meloxicam 0.1 mg/kg [Metacam, Boehringer Ingelheim, St. Joseph, Missouri] PO q24hr) was given for 5 days after the procedure. Antibiotics were not given to any of the dogs.

This treatment regimen was repeated at 2-week intervals until there was no gross evidence of disease (Figure 2C). At this point, biopsies were repeated for histopathology and culture. The frontal sinus was not debrided or flushed, and clotrimazole cream was deposited through a catheter as previously described. Resolution of disease (cure) was defined as the absence of fungal plaques on repeat sinuscopy, negative fungal culture, and no fungal elements seen on histopathology.

3 | RESULTS

A total of 12 dogs were included. Breeds included Golden Retriever ($n = 4$), Border Collie ($n = 3$), Collie cross, Cockapoo, Dalmatian cross, Labrador Retriever, and Welsh Springer Spaniel. There were 9 males (1 intact) and 3 females (1 intact). Age at the time of diagnosis ranged from 1 to 13.5 years (mean, 6.7 years). Body weight ranged from 12.6 to 41.9 kg (median, 26.8 kg).

The median duration of clinical signs at presentation was 12 weeks, ranging from 3 to 48 weeks. Previous treatments before referral included antibiotics (12/12), itraconazole (2/12), meloxicam (4/12), corticosteroids (4/12), and chemotherapy (1/12, cyclophosphamide, doxorubicin, vincristine, and prednisolone protocol initiated because the biopsy specimen initially was misdiagnosed as nasal

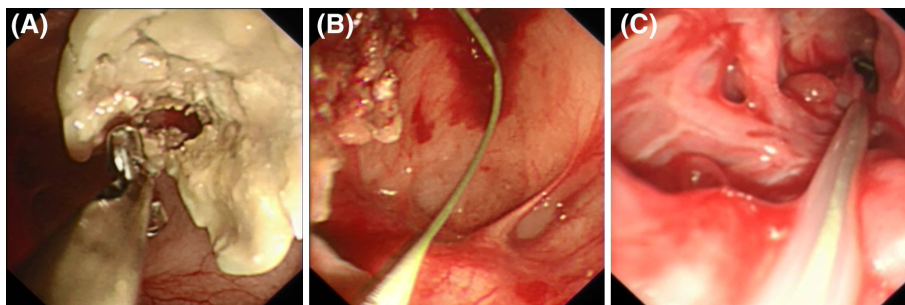


FIGURE 1 Frontal sinuscopy demonstrating fungal plaques and placement of flushing and treatment catheter. (A) Plaques are being fragmented and loosened using a biopsy forceps. (B) A 0.035 in Basset (straight Bentson) wire is placed into the frontal sinus through the biopsy channel of the flexible endoscope. The scope is then withdrawn over the guidewire, leaving the guidewire in place. (C) A rigid canine urinary catheter is trimmed to the appropriate length and inserted over the wire into the frontal sinus. The guidewire is then removed and the frontal sinus is flushed vigorously with 0.9% NaCl solution.

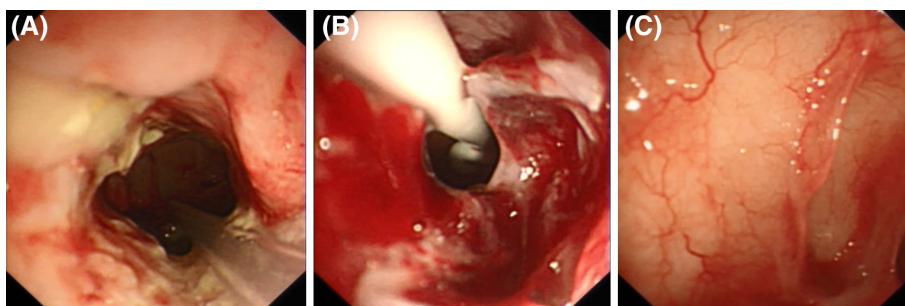


FIGURE 2 Frontal sinuscopy after debridement with instillation and follow-up endoscopy. (A) At the completion of manual debridement and flushing, the majority of fungal plaques have been flushed out. (B) Clotrimazole cream is instilled via the catheter into the frontal sinus. The sinus is filled until cream is observed to protrude out of the sinus. The flexible endoscope is gradually withdrawn as cream is continuously instilled, filling the nasal cavity. (C) After a single treatment in 1 dog, no fungal plaques are apparent in the frontal sinus. One final clotrimazole treatment is performed as previously described.

lymphoma). At the time of referral, the owners reported minimal or no response to the aforementioned treatments.

Dogs presented with the following clinical signs: nasal discharge (12/12, 7 unilateral and 5 bilateral), sneezing, reverse sneezing, or both (12/12), epistaxis (10/12), facial pain (4/12), and lethargy (3/12). Clinical examination disclosed submandibular lymph node enlargement (10/12), nasal depigmentation (5/12), mildly increased temperature (2/12), and nasal asymmetry (1/12).

Routine hematology, serum biochemistry, and coagulation profiles were normal in 11/12 dogs. Mild neutrophilia was recorded in 1 dog. The CT findings showed turbinate destruction, characteristic of sino-nasal aspergillosis, in all dogs as previously described.¹² Nasal turbinate destruction was unilateral in 5 dogs and bilateral in 7 dogs. Evidence of frontal sinus involvement (based on CT and sinuscopy) was established in 10/12 dogs. Of these 10 dogs, 7 had unilateral involvement. Three of these dogs had follow-up CT scans with no evidence of contralateral involvement and none of them developed clinical signs on the contralateral side. Three dogs had osteolytic changes within the left internal frontal bone with visible communication between the frontal sinus and the frontal lobe of the brain (defect size: 2 mm, 3.2 mm, and 9 mm). The dog with the 9 mm defect had meningeal enhancement (Figure 3). The dog with the 2 mm defect also had a cribriform plate defect of 4 mm.

In 11/12 dogs, fungal plaques were seen on rhinoscopy or sinuscopy: 2 on rhinoscopy only, 8 on sinuscopy only, and 1 on both

rhinoscopy and sinuscopy. In 11/12 dogs, fungal culture was positive for *Aspergillus* spp. In 8 dogs, characteristic fungi were seen on histopathology. Seven of 12 dogs were positive on culture and histopathology, with fungal plaques seen. In 3 dogs, culture and endoscopy were positive for *Aspergillus* spp., but histopathology was negative. One dog was diagnosed based on the presence of obvious fungal plaques alone (no culture or biopsy was performed). One dog was diagnosed based on positive culture and histopathology and characteristic CT changes without obvious fungal plaques.

Clinical signs improved or resolved after first treatment in 10/12 dogs. Nasal discharge resolved in 3/12, improved in 7/12, and remained unchanged in 2/12. Sneezing resolved in 8/12, improved in 2/12 and remained unchanged in 2/12. All dogs with epistaxis as a presenting clinical sign (10 dogs) had resolution of epistaxis after a single treatment. Facial pain resolved in 1/4 dogs after a single treatment.

All 12 dogs completed a full therapeutic course until resolution of disease was confirmed. Clinical remission was achieved after 1 treatment in 2/12, 2 treatments in 5/12, 3 treatments in 3/12, and 4 treatments in 2/12. The median number of treatments for remission was 2. In the 3 dogs with bilateral frontal sinus involvement, 4 treatments were required in 1 dog and 3 treatments in 2 dogs. The 2 dogs cured after a single treatment had minimal serous nasal discharge as the only persistent clinical sign, which resolved after the second (final) instillation of clotrimazole at the time cure was confirmed. In 11 dogs,

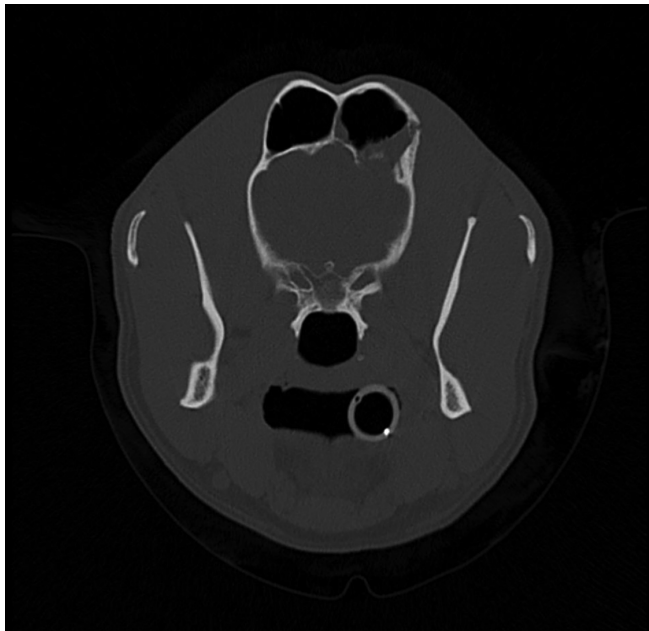


FIGURE 3 Frontal bone defect. Computed tomography image demonstrating osteolytic changes within the left internal frontal bone with visible communication between the frontal sinus and the frontal lobe of the brain.

histopathology and fungal culture were negative once no gross plaques were visualized. One dog was culture positive without gross evidence of fungal plaques or clinical signs typical for aspergillosis. One dog received an additional treatment beyond clinical remission because of clinician preference, for a total of 3 treatments. Time under anesthesia ranged from 75 to 115 minutes (median, 95 minutes) for the first treatment with a repeat treatment, range of 20 to 60 minutes (median, 35 minutes). Frontal sinuscopy of the affected sinus was possible in all 12 dogs and of the contralateral unaffected sinus in 2 dogs as a result of the nasal turbinate destruction. Adverse effects of treatment including a bloody or creamy nasal discharge for up to 1 week after treatment (typically 3-5 days with blood stopping by Day 3) and 2 dogs had an increase in reverse sneezing until cure. No serious adverse events were noted. At the time of remission, epistaxis and pain resolved in all dogs, minimal serous nasal discharge remained in 4/12 of the dogs and occasional sneezing was reported in 3/12 dogs.

The 3 dogs with potential central nervous system (CNS) involvement were treated with the same protocol and received 4 to 5 treatments (median, 4 treatments). Two of these dogs with potential CNS involvement also were given itraconazole (Sporanox, Janssen, Horsham, New Jersey) 5 mg/kg PO q24hr until resolution. All 3 dogs appeared endoscopically to have intact epithelium over the area where osteolysis was noted on CT scan, which increased clinician confidence to treat. In a dog with marked frontal bone osteolysis, a large piece of necrotic bone embedded into mucosa was removed by gentle traction from the floor of the sinus during the fourth treatment. Topical treatment was not performed during this treatment because of concerns about possible defects in the epithelium over the osteolytic area after removal of the necrotic bone fragment. Fungal culture

was negative at this stage, and no additional treatments were performed.

Sino-nasal aspergillosis recurred in 2 dogs. One dog had recurrence 2 months after completing the initial course of treatment (2 treatments) and received an additional 4 treatments for resolution of disease. This dog was in clinical remission for the 22 months available for follow-up. The other dog had recurrence 7 months after completion of the initial course of treatment (2 treatments). This dog was diagnosed with hyperadrenocorticism and a soft tissue sarcoma at the time of recurrence. The owner declined repeat topical treatment and PO itraconazole was prescribed. The remaining 10 dogs remained in remission until death from unrelated causes or until they were lost to follow-up. One dog was euthanized 2 months after remission because of a bladder tumor, and 1 died 13 months after remission of an unrelated cause. The remaining 8/12 remained in clinical remission during the follow-up period, that ranged from 4 to 33 months (median, 11.5).

4 | DISCUSSION

This minimally-invasive approach to treatment of sino-nasal aspergillosis was effective in resolving *Aspergillus* in all treated dogs with minimal morbidity, with a second course of treatment required in 2/12 dogs. All dogs completing the recommended topical treatment protocol were cured until the time of euthanasia (unrelated to sino-nasal aspergillosis) or were lost to follow-up. This finding compares favorably with previous reported remission rates up to 94%.⁵ Our treatment protocol incorporated confirmation of cure by frontal sinuscopy combined with negative culture and histopathology. Previous studies based success rates largely on clinical remission and therefore may overestimate the efficacy of treatment. Clinical signs are not necessarily indicative of disease status. Repeat biopsy and culture are required to confirm resolution, as evidenced by the 1 dog in our study that was positive on culture with no clinical signs and no gross evidence of disease.

The diagnosis of aspergillosis was based on a combination of evidence of gross disease, positive fungal culture, and positive histopathologic findings. One of the 12 dogs was diagnosed based on the presence of gross disease along with characteristic changes on the CT scan. As a retrospective study, culture and histopathology results were not available for all dogs. At the time of initial diagnosis, culture and histopathology were performed in 11/12 dogs; 1 dog was diagnosed based on the presence of fungal plaques and compatible CT changes. Three dogs were negative on histopathology despite having a positive fungal culture. The reason for this discrepancy is unclear, and attempts had been made to collect biopsy specimens near the plaque whenever possible. It is possible that culture is a more sensitive modality than biopsy for diagnosis of aspergillosis, although such a conclusion is beyond the scope of our study. In 11/12 dogs, cure was confirmed by negative culture and histopathology. For the remaining 1 dog, cure was presumed because no fungal plaques were seen endoscopically and clinical signs had resolved.

Our treatment failure rate of 17%, is similar to previously reported rates of 11%-20%.^{8,13,14} One of the 2 dogs was diagnosed with hyperadrenocorticism which may have predisposed to recurrence.

Previous studies that have used endoscopically-placed catheters have used a method that involves the biopsy forceps protruding from the endoscope and grasping a suture that is attached to the catheter.^{5,6,14,15} Although that technique is similarly minimally invasive, the forceps may induce trauma while being passed into the frontal sinus. Also, because both the endoscope and the catheter must simultaneously pass through the naso-frontal ostium, it may not be possible in some dogs in which the ostium is not large enough. We were able to successfully access and treat the affected frontal sinus in all dogs endoscopically, even where the ostium was narrow.

Three dogs with potential CNS involvement (based on CT scan results) and with intact mucosal epithelium covering the defect were treated using the same protocol (in addition to PO itraconazole in 2 dogs) for a total of 13 treatments, with no complications. This included 1 dog with a fairly large 9 mm defect and secondary meningeal enhancement. The remaining defects were small to moderate (up to 4 mm). Previous reports describe a total of 10 dogs with CNS involvement treated with topical antifungal medication with no complications.^{5,8,12} Although our treatment protocol appears to be safe for dogs with frontal bone or cribriform plate destruction, further assessment with increased numbers of patients would be required to definitively determine safety.

In unilateral disease where there was no destruction on the contralateral side, it was not possible in most dogs to perform frontal sinuscopy on the apparently unaffected side. CT scans showed no evidence of disease and in those dogs that had follow-up CT scans; no disease process became evident in the unaffected sinuses and no dog developed clinical signs on the contralateral side.

In summary, minimally-invasive debridement and depot treatment appears to be an effective and well-tolerated technique for the treatment of sino-nasal aspergillosis in dogs, with minimal morbidity and a cure rate of up to 100%.

ACKNOWLEDGMENTS

The authors acknowledge all the staff and owners involved in the care of these cases. The authors also thank Dr Ian Handel, Dr Richard Melanby, and Dr Craig Breheny for their contributions to this project.

CONFLICT OF INTEREST DECLARATION

Authors declare no conflict of interest.

OFF-LABEL ANTIMICROBIAL DECLARATION

Authors declare no off-label use of antimicrobials.

INSTITUTIONAL ANIMAL CARE AND USE COMMITTEE (IACUC) OR OTHER APPROVAL DECLARATION

Authors declare no IACUC or other approval was needed.

ORCID

Tracy L. Hill  <https://orcid.org/0000-0001-5701-9704>

REFERENCES

1. Sharp NJ, Harvey C, O'Brien J. Treatment of canine nasal aspergillosis/penicilliosis with fluconazole. *J Small Anim Pract.* 1991;32:513-516.
2. Sharman MJ, Mansfield CS. Sinonasal aspergillosis in dogs: a review. *J Small Anim Pract.* 2012;53:434-444.
3. Sissener TR, Bacon NJ, Friend E, Anderson DM, White RA. Combined clotrimazole irrigation and depot therapy for canine nasal aspergillosis. *J Small Anim Pract.* 2006;47:312-315.
4. Billen F, Guieu LV, Bernaerts F, et al. Efficacy of intranasal administration of bifonazole cream alone or in combination with enilconazole irrigation in canine sino-nasal aspergillosis: 17 cases. *Can Vet J.* 2010;51:164-168.
5. Hazuchova K, Neiger R, Stengel C. Topical treatment of mycotic rhinitis-rhinosinusitis in dogs with meticulous debridement and 1% clotrimazole cream: 64 cases (2007-2014). *J Am Vet Med Assoc.* 2017;250:309-315.
6. McCullough SM, McKiernan BC. Endoscopically placed tubes for administration of enilconazole for treatment of nasal aspergillosis in dogs. *J Am Vet Med Assoc.* 1998;212:67-69.
7. Mathews KG, Davidson AP, Koblik PD, et al. Comparison of topical administration of clotrimazole through surgically placed versus nonsurgically placed catheters for treatment of nasal aspergillosis in dogs: 60 cases (1990-1996). *J Am Vet Med Assoc.* 1998;213:501-506.
8. Pomrantz JS, Johnson LR. Repeated rhinoscopic and serologic assessment of the effectiveness of intranasally administered clotrimazole for the treatment of nasal aspergillosis in dogs. *J Am Vet Med Assoc.* 2010;236:757-762.
9. Bray JP, White RA, Lascelles BD. Treatment of canine nasal aspergillosis with a new non-invasive technique. Failure with enilconazole. *J Small Anim Pract.* 1998;36:223-226.
10. Burrow R, Baker M, White L, McConnell JF. Trephination of the frontal sinuses and instillation of clotrimazole cream: a computed tomographic study in canine cadavers. *Vet Surg.* 2013;42:322-328.
11. Girod M, Goosens D, Volpe CC, Billen F. Comparison of two non-invasive 2% enilconazole infusion protocols for treatment of canine sinonasal aspergillosis and importance of debridement for treatment efficacy. In Research Communications of the 25th ECVIM-CA Congress. *J Vet Intern Med.* 2016;30:378.
12. Saunders JH, Duchateau L, Störk C, Van Bree H. Use of computed tomography to predict the outcome of a non-invasive intranasal infusion in dogs with nasal aspergillosis. *Can Vet J.* 2003;44:305.
13. Sharp NJ, Sullivan M, Harvey CE, Webb T. Treatment of canine nasal aspergillosis with enilconazole. *J Vet Intern Med.* 1993;7:40-43.
14. Schuller S, Clercx C. Long-term outcomes in dogs with sinonasal aspergillosis treated with intranasal infusions of enilconazole. *J Am Anim Hosp Assoc.* 2007;43:33-38.
15. Zonderland JL, Störk CK, Saunders JH, Hamaide AJ, Balligand MH, Clercx CM. Intranasal infusion of enilconazole for treatment of sinonasal aspergillosis in dogs. *J Am Vet Med Assoc.* 2002;221:1421-1425.

How to cite this article: Ballber C, Hill TL, Bommer NX. Minimally invasive treatment of sino-nasal aspergillosis in dogs. *J Vet Intern Med.* 2018;32:2069-2073. <https://doi.org/10.1111/jvim.15311>