

## Single incision laparoscopic cholecystectomy using Konyang Standard Method

Jong Il Son<sup>1</sup>, In Seok Choi<sup>1,2</sup>, Ju Ik Moon<sup>1</sup>, Yu Mi Ra<sup>1</sup>, Sang Eok Lee<sup>1</sup>, Won Jun Choi<sup>1</sup>, Dae Sung Yoon<sup>1</sup>

<sup>1</sup>Department of Surgery, Konyang University Hospital, Konyang University College of Medicine, Daejeon, <sup>2</sup>Konyang University Myunggok Medical Research Institute, Daejeon, Korea

**Purpose:** Single incision laparoscopic cholecystectomy (SILC) is a minimally invasive surgery that is growing rapidly among surgical procedures. However, there is no standard method for SILC. Therefore, we evaluated the adequacy and feasibility of SILC using Konyang Standard Method.

**Methods:** We retrospectively reviewed our series of 307 SILCs performed between April 2010 and August 2012. Initially we excluded the patients who were more than 70 years old, had cardiologic or pulmonologic problems and complications of acute cholecystitis. After 50 cases, we did not apply the exclusion criteria. We performed SILC by Konyang Standard Method using three-trocar single port (hand-made) and long articulated instruments.

**Results:** Three hundred and seven patients underwent SILC. Male were 131 patients and female were 176 patients. Mean age was  $51.6 \pm 13.7$  years old and mean body mass index was  $24.8 \pm 3.6$  kg/m<sup>2</sup>. Ninety-three patients had histories of previous abdominal operation. Patient's pathologies included: chronic cholecystitis (247 cases), acute cholecystitis (30 cases), gall bladder (GB) polyps (24 cases), and GB empyema (6 cases). Mean operating time was  $53.1 \pm 25.4$  minutes and mean hospital stay was  $2.9 \pm 3.4$  days. There were four cases of 3–4 ports conversion due to cystic artery bleeding. Complications occurred in 5 cases including wound infection (2 cases), bile duct injury (1 case), duodenal perforation (1 case), and umbilical hernia (1 case).

**Conclusion:** SILC using Konyang Standard Method is safe and feasible. Therefore, our standard procedure can be applied to almost all benign GB disease.

[Ann Surg Treat Res 2014;86(4):177-183]

**Key Words:** Laparoscopic cholecystectomy, Konyang Standard Method

### INTRODUCTION

Laparoscopic surgery has been progressing with the development of surgical instruments and techniques. Since the introduction of laparoscopic surgery, multiport laparoscopic cholecystectomy has been recognized as the gold standard for treatment of benign gallbladder disease [1]. Many surgeons have attempted to reduce the size and the number of incisions [2], and several types of single incision procedures have been performed by general surgeons. Single incision laparoscopic

surgery was described as early as in 1992 by Pelosi and Pelosi 3rd [3] who performed single-puncture laparoscopic appendectomy, and in 1997, by Navarra et al. [4] who performed laparoscopic cholecystectomy via two transumbilical trocars and three transabdominal gallbladder stay sutures. Furthermore, several reports have been demonstrated the advantages of single port laparoscopic surgery in different patients and clinical situations [5], therefore attracting many surgeons to single incision laparoscopic cholecystectomy (SILC).

In the last few years, many centers in the world have reported

Received October 1, 2013, Revised December 2, 2013, Accepted December 13, 2013

**Corresponding Author: In Seok Choi**

Department of Surgery, Konyang University Hospital, Konyang University College of Medicine, Konyang University Myunggok Medical Research Institute, 158 Gwanjeodong-ro, Seo-gu, Daejeon 302-718, Korea

Tel: +82-42-600-8833, Fax: +82-42-543-8956

E-mail: choiins@kyuh.ac.kr

Copyright © 2014, the Korean Surgical Society

© Annals of Surgical Treatment and Research is an Open Access Journal. All articles are distributed under the terms of the Creative Commons Attribution Non-Commercial License (<http://creativecommons.org/licenses/by-nc/3.0/>) which permits unrestricted non-commercial use, distribution, and reproduction in any medium, provided the original work is properly cited.

successful attempts at performing SILC. Results have indicated reduced postoperative pain, early return to work, improve cosmetic outcomes [6], and in several studies, SILC reduced the risk of trocar-related complication such as incisional hernia or infection [7]. However, with the exception of the obvious cosmetic result, several benefits of SILC are not quite clear. Also, many reports have only recommended SILC for symptomatic cholelithiasis cases which excluded complicated gallbladder disease, because of operative difficulties and lack of adapted instruments. And, so far there is no standard method for the SILC. Therefore, in this study, we evaluated an adequacy and feasibility of SILC using Konyang Standard Method.

## METHODS

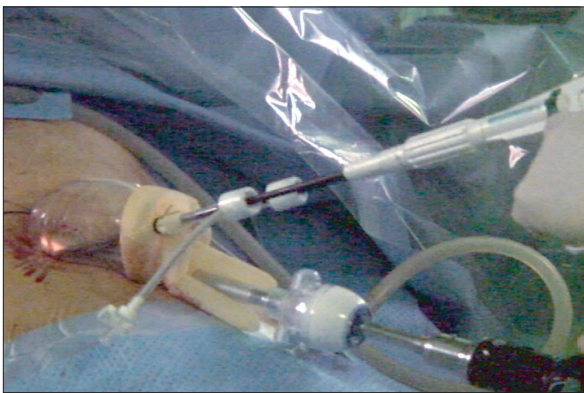We retrospectively reviewed our series of 307 SILC performed between April 2010 and August 2012. All patients underwent surgery after obtaining an informed consent. Initially we excluded the patients who with age greater than 70, cardiologic or pulmonologic problems, cystic duct abnormalities and complications of acute cholecystitis. After 50 cases, as our experience with technique improved, the inclusion criteria of SILC evolved to include all patients who would typically be considered for conventional laparoscopic cholecystectomy (CLC). Therefore, the only exclusion criterion was; suspicion of malignancy. We performed SILC by Konyang Standard Method using three-trocar single port (hand-made) and long articulated instruments.

### Surgical technique

The standardized procedure is called "Konyang Standard Method" which is composed of traction, dissection, isolation, ligation, and dissection from gall bladder (GB) bed.

#### Instruments & port

Hand-made port was constructed from a 10-mm size ALEXIS



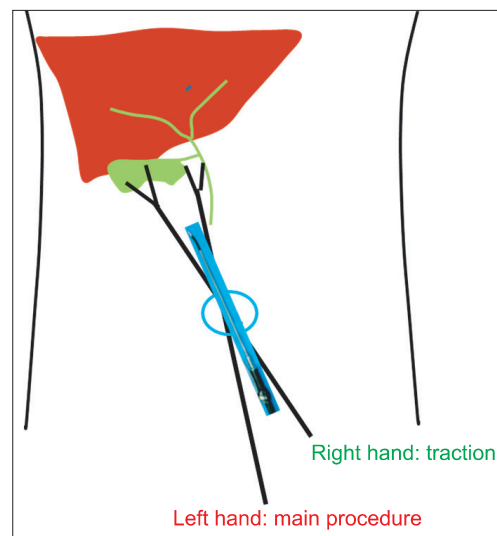
**Fig. 1.** Hand-made port and the long articulated Endo-rotator.

wound retractor (Applied Medical, Rancho Santa Margarita, CA, USA) and a size-7 sterile glove in which three or two 5-mm ports and one 10-mm port (Laport, Sejong Medical, Paju, Korea) were prepared on the tip of fingers to create a working channel for the laparoscopic instruments. The wound retractor was introduced through the transumbilical incision. The surgical glove was fixed to the outer ring of the wound retractor, then the CO<sub>2</sub> pipe was connected to 10-mm port, and then pneumoperitoneum was made. We used a flexible telescope (Olympus, Tokyo, Japan), a long articulated Endo-Rotator (Covidien, Mansfield, MA, USA) for traction and dissection, and a suction-hook bovies (Endopath Probe Plus II Pistol Grip handle, Ethicon, Bridgewater, NJ, USA) for irrigation and coagulation. We ligated cystic duct and artery using 5-, 10-mm hem-o-lok clips (Weck Closure Systems, Research Triangle Park, NC, USA) (Fig. 1)

#### Method

Patient was placed in reverse Trendelenburg position (15°–30°) and rotated right up. The surgeon stood on the left side of the patient. The first assistant who played the role of scopist stood below the surgeon and the second assistant who was to help with insertion and angulation of instruments stood on the right of the patient. All instruments were inserted by right side of the telescope. Surgeon used right hand for traction, left hand for main surgery. (Fig. 2)

*Traction:* Cephalic traction on the fundus of the gallbladder by right hand (grasper) and lateral traction on the infundibulum of the gallbladder by left hand (dissector) is the best way for identification of the cystic duct. After identification of the cystic duct at its junction with the gallbladder, lateral traction of the gallbladder by right hand place the cystic duct perpendicular to

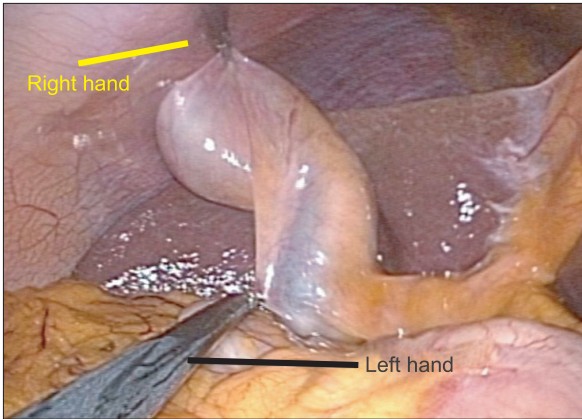

**Fig. 2.** Schematic diagram of single incision laparoscopic cholecystectomy.

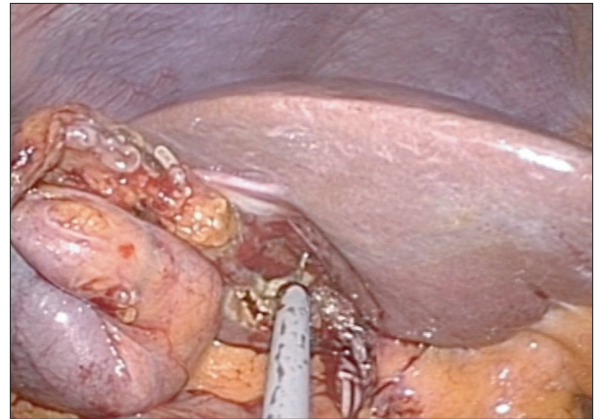
the common bile duct (CBD) (Fig. 3).

*Dissection:* Anterior peritoneum is dissected by the left hand using a dissector. After that, the left hand performed the

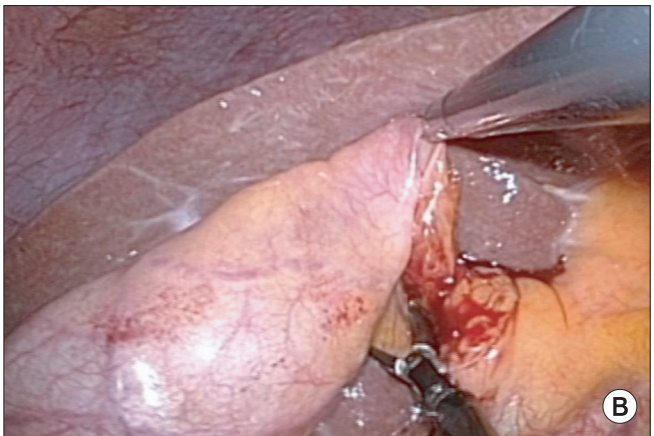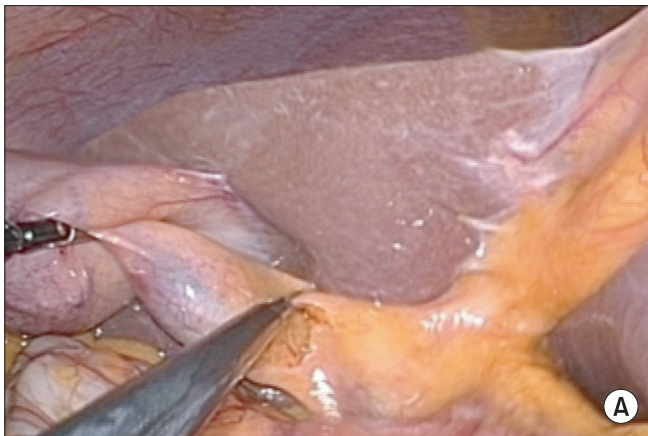
cephalic traction of the infundibulum and exposure posterior peritoneum of the cystic duct, and then the right hand grasper carried out the posterior peritoneal dissection. Cystic duct and



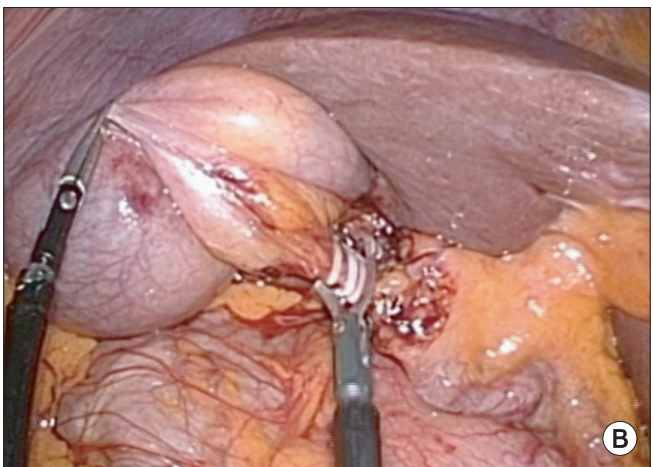
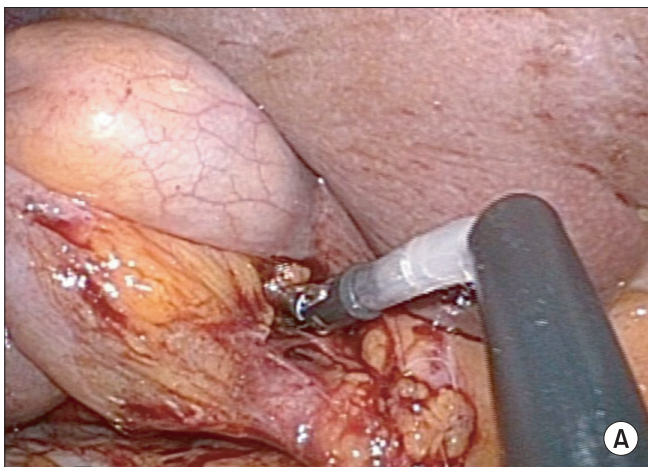
**Fig. 3.** “Cephalic traction” on the fundus and “lateral traction” on the infundibulum of the gallbladder.



**Fig. 6.** Dissection of the gallbladder off the liver bed using suction-hook bovie devices.



**Fig. 4.** Exposure of the Calot's Triangle. (A) Anterior dissection, (B) posterior dissection of peritoneum of cystic duct.



**Fig. 5.** Isolation and division of cystic duct and artery. (A) Isolation of the cystic duct and artery using 30°–50° angulated dissector, (B) division of the cystic duct and artery.

artery are dissected free of the underlying fat and connective tissue (Fig. 4).

**Isolation and division:** After dissection of posterior peritoneum of the cystic duct, lateral traction of the gallbladder by the right hand was performed to place the cystic duct perpendicular to the CBD. Isolation of the cystic duct and artery using 30°–50° angulated dissectors on the left hand was performed. After isolation, the cystic duct and artery are clipped using 5-mm hem-o-lok on the left hand and the cystic duct and artery were divided using scissors on the left hand (Fig. 5).

**Dissection of GB bed:** After cystic artery and duct being divided, The GB was pulled in cephalic way using grasper held in the right hand and then GB was dissected from GB bed by suction-hook bovie on the left hand. After cholecystectomy, irrigation was done by the right hand using the suction-hook bovie (Fig. 6).

## RESULTS

### Preoperative clinical characteristics

The patient's preoperative clinical characteristics of undergoing SILC are shown in Table 1. Three hundred and seven patients were underwent SILC during this study period, consisting of 131 male patients and 176 female patients. Mean age was  $51.6 \pm 13.7$  years old and mean body mass index (BMI) was  $24.8 \pm 3.6$  kg/m<sup>2</sup>. Ninety-three patients had a history of previous abdominal surgery. Among the 93 patients, 6 (6.5%) underwent upper abdominal surgery. Pathologic data were available for

**Table 1.** Preoperative clinical characteristics of all patients undergoing SILC (n = 307)

Characteristic	Value
Age (yr)	51.6 ± 13.7 (16.0–85.0)
Gender	
Male	131 (42.7)
Female	176 (57.3)
Body mass index (kg/m <sup>2</sup> )	24.8 ± 3.6 (15.9–40.8)
Previous OP history	
No	214 (69.8)
Yes	93 (30.2)
PTGBD insertion	
No	282 (91.9)
Yes	25 (8.1)
Pathologic diagnosis	
Acute cholecystitis	30 (9.8)
Chronic cholecystitis	247 (80.5)
Gallbladder polyp	24 (7.8)
Gallbladder empyema	6 (1.9)

Values are presented as mean ± standard deviation (range) or number (%).

SILC, single incision laparoscopic cholecystectomy; OP, operation; PTGBD, percutaneous transhepatic gallbladder drainage.

all patients. Among the study group, 247 patients (80.5%) had chronic cholecystitis, 30 patients (9.8%) had acute cholecystitis, 24 patients (7.8%) had gallbladder polyp, 6 patients (2%) had GB empyema.

### Operative and postoperative outcomes

Mean operating time was  $53.1 \pm 25.4$  minutes, average length of hospital stay was 2.9 days, and average blood loss was 25 mL (Table 2). There were four conversions to three (3 cases) or four (1 case) port, because of cystic artery bleeding. There was no open conversion. In five cases (1.6%), Hemo-vac drain was placed in subhepatic space.

### Postoperative complications

There were 5 patients with postoperative complications (Table 3). Wound infection in 2 cases, bile duct injury in 1 case, duodenal perforation in 1 case, incisional hernia in 1 case. However, there was no mortality. Among those who developed complications, one patient with severe GB inflammation had major bile duct injury (Strasberg's classification type E [8]) which was recognized at the second postoperative day and hepaticojejunostomy was performed. In addition, duodenal

**Table 2.** Operative and postoperative outcomes of all patients undergoing SILC (n = 307)

Variable	Value
Hemo-vac insertion	
No	302 (98.4)
Yes	5 (1.6)
Operation time (min)	53.1 ± 25.4 (10–320)
Conversion	
3 Port	3 (1.0)
4 Port	1 (0.3)
Open	0 (0)
Bleeding (mL)	25.0 ± 55.3 (0–900)
Hospital stay (day)	2.9 ± 3.4 (1–35)

Values are presented as number (%) or mean ± standard deviation (range).

SILC, single incision laparoscopic cholecystectomy.

**Table 3.** Postoperative complication of all patients undergoing SILC (n = 307)

	Value
Complication	5 (1.6)
Wound infection	2 (0.7)
Bile duct injury	1 (0.3)
Duodenal perforation	1 (0.3)
Incision hernia	1 (0.3)

Values are presented as number (%).

SILC, single incision laparoscopic cholecystectomy.

perforation occurred in one patient that had undergone subtotal gastrectomy previously. We suspect that the complication could have occurred from dissection of duodenum attached to the liver. The patient underwent reoperation due to peritonitis at the second operative day. Reoperation was performed with laparoscopic primary repair of duodenal perforation site. In addition, there were two cases of surgical wound infection. Among these patients, one patient developed incisional hernia after three months, which was corrected by herniorrhaphy.

## DISCUSSION

Laparoscopic surgery is a well-established alternative to open surgery. Many surgeons consider laparoscopic cholecystectomy to be the standard treatment for patients with benign gallbladder disease [1]. The result of laparoscopic cholecystectomy compare favorably to those for open cholecystectomy, because of decreased pain, shorter hospital stay and better cosmetic outcomes [9].

In an attempt to achieve better outcomes, surgeons have been successful in decreasing the number of ports for laparoscopic cholecystectomy. Many technical developments have been proposed to achieve further improvement in postoperative outcomes by reducing the port size and number. In recent year, many centers have published reports about their experiences with SILC. The SILC can predict better cosmetic outcome, reduce postoperative pain due to less operative trauma and quick recovery [10]. However, the superiority of the SILC compared to the CLC is still controversial.

Han et al. [11] reported SILC to be feasible and safe in selected patients with uncomplicated gallstone disease or gallbladder polyp [11]. And because of relatively high conversion rate to CLC, increased complications (bile leak by GB rupture, wound infection, bile duct injury), and prolonged operating time, SILC was not recommended in patients who have a high BMI or acute cholecystitis with complication (GB empyema, GB perforation) [12]. Erbella and Bunch [13] thought that patients with a lower BMI, early disease or no previous abdominal surgery would be ideal candidates for SILC. And Han et al. [11] demonstrated that SILC could be excluded patients with acute cholecystitis, previous upper abdominal surgery, suspected presence of CBD or intrahepatic duct stones, and suspected gallbladder malignancy. Initially, the inclusion criteria of SILC limited eligible subjects to favorable surgical candidates who are young women with minimal signs of inflammation of GB. However, by accumulation of our experiences and standardization of the method, the inclusion criteria evolved to include all patients who would typically be considered for CLC. Therefore, it was shown that SILC can be carried out even in patients with serious medical problems or complications of acute cholecystitis such as GB empyema. However, GB perforation in CLC was

3.5% (noncomplicated) and GB perforation in SILC occurred in 9.6%. SILC may have inadvertently increased the chance of GB perforation [14]. So we propose that patients who suspected malignancy were performed by CLC. In many studies, SILC was contraindicated in patients had been underwent abdominal surgery. But we performed SILC in 93 patients who had been underwent abdominal surgery, including upper abdominal surgery in six patients. If operative field could be secured through umbilical incision, SILC could be applied to these select patients.

Many centers have introduced various procedures and instruments of SILC. Podolsky et al. [15] demonstrated single port access cholecystectomy, which was performed through a single umbilical incision within the umbilicus. Then three trocars and a rigid grasper were inserted through separate fascial sites within the same skin incision to perform the procedure. Ceci et al. [16] used a SILC port (Covidien) and traditional laparoscopic instrument in all cases, where as in our center we performed SILC by hand-made port that have several advantages. It is easy to use and can be simply accommodated to the abdominal wall. Many commercial ports have three or four working channel, whereas 4 or 5 channel port is made for liver traction with snake retractor or for ligation of thick cystic duct with 10-mm hem-o-lok clip. In addition, a wide axis of movements is possible, so the instruments can be used apart, easily crossed or rotated as required in any situation. However, the hand-made port requires a long time to be made during operation, and there is some inconvenience during insertion of instruments through umbilical incision. The using of articulated instruments and flexible telescope is important, which would avoid the interference with each other and help to perform more meticulous dissection of cystic duct and artery.

If SILC become the gold standard of procedure, it is not only better cosmetics, shorter hospital stay, decreased pain, but also lower incidence in bile leakage, duct injury, incisional hernia and organ damage. However, there is no available study including accurate incidence of complications, especially of bile duct injury. Unfortunately, the widespread application of LC has led to concurrent rise in the incidence of bile duct injuries. Compared with open cholecystectomy, the incidence of biliary injuries in CLC has doubled from 0.2% to 0.4% and remained constant despite the advances in knowledge, technique and technology [17-19]. To prevent bile duct injury, Hugh [20] recommends identifying Rouviere's sulcus. Also, Hunter [21] and Troidl [22] have proposed several techniques to prevent the injury: a 30' telescope, avoidance of approach close to the common hepatic duct, dissection close to the gallbladder-cystic duct-common hepatic duct junction, and conversion to an open approach when uncertain. We had one case of bile duct injury which was occurred by failure to identify location of cystic duct due to severe inflammation of gallbladder. Recently, traction of

liver by snake retractor which is inserted through a 4-channel port can prevent bile duct injury and provide proper exposure of cystic duct and artery. Therefore, it can minimize bile duct injury and be used for extensive indications of SILC.

Several published reports have focused on postoperative herniation in laparoscopic surgery. The consensus is that an incision located in midline with larger size has a higher risk of herniation, especially in the perinavel area [23]. In our experience, there was one incisional hernia after 3 months. The suture of incisional site could also be a concern, and sterile techniques should be strictly practiced to prevent wound infection.

Sasaki et al. [24] demonstrated that SILC required additional ports for acute cholecystitis compare to chronic calculous cholecystitis. Also, Rao et al. [25] thought that SILS would be possible to start as a single port procedure and add extra needles or ports for retraction as needed. In our experience, of the 307 cases of SILC, four cases were converted to CLC. The main reason for conversion to CLC was cystic artery bleeding. Therefore, the cystic artery was first exposed, then separately clipped with a 5-mm hem-o-lok clip and divided with scissors. After that, cystic duct was dissected and divided. We thought that cystic artery bleeding could be prevented by this method. After accumulation of our experience, SILC is becoming the

standard of care for most of our elective patients with benign gallbladder disease.

In conclusion, with the accumulation of experience and the development of instruments, SILC may be recognized as an alternative for CLC in almost all benign gallbladder diseases. We documented the feasibility and the safety of SILC. There seems to be no typical limitation and there are no potential increased complication and operating time with SILC compared to CLC. It is likely to gain popularity among patients and surgeons alike due to its benefits (less scar, minimal pain, lower incidence of port-related complications etc.). Therefore, almost all benign disease of gallbladder can be applied to the SILC using Konyang Standard Method.

## CONFLICTS OF INTEREST

No potential conflict of interest relevant to this article was reported.

## ACKNOWLEDGEMENTS

This work was supported (in part) by Konyang University Myunggok Research Fund of 2010.

## REFERENCES

- Begos DG, Modlin IM. Laparoscopic cholecystectomy: from gimmick to gold standard. *J Clin Gastroenterol* 1994;19:325-30.
- Curcillo PG 2nd, Wu AS, Podolsky ER, Graybeal C, Katkhouda N, Saenz A, et al. Single-port-access (SPA) cholecystectomy: a multi-institutional report of the first 297 cases. *Surg Endosc* 2010;24:1854-60.
- Pelosi MA, Pelosi MA 3rd. Laparoscopic appendectomy using a single umbilical puncture (minilaparoscopy). *J Reprod Med* 1992;37:588-94.
- Navarra G, Pozza E, Occhionorelli S, Carcoforo P, Donini I. One-wound laparoscopic cholecystectomy. *Br J Surg* 1997;84:695.
- Hernandez JM, Morton CA, Ross S, Albrink M, Rosemurgy AS. Laparoendoscopic single site cholecystectomy: the first 100 patients. *Am Surg* 2009;75:681-5.
- Bucher P, Pugin F, Buchs N, Ostermann S, Charara F, Morel P. Single port access laparoscopic cholecystectomy (with video). *World J Surg* 2009;33:1015-9.
- Duron VP, Nicastrì GR, Gill PS. Novel technique for a single-incision laparoscopic surgery (SILS) approach to cholecystectomy: single-institution case series. *Surg Endosc* 2011;25:1666-71.
- Strasberg SM, Hertl M, Soper NJ. An analysis of the problem of biliary injury during laparoscopic cholecystectomy. *J Am Coll Surg* 1995;180:101-25.
- Leandros EI, Alexakis N, Archontovasilis F, Albanopoulos K, Dardamanis D, Menenakos E, et al. Outcome analysis of laparoscopic cholecystectomy in patients aged 80 years and older with complicated gallstone disease. *J Laparoendosc Adv Surg Tech A* 2007;17:731-5.
- Qiu Z, Sun J, Pu Y, Jiang T, Cao J, Wu W. Learning curve of transumbilical single incision laparoscopic cholecystectomy (SILS): a preliminary study of 80 selected patients with benign gallbladder diseases. *World J Surg* 2011;35:2092-101.
- Han HJ, Choi SB, Kim WB, Choi SY. Single-incision multiport laparoscopic cholecystectomy: things to overcome. *Arch Surg* 2011;146:68-73.
- Lai EC, Yang GP, Tang CN, Yih PC, Chan OC, Li MK. Prospective randomized comparative study of single incision laparoscopic cholecystectomy versus conventional four-port laparoscopic cholecystectomy. *Am J Surg* 2011;202:254-8.
- Erbella J Jr, Bunch GM. Single-incision laparoscopic cholecystectomy: the first 100 outpatients. *Surg Endosc* 2010;24:1958-61.
- Hassan AM, Hedaya MS, Nasr MM, Nafeh AI, Elsebae MM. Single incision transumbilical laparoscopic cholecystectomy using conventional laparoscopic instru-

- ments: initial experience of single institute. *J Egypt Soc Parasitol* 2011;41:675-84.
15. Podolsky ER, Rottman SJ, Curcillo PG 2nd. Single port access (SPA) cholecystectomy: two year follow-up. *JSLs* 2009;13:528-35.
  16. Ceci F, Di Grazia C, Cipriani B, Nicodemi S, Corelli S, Pecchia M, et al. Cholecystectomy by single incision laparoscopic surgery (SILS): early experience and technique standardization. *G Chir* 2012; 33:280-4.
  17. Flum DR, Cheadle A, Prella C, Dellinger EP, Chan L. Bile duct injury during cholecystectomy and survival in medicare beneficiaries. *JAMA* 2003;290:2168-73.
  18. Nuzzo G, Giuliante F, Giovannini I, Ardito F, D'Acapito F, Vellone M, et al. Bile duct injury during laparoscopic cholecystectomy: results of an Italian national survey on 56 591 cholecystectomies. *Arch Surg* 2005;140:986-92.
  19. Waage A, Nilsson M. Iatrogenic bile duct injury: a population-based study of 152 776 cholecystectomies in the Swedish Inpatient Registry. *Arch Surg* 2006;141: 1207-13.
  20. Hugh TB. New strategies to prevent laparoscopic bile duct injury: surgeons can learn from pilots. *Surgery* 2002;132:826-35.
  21. Hunter JG. Avoidance of bile duct injury during laparoscopic cholecystectomy. *Am J Surg* 1991;162:71-6.
  22. Troidl H. Disasters of endoscopic surgery and how to avoid them: error analysis. *World J Surg* 1999;23:846-55.
  23. Helgstrand F, Rosenberg J, Bisgaard T. Trocar site hernia after laparoscopic surgery: a qualitative systematic review. *Hernia* 2011;15:113-21.
  24. Sasaki K, Watanabe G, Matsuda M, Hashimoto M. Original single-incision laparoscopic cholecystectomy for acute inflammation of the gallbladder. *World J Gastroenterol* 2012;18:944-51.
  25. Rao PP, Bhagwat SM, Rane A, Rao PP. The feasibility of single port laparoscopic cholecystectomy: a pilot study of 20 cases. *HPB (Oxford)* 2008;10:336-40.