

Magnetic Resonance Imaging of the Cervical, Thoracic, and Lumbar Spine in Children: Spinal Incidental Findings in Pediatric Patients

Uma E. Ramadorai¹ Justin M. Hire¹ John G. DeVine¹

¹Department of Orthopaedics and Rehabilitation, Dwight D. Eisenhower Army Medical Center, Fort Gordon, Georgia, United States

Address for correspondence Justin M. Hire, MD, Department of Orthopaedics and Rehabilitation, Dwight D. Eisenhower Army Medical Center, 300 Hospital Road, Fort Gordon, GA 30905, United States (e-mail: justin.m.hire.mil@mail.mil).

Global Spine J 2014;4:223–228.

Abstract

Study Design Retrospective case series.

Objective To determine the rate of spinal incidental findings on magnetic resonance imaging (MRI) of the cervical, thoracic, and lumbar spine in the pediatric population.

Methods We reviewed MRI imaging of the neuraxial spine in patients less than 18 years of age and documented abnormal spinal findings. We then reviewed the charts of these patients to determine the reason for ordering the study. Those who presented with pain were considered symptomatic. Those who had no presenting complaint were considered asymptomatic. The data were analyzed to break down the rate of spinal incidental findings in the cervical, thoracic, and lumbar spine, respectively.

Results Thirty-one of the 99 MRIs had positive findings, with the most common being disk protrusion (51.6%). Spinal incidental findings were most common in the lumbar spine (9.4%) versus the cervical spine (8%) or thoracic spine (4.7%). In this group, Schmorl nodes and disk protrusion were the two most common findings (37.5% each). Other spinal incidental findings included a vertebral hemangioma and a Tarlov cyst. In the thoracic spine, the only spinal incidental finding was a central disk protrusion without spinal cord or nerve root compression.

Conclusion MRI is a useful modality in the pediatric patient with scoliosis or complaints of pain, but the provider should remain cognizant of the potential for spinal incidental findings.

Keywords

- ▶ pediatric
- ▶ children
- ▶ magnetic resonance imaging (MRI)
- ▶ spinal incidental findings
- ▶ Schmorl nodules

Introduction

Magnetic resonance imaging (MRI) of the spine is commonly utilized in establishing a diagnosis of the pediatric patient with neck and back complaints. It offers excellent visualization of the vertebral body, ligaments, disk, and neural elements and is a valuable tool in the assessment of the pediatric patient with a neurologic complaint or abnormal neurologic examination. MRI of the entire spine is also used as a screening tool in the patient with juvenile scoliosis or with a nonidiopathic scoliotic curve.

In the adult population, MRI is a useful adjunct to the history and physical examination to arrive at a diagnosis. Several studies have investigated the rate of abnormal findings in the asymptomatic patient, and results suggest that, although sensitive, MRI may not be the most specific imaging modality in adults. To our knowledge, no studies have specifically investigated the rate of spinal incidental MRI findings in the pediatric population or the rate of positive and negative findings in symptomatic patients. We aim to determine the rate of spinal incidental findings in asymptomatic pediatric

received
March 10, 2014
accepted after revision
June 23, 2014
published online
August 5, 2014

© 2014 Georg Thieme Verlag KG
Stuttgart · New York

DOI <http://dx.doi.org/10.1055/s-0034-1387179>
ISSN 2192-5682.

patients, as well as the rate of negative findings in symptomatic patients. We then compare this with the adult population as based on available literature.

Materials and Methods

The study protocol was approved by the local Institutional Review Board. MRI obtained at a single institution from 2006 to 2011 of the cervical, thoracic, and lumbar spine in patients less than 18 years of age were read by both a board-certified radiologist and fellowship-trained, board-certified orthopedic spine surgeon. Any disagreements between findings were mutually discussed and consensus was reached. Ninety-nine MRIs were reviewed in 67 patients with an average age of 14.4 (range 5 to 17) years at the time the MRI was performed. Thirty-seven girls and 30 boys were included. A pre hoc power analysis was performed using comparable studies in the adult population with similar patient and imaging numbers. Inclusion criteria were any patient under the age of 18 who had an MRI performed of the neuraxial spine with an available chart for review that stated the reason for ordering the imaging study. Exclusion criteria included any patient with a known history of trauma, infection, or congenital abnormalities. We reviewed all available MRIs but excluded four patients who did not meet inclusion criteria: two due to a history of trauma with visualized fracture on plain films, one with a known history of infection, and one with a known hemivertebra. A spinal incidental finding was defined as any finding on MRI that did not correlate with the provider's indication for ordering the study. For example, if a patient presented with leg pain and a physical exam consistent with radiculopathy, a finding of Schmorl nodule was considered incidental. Similarly, if spine imaging was performed for an abnormal scoliotic curve in an asymptomatic child and disk desiccation or end plate changes were noted, this was considered a spinal incidental finding. If the area (cervical, thoracic, lumbar) of complaint did not match the physical area of the positive finding, a spinal incidental finding was recorded wherein a patient complaining of low back pain with a positive cervical MRI was placed in the $-/+$ (spinal incidental) group. Positive findings included Schmorl nodes, disk protrusion, disk desiccation, congenital stenosis, end plate irregularities and modic changes, disk extrusion, a vertebral hemangioma, synovial cyst, and Tarlov cyst. Extraspinal incidental findings were not evaluated in this study.

The charts of those patients were then reviewed to determine the chief complaint, physical exam findings, and the provider's rationale for ordering the study in an attempt to find associations between the MRI findings with the patient's presentation. The data measured were coded as follows. A $+/+$ patient was one who presented with a complaint of neck or back pain and a positive MRI. A $-/-$ patient was one who was completely asymptomatic and had a normal MRI. A $+/-$ patient was one who presented with pain and had a negative MRI. A $-/+$ patient was one without symptoms and a positive MRI—our “spinal incidental finding” group. The data were analyzed to break down the rate of spinal incidental findings in the cervical, thoracic, and lumbar spine, respectively. If a

patient had more than one finding, those data were collected and analyzed separately to look at the incidence of that particular finding independent of the patient. The data were also analyzed as an overall per patient rate of spinal incidental findings.

Results

Overall 99 MRIs were reviewed and broken down into cervical, thoracic, and lumbar studies. Twenty-five cervical studies (\rightarrow Fig. 1), 21 thoracic studies (\rightarrow Fig. 2), and 53 lumbar studies (\rightarrow Fig. 3) in 64 patients were included. These studies were ordered for a variety of reasons ranging from complaints of back, neck, leg, and arm pain, as well as screening studies for scoliosis workup. Multiple patients had more than one finding on MRI (i.e., disk desiccation and Schmorl nodes), and these findings were evaluated separately but counted as a positive MRI finding (+) or a negative finding (–) to perform statistical analysis.

There were 31 positive MRIs of the 99, with the most common finding being disk protrusion (51.6%). This was most common in the lumbar spine. The second most common finding was Schmorl nodes (25.8%). The rate of positive findings in the lumbar spine was higher than in the cervical and thoracic spine (45.3 versus 0.2 and 0.9%, respectively).

In the spinal incidental finding group (those with a positive MRI and no pain, $-/+$), the overall rate was 8% when considering cervical, thoracic, and lumbar imaging as a whole. In this group, Schmorl nodes and disk protrusion were the two most common findings (37.5% each). The next most common spinal incidental finding was disk desiccation. Spinal incidental findings were most common in the lumbar spine (9.4%) versus the cervical spine (8%) or thoracic spine (4.7%). Other spinal incidental findings included a vertebral hemangioma and a Tarlov cyst. In the thoracic spine, the only spinal incidental finding was a central disk protrusion without spinal cord or nerve root compression.

Positive findings with correlating symptoms ($+/+$) comprised roughly 23% of the overall population, with the lumbar spine having the highest number of patients complaining of back pain with positive findings (19/53). The most common correlating MRI finding was disk protrusion, and this was most common at the L4–5 and L5–S1 levels.

Interestingly, Schmorl nodes seen in the same setting as disk desiccation and protrusion were more likely to be associated with pain (\rightarrow Table 1). Six of eight of these patients reported pain whereas only one of the patients with isolated Schmorl nodes presented with pain. None of the patients with Schmorl nodes had evidence of surrounding bony edema.

Discussion

In the adult population, several studies have established that there are age-dependent disk and osseoligamentous changes on MRI despite a lack of clinical complaints by the patient. Boden et al performed lumbar MRI on 67 asymptomatic patients and found evidence of disk herniation in 20% of those under the age of 60.¹ In those over the age of 60, 37%

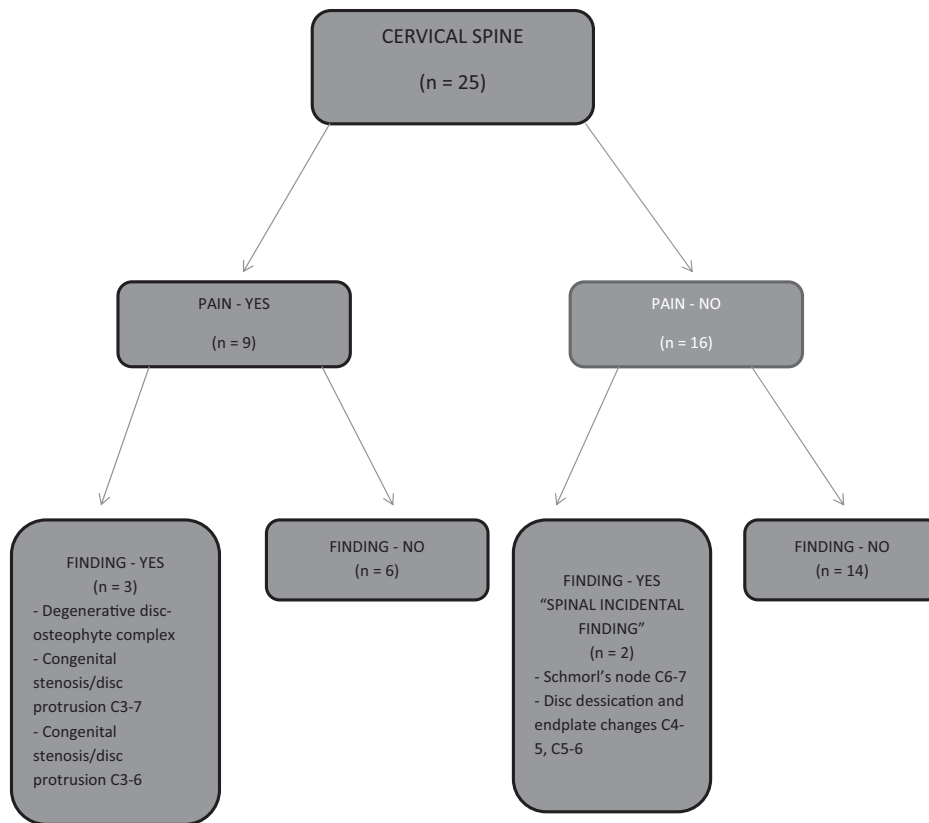


Fig. 1 Cervical spine magnetic resonance imaging flowchart.

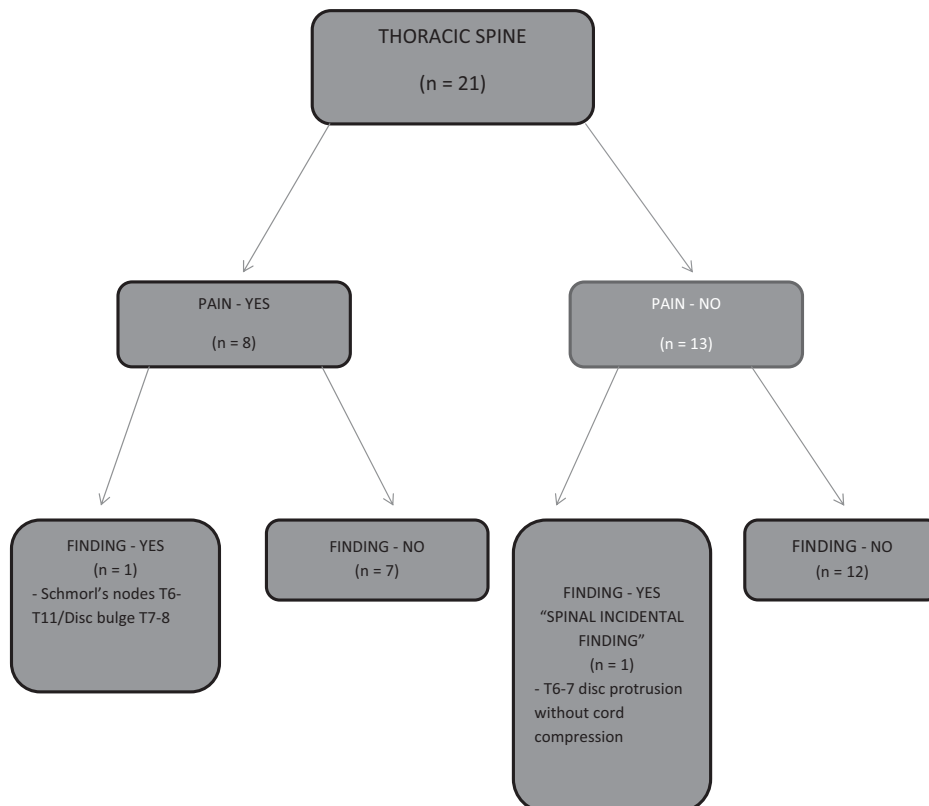


Fig. 2 Thoracic spine magnetic resonance imaging flowchart.

This document was downloaded for personal use only. Unauthorized distribution is strictly prohibited.

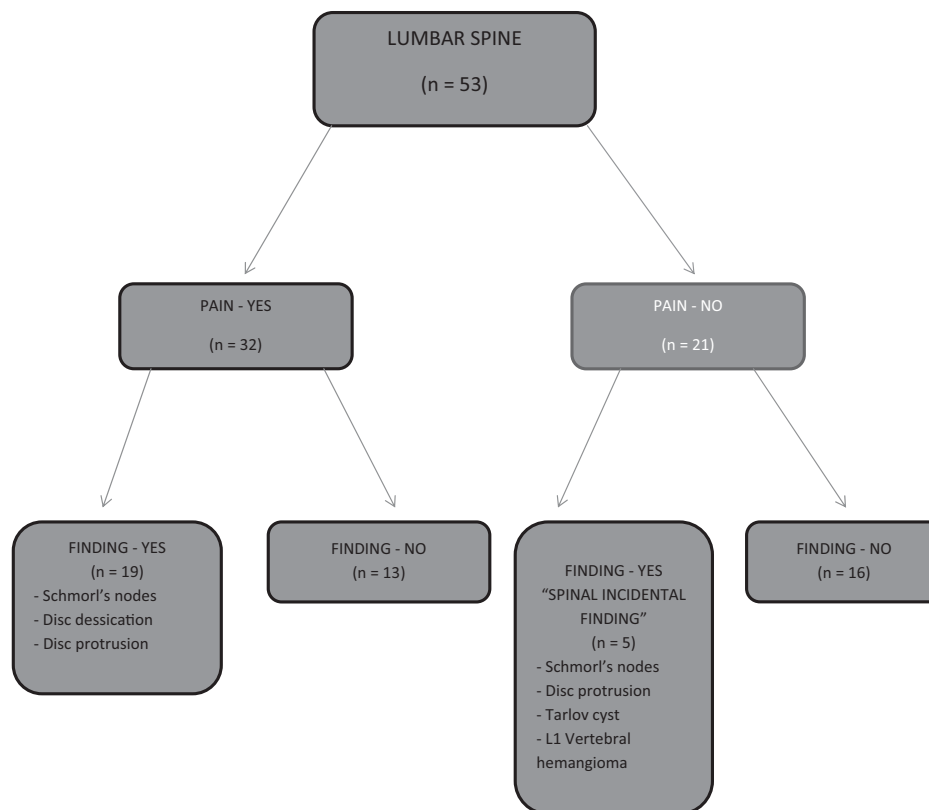


Fig. 3 Lumbar spine magnetic resonance imaging flowchart.

had a disk herniation and 21% had spinal stenosis despite being pain-free. Jensen et al performed MRI of the lumbar spine on 98 patients and found 64% had an abnormal disk and 14% with degenerative facet joints, 7% with spondylolisthesis, 7% with spondylosis, and 7% with central stenosis.² Weishaup et al evaluated a comparatively young patient group without back pain (average age of 35) and found 18% had actual disk extrusion, with a 2% rate of nerve root displacement, and 40% had disk protrusions.³

The use of MRI to predict the development of lower back pain has also been investigated. Borenstein et al studied MRIs of 67 asymptomatic individuals with no history of back pain and found a 31% incidence of disk or spinal canal abnormality.⁴ At 7-year follow-up, 58% had no back pain, and overall the investigators concluded that abnormal MRI scans of the lumbar spine did not predict the development or duration of low back pain, whereas with leg pain, there was more frequently a lesion that correlated with physical exam findings. In our study, 24 of 53 (45.3%) lumbar MRI studies had

positive findings. Of these, 19 (79.2%) patients complained of pain and 5 (20.8%) were asymptomatic.

Incidental findings in the cervical spine have not been as extensively studied in the literature. Giuliano et al performed a study aimed at determining the value of flexion and extension MRI in the traumatized cervical spine following low-impact acceleration-deceleration injury.⁵ The authors scanned the cervical spines of 100 asymptomatic adults and 100 accident victims with mean age of 35 years. There was a much lower overall incidence of disk herniation in the asymptomatic group. This correlates to our findings in the pediatric population with only 2 of 16 studies having a positive spinal incidental findings in asymptomatic patients compared with 3 of 9 of those with pain.

In the pediatric population, the presentation of back pain is concerning and warrants a full workup as the differential diagnosis is varied and ranges from spondylolysis and spondylolisthesis to infection, tumor, and disk herniation. In this population, disk herniation is more uncommon and more

Table 1 Findings of disk desiccation and Schmorl node^a

Schmorl node + disk desiccation/protrusion (n = 8)	Schmorl node alone (n = 2)
With pain (n = 6; 75%)	With pain (n = 1; 50%)
Without pain (n = 2; 25%)	Without pain (n = 1; 50%)

^aConcomitant finding of disk desiccation in addition to Schmorl node was more likely to be correlated with pain than an isolated Schmorl node. None of the patients with Schmorl nodes had evidence of surrounding bony edema in this study.

frequently related to trauma as opposed to the degenerative causes in the adult population. The peak incidence occurs at age 10 to 18, and disk herniation is more common in males with 50% having a previous traumatic incident that initiated the workup.^{6,7} MRI is useful as an adjunct to a complete history and physical examination and holds specific indications especially in the evaluation of a child with scoliosis. Indications for an MRI in patients with scoliosis include an abnormal neurologic examination, left thoracic curve, juvenile scoliosis, a rapidly progressive curve, and back pain. Ramirez et al further investigated this practice by performing a retrospective study of 2,442 patients and found that a left thoracic curve or abnormal neurologic examination best predicted an underlying pathologic condition.⁸ Nine percent of patients who presented with back pain had an abnormal finding on MRI, and there was a significant association between back pain and age more than 15 years, skeletal maturity, postmenarchal status, and a history of injury. In a prospective trial, Evans et al performed MRI examinations of the spine and brain in patients with scoliosis whose onset occurred between 4 and 12 years of age.⁹ The authors found a 26% rate of neuroanatomical abnormalities to include Chiari malformations, a syrinx, and an astrocytoma. Of these patients, four had left-sided curves but no clinical features were found that could reliably predict MRI abnormalities. Therefore, these findings warranted MRI of all patients with juvenile onset scoliosis prior to surgical correction.

Lower back pain in general is a relatively common complaint in the adolescent population and can lead to MRI evaluation as an adjunct to the workup. Kjaer et al performed a cross-sectional cohort study of 439 13-year-old children with the goal of describing associations between abnormal MRI findings and low back pain.¹⁰ They found that disk protrusions, end plate changes, and anterolisthesis were strongly associated with seeking care for lower back pain and degenerative disk findings were not as strongly associated with seeking care for back pain.

Another study investigated the relationship between radiographic abnormalities of the lumbar spine and the incidence of low back pain in high school rugby players¹¹; 74.3% of the subjects had a radiographic abnormality, including spondylolysis, disk space narrowing, and Schmorl nodes. Both the groups with and without radiographic abnormalities had a 40% incidence of pain complaints.

Schmorl nodules have been implicated in the etiology of back pain in the pediatric population, but the literature is inconsistent. It appears that MRI findings consistent with acute nodule formation may be related to back pain. There have been reports of symptomatic cases, but two studies found that only vascularized Schmorl nodules or those with surrounding bony edema cause pain. Stähler et al retrospectively reviewed MRIs of the spine and found that vascularized Schmorl nodules were larger and more frequently associated with bone marrow edema in patients with back pain.¹² Takahashi et al found a high T2 signal in the bone marrow surrounding the nodule in all of their symptomatic cases.¹³ This was not present in any asymptomatic individuals. The authors postulated that the nodules act similar to vertebral

compression fractures, which become less symptomatic as inflammation decreases. Of note, none of the patients in our study had bony edema surrounding their Schmorl nodules. However, we found that Schmorl nodes were often found in the same region as other pathology such as disk desiccation and protrusion and that those patients were more likely to report pain compared with those with isolated Schmorl nodes.

Alyas et al studied 33 elite adolescent tennis players who were asymptomatic and found an 84.8% rate of abnormalities ranging from chronic stress reactions in the pars to synovial cysts and early facet arthropathy.¹⁴ Thirteen players had evidence of disk desiccation and disk bulging most often at L4/5 and L5/S1. In our study group, disk desiccation and herniated disks constituted a large number of the findings but were more commonly associated with a patient presenting with pain (+/+ group) and less commonly placed in the spinal incidental finding (-/+) group. The majority of the patients who had a disk protrusion presented with pain, and this was most common at the L4-5 and L5-S1 levels. This is similar to the adult population.

To our knowledge, there are no studies that look specifically at the frequency of spinal incidental findings on MRI evaluation of the cervical, thoracic, and lumbar spine in the pediatric population. Park et al investigated the frequency and type of spinal incidental findings in subjects aged 1 to 97 years who were undergoing evaluation for a herniated disk¹⁵; 8.7% of patients had a spinal incidental finding with the most common being fibrolipoma, followed by Tarlov cyst and vertebral hemangioma. Within our small patient population, we encountered one synovial cyst, one vertebral hemangioma, and one Tarlov cyst, suggesting that these may be relatively common findings in the pediatric population. Incidental findings outside of the spinal elements are also important to appropriately address, such as thyroid and salivary gland lesions on cervical spine imaging, pulmonary nodules on thoracic evaluation, and renal, splenic, pancreatic, gastrointestinal, uterine, and ovarian lesions on lumbar and sacral evaluation.¹⁶ Lymphadenopathy and vascular lesions are also easily visualized with MRI, and their frequency is well documented.^{16,17} Extraplural incidental findings remained outside the scope of this study.

The weakness of this study is its retrospective nature. The ideal study design would allow for MRI evaluations in a volunteer asymptomatic pediatric population. However, given the restrictions in this patient population with informed consent and the need for supplemental anesthesia in the younger patient to obtain adequate imaging, this study design was deemed less practical. The relatively low number of subjects in the study also made it impossible to detect the prevalence of rare spinal incidental findings.

Conclusion

MRI is a valuable imaging modality in the workup of the pediatric patient with neck, back, or leg pain or in the evaluation of the patient with scoliosis with an abnormal neurologic examination, left thoracic curve, juvenile scoliosis,

rapidly progressing curve, and concomitant back pain. However, despite its sensitivity at detecting abnormalities, spinal incidental findings will be encountered during its routine use. We identified a 14% rate of spinal incidental findings in asymptomatic patients in our review, including end plate changes, disk desiccation, Tarlov cysts, Schmorl nodules, and annular tears. We urge the provider to exercise caution when interpreting these studies, as it is important to correlate these findings with history and physical examination.

Disclosures

Uma E. Ramadorai, none
Justin M. Hire, none
John G. DeVine, none

References

- 1 Boden SD, Davis DO, Dina TS, Patronas NJ, Wiesel SW. Abnormal magnetic-resonance scans of the lumbar spine in asymptomatic subjects. A prospective investigation. *J Bone Joint Surg Am* 1990; 72(3):403–408
- 2 Jensen MC, Kelly AP, Brant-Zawadzki MN. MRI of degenerative disease of the lumbar spine. *Magn Reson Q* 1994;10(3):173–190
- 3 Weishaupt D, Zanetti M, Hodler J, Boos N. MR imaging of the lumbar spine: prevalence of intervertebral disk extrusion and sequestration, nerve root compression, end plate abnormalities, and osteoarthritis of the facet joints in asymptomatic volunteers. *Radiology* 1998;209(3):661–666
- 4 Borenstein DG, O'Mara JW Jr, Boden SD, et al. The value of magnetic resonance imaging of the lumbar spine to predict low-back pain in asymptomatic subjects: a seven-year follow-up study. *J Bone Joint Surg Am* 2001;83-A(9):1306–1311
- 5 Giuliano V, Giuliano C, Pinto F, Scaglione M. The use of flexion and extension MR in the evaluation of cervical spine trauma: initial experience in 100 trauma patients compared with 100 normal subjects. *Emerg Radiol* 2002;9(5):249–253
- 6 Epstein JA, Epstein NE, Marc J, Rosenthal AD, Lavine LS. Lumbar intervertebral disk herniation in teenage children: recognition and management of associated anomalies. *Spine (Phila Pa 1976)* 1984;9(4):427–432
- 7 Fraser RD, Sandhu A, Gogan WJ. Magnetic resonance imaging findings 10 years after treatment for lumbar disc herniation. *Spine (Phila Pa 1976)* 1995;20(6):710–714
- 8 Ramirez N, Johnston CE, Browne RH. The prevalence of back pain in children who have idiopathic scoliosis. *J Bone Joint Surg Am* 1997; 79(3):364–368
- 9 Evans SC, Edgar MA, Hall-Craggs MA, Powell MP, Taylor BA, Noordeen HH. MRI of “idiopathic” juvenile scoliosis. A prospective study. *J Bone Joint Surg Br* 1996;78(2):314–317
- 10 Kjaer P, Leboeuf-Yde C, Sorensen JS, Bendix T. An epidemiologic study of MRI and low back pain in 13-year-old children. *Spine (Phila Pa 1976)* 2005;30(7):798–806
- 11 Iwamoto J, Abe H, Tsukimura Y, Wakano K. Relationship between radiographic abnormalities of lumbar spine and incidence of low back pain in high school rugby players: a prospective study. *Scand J Med Sci Sports* 2005;15(3):163–168
- 12 Stähler A, Bellan M, Weiss M, Gärtner C, Brossmann J, Reiser MF. MR imaging of enhancing intraosseous disk herniation (Schmorl's nodes). *AJR Am J Roentgenol* 1997;168(4):933–938
- 13 Takahashi K, Miyazaki T, Ohnari H, Takino T, Tomita K. Schmorl's nodes and low-back pain. Analysis of magnetic resonance imaging findings in symptomatic and asymptomatic individuals. *Eur Spine J* 1995;4(1):56–59
- 14 Alyas F, Turner M, Connell D. MRI findings in the lumbar spines of asymptomatic, adolescent, elite tennis players. *Br J Sports Med* 2007;41(11):836–841, discussion 841
- 15 Park HJ, Jeon YH, Rho MH, et al. Incidental findings of the lumbar spine at MRI during herniated intervertebral disk disease evaluation. *AJR Am J Roentgenol* 2011;196(5):1151–1155
- 16 Quattrocchi CC, Giona A, Di Martino AC, et al. Extra-spinal incidental findings at lumbar spine MRI in the general population: a large cohort study. *Insights Imaging* 2013;4(3): 301–308
- 17 Kamath S, Jain N, Goyal N, Mansour R, Mukherjee K. Incidental findings on MRI of the spine. *Clin Radiol* 2009; 64(4):353–361