



OPEN ACCESS

Technical aspects of web device in aneurysm treatment

Jeremy Peterson,^{1,2} Nitin Goyal,^{1,3} Adam S Arthur ,^{1,2} David Fiorella⁴

► Additional material is published online only. To view please visit the journal online (<http://dx.doi.org/10.1136/neurintsurg-2019-015748>).

¹Semmes-Murphey Neurologic and Spine Institute, Memphis, Tennessee, USA

²Department of Neurosurgery, University of Tennessee Health Science Center, Memphis, Tennessee, USA

³Department of Neurology, University of Tennessee Health Science Center, Memphis, Tennessee, USA

⁴Stony Brook University Hospital, Stony Brook, New York, USA

Correspondence to

Dr Adam S Arthur, Semmes-Murphey Neurologic and Spine Institute, Memphis, TN 38120, Tennessee, USA; aarthur@semmes-murphey.com

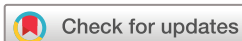Received 19 December 2019

Revised 17 April 2020

Accepted 21 April 2020

Published Online First

31 May 2020



© Author(s) (or their employer(s)) 2020. Re-use permitted under CC BY-NC. No commercial re-use. See rights and permissions. Published by BMJ.

To cite: Peterson J, Goyal N, Arthur AS, *et al.* *J NeuroInterv Surg* 2020;**12**:924.

ABSTRACT

Wide-neck bifurcation aneurysms (WNBA)s make up 26–36% of all brain aneurysms. Intracascular flow disruption is an innovative technique for the treatment of WNBA)s. The Woven EndoBridge (WEB) device (Sequent Medical, Aliso Viejo, California USA) is the only United States Food and Drug Administration approved intracascular flow disruption device. In this video article, a few cases of intracranial aneurysms treated with the WEB device are presented and various aspects of treating WNBA)s with the WEB device, including aneurysm/device selection strategies, and procedural technique, are discussed (video 1).

Twitter Adam S Arthur @AdamArthurMD

Acknowledgements The authors thank Andrew J. Gienapp (Neuroscience Institute, Le Bonheur Children's Hospital and Department of Neurosurgery, University of Tennessee Health Science Center, Memphis, TN, USA) for technical and copy editing, preparation of the manuscript for publishing, and providing publication assistance.

Contributors All authors of this work met ICMJE criteria for authorship and made substantial contributions to the conception and design, acquisition of data, analysis and interpretation of data, drafting, critical revising, and final approval of this manuscript.

Funding The authors have not declared a specific grant for this research from any funding agency in the public, commercial or not-for-profit sectors.

Competing interests JP and NG report no disclosures or conflict of interests. ASA is a consultant for Balt, Johnson and Johnson, Leica, Medtronic, Microvention, Penumbra, Scientia, Siemens, and Stryker; receives research support from Microvention, Penumbra, and Siemens; and is a shareholder in Bendit, Cerebrotech,

Endostream, Magneto, Marblehead, Neurogami, Serenity, Synchron, Triad Medical and Vascular Simulations outside of the submitted work. DF is a consultant for Balt, Marblehead, Medtronic, Stryker, Microvention, Stryker, Penumbra, and Cerenovus; receives research support from Cerenovus, Medtronic, Stryker, Siemens, Microvention, and Penumbra, and royalties from Codman; and is a stockholder for Marblehead, Neurogami, and Vascular Simulations outside of the submitted work.

Patient consent for publication Not required.

Provenance and peer review Not commissioned; externally peer reviewed.

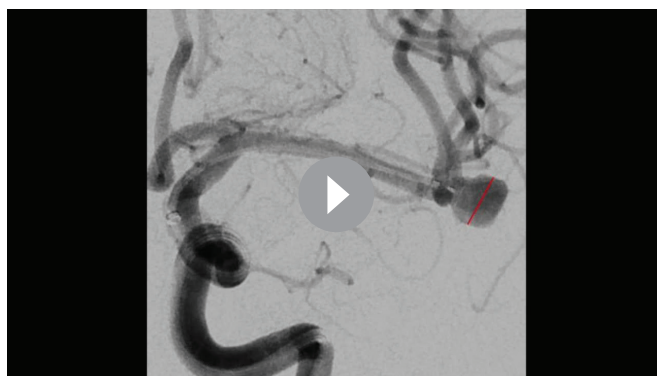
Open access This is an open access article distributed in accordance with the Creative Commons Attribution Non Commercial (CC BY-NC 4.0) license, which permits others to distribute, remix, adapt, build upon this work non-commercially, and license their derivative works on different terms, provided the original work is properly cited, appropriate credit is given, any changes made indicated, and the use is non-commercial. See: <http://creativecommons.org/licenses/by-nc/4.0/>.

ORCID iD

Adam S Arthur <http://orcid.org/0000-0002-1536-1613>

REFERENCES

- 1 De Leacy RA, Fargen KM, Mascitelli JR, *et al.* Wide-neck bifurcation aneurysms of the middle cerebral artery and basilar apex treated by endovascular techniques: a multicentre, core lab adjudicated study evaluating safety and durability of occlusion (branch). *J Neurointerv Surg* 2019;**11**:31–6.
- 2 Goyal N, Hoit D, DiNitto J, *et al.* How to web: a practical review of methodology for the use of the Woven EndoBridge. *J Neurointerv Surg* 2020;**12**:512–20.
- 3 Pierot L, Liebig T, Sychra V, *et al.* Intracascular flow-disruption treatment of intracranial aneurysms: preliminary results of a multicenter clinical study. *AJNR Am J Neuroradiol* 2012;**33**:1232–8.
- 4 Pierot L, Spelle L, Molyneux A, *et al.* Clinical and anatomical follow-up in patients with aneurysms treated with the web device: 1-year follow-up report in the cumulated population of 2 prospective, multicenter series (WEBCAST and French Observatory). *Neurosurgery* 2016;**78**:133–41.



Video 1 1–4